

Systematic Review on Interventions for Recurrent Corneal Erosion (RCE).<sup>2</sup> There was a mistake in our review. According to Eke *et al*,<sup>3</sup> additional nightly ointment is associated with significantly higher risk of increased symptoms of RCE at 3 months follow up. We have corrected the text in the review accordingly as outlined below. In terms of assessment of bias, it is not affected. Our conclusion from the review stands that only a few papers qualify for meta-analysis using the Cochrane protocol and more research is needed for a better understanding on the best available treatment for RCE.

Eke *et al*<sup>3</sup> reported, for patients whose injury was caused by a fingernail, symptoms were significantly more prevalent ( $P = 0.016$ ) and more severe in the group receiving additional ointment at 3 months. Eke *et al*'s study included only a small number of patients ( $n = 21$ ) who were still symptomatic at 3 months, following the acute injury. Recurrent erosion typically persists beyond 3 months.<sup>4</sup> The use of additional nightly ointment did not appear to have any effect on the incidence of macroform RCE by 2 years,<sup>3</sup> but the small numbers and possible incomplete data capture preclude us from drawing a firm conclusion regarding the effects of nightly ointment in recurrent corneal erosion.<sup>4</sup>

The text in our review now states, 'The addition of lubricating ointment at night to the standard therapy for traumatic corneal abrasion following the fingernail injury resulted in significantly more patients with mild or moderate symptoms of recurrent corneal erosion at 3 months compared to the control group that received standard therapy alone (OR 5.67, 95% CI 1.28 to 25.0). At 2 years, on review of the case notes, 2/42 patients had presented back to the trial centre with recurrent corneal erosion, one in the treatment group and one in the control (OR 0.90, 95% CI 0.05 to 15.49).'

'For averting the development of recurrent corneal erosion following a traumatic corneal abrasion due to a fingernail injury, lubricating ointment at night for 2 months in addition to standard treatment (cyclopentolate drops, then chloramphenicol ointment for 5 days) led to increased development of the symptoms of recurrent corneal erosion at 3 months compared to standard therapy alone.<sup>3</sup> This was the only included study to examine measures to avert the development of recurrent corneal erosion following traumatic corneal abrasion; clearly more studies are needed as a range of treatment options are available for traumatic corneal erosions.<sup>5,6</sup> It is common practice to treat a traumatic corneal abrasion with antibiotic and/or lubricating ointment; however, such therapy is not always continued for months.'

#### Conflict of interest

The authors declare no conflict of interest.

#### References

- Spitzer D, Habib A, Imonikhe R, Raina J. Lubricants to prevent recurrent corneal erosion: an error in the Cochrane review *Eye* 2013; **27**(11): 1329–1330.
- Watson SL, Lee M-HH, Barker NH. Interventions for recurrent corneal erosions. *Cochrane Database Syst Rev* 2012; **9**: CD001861.
- Eke T, Morrison DA, Austin DJ. Recurrent symptoms following traumatic corneal abrasion: prevalence, severity, and the effect of a simple regimen of prophylaxis. *Eye (Lond)* 1999; **13**(Part 3a): 345–347.
- Heyworth P. Reply to Topical ointment does not prevent recurrent symptoms following traumatic corneal abrasion. *Br J Ophthalmol* 1998; **82**(9): 1097.
- Wilson SA, Last A. Management of corneal abrasions. *Am Fam Physician* 2004; **70**(1): 123–128.
- Calder L, Balasubramanian S, Stiehl I. Lack of consensus on corneal abrasion management: results of a national survey. *CJEM* 2004; **6**(6): 402–407.

S Watson and H Lee

Save Sight Institute, University of Sydney, Sydney,  
New South Wales, Australia  
E-mail: Stephanie.watson@sydney.edu.au

*Eye* (2013) **27**, 1330–1331; doi:10.1038/eye.2013.191;  
published online 30 August 2013

---

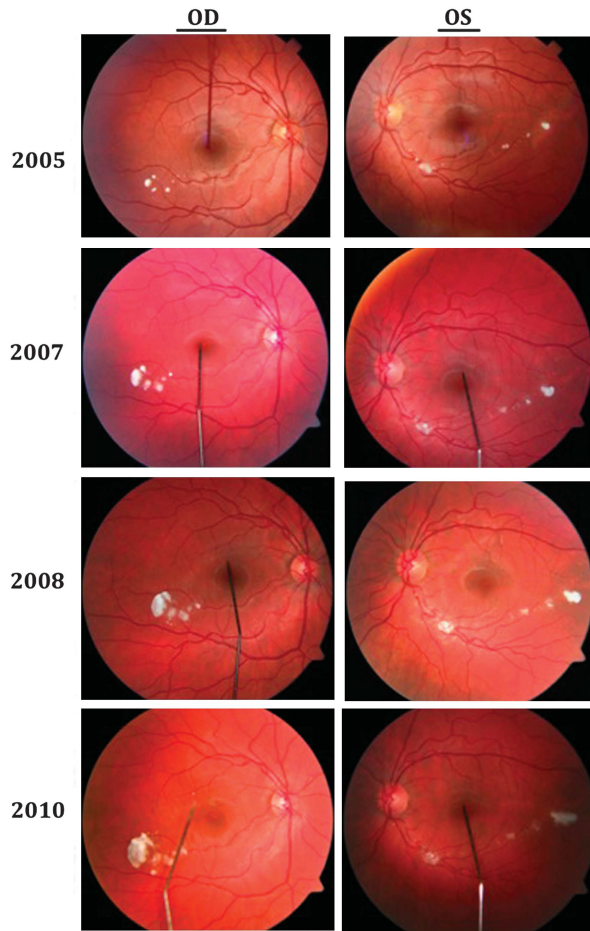
#### Sir, Progression of retinal changes in Gaucher disease: a case report

Gaucher disease is the most common lysosomal storage disease with an estimated incidence of 1/57 000.<sup>1</sup> It results from a deficiency in  $\beta$ -glucocerebrosidase and accumulation of glucosylceramide. Typically patients develop hepatosplenomegaly and osseous manifestations. Neuronopathic involvement is less common, but ocular manifestations including oculomotor apraxia and supranuclear gaze abnormalities are usual in Types II and III. Intraocular manifestations including corneal clouding and retinal lesions have also been reported.<sup>2,3</sup> However, little is known about their natural progression.

#### Case report

We describe the progression of retinal lesions over a 5-year period in a French-Canadian girl born to non-consanguineous parents and diagnosed with Gaucher disease Type III at 21 months of age after presenting with hepatosplenomegaly and recurrent infections. Investigations revealed anaemia, thrombocytopenia and elevated acid phosphatase. The diagnosis was confirmed by low glucocerebrosidase activity. Genetic testing revealed homozygosity for the L444P mutation commonly associated with Type III disease. Treatment with Imiglucerase 60 Units/kg every other week was started.

At first her neurological examination was normal but slowing of horizontal saccades was noted at the age of 5 years. Fundoscopy revealed white globular lesions OU at the age of 13 years in 2005, which were confirmed to be

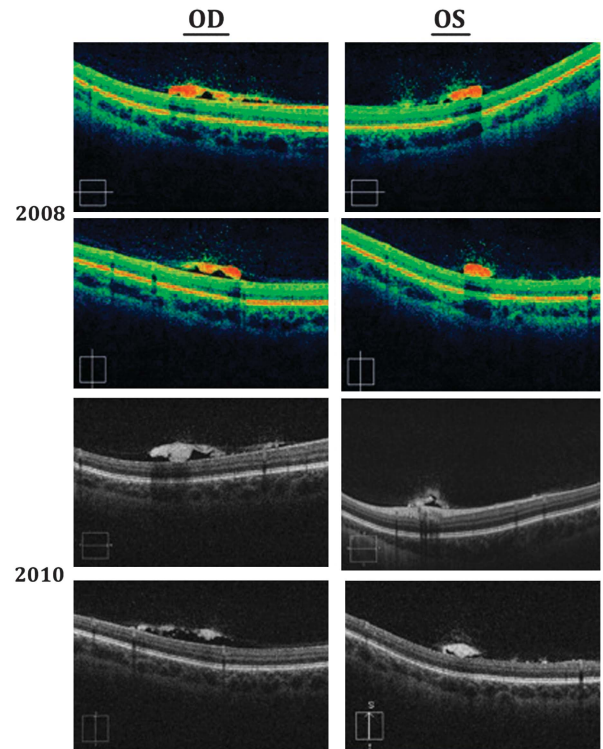


**Figure 1** OU fundus photos between 2005 and 2010.

pre-retinal on OCT (Figures 1 and 2). Subsequent annual visits showed slow increase in size more pronounced in OD. Visual acuity remained stable at 20/20 OU and there were no changes in electroretinography patterns.

**Comment**

Retinal lesions have been infrequently reported in Gaucher patients and were thought to represent the eponymous Gaucher cells: pathognomonic macrophages distended with sphingolipid forming a ‘crumpled silk’ appearance.<sup>3–5</sup> The pathophysiology of the retinal Gaucher cells is yet to be explained, but the accumulation of higher levels of circulating glucosylceramide in unusual systemic locations has been suggested as causal.<sup>5</sup> Progression over time was only reported by Stark<sup>6</sup> who described chalk-white spots of varying sizes mainly located peripherally without foveal interference. In our case, the reported lesions did not shrink despite glucocerebrosidase replacement possibly explaining the immune-privilege enjoyed by the eye, which prevents such large proteins from crossing the blood–brain barrier. Although our patient had normal acuity and ERG findings, Seidova *et al*<sup>5</sup> reported pre-retinal lesions and subclinical abnormalities on one ERG recording, which



**Figure 2** OU OCT in 2008 and 2010.

was attributed to the accumulation of storage lipid in glial cells. We believe that our patient’s visual acuity was not affected because the reported lesions spared the fovea. Further studies will help to shed light on the precise nature of the retinal lesions seen in Gaucher disease.

**Conflict of interest**

The authors declare no conflict of interest.

**References**

- 1 Meikle PJ, Hopwood JJ, Clague AE, Carey WF. Prevalence of lysosomal storage disorders. *JAMA* 1999; **281**(3): 249–254.
- 2 Abrahamov A, Elstein D, Gross-Tsur V, Farber B, Glaser Y, Hadas-Halpern I *et al*. Gaucher’s disease variant characterised by progressive calcification of heart valves and unique genotype. *Lancet* 1995; **346**(8981): 1000–1003.
- 3 Cogan DG, Chu FC, Gittinger J, Tychsen L. Fundal abnormalities of Gaucher’s disease. *Arch Ophthalmol* 1980; **98**(12): 2202–2203.
- 4 Petrohelos M, Tricoulis D, Kotsiras I, Vouzoukos A. Ocular manifestations of Gaucher’s disease. *Am J Ophthalmol* 1975; **80**(6): 1006–1010.
- 5 Seidova SF, Kotliar K, Foerger F, Klopfer M, Lanzl I. Functional retinal changes in Gaucher disease. *Doc Ophthalmol* 2009; **118**(2): 151–154.
- 6 Stark H. [Eye changes in Gaucher’s disease]. *Klin Monbl Augenheilkd* 1983; **183**(3): 216–220.

RG Coussa<sup>1</sup>, JCP Roos<sup>2</sup>, M Aroichane<sup>1</sup>, M-C Miron<sup>3</sup> and LH Ospina<sup>1</sup>

<sup>1</sup>Department of Pediatric Ophthalmology and Neuro-Ophthalmology, Centre Hospitalier Universitaire Sainte-Justine, Université de Montréal, Montréal, Québec, Canada

<sup>2</sup>Department of Medicine, University of Cambridge, Cambridge, UK

<sup>3</sup>Department of Medical Imaging, Sainte-Justine Hospital, University of Montréal, Montréal, Québec, Canada

E-mail: lhospina@gmail.com

*Eye* (2013) 27, 1331–1333; doi:10.1038/eye.2013.180; published online 23 August 2013

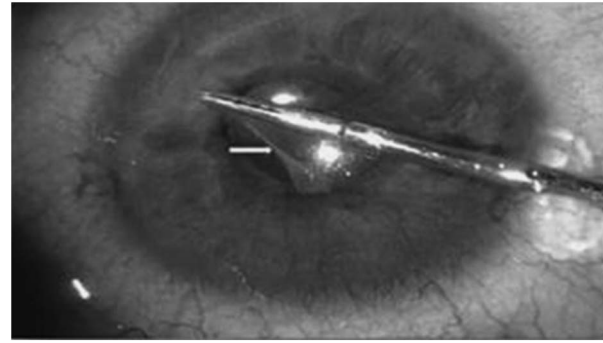
Sir,  
**Capsular blockage syndrome in a child: a case report**

The case report is from Great Ormond Street Hospital, London, UK. Capsular blockage syndrome (CBS) is a rare complication of cataract surgery. We report a case of 7 year old girl with CBS after lensectomy and PCIOL implantation for uveitic cataract.

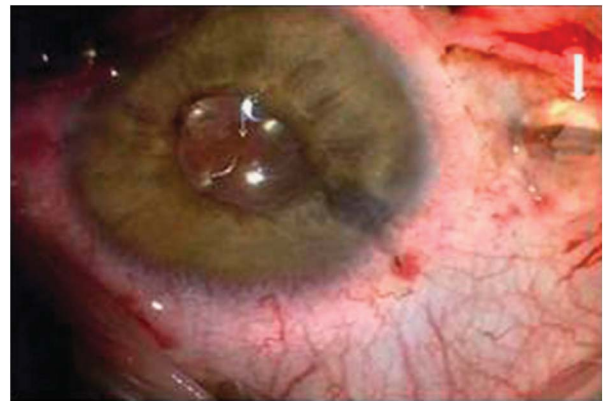
**Case report**

A 7-year-old girl with ANA positive, oligoarticular onset Juvenile idiopathic arthritis (JIA) had left cataract extraction with PCIOL. She had been uveitis free for 2 years having been on methotrexate and systemic steroids (1 mg/kg). She had posterior synechiolysis, TIPP (two-incision push-pull rhexis—a variant of continuous curvilinear capsulorrhexis (CCC))<sup>1</sup> anterior and posterior rhexis approximately 5 and 3.5 mm in diameter, respectively, lens aspiration, anterior vitrectomy, in the bag hydrophobic acrylic IOL implantation (MA60AC, Alcon) and a peripheral iridectomy. She was given intracameral preservative-free dexamethasone (0.2 ml of 4 mg/ml), intravitreal and orbital floor triamcinolone and subconjunctival cefuroxime.

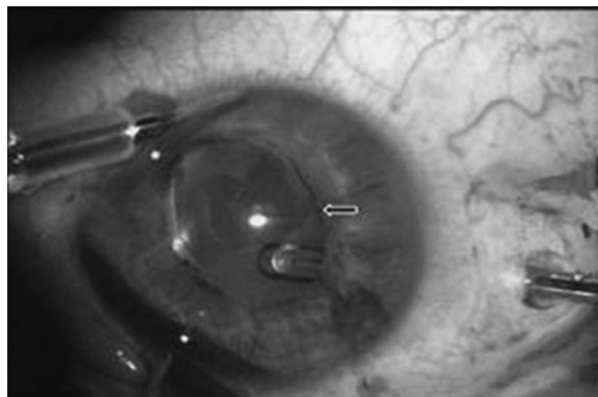
Postoperatively she received topical steroid/antibiotic drops and a 6 weeks oral steroid taper. Ocular examination and intraocular pressure (IOP) was normal in the immediate postoperative period. Four months later, she presented with left decreased vision (BCVA 20/200), shallow anterior chamber, a pupillary membrane, and visual axis opacification. The right eye was normal. IOP was 12 mmHg in both the eyes. Surgical removal of the anterior membrane (Figure 1) had no effect on the anterior chamber depth. However, pars plana posterior membranectomy resulted in rapid egress of the bag contents (clear fluid) with immediate deepening of anterior chamber (Figures 2 and 3). The diagnosis of capsular blockage syndrome (CBS) was made (see Supplementary Video). The patient recovered 20/80 of BCVA after 6 weeks.



**Figure 1** Intra-operative picture showing removal of anterior membrane (white arrow), fixed pupil, and shallow anterior chamber.



**Figure 2** Intra-operative picture showing an incision into a thick membrane in the visual axis. (Thin arrow) and MVR blade is being removed. As MVR is withdrawn, gush of aqueous-like fluid (thick arrow) is seen.



**Figure 3** Intra-operative picture showing deep anterior chamber, dilated pupil with anterior vitrectomy and enlargement of posterior membrane opening.

**Comment**

CBS is a rare complication of cataract extraction with PCIOL and CCC. A closed chamber forms between the PCIOL and the posterior capsule due to anterior capsule