



Nasal and Pulmonary Toxicity of Titanium Dioxide Nanoparticles in Rats

Soonjin Kwon^{1,2}, Young-Su Yang¹, Hyo-Seon Yang¹, Jinsoo Lee^{1,2}, Min-Sung Kang¹,
Byoung-seok Lee³, Kyuhong Lee¹ and Chang-Woo Song¹

¹Inhalation Toxicology Center, Korea Institute of Toxicology Jeongeup Campus, Jeollabuk-do

²Major of Pharmacology and Toxicology, University of Science and Technology, Daejeon

³Toxicologic Pathology Center, Korea Institute of Toxicology, Daejeon, Korea

(Received November 28, 2012; Revised December 3, 2012; Accepted December 3, 2012)

In recent decades, titanium dioxide (TiO₂) nanoparticles have been used in various applications, including paints, coatings, and food. However, data are lacking on the toxicological aspects associated with their use. The aim of this study was to assess the inhalation toxicity of TiO₂ nanoparticles in rats by using inhalation exposure. Male Wistar rats were exposed to TiO₂ nanoparticles for 2 weeks (6 hr/day, 5 days/week) at a mean mass concentration of 11.39 ± 0.31 mg/m³. We performed time-course necropsies at 1, 7, and 15 days after exposure. Lung inflammation and injury were assessed on the basis of the total and individual cell counts in bronchoalveolar lavage fluid (BALF), and by biochemical assays, including an assay for lactate dehydrogenase (LDH). Furthermore, histopathological examination was performed to investigate the lungs and nasal cavity of rats. There were no statistically significant changes in the number of BALF cells, results of biochemical assays of BALF and serum, and results of cytokine analysis. However, we did observe histopathological changes in the nasal cavity tissue. Lesions were observed at post-exposure days 1 and 7, which resolved at post-exposure day 15. We also calculated the actual amounts of TiO₂ nanoparticles inhaled by the rats. The results showed that the degree of toxicity induced by TiO₂ nanoparticles correlated with the delivered quantities. In particular, exposure to small particles with a size of approximately 20 nm resulted in toxicity, even if the total particle number was relatively low.

Key words: Titanium dioxide, Nanoparticle, Nose-only exposure, Nasal toxicity, BAL fluid, Lung

INTRODUCTION

Titanium dioxide (TiO₂) nanoparticles have been used as a white pigment in paint, a food-coloring agent and a wastewater remediation agent (Nordman and Berlin, 1986; Lomer *et al.*, 2002; Cho *et al.*, 2004). Additionally, they have been widely used as an ultraviolet blocker in sunscreens (Sadrieh *et al.*, 2010). Recently, researchers have investigated whether TiO₂ nanoparticles may be also useful as a photocatalyst and as an important material of solar cells. In addition, studies are being conducted to establish new approaches for medical treatment using photosensitive TiO₂ nanoparticles (Gurr *et al.*, 2005). TiO₂ nanoparticles

may be applicable to various coating or surface treatment processes. Therefore, widespread human exposure may occur during the production processes and applications of TiO₂ nanoparticles.

Upon inhalation, TiO₂ nanoparticles are deposited in all regions of the respiratory system and distributed into other organs through cardiovascular circulation. Previous studies have reported cases of TiO₂-induced fibrosis (Bermudez *et al.*, 2004; Driscoll *et al.*, 1991) and lung inflammation (Nemmar *et al.*, 2008; Hhr *et al.*, 2002; Park *et al.*, 2009; van Ravenzwaay *et al.*, 2009). In 2006, the International Agency for Research on Cancer (IARC) classified pigment-grade TiO₂ as a group 2B carcinogen, which may be harmful to humans (Baan, 2007). Furthermore, the Workplace Hazardous Materials Information System (WHMIS) groups TiO₂ as D2A, which indicates chemical carcinogenic risk to humans. Therefore, it is necessary to assess the risk of TiO₂ nanoparticles and to collect toxicity information, since they are still in use, but possibly carcinogenic.

In this study, we exposed male Wistar rats to dispersed aerosols of TiO₂ nanoparticles using a nanoparticle generator (SIBATA, Japan), which was used to distribute a consis-

Correspondence to: Chang-Woo Song, Inhalation Toxicology Center, Korea Institute of Toxicology, 1051, Shinjeong-dong, Jeongeup-si, Jeollabuk-do 580-185, Korea
E-mail: cwsong@kitox.re.kr

This is an Open-Access article distributed under the terms of the Creative Commons Attribution Non-Commercial License (<http://creativecommons.org/licenses/by-nc/3.0>) which permits unrestricted non-commercial use, distribution, and reproduction in any medium, provided the original work is properly cited.

tent concentration of nanoparticles ($11.39 \pm 0.31 \text{ mg/m}^3$) to animals for 2 weeks (6 h/day, 5 days/week). Considering the potential health effects of nanoparticles, we suggest that examination of chronic effects from exposure is more important than assessment of fetal injuries associated with acute response. For that reason, we conducted this study for 2 weeks and compared our results with those from previous TiO_2 inhalation toxicity studies that were carried out for 5 days (Driscoll *et al.*, 1991; van Ravenzwaay *et al.*, 2009; Ma-Hock *et al.*, 2009) or 13 weeks (Bermudez *et al.*, 2002; Bermudez *et al.*, 2004).

MATERIALS AND METHODS

Test material and TiO_2 nanoparticle generation. TiO_2 (Titanium dioxide, 811X1240) nanoparticles were obtained from KANTO CHEMICAL Corporation (Japan). To generate TiO_2 nanoparticles, we dispersed test material in distilled water at a concentration of 0.4% w/w. We generated the test material suspension using a nanoparticle generator connected to a nose-only exposure system (SIBATA, Japan). The nanoparticle generator consisted of 3 main parts, including a nebulizer for spraying test materials, a heater to blow away the solvent of the aerosol, and a neutralizer for removing the charges of the materials. The treated group of animals were exposed to the generated aerosols for 2 weeks (6 h/day, 5 days/week). We determined the target mass concentration of approximately 10 mg/m^3 using the scanning mobility particle sizer (SMPS) 3034 (TSI, USA). The control animal group was exposed to clean air only.

Animals and conditions. This study was conducted using 7 week-old male Crl:WI (Han) Wistar rats that were obtained from Orient Bio (Korea). The animals were acclimated for 10 days before we began the study. The rats were maintained in cages at $23 \pm 3^\circ\text{C}$, with relative humidity of $50 \pm 10\%$, and a 12 hour light-dark cycle. The rats were fed rodent diet (Labdiet; PMI Nutrition International Inc., USA) and filtered water *ad libitum*. The animals were examined for clinical signs once a day for the duration of exposure. After 2 weeks of exposure, we conducted necropsies at 1, 7, and 15 days. Subsequently, we weighed the organs, performed histopathological examination, and analyzed the bronchoalveolar lavage fluid (BALF) and serum for 6~7 animals at each time point (Table 1). This study was carried out in compliance with the Association for Assessment and Accreditation of Laboratory Animal Care.

Biochemistry in BAL fluid and serum. On 1, 7 and 15 days post-exposure, bronchoalveolar lavage fluid (BALF) was collected. The right lung was lavaged 3 times with 15 ml (22 ml/kg body weight) of 0.9% (w/v) saline to obtain the BALF from animals. The BALF samples were centrifuged (600 g, 10 min, 4°C) and their supernatants were analyzed with a FUJI DRI-CHEM FDC3500 (FUJIFILM, Japan) for activities of lactate dehydrogenase (LDH), γ -glutamyltransferase (GGT), and alkaline phosphatase (ALP). We also determined the total cell count in BALF with a Vi-CELL (Beckman Coulter, USA). Differential cell counts were performed on cytocentrifuged preparations and stained with Wright-Giemsa. The blood from abdominal vein was centrifuged (1600 g, 15 min, 4°C) and the resultant supernatants were stored at -80°C for further biochemical analyses. To be specific, we determined levels of lactate dehydrogenase (LDH), and blood urea nitrogen (BUN), total protein (TP) in serum using a FUJI DRI-CHEM FDC3500.

Histopathology. Necropsies were performed at 1, 7, and 15 days post-exposure. Rats were euthanized by isoflurane anesthesia. Blood was collected from abdominal vein. We obtained the lungs, livers, and nasal cavities from animals after necropsy and measured the organs weights. The lungs and nasal cavities were fixed in a 10% natural formalin solution for further histopathological diagnosis. Paraffin-embedded tissues were sectioned, stained with hematoxylin and eosin (H&E), and examined by light microscopy.

Statistical analysis. Each of the experimental values was compared to the corresponding control value for each time point using Student's *t*-test. Comparisons were considered statistically significant when $p < 0.05$.

RESULTS

Test material analysis. TiO_2 nanoparticles consisted of anatase as the major crystal phase from the XRD (X-ray diffractometry) pattern (Data not shown). Briefly, we obtained the volume ratio of the two crystal phases, 100 of anatase phase and 5.8 of rutile phase. Thus, it was noted that approximately 5.5% volume of the rutile phase existed in the nanoparticles. Furthermore, we calculated the mean crystallite size of TiO_2 nanoparticles using the full width at half maximum of peaks and the Scherrer formula. Anatase and rutile phases revealed mean crystallite sizes of 52.6 nm and 60.9 nm, respectively. In addition, TiO_2 nanoparticles

Table 1. Study design

Study day	1-10	11	12-16	17	18-24	25
Study phase	EP	R	R	R	R	R
Examinations and their time points		N (Day 1)		N (Day 7)		N (Day 15)

EP = Nose-only exposure for 6 hours a day; R = Recovery period; N = Necropsy, organ weight, histopathology, and BALF.

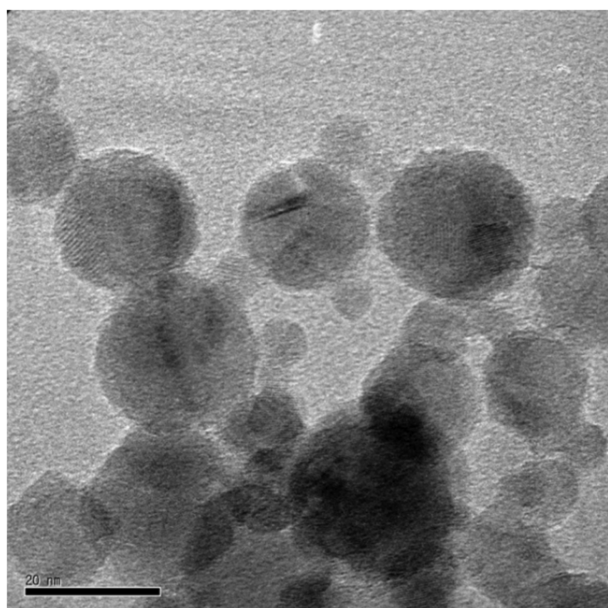


Fig. 1. TEM micrograph of TiO₂ nanoparticles obtained at the magnification of 200,000 ×. The morphological characteristics of TiO₂ nanoparticles are shown, which exhibit a wide range of size, with a few particles up to 100 nm. The particle shape was mostly spherical. Agglomerated TiO₂ nanoparticles were also found. TEM: Transmission electron microscopy.

seemed not to be charged, but instead neutral from fourier transform infrared spectroscopy (FT-IR) spectrum (Data not shown). Fig. 1 shows the morphological characteristics of TiO₂ nanoparticles, which exhibited a wide range of sizes with a few particles up to 100 nm. We also observed that the particles have mostly spherical shapes and the presence of some agglomerated nanoparticles.

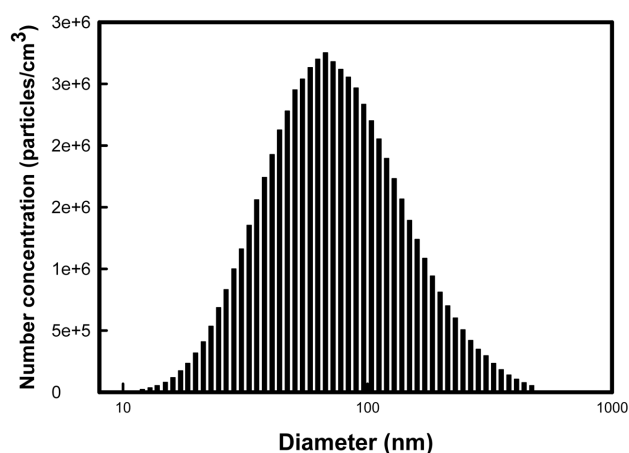


Fig. 2. The size distribution was monitored using the SMPS during inhalation exposure periods. It shows the representative distribution of the sizes of TiO₂ nanoparticles. SMPS: Scanning mobility particle sizer.

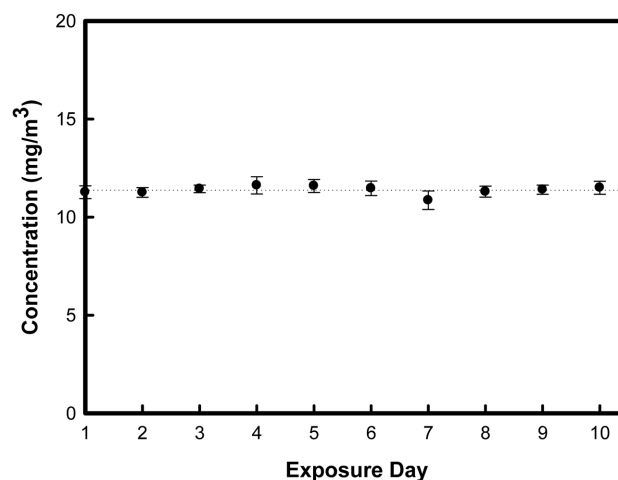


Fig. 3. In the nose-only inhalation chamber, mean mass concentration of TiO₂ nanoparticles were determined to be 11.39 ± 0.31 mg/m³. Error bar means standard deviation of each exposure day.

Particle concentration in the chamber. We also evaluated the size distribution of nanoparticles in the chamber using a SMPS during inhalation exposure periods. Fig. 2 shows the representative data from this analysis. By controlling the generation of the airflow and the dilution of the airflow of the nanoparticle generator, we could maintain the mean mass concentration of TiO₂ nanoparticles as 11.39 ± 0.31 mg/m³ (Fig. 3). Furthermore, we obtained the geometric mean diameter (GMD) and total number concentration during inhalation exposure periods. The mean GMD (nm) ± geometrical standard deviation (GSD) and total number concentration was determined to be 79.19 ± 4.41 nm and 1.8×10^6 particles/cm³, respectively (Data not shown).

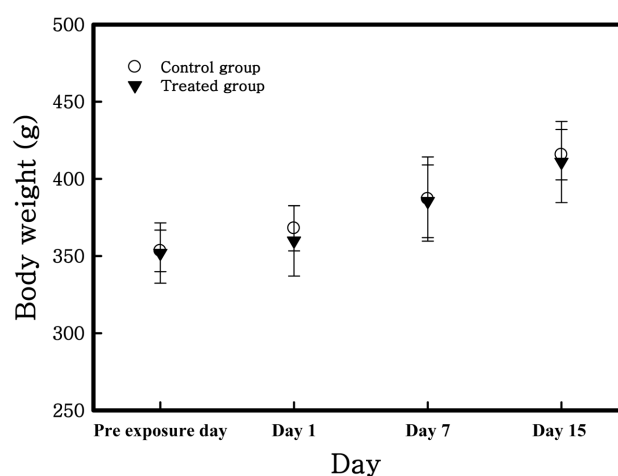


Fig. 4. Body weight change of rats exposed to TiO₂ nanoparticles. There were no significant differences between the control and treated group. The data are presented as the mean (g) ± SD.

Animal observations, body weights, and organ weights. There was no significant clinical sign induced by TiO₂ nanoparticles for the study durations. Body weight was measured prior to inhalation exposure and at 1, 7 and 15 days post-exposure. In all groups, body weights were increased with the passage of time (Fig. 4) but there were no statistically significant changes. Table 2 shows that calculated relative organ weights (i.e. lung, liver and spleen) to mean body weight of each group. Increased weight of the

spleen of all groups was caused by increasing their body weight. There were no significant changes of liver and lung weights.

BAL fluid cytology and biochemical parameters in BAL fluid and serum. Results of BAL fluid cytology show that the total cell number and macrophage value were highest at 1 day post-exposure (Table 3). In treated group, total cell number and macrophage value were higher than con-

Table 2. Absolute and relative organ weights

	Day 1 post-exposure		Day 7 post-exposure		Day 15 post-exposure	
	Control	Treated	Control	Treated	Control	Treated
Necropsy body weight	367.91 ± 14.61	359.87 ± 22.81	386.97 ± 27.29	385.48 ± 23.53	415.66 ± 16.32	410.95 ± 26.26
Lung						
Absolute	0.46 ± 0.05	0.47 ± 0.04	0.47 ± 0.07	0.47 ± 0.04	0.49 ± 0.05	0.49 ± 0.02
Relative	0.12 ± 0.01	0.13 ± 0.01	0.12 ± 0.01	0.12 ± 0.02	0.12 ± 0.01	0.12 ± 0.01
Liver						
Absolute	13.52 ± 1.60	13.11 ± 1.56	13.25 ± 2.79	14.73 ± 1.20	14.28 ± 0.89	14.59 ± 1.26
Relative	3.67 ± 0.43	3.64 ± 0.43	3.42 ± 0.72	3.82 ± 0.31	3.44 ± 0.21	3.55 ± 0.31
Spleen						
Absolute	0.79 ± 0.08	0.75 ± 0.11	0.85 ± 0.17	0.94 ± 0.16	1.03 ± 0.05	0.93 ± 0.10
Relative	0.22 ± 0.02	0.21 ± 0.03	0.22 ± 0.04	0.24 ± 0.04	0.25 ± 0.01	0.23 ± 0.02

Note: All values are presented as the mean (g) ± standard deviation for the indicated animal groups.

Table 3. BALF cytology of rats exposed to TiO₂ nanoparticles

Cell type	Day 1 post-exposure		Day 7 post-exposure		Day 15 post-exposure	
	Control	Treated	Control	Treated	Control	Treated
Total cell	5.246	5.361	4.166	4.230	4.650	4.780
Macrophage	5.230	5.356	4.153	4.221	4.640	4.716
Neutrophil	0.003	0.004	0.008	0.005	0.004	0.008
Lymphocyte	0.013	0.002	0.005	0.004	0.006	0.057

Note: Rats were treated with 0 (control) or 11.39 mg/m³ (Treatment) TiO₂ nanoparticles by inhalation for 2 weeks. Lung lavage was performed on 1, 7, and 15 days post-exposure.

Mean values {(Cell counts/ml/ BALF) × 10³} of the indicated animal groups are shown.

Table 4. Biochemical parameters in BALF and serum after exposure of TiO₂ nanoparticles

		Day 1 post-exposure		Day 7 post-exposure		Day 15 post-exposure	
		Control	Treated	Control	Treated	Control	Treated
BALF	LDH	1.33 ± 0.82	1.14 ± 0.38	2.00 ± 1.41	1.67 ± 1.63	1.75 ± 5.96	1.50 ± 2.07
	GGT	10.00 ± 2.58	8.86 ± 1.07	9.86 ± 2.41	9.00 ± 0.89	8.67 ± 1.03	8.00 ± 1.67
	ALP	17.57 ± 3.55	14.57 ± 3.60	16.71 ± 4.23	19.83 ± 3.25	19.67 ± 6.95	25.67 ± 6.62
Serum	LDH	820.86 ± 62.34	771.33 ± 154.30	703.57 ± 171.52	728.00 ± 181.43	641.50 ± 232.23	729.50 ± 87.55
	BUN	13.73 ± 0.69	15.29 ± 2.29	17.29 ± 6.10	14.22 ± 1.14	19.35 ± 4.39	20.48 ± 4.48
	TP	5.17 ± 0.19	5.41 ± 0.19	5.17 ± 0.18	5.13 ± 0.19	5.40 ± 0.18	5.52 ± 0.16

Note: All values are presented as the mean (U/L) ± standard deviation for the indicated animal groups.

BALF: Bronchoalveolar lavage fluid, LDH: Lactate dehydrogenase, ALP: Alkaline phosphatase, GGT: γ -glutamyltransferase, BUN: Blood urea nitrogen, TP: Total protein

control group of each time point. However there was no statistical significance between control and treated group. In addition, there were no differences in biochemical parameters of LDH, ALP, and GGT in BAL fluid and LDH, BUN, and TP in serum of all rats (Table 4).

Histopathological examination. Upon examination of the lung tissues of all treated rats, we observed numerous brown pigmented macrophages in alveoli until 15 days

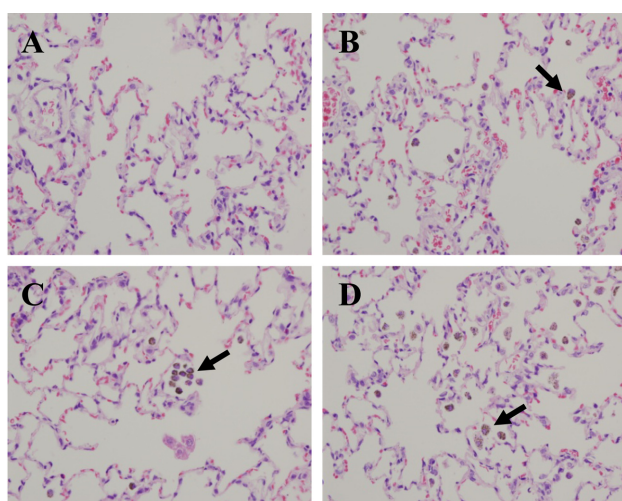


Fig. 5. Histopathological examination was performed in the lungs of rats exposed to TiO₂ nanoparticles for 2 weeks. (A) Lung of control rat. (B) Day 1 post-exposure. (C) Day 7 post-exposure. (D) Day 15 post-exposure. Arrows indicate pigmented macrophages in alveoli. Hematoxylin and eosin, 400× magnification.

post-exposure (Fig. 5). At 1 day post-exposure, we found olfactory epithelium degeneration/regeneration with inflammatory cell infiltration on the nasal septum and ethmoid turbinate of the treated rats. Besides, we observed basal cell proliferation on the ethmoid turbinate at 7 day post-exposure. However, these lesions were not observed at 15 days post-exposure (Fig. 6).

DISCUSSION

The aim of this study is to examine the influence of TiO₂ nanoparticles on rats that were exposed using a system for nose-only exposure. Rats in the treated group were exposed to a mass concentration of 11.39 mg/m³ for 2 weeks; control rats were exposed to clean air only. We did not observe changes in clinical signs, body weights and organ weight, cells of the BALF, biochemical parameters and cytokines on BALF and serum during the study. In general, total cell counts, LDH, TP levels and other enzyme activities represent parameters of cell injury in toxicity studies including nanoparticles (Driscoll *et al.*, 1991; Bermudez *et al.*, 2002; Bermudez *et al.*, 2004; van Ravenzwaay *et al.*, 2009; Ma-Hock *et al.*, 2009). In this study, we did not observe any significant differences between the control and treated groups in terms of these factors. Also, IL-6, an important immune modulation mediator, is generally known to function in acute inflammation. As cell activators, IL-4 and IL-10 are cytokines of the Th2-type. Specially, IL-10 is related to the fibrotic process and chronic inflammation (Park *et al.*, 2009). In this study, we did not observe significant differences in levels of IL-4, IL-6, or IL-10 between the control and treated groups on 1, 7, and 15 days post-

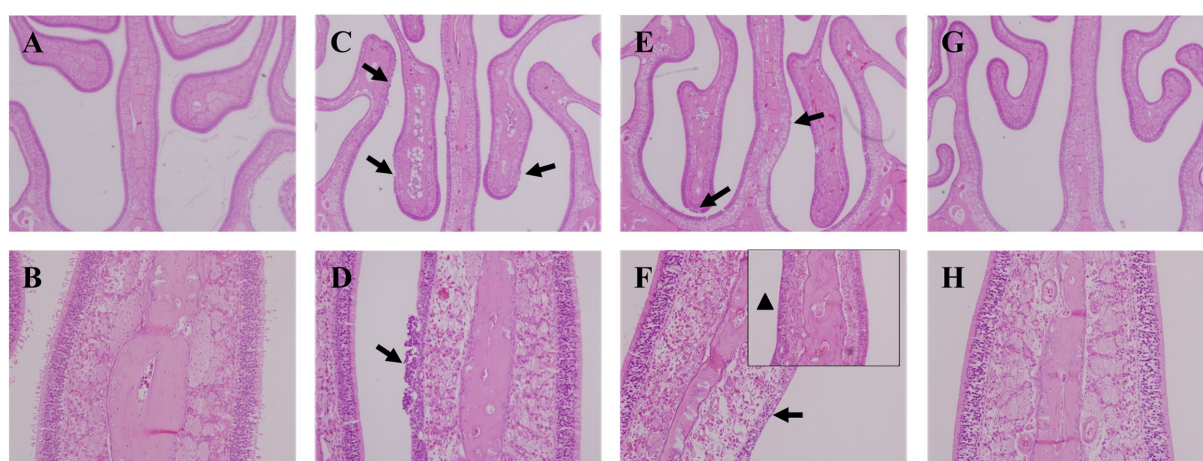


Fig. 6. Histopathological examination of the nasal cavities of rats exposed to TiO₂ nanoparticles for 2 weeks. (A, B) Nasal cavity of control rat. (C, D) Nasal cavity of rat sacrificed at day 1 post-exposure. Moderate olfactory degeneration/regeneration with inflammatory cell infiltration was observed on the nasal septum and ethmoid turbinate (arrows) (E, F) Nasal cavity of rat sacrificed at day 7 post-exposure. Besides, olfactory degeneration/regeneration was observed on the nasal septum and ethmoid turbinate (arrows). Also, basal cell proliferation was observed on the ethmoid turbinate (arrow head). (G, H) Nasal cavity of rat sacrificed at day 15 post-exposure. Lesions were not observed. Hematoxylin and eosin, A, C, E, G: 40× magnification; B, D, F, H: 200× magnification.

Table 5. The delivered amounts of TiO₂ nanoparticles to rats

Reference	Particle size (nm)	Aerosol concentration (mg/m ³)	Exposure time (min)	Delivered TiO ₂ amounts (mg/rat) ^{a)}	Degree of toxicity
Bermudez (2004)	21	0.52	23400	0.63	No histopathological lesions in lung, No changes in BALF cell parameter or lung burdens
Lan Ma-Hock (2009)	25.1	2.4	1800	1.08	No effect on the BALF parameters
Bermudez (2004)	21	2.1	23400	2.56	No histopathological lesions in lungs, No changes in BALF cell parameter or lung burdens
Lan Ma-Hock (2009)	25.1	12.1	1800	5.45	Increase in BALF cell counts, total protein levels, and enzyme activities
This study	79	11.39	3600	10.27	No effect on the BALF parameters and biochemistry in BALF and serum, Mild degeneration/regeneration of olfactory in nasal cavity, lung infiltration of macrophage
Bermudez (2002)	Pigment grade	9.6	23400	11.72	No response to inflammation
Bermudez (2004)	21	10.5	23400	12.82	Increased number of macrophages and neutrophils in BALF, Pulmonary particle overload, epithelial and fibroproliferative changes
Kevin E. Driscoll (1991)	Pigment grade	51.1	1800	13.59	No changes in BALF biochemistry, cellular parameter, or histopathological examination.
Lan Ma-Hock (2009)	25.1	50.0	1800	22.53	Increase in lung weight, BALF cell counts, total protein levels, and enzyme activities Histopathological lesions in the nasal epithelium
Ranvenzwaay (2009)	20~30	88.0	1800	39.66	Increase in lung weight, neutrophilic inflammation, and activation of macrophages in the lung
Bermudez (2002)	Pigment grade	47.7	23400	58.22	Increase in BALF cell number, LDH level in BALF
Bermudez (2002)	Pigment grade	239.1	23400	291.85	Increase in BALF cell number, LDH and TP levels in BALF, and epithelial and fibroproliferative changes

a) Actual delivered TiO₂ amounts (mg/kg) = (Aerosol concentration × RMV × Exposure time). RMV: respiratory minute volume (L/min) = 0.608 × BW(kg)^{0.852}.

Note: Delivered TiO₂ amounts were calculated according to the article by Alexander *et al.* (2008). Reference of the body weight was according to Bermudez *et al.*: www.Lapanimal.co.kr.

exposure (Data not shown). However, upon examination of stained BALF cell (1000 × magnification) with a microscope, we found phagocytosed macrophages of all the treated rats (Data not shown). This result suggests that the concentration of TiO₂ nanoparticles that we exposed to rat was not high enough to activate the immune cells. Instead, the concentration we used was sufficient to control macrophages in alveoli. Bermudez *et al.* (2002) also noted no signs of inflammation upon histopathological observation of 6-week-old female rats exposed to 10 mg/m³ TiO₂ concentration for 13 weeks (6 hr/day, 5 days/week). However, other studies indicated toxicological changes when nanoparticles were phagocytosed by macrophage. It is the case that exposure period is sufficiently long and particle concentration is high to cause inflammation.

The actual delivered amounts of TiO₂ nanoparticles that

are exposed to rats can be calculated by multiplying the aerosol concentration of TiO₂ nanoparticles by the amount of inhaled air by rats, which was previously reported by Alexander *et al.* (2008). Table 5 shows the estimation data that we calculated by this formula using the aerosol concentration of TiO₂ nanoparticles and the animals' mean body weights from the data of several inhalation studies. From this table, we concluded that the exposure amount used in this study is comparatively low (10.27 mg/rat) in comparison to other studies that indicated toxicity. In this method, we concluded an aspect of correspondence between the actual exposure levels and toxicity degree. When the rats inhaled higher amounts of nanoparticle, the toxic responses were more severe. In addition, we have to consider the size of nanoparticle. We measured that mean particle size of approximately 80 nm in actual exposure atmosphere during

study period. As we already know, the toxicity increases as the size of nanoparticles decreases (Sager *et al.*, 2008) due to the high reactivity between nanoparticles with large surface area and because materials of the body (Oberdörster *et al.*, 2005; Warheit *et al.*, 2004; Donaldson *et al.*, 2006; Warheit *et al.*, 2006). In the study carried out by Ma-Hock *et al.* (2009), these results represent more toxic than other studies because of their small size.

We could not observe any changes in biochemical parameters. However, we observed that macrophages infiltrated TiO₂ nanoparticles in alveoli of treated rats until 15 days post-exposure. These findings are in line with the results of a previous inhalation study by Bermudez *et al.* (2004), which showed degeneration and thickness of lung epithelial cells and particle-laden macrophages of the alveolar region. In our study, histopathological examination of nasal cavity of rats at 1 day post-exposure revealed that TiO₂ nanoparticles induced olfactory epithelium degeneration/regeneration which was recovered by 15 days post-exposure. Several studies have observed toxicity in the nasal cavity of animals after exposure to nanoparticles. For instance, Tin-Tin-Win-Shwe *et al.* (2006) observed deposited carbon black nanoparticles in the nasal cavities of BALB/c mice after intranasal instillation once a week for 4 weeks. It has been also reported that ultrafine silver nanoparticles were deposited on the posterior portion of nasal cavities of female Fischer rats after exposure (Takenaka *et al.*, 2001). Furthermore, the previous report of Korea National Toxicology Program, KNTP (2005) demonstrated that ICR mice subjected to nose-only exposure with amorphous silica for 4 weeks exhibited focal histopathological changes in their nasal cavities. In the report, biochemical changes (LDH, total protein, BUN, glucose, total bilirubin and etc.) were observed. In another study including head-nose exposure with nano-TiO₂ at 88 mg/m³, particles were observed in the olfactory epithelium of nasal cavities (van Ravenzwaay *et al.*, 2009). Additionally, there were studies that showed histopathological lesions in the nasal epithelium of rats after exposure to TiO₂ nanoparticles at concentration of 50 mg/m³ (Ma-Hock *et al.*, 2009) and increases in the incidence of pneumonia, trachitis and rhinitis with squamous metaplasia in the anterior nasal cavity of CD rats exposed TiO₂ for 2 years (Lee *et al.*, 1985).

Compared to delivered amount of TiO₂ nanoparticle to rats in the table, it is apparent that the table represents dose-response toxicological changes. In our study, where TiO₂ was exposed to ~11 mg/m³ for 2 weeks, we observed histopathological lesions of nasal cavity of treated rats. Among the studies showing toxicity of nasal cavity, it is related to the exposure concentration of inhaled nanoparticles whether the results represent biochemical changes or not.

Inhaled nanoparticles into the body contact with the nasal cavity first and this area is open to outer space. Deposited nanoparticles in the nasal cavity have potential toxicity;

they could be translocated to other organs, especially the brain. A previous study reported that TiO₂ nanoparticles translocated into the central nervous system and potentially caused lesions of the brain (Wang *et al.*, 2008). This study is in agreement with other previous studies that showed, following inhalation exposure, nanoparticles traveled via the nasal nerves to the brain (Kreuter *et al.*, 2002; Oberdörster *et al.*, 2004). Other studies have also indicated that the olfactory route may be an important transfer route for inhaled nanoparticles to the central nervous system (Oberdörster *et al.*, 2005; KNTP, 2005; Hunter and Udem, 1999; Utell *et al.*, 2002). Therefore, we need to consider the nasal cavity for accomplishment the study of inhalation toxicity.

We observed nasal and pulmonary toxicity which was reversible at the concentration approximately 11 mg/m³ of TiO₂ nanoparticles and without any other biochemical changes. This study can serve as an example of investigation of the influence of TiO₂ nanoparticles of rats upon nose-only exposure, and can be used to guide future studies designed to estimate nanotoxicity and examine other similar nanoparticles.

ACKNOWLEDGMENTS

This study was supported by the Ministry of Knowledge Economy for General Project grant of the establishment of the International Inhalation Toxicology Evaluation technology of Korea Institute of Toxicology.

REFERENCES

- Alexander, D.J., Collins, C.J., Coombs, D.W., Gilkison, I.S., Hardy, C.J., Healey, G., Karantabias, G., Johnson, N., Karlsson, A., Kilgour, J.D. and McDonald, P. (2008). Association of inhalation toxicologists (AIT) working party recommendation for standard delivered dose calculation and expression in non-clinical aerosol inhalation toxicology studies with pharmaceuticals. *Inhal. Toxicol.*, **20**, 1179-1189.
- Baan, R.A. (2007). Carcinogenic hazards from inhaled carbon black, titanium dioxide, and talc not containing asbestos or asbestiform fibers: Recent evaluations by an iarc monographs working group. *Inhal. Toxicol.*, **19 Suppl 1**, 213-228.
- Bermudez, E., Mangum, J.B., Asgharian, B., Wong, B.A., Reverdy, E.E., Janszen, D.B., Hext, P.M., Warheit, D.B. and Everitt, J.I. (2002). Long-term pulmonary responses of three laboratory rodent species to subchronic inhalation of pigmentary titanium dioxide particles. *Toxicol. Sci.*, **70**, 86-97.
- Bermudez, E., Mangum, J.B., Wong, B.A., Asgharian, B., Hext, P.M., Warheit, D.B. and Everitt, J.I. (2004). Pulmonary responses of mice, rats, and hamsters to subchronic inhalation of ultrafine titanium dioxide particles. *Toxicol. Sci.*, **77**, 347-357.
- Cho, M., Chung, H., Choi, W. and Yoon, J. (2004). Linear correlation between inactivation of *E. coli* and OH radical concentration in TiO₂ photocatalytic disinfection. *Water Res.*, **38**, 1069-1077.

- Donaldson, K., Aitken, R., Tran, L., Stone, V., Duffin, R., Forrester, G. and Alexander, A. (2006). Carbon nanotubes: A review of their properties in relation to pulmonary toxicology and workplace safety. *Toxicol. Sci.*, **92**, 5-22.
- Driscoll, K.E., Lindenschmidt, R.C., Maurer, J.K., Perkins, L., Perkins, M. and Higgins, J. (1991). Pulmonary response to inhaled silica or titanium dioxide. *Toxicol. Appl. Pharmacol.*, **111**, 201-210.
- Gurr, J.R., Wang, A.S., Chen, C.H. and Jan, K.Y. (2005). Ultrafine titanium dioxide particles in the absence of photoactivation can induce oxidative damage to human bronchial epithelial cells. *Toxicology*, **213**, 66-73.
- Höhr, D., Steinfartz, Y., Schinsm, R.P., Knaapen, A.M., Martra, G., Fubini, B. and Borm, P.J. (2002). The surface area rather than the surface coating determines the acute inflammatory response after instillation of fine and ultrafine TiO₂ in the rat. *Int. J. Hyg. Environ. Health*, **205**, 239-244.
- Hunter, D.D. and Udem, B.J. (1999). Identification and substance P content of vagal afferent neurons innervating the epithelium of the guinea pig trachea. *Am. J. Respir. Crit. Care Med.*, **159**, 1943-1948.
- Kreuter, J., Shamenkov, D., Petrov, V., Ränge, P., Cychutek, K., Koch-Brandt, C. and Alyautdin, R. (2002). Apolipoprotein-mediated transport of nanoparticle-bound drugs across the blood-brain barrier. *J. Drug Target.*, **10**, 317-325.
- Kwon, J.T., Kim, H., Hwang, S.T., Yun, H.J., Kim, D.S., Choi, M.S., Han, D.Y., Kang, Y.W., Yun, T.J., Lee, J.K. and Cho, M.H. (2005). Inhalation Toxicology of nanoparticle. The Annual Report of KNTP, pp. 487-507.
- Lee, K.P., Trochinowicz, H.J. and Reinhardt, C.F. (1985). Pulmonary response of rats exposed to titanium dioxide (TiO₂) by inhalation for two years. *Toxicol. Appl. Pharmacol.*, **79**, 179-192.
- Lomer, M.C., Thompson, R.P. and Powell, J.J. (2002). Fine and ultrafine particles of the diet: influence on the mucosal immune response and association with Crohn's disease. *Proc. Nutr. Soc.*, **61**, 123-130.
- Ma-Hock, L., Burkhardt, S., Strauss, V., Gamer, A.O., Wiench, K., van Ravenzwaay, B. and Landsiedel, R. (2009). Development of a short-term inhalation test in the rat using nano-titanium dioxide as a model substance. *Inhal. Toxicol.*, **21**, 102-118.
- Nemmar, A., Melghit, K. and Ali, B.H. (2008). The acute proinflammatory and prothrombotic effects of pulmonary exposure to rutile TiO₂ nanorods in rats. *Exp. Biol. Med. (Maywood)*, **233**, 610-619.
- Nordman, H. and Berlin, M. (1986). Titanium: in Handbook on the Toxicology of Metals, vol. II. (Friberg, L., Nordberg, G.F., Vouk, V.B. Ed.). Elsevier, Amsterdam, pp. 595-609.
- Oberdörster, G., Oberdörster, E. and Oberdörster, J. (2005). Nanotoxicology: An emerging discipline evolving from studies of ultrafine particles. *Environ. Health Perspect.*, **113**, 823-839.
- Oberdörster, G., Sharp, Z., Atudorei, V., Elder, A., Gelein, R., Kreyling, W. and Cox, C. (2004). Translocation of inhaled ultrafine particles to the brain. *Inhal. Toxicol.*, **16**, 437-445.
- Park, E.J., Yoon, J., Choi, K., Yi, J. and Park, K. (2009). Induction of chronic inflammation in mice treated with titanium dioxide nanoparticles by intratracheal instillation. *Toxicology*, **260**, 37-46.
- Sadrieh, N., Wokovich, A.M., Gopee, N.V., Zheng, J., Haines, D., Parmiter, D., Siitonen, P.H., Cozart, C.R., Patri, A.K., McNeil, S.E., Howard, P.C., Doub, W.H. and Buhse, L.F. (2010). Lack of significant dermal penetration of titanium dioxide from sunscreen formulations containing nano- and submicron-size TiO₂ particles. *Toxicol. Sci.*, **115**, 156-166.
- Sager, T.M., Kommineni, C. and Castranova, V. (2008). Pulmonary response to intratracheal instillation of ultrafine versus fine titanium dioxide: role of particle surface area. *Part. Fibre Toxicol.*, **5**, 17.
- Takenaka, S., Karg, E., Roth, C., Schulz, H., Ziesenis, A., Heinzmann, U., Schramel, P. and Heyder, J. (2001). Pulmonary and systemic distribution of inhaled ultrafine silver particles in rats. *Environ. Health Perspect.*, **109 Suppl 4**, 547-551.
- Tin-Tin-Win-Shwe, Yamamoto, S., Ahmed, S., Kakeyama, M., Kobayashi, T. and Fujimaki, H. (2006). Brain cytokine and chemokine mRNA expression in mice induced by intranasal instillation with ultrafine carbon black. *Toxicol. Lett.*, **163**, 153-160.
- Utell, M.J., Frampton, M.W., Zareba, W., Devlin, R.B. and Cascio, W.E. (2002). Cardiovascular effects associated with air pollution: potential mechanisms and methods of testing. *Inhal. Toxicol.*, **14**, 1231-1247.
- van Ravenzwaay, B., Landsiedel, R., Fabian, E., Burkhardt, S., Strauss, V. and Ma-Hock, L. (2009). Comparing fate and effects of three particles of different surface properties: Nano-TiO₂, pigmentary TiO₂ and quartz. *Toxicol. Lett.*, **186**, 152-159.
- Wang, J., Chen, C., Liu, Y., Jiao, F., Li, W., Lao, F., Li, Y., Li, B., Ge, C., Zhou, G., Gao, Y., Zhao, Y. and Chai, Z. (2008). Potential neurological lesion after nasal instillation of TiO₂ nanoparticles in the anatase and rutile crystal phases. *Toxicol. Lett.*, **183**, 72-80.
- Warheit, D.B., Laurence, B.R., Reed, K.L., Roach, D.H., Reynolds, G.A. and Webb, T.R. (2004). Comparative pulmonary toxicity assessment of single-wall carbon nanotubes in rats. *Toxicol. Sci.*, **77**, 117-125.
- Warheit, D.B., Webb, T.R., Sayes, C.M., Colvin, V.L. and Reed, K.L. (2006). Pulmonary instillation studies with nanoscale TiO₂ rods and dots in rats: Toxicity is not dependent upon particle size and surface area. *Toxicol. Sci.*, **91**, 227-236.