

Vertebral artery injuries in cervical spine surgery

Gregory D. Schroeder, Wellington K. Hsu

Department of Orthopaedic Surgery, Northwestern University, 676 N. Saint Clair, Suite 1350, Chicago, IL, 60611, USA

E-mail: *Gregory D. Schroeder - g-schroeder@md.northwestern.edu; Wellington K. Hsu - whsu@nmff.org

*Corresponding author

Received: 29 June 13 Accepted: 05 August 13 Published: 29 October 13

This article may be cited as:

Schroeder GD, Hsu WK. Vertebral artery injuries in cervical spine surgery. *Surg Neurol Int* 2013;4:S362-7.

Available FREE in open access from: <http://www.surgicalneurologyint.com/text.asp?2013/4/6/362/120777>

Copyright: © 2013 Schroeder GD. This is an open-access article distributed under the terms of the Creative Commons Attribution License, which permits unrestricted use, distribution, and reproduction in any medium, provided the original author and source are credited.

Abstract

Background: Vertebral artery injuries during cervical spine surgery are rare, but potentially fatal. When performing cervical spine surgery, it is imperative that the surgeon has a systematic approach for avoiding, and if necessary, dealing with a vertebral artery injury.

Methods: This is a review paper.

Results: Upper posterior cervical spine surgeries put the vertebral artery at the highest risk, as opposed to anterior subaxial cervical spine procedures, which put the artery at the least risk. A thorough understanding of the complex anatomy of the vertebral artery is mandatory prior to performing cervical spine surgery, and since the vertebral artery can have a variable course, especially in the upper cervical spine, the surgeon must minimize the possibility of an arterial injury by preoperatively assessing the artery with a computed tomography (CT) scan or magnetic resonance imaging (MRI). Intraoperatively, the surgeon must be aware of when the vertebral artery is most at risk, and take precautions to avoid an injury. In the event of an arterial injury, the surgeon must have a plan of action to (1) Achieve control of the hemorrhage. (2) Prevent acute central nervous system ischemia. (3) Prevent postoperative complications such as embolism and pseudoaneurysm

Conclusion: Prior to performing cervical spine surgery, one must understand the four A's of vertebral artery injuries: Anatomy, Assessment, Avoidance, and Action.

Key Words: Cervical spine surgery, planning, treatment, vertebral artery injury

Access this article online

Website:

www.surgicalneurologyint.com

DOI:

10.4103/2152-7806.120777

Quick Response Code:



INTRODUCTION

Injury to the vertebral artery is a potentially devastating complication of cervical spine surgery. While the overall incidence rate in the cervical spine is 1.4%,^[22] patients are at the greatest risk when undergoing posterior instrumented upper cervical spine surgery (4-8% incidence).^[17,29] In contrast, the risk of injury is only 0.3-0.5% for anterior subaxial cervical spine procedures.^[2,24] The clinical sequelae of an iatrogenic vertebral artery injury can vary widely depending on anatomic variations, circulation dominance,

and the presence of collateral blood flow. Patients can have minimal, but noticeable, sequelae, and serious complications such as lateral medullary (Wallenberg) syndrome, quadraparesis, and even mortality have been reported.^[2,22,24,29] Understanding the key principles of vertebral artery circulation will help management of this complication.

ANATOMY

The vertebral artery originates off the subclavian artery and travels through the foramen transversarium in the

subaxial cervical spine prior to anastomosing with the contralateral vertebral artery in the foramen magnum to form the basilar artery. It then delivers blood flow to the posterior portions of the brain. Importantly, the basilar artery forms the posterior contribution to the Circle of Willis, and the redundancy in circulation may be protective during a segmental injury or blockage. However, this redundancy is often limited by atherosclerosis or other vascular abnormalities.^[7] The vertebral artery can be divided into four distinct segments depending on surrounding anatomy.^[7]

The first or prevertebral segment of the vertebral artery starts at the subclavian artery and ends at the transverse foramen [Figure 1].^[7] The vertebral artery most frequently enters the foramen at C6 (87-89%), however, there can be variations: 3.5-5.4% enter the C7 foramen, 6% enter at C5, and less than 1.4% enter above the C5 foramen.^[11] Most commonly, at C7, the vertebral artery is anterior to the foramen and is located 1.7 cm anterior to the posterior cortex of the vertebral body and 1.8 cm lateral from the midline of the vertebral body.^[30]

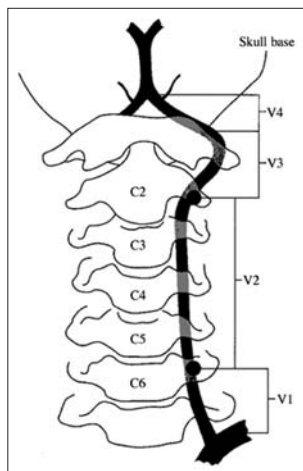


Figure 1: Four segments of the vertebral artery^[4]

The second segment is defined as the vertebral artery within transverse foramen (most commonly between C3 and C6).^[7] As the vertebral artery ascends cephalad, the transverse foramen moves from a more anterior and lateral position to a more posterior and medial position. The interforaminal distances decreases from an average of 29 mm at C6 to 26 mm at C3, and the distance between the posterior wall of the foramen to the posterior wall of the vertebral body decreases from 3.5 mm at C6 to 2.2 mm at C3 [Figure 2].^[28] Running medially to the vertebral artery in the transverse foramen is a venous and nervous plexus consisting of one to three veins and sympathetic nerves,^[7,11] and fibrous tissue connects these structures to the uncinat process.^[8] Up to 7% of the time there may be a duplicate foramen, and in this case, the artery runs in the more medial foramen [Figure 3].^[25] The left foramen is often slightly larger, as the left vertebral artery is more commonly the dominant vessel.^[11,24,25] While the transverse foramen is most often located lateral to the uncovertebral joint, there is a 2.7% risk of a tortuous or anomalous vertebral artery. In these cases, the foramen is located on average 0.14 mm medial to the uncovertebral joint.^[6]

The third segment of the vertebral artery starts caudally at the transverse foramen of C3 and ends at the atlanto-occipital membrane.^[7] The vertebral artery exits the C3 foramen, takes a sharp turn at the superior articular facet of C2, and exits the C2 foramen around a 45-degree angle. There, it enters the C1 transverse foramen and travels horizontally in the groove of the superior arch of C1. The artery then crosses the atlanto-occipital membrane to enter the cranial cavity approximately 15 mm lateral to the midline at C1.^[7] The fourth segment of the vertebral artery is intracranial.

Although most vertebral arteries travel through this path, substantial bony and arterial variation can exist in the upper cervical spine.^[12,26,31] Hong *et al.* used computed tomography (CT) angiograms of over 1000 patients to

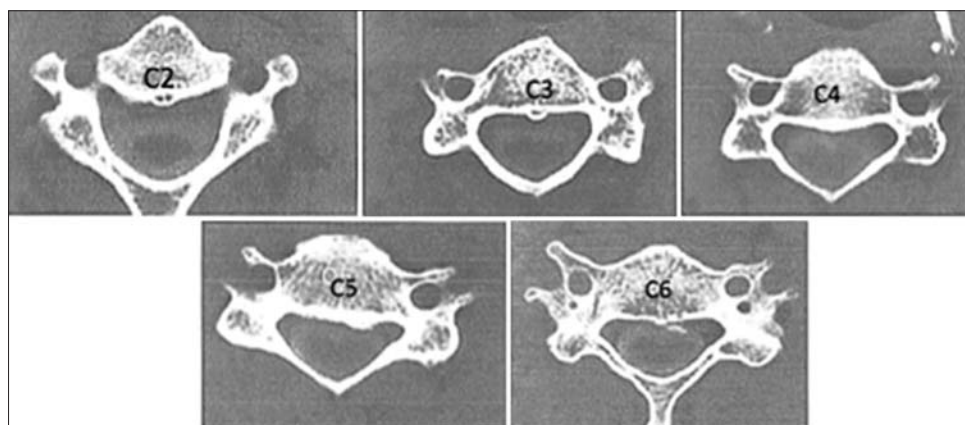


Figure 2: As the vertebral artery ascends cephalad, the transverse foramen moves from a more anterior and lateral position to a more posterior and medial position^[28]

demonstrate that 5.4% of patients have an anomalous course of the vertebral artery in V3, with the most common variation being one that travels below the C1 arch after exiting the C2 transverse foramen [Figure 4]. It then enters the spinal canal without entering the C1 transverse foramen.^[12]

ASSESSMENT

Prior to cervical spine surgery, a thorough assessment of the vertebral artery with either a CT or magnetic resonance imaging (MRI) study is vital. Heary *et al.* demonstrated that the interforaminal distance is consistently slightly less when measured on CT than on a cadaver.^[11] This allows for surgeons to reliably preoperatively template the safe width of the decompression on CT scan.

Curylo *et al.* demonstrated a 2.7% incidence of abnormal vertebral artery location on 222 cadavers. In the abnormal specimens, the vertebral artery was located 0.14 mm medial to the uncovertebral joint on average.^[6] Advanced cervical spondylotic changes increase the risk of a tortuous vertebral artery,^[20] and this finding has led some authors to postulate that patients with diseases such as rheumatoid arthritis are at an increased risk

for medialization of the vertebral artery in the subaxial cervical spine.^[27] Medialization of the vertebral artery can occur near the mid vertebral body level, which increases the risk of injury in corpectomies than in discectomies [Figure 5].^[6]

Critical evaluation of the vertebral artery anatomy is essential when performing posterior surgery on the upper cervical spine (occiput to C3). In 23% of patients, the C2 isthmus is too small to accommodate a unilateral 3.5 mm transarticular screw, and in 6% of patients it cannot accommodate a screw on both sides.^[14,17,19] Placement of a transarticular screw in these patients would put the vertebral artery at an increased risk of injury.^[14,17,19] Furthermore, because there is a 5.4% rate of variation in the third segment of the vertebral artery, C1 lateral mass screws can put the vessel at unnecessary risk in these patients.^[7,12]

While the vertebral artery should always be assessed preoperatively, with advanced imaging, the evaluation of other cervical arterial systems can also potentially avoid catastrophic injury. For example, in a study of 1000 patients, Koreckij *et al.* recently demonstrated that 12.6% of patients have a medially aberrant carotid artery, and 2.6% have a retropharyngeal carotid vessel where the artery is found anterior to the midline of the vertebral body. Patients with such an abnormality may require an alternate approach, such as one from the opposite anterior side or a posterior approach.^[16]

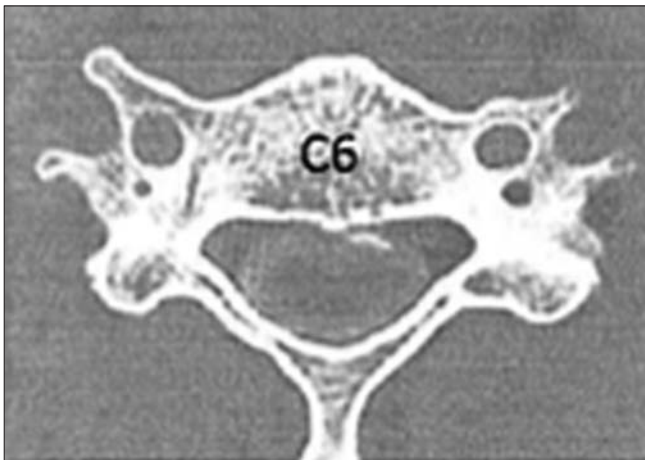


Figure 3: C6 vertebrae with a duplicate transverse foramen^[28]

AVOIDANCE

Anterior cervical surgery

Vertebral artery injuries in anterior subaxial cervical spine surgery are rare,^[2,24] and most occur during the decompression. An important mode of prevention involves evaluation of a tortuous vertebral artery on preoperative advanced imaging. Assessment of spinal canal width can also aid in the avoidance of the vertebral artery. Although the average width of the spinal cord is relatively constant in the subaxial spine and ranges

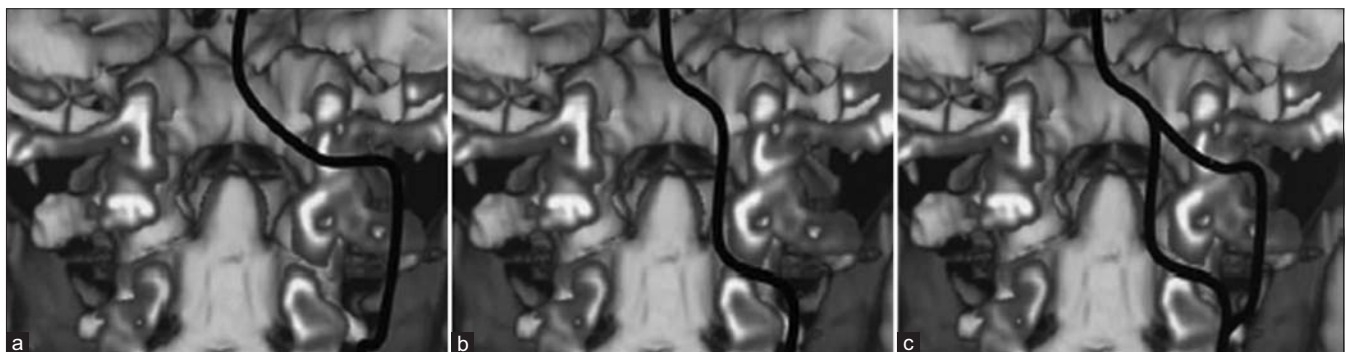


Figure 4: Aberrant path of V3.^[26] (a) Depiction of the most common course. (b) Depiction of an intersegmental artery. (c) Depiction of a fenestrated vertebral artery

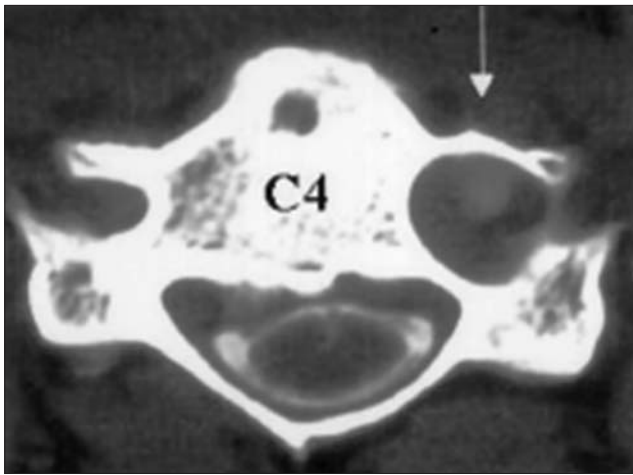


Figure 5: Aberrant subaxial vertebral artery^[6]

between 13 and 14.5 mm,^[24] the average interforaminal distance increases from C3 to C6; therefore a wider decompression is safer at the more caudal levels.^[28] Thus, properly performed multilevel corpectomies usually result in a trapezoidal-shaped decompression.^[7] Since the vertebral artery is located between 0.8 and 1.6 mm from the lateral tip of the uncinete process^[21] and decompression to the upward curve of the uncovertebral joint is often sufficient for symptom relief,^[7] avoiding an aggressive removal of the uncinete joint is prudent when pathology is appropriate. Finally, one potential pitfall from the use of an operating microscope is the potential for an asymmetric decompression. An oblique or asymmetrical decompression during a corpectomy may put the vertebral artery at risk, especially if a tortuous path is missed.^[2] The keys to preventing this complication include symmetric and stable patient placement on a head holder and positioning of the microscope perpendicular to and over the center of the wound.

Posterior cervical spine

Instrumented posterior surgery of the upper cervical spine places the vertebral artery at the highest risk for injury.^[17,29] Avoidance measures start with preoperative evaluation of the vessel course on advanced imaging, preferably a CT scan. In 18-23% of patients, at least one side will not accommodate a transarticular (Magerl) screw, and in up to 6%, a transarticular screw cannot be placed in either side.^[14,17,19] Finally, an intersegmental or fenestrated (4.6% and 0.5%, respectively) vertebral artery, as well as an abnormal posterior inferior cerebellar artery (0.2%), can cross the starting point for a C1 lateral mass screw, substantially increasing the likelihood of injury if unrecognized.^[12,26] Vertebral artery injuries during posterior exposure can also be avoided. When exposing the posterior ring of the atlas, lateral dissection should be limited to a point 15 mm lateral to the midline. Furthermore, since the vertebral artery typically runs along the superior aspect of C1 posterior ring, dissection

along the inferior aspect is safest. No dissection should occur on the superior edge of C1 more than 8 mm lateral to the midline. To allow adequate visualization of the surgical field, care must be taken to maintain meticulous hemostasis. There is often significant bleeding from the epidural plexus surrounding the C2 nerve root, and this is best controlled with thrombin soaked gel foam, avatine powder, and a cottonoid.^[23]

Because instrumentation puts the vertebral artery at greatest risk, care must be given to mitigating measures. For example, Madawi *et al.* reported on 61 patients who underwent transarticular screw placement for traumatic or atraumatic atlanto-axial instability. In his study, all patients who sustained a vertebral artery injury after the placement of transarticular screws had a poorly reduced C1/C2 joint when screw placement occurred.^[17] The authors argued that with an anatomically aligned C1/C2 joint and use of biplanar fluoroscopy, the safety of placement of a transarticular screw increases significantly.^[17] During placement of a C1 lateral mass screw, avoidance of a vertebral artery injury hinges upon use of an appropriate starting point, which is the junction of lateral mass and inferior aspect of posterior arch [Figure 6]. To facilitate exposure, the overhang of the C1 arch must be removed at times to ensure a proper starting point. The screw is then angled 10-15 degrees medially to avoid the vertebral artery, which courses laterally. The screw is then inserted short of the anterior arch to avoid the typical path of the internal carotid artery.^[13] Similarly, a properly placed C2 pedicle screw has minimal risk to the vertebral artery. The C2 pedicle screw is placed utilizing a starting point slightly superior and medial to the center of the lateral mass and aimed 10 degrees medially and 15 degrees cephalad [Figure 6]. To ensure this screw is placed safely, a combination of lateral fluoroscopy as well as a small laminotomy (allowing for direct palpation of the pedicle) can be beneficial.^[13] Placing subaxial cervical spine lateral mass screws can also put the vertebral artery at risk. Techniques such as the Magerl, Roy-Camille, and Anderson all describe a laterally directed screw (10-25 degrees) from the midpoint of the lateral mass to avoid the vertebral artery in the foramen transversarium [Figure 7].^[13]

ACTION

Once a vertebral artery injury has occurred, the surgeon must always keep the treatment goals in mind in the appropriate order: (1) Achieve control of the hemorrhage. (2) Prevent acute central nervous system ischemia. (3) Prevent postoperative complications such as embolism and pseudoaneurysm. Control of vertebral artery bleeding can be achieved in three different ways: Primary repair, bypass surgery, or sacrifice. Primary repair, when available, remains the best option. After vascular

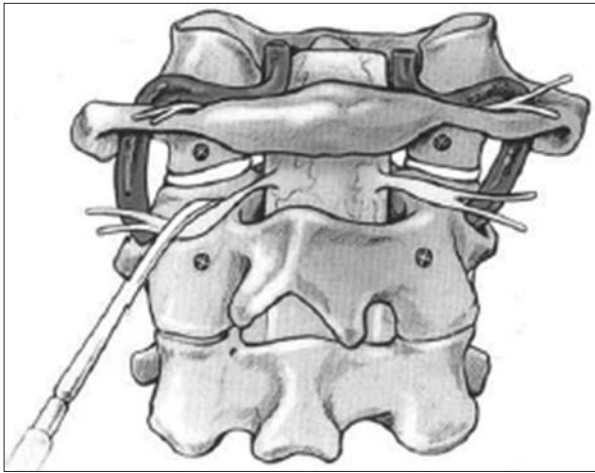


Figure 6: Starting point for C1 lateral mass and C2 pedicle screw^[13]

surgery consultation is obtained and aggressive intravenous access for fluid resuscitation has been communicated to the anesthesia team, the first step should be to ensure that the head is in a neutral position, as cervical extension and axial rotation can lead to occlusion of the contralateral vertebral artery.^[18] Digital pressure can often be used to obtain hemostasis, followed by large pieces of hemostatic agents such as thrombin soaked gel foam and cottonoids. It is important to use only large items that cannot accidentally embolize.^[10] Since the artery must be well-visualized to allow for proximal and distal control, it is often necessary to expose the artery through the foramen transversarium one level above and below the injury.^[7,10] After proper exposure, a temporary aneurysm clip or vessel loop is placed proximal and distal to the injury site. The injury can then be directly repaired with 7-0 or 8-0 Prolene (Ethicon Sumerville, NJ).^[7,10] Prior to completion of the repair, the temporary clips should be removed to prevent air embolism or the propagation of other emboli.^[10] If direct repair is not possible, the remaining options are to bypass the injury site or vessel sacrifice. Ligation of the vessel should only occur if there is good retrograde flow, as this may be a sign of considerable contralateral/collateral flow.^[7] To evaluate this, place an aneurysm clip proximal to the injury on the vertebral artery and look for significant back flow from the cephalad end.^[7] The use of endovascular coiling has also been shown to be effective in stopping hemorrhage from a pseudoaneurysm after a vertebral artery injury, but there is no literature on its use intraoperatively immediately after the injury.^[3,9] The decision to sacrifice the vessel should be a last resort, as the severe neurologic complication rate can be as high as 43%.^[24] If the vessel cannot be repaired, and there is poor retrograde flow, bypass is indicated. There is very little literature about the use of stenting iatrogenic vertebral artery injuries, however, case reports have demonstrated it as a possible option.^[9,15] Alternatively, the vascular surgeon may choose to perform traditional bypass surgery. Tamponade alone is not effective in achieving

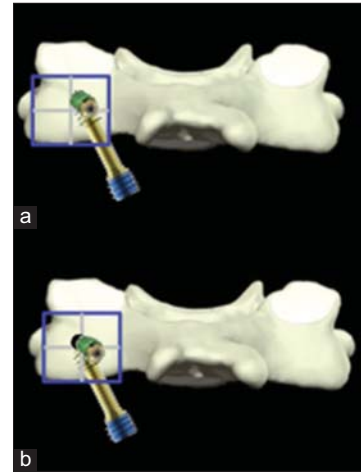


Figure 7: Starting points for the (a) Magerl and (b) Roy-Camille lateral mass screw

hemostasis, as multiple reports exist of complications after use of this method.^[3,5,9,15] Postoperatively the patient should be started on an antiplatelet medication after 6 hours and should be evaluated with conventional angiography, as often times there may be significant artifact with an MR angiogram.

CONCLUSION

Vertebral artery injuries are a rare but serious complication of cervical spine surgery. Prevention hinges on the surgeon having a complete understanding of the complex anatomy of the vertebral artery. Because of the high rate of vertebral artery anomalies, scrutiny of the anatomy on advanced imaging is mandatory. Assessment of these anomalies, as it pertains to the normal path, can help surgeons employ avoidance measures during surgery. If a vertebral artery injury occurs and an action plan is in place, then catastrophic complications can be minimized.

REFERENCES

1. Argenson GF, Sylla S, Dintimille H, Pasion S, DiMarino V. The vertebral arteries (segments V1 and V2). *Anat Clin* 1980;2:29-41.
2. Burke JP, Gerszten PC, Welch WC. Iatrogenic vertebral artery injury during anterior cervical spine surgery. *Spine J* 2005;5:508-14.
3. Choi JW, Lee JK, Moon KS, Kim YS, Kwak HJ, Joo SP, et al. Endovascular embolization of iatrogenic vertebral artery injury during anterior cervical spine surgery: Report of two cases and review of the literature. *Spine (Phila Pa 1976)* 2006;31:E891-4.
4. Cloud GC, Markus HS. Diagnosis and management of vertebral artery stenosis. *QJM* 2003;96:27-54.
5. Cosgrove GR, Theron J. Vertebral arteriovenous fistula following anterior cervical spine surgery. Report of two cases. *J Neurosurg* 1987;66:297-9.
6. Curylo LJ, Mason HC, Bohlman HH, Yoo JU. Tortuous course of the vertebral artery and anterior cervical decompression: A cadaveric and clinical case study. *Spine (Phila Pa 1976)* 2000;25:2860-4.
7. Devin CJ, Kang JD. Vertebral artery injury in cervical spine surgery. *Instr Course Lect* 2009;58:717-28.
8. Ebraheim NA, Lu J, Haman SP, Yeasting RA. Anatomic basis of the anterior surgery on the cervical spine: Relationships between uncus-artery-root complex and vertebral artery injury. *Surg Radiol Anat* 1998;20:389-92.

9. Garcia Alzamora M, Rosahl SK, Lehmborg J, Klisch J. Life-threatening bleeding from a vertebral artery pseudoaneurysm after anterior cervical spine approach: Endovascular repair by a triple stent-in-stent method. Case report. *Neuroradiology* 2005;47:282-6.
10. Golfinos JG, Dickman CA, Zabramski JM, Sonntag VK, Spetzler RF. Repair of vertebral artery injury during anterior cervical decompression. *Spine (Phila Pa 1976)* 1994;19:2552-6.
11. Heary RF, Albert TJ, Ludwig SC, Vaccaro AR, Wolansky LJ, Leddy TP, et al. Surgical anatomy of the vertebral arteries. *Spine (Phila Pa 1976)* 1996;21:2074-80.
12. Hong JT, Lee SW, Son BC, Sung JH, Yang SH, Kim IS, et al. Analysis of anatomical variations of bone and vascular structures around the posterior atlantal arch using three-dimensional computed tomography angiography. *J Neurosurg Spine* 2008;8:230-6.
13. Hsu WK. Advanced techniques in cervical spine surgery. *J Bone Joint Surg Am* 2011;93:780-8.
14. Igarashi T, Kikuchi S, Sato K, Kayama S, Otani K. Anatomic study of the axis for surgical planning of transarticular screw fixation. *Clin Orthop Relat Res* 2003;408:162-6.
15. Katsaridis V, Papagiannaki C, Violaris C. Treatment of an iatrogenic vertebral artery laceration with the Symbiot self expandable covered stent. *Clin Neurol Neurosurg* 2007;109:512-5.
16. Koreckij J, Alvi H, Gibly R, Pang E, Hsu WK. Incidence and risk factors of the retropharyngeal carotid artery on cervical magnetic resonance imaging. *Spine (Phila Pa 1976)* 2013;38:E109-12.
17. Madawi AA, Casey AT, Solanki GA, Tuite G, Veres R, Crockard HA. Radiological and anatomical evaluation of the atlantoaxial transarticular screw fixation technique. *J Neurosurg* 1997;86:961-8.
18. Mitchell JA. Changes in vertebral artery blood flow following normal rotation of the cervical spine. *J Manipulative Physiol Ther* 2003;26:347-51.
19. Nogueira-Barbosa MH, Defino HL. Multiplanar reconstructions of helical computed tomography in planning of atlanto-axial transarticular fixation. *Eur Spine J* 2005;14:493-500.
20. Oga M, Yuge I, Terada K, Shimizu A, Sugioka Y. Tortuosity of the vertebral artery in patients with cervical spondylotic myelopathy. Risk factor for the vertebral artery injury during anterior cervical decompression. *Spine (Phila Pa 1976)* 1996;21:1085-9.
21. Pait TG, Killefer JA, Arnautovic KI. Surgical anatomy of the anterior cervical spine: The disc space, vertebral artery, and associated bony structures. *Neurosurgery* 1996;39:769-76.
22. Rampersaud YR, Moro ER, Neary MA, White K, Lewis SJ, Massicotte EM, et al. Intraoperative adverse events and related postoperative complications in spine surgery: Implications for enhancing patient safety founded on evidence-based protocols. *Spine (Phila Pa 1976)* 2006;31:1503-10.
23. Sasso RC. C1 lateral screws and C2 pedicle/pars screws. *Instr Course Lect* 2007;56:311-7.
24. Smith MD, Emery SE, Dudley A, Murray KJ, Leventhal M. Vertebral artery injury during anterior decompression of the cervical spine. A retrospective review of ten patients. *J Bone Joint Surg Br* 1993;75:410-5.
25. Taitz C, Nathan H, Arensburg B. Anatomical observations of the foramina transversaria. *J Neurol Neurosurg Psychiatry* 1978;41:170-6.
26. Takahashi T, Tominaga T, Hassan T, Yoshimoto T. Cervical cord compression with myelopathy caused by bilateral persistence of the first intersegmental arteries: Case report. *Neurosurgery* 2003;53:234-7.
27. Tumialan LM, Wippold FJ 2nd, Morgan RA. Tortuous vertebral artery injury complicating anterior cervical spinal fusion in a symptomatic rheumatoid cervical spine. *Spine (Phila Pa 1976)* 2004;29:E343-8.
28. Vaccaro AR, Ring D, Scuderi G, Garfin SR. Vertebral artery location in relation to the vertebral body as determined by two-dimensional computed tomography evaluation. *Spine (Phila Pa 1976)* 1994;19:2637-41.
29. Wright NM, Laurysen C. Vertebral artery injury in C1-2 transarticular screw fixation: Results of a survey of the AANS/CNS section on disorders of the spine and peripheral nerves. American Association of Neurological Surgeons/ Congress of Neurological Surgeons. *J Neurosurg* 1998;88:634-40.
30. Xu R, Ebraheim NA, Tang G, Stanesco S. Location of the vertebral artery in the cervicothoracic junction. *Am J Orthop (Belle Mead NJ)* 2000;29:453-6.
31. Yamazaki M, Koda M, Aramomi MA, Hashimoto M, Masaki Y, Okawa A. Anomalous vertebral artery at the extraosseous and intraosseous regions of the craniovertebral junction: Analysis by three-dimensional computed tomography angiography. *Spine (Phila Pa 1976)* 2005;30:2452-7.

Disclaimer: The authors of this article have no conflicts of interest to disclose, and have adhered to SNI's policies regarding human/animal rights, and informed consent. Advertisers in SNI did not ask for, nor did they receive access to this article prior to publication.