

Long-term Evaluation of Endothelial Cell Changes in Fuchs Corneal Dystrophy: The Influence of Phacoemulsification and Penetrating Keratoplasty

Yong Woo Kim^{1,2}, Mee Kum Kim^{1,2}, Won Ryang Wee^{1,2}

¹Department of Ophthalmology, Seoul National University Hospital, Seoul National University College of Medicine, Seoul, Korea

²Seoul Artificial Eye Center, Seoul National University Hospital Biomedical Research Institute, Seoul, Korea

Purpose: To evaluate the natural course of the long-term endothelial cell changes in Fuchs corneal dystrophy (FCD) patients and investigate the effects of phacoemulsification on the annual rate of change in endothelial indices in FCD patients.

Methods: Thirty-four patients diagnosed with FCD at Seoul National University Hospital from 1994 to 2010 were retrospectively reviewed. Sixteen patients who had been followed up for more than 1 year were selected and classified into 3 groups: group A, patients with no ocular surgery; group B, patients who had undergone phacoemulsification only; and group C, patients who had undergone penetrating keratoplasty with cataract surgery. Endothelial cell density, polymegathism, pleomorphism, and pachymetry were measured and the exponential rates of endothelial cell and pachymetry change were analyzed.

Results: A non-linear mixed model of non-operated FCD patients showed that only pachymetric data tended to increase with statistical significance ($p = 0.001$) with a mean follow-up period of 4.15 years. Using an exponential regression analysis fitting curve, the mean rates of annual endothelial cell loss were 0.82%/yr, 20.39%/yr, and 29.27%/yr in groups A, B, and C respectively, and statistical significance was seen only in group C ($p < 0.05$).

Conclusions: Retrospective long-term follow-up data showed that changes in endothelial density did not significantly decrease over at least 4 years in middle-aged FCD patients. The changes in pachymetric corneal thickness appeared to increase over the same period. Considering that no exponential changes were aggravated after performing cataract surgery alone, cataract surgery would be a preferable option in FCD patients compared to an approach of "wait-and-do" penetrating keratoplasty combined with cataract surgery.

Key Words: Endothelial cell density, Fuchs corneal dystrophy, Pachymetry, Phacoemulsification

Fuchs corneal dystrophy (FCD) is a bilateral, slowly progressive disease causing focal excrescences of Descemet's

membrane, or so-called guttata, which commonly appears during the fifth to seventh decades of life [1-3]. FCD occurs predominantly among women and is inherited in an autosomal dominant fashion with incomplete penetrance [4,5]. The exact pathogenic mechanism of progressive endothelial cell loss has not yet been determined. Currently, evidence is emerging that decreased expression of anti-apoptotic genes or aquaporin genes in the cornea may be

Received: October 9, 2012 Accepted: February 8, 2013

Corresponding Author: Mee Kum Kim, MD. Department of Ophthalmology, Seoul National University College of Medicine, #103 Daehank-ro, Jongno-gu, Seoul 110-799, Korea. Tel: 82-2-2072-2665, Fax: 82-2-741-3187, E-mail: kmk9@snu.ac.kr

© 2013 The Korean Ophthalmological Society

This is an Open Access article distributed under the terms of the Creative Commons Attribution Non-Commercial License (<http://creativecommons.org/licenses/by-nc/3.0/>) which permits unrestricted non-commercial use, distribution, and reproduction in any medium, provided the original work is properly cited.

involved in the pathogenesis of FCD [6-9]. Secondary stromal edema due to progressive endothelial cell loss often leads to loss of vision.

With regard to time-dependent changes, endothelial cell density normally decreases with age by 0.6% per year in the normal population [10,11]. Some diseases, including angle closure glaucoma, uveitis, and pseudoexfoliation syndrome are involved in more progressive endothelial cell loss than usually occurs [12,13]. In addition, intraocular surgery is also a critical factor involved in progressive endothelial cell loss, considering that the rate of endothelial cell loss increases to 2.5% per year with cataract surgery and 4.2% per year with penetrating keratoplasty [10,14,15].

It is unclear how fast endothelial loss or dysfunction progresses during the long-term natural course of FCD. This is very concerning when cataract surgery is required. Seitzman et al. [16] suggested that a preoperative pachymetry measurement of less than 640 μm indicated tolerable endothelial loss, resulting in the promotion of visual rehabilitation after cataract surgery in FCD patients. Afshari et al. [17] reported that cataract extraction advanced the time of penetrating keratoplasty by a mean of 3.2 years in a 30-year observational study in FCD patients. The effect of cataract surgery on the natural course of endothelial cell changes in FCD patients should be determined in a quantitative manner. This information will help to determine which approach would be better for FCD patients who need cataract surgery.

Thus, for the first time, we evaluated the natural course of long-term endothelial cell changes in FCD patients. We also investigated the effect of phacoemulsification on the annual rate of change in endothelial indices in FCD patients.

Materials and Methods

We retrospectively reviewed the medical records of 34 patients who were diagnosed with FCD at Seoul National University Hospital from 1994 to 2010. FCD was diagnosed when the patients showed central guttata in both eyes on examination by a slit-lamp and specular microscope, without any history of ocular inflammation. Among these patients, we selected 16 patients who had been followed up for more than 1 year and classified them into 3 groups: group A, patients with no ocular surgery (16 eyes

in 8 patients); group B, patients who had undergone phacoemulsification only (7 eyes in 4 patients); and group C, patients who had undergone penetrating keratoplasty with simultaneous extracapsular cataract extraction (2 eyes in 2 patients) or phacoemulsification afterwards (2 eyes in 2 patients). The follow-up period ranged from 12.3 months to 109.9 months (group A, 18.2 to 109.9 months; group B, 12.3 to 45.8 months; and group C, 41.7 to 85.1 months). Every patient in group C had a diagnosis of bullous keratopathy due to FCD. Age- and sex-matched non-FCD patients who underwent phacoemulsification and penetrating keratoplasty were also included to compare exponential changes in endothelial cell count (ECC) between non-FCD and FCD patients (8 eyes in 7 patients; 6 with viral keratitis, 1 with band keratopathy, and 1 with bullous keratopathy). Endothelial cell density, polymegethism (coefficient of variance, CV), pleomorphism (hexagonality), and pachymetry were measured by experienced ophthalmic technicians using a specular microscope (Noncon ROBO CA; Konan Medical, Hyogo, Japan) and ultrasonic pachymeter (Pocket II; Quantel Medical, Clermont-Ferrand, France). We investigated the annual change in FCDs using a non-linear mixed model with the SAS ver. 9.1 (SAS Institute, Cary, NC, USA). We evaluated the exponential rate of endothelial cell and pachymetry change in each group by exponential curve fitting regression analysis using the SPSS ver. 17.0 (SPSS Inc., Chicago, IL, USA). The Kruskal-Wallis method was used for comparing demographic findings between groups. A non-linear mixed model was used in group A, which included a sufficient number of patients to show statistical significance.

Results

There were 3 men and 13 women among the 16 patients. Ages ranged from 22 to 82 years (62.32 ± 13.10 years, mean \pm standard deviation), and the mean follow-up period was 3.88 ± 2.25 years. The mean endothelial cell density and pachymetry measurements of the 16 patients at initial examination were $1,413.91 \pm 735.42/\text{mm}^2$ and 576.56 ± 74.04 μm , respectively. There were no statistical differences in age, sex, initial endothelial cell density, and initial pachymetry measurements among the 3 groups (Table 1).

First, we investigated the natural course of FCD among patients who had not undergone surgery. Non-linear mixed

Table 1. Patient demographics in groups A, B, and C

	Group A* (16 eyes)	Group B† (7 eyes)	Group C‡ (4 eyes)	p-values§
Sex (male : female)	1 : 7	0 : 4	2 : 2	0.081
Mean age (yr)	56.38	68.5	67.14	0.233
Range	22-71	55-82	48-79	
Mean follow-up period (yr)	4.15	1.99	5.23	0.003
Range	1.5-9.2	1.02-3.81	3.5-7.1	
Mean initial logMAR	0.112	0.642	0.429	0.001
Mean initial ECC (mm ²)	1528.33	1456.42	857.00	0.411
Mean initial pachymetry (mm)	566.91	642.50	576.85	0.376
Mean final logMAR	0.185	0.235	1.494	0.032

logMAR = logarithm of the minimum angle of resolution; ECC = endothelial cell count.

*Patients with no ocular surgery; †Patients who had undergone phacoemulsification only; ‡Patients who had undergone penetrating keratoplasty with cataract surgery; §Kruskall-Wallis method.

Table 2. Annual rate (r) using a nonlinear mixed model ($y = e^{-rt}$) showed significant change in pachymetry over time in non-operated Fuchs dystrophy patients

Variable	Parameter	Estimate	Standard error	p-value*
ECC	Rate	0.0423	0.0231	0.0713
	ECC _{initial}	1,628.29	163.28	<0.0001
CV	Rate	-0.0006	0.0183	0.975
	CV _{initial}	35.6886	2.1734	<0.0001
Hexagonality	Rate	0.0150	0.0218	0.4946
	HEXA _{initial}	45.5137	2.9396	<0.0001
Pachymetry	Rate	-0.0083	0.0024	0.001
	PACHY _{initial}	559.73	12.7416	<0.0001

ECC = endothelial cell count; ECC_{initial} = estimated initial ECC from nonlinear mixed model; CV = coefficient of variance; CV_{initial} = estimated initial CV from nonlinear mixed model; HEXA_{initial} = estimated initial hexagonality from nonlinear mixed model; PACHY_{initial} = estimated initial pachymetry from nonlinear mixed model.

*Nonlinear mixed model.

models for time-dependent changes in these patients showed that only pachymetric data tended to increase with statistical significance ($p = 0.001$), with a mean follow-up of 4.15 years (Table 2). The changes in ECC, CV, and hexagonality were not significant during these periods using the aforementioned model. This suggests that functional deterioration progresses over a period of 4 years without noticeable morphologic changes in endothelial cells.

Next, we evaluated whether long-term endothelial changes were worse when FCD patients underwent cataract surgery only or penetrating keratoplasty with cataract surgery. Regression analysis showed that the mean rates of annual endothelial cell loss were 0.82%/yr, 20.39%/yr, and 29.27%/yr in groups A, B, and C, respectively, and the rate

in group C showed statistical significance ($p < 0.05$) (Fig. 1A). Thus, only the patients who underwent penetrating keratoplasty and cataract surgery showed exponential endothelial cell loss over time. The mean rates of pachymetric change were -1.81%/yr, +1.21%/yr, and +1.89%/yr in groups A, B, and C, respectively, showing no statistical significance (Fig. 1B). The mean rates of change in CV were +1.94%/yr, +1.21%/yr, and +0.48%/yr in groups A, B, and C, respectively, showing no statistical significance (Fig. 1C). The mean rates of hexagonality change were -1.04%/yr, -8.06%/yr, and -1.19%/yr in groups A, B, and C, respectively, showing no statistical significance (Fig. 1D). There was no significant change in the logarithm of the minimum angle of resolution (logMAR) visual acuity of group

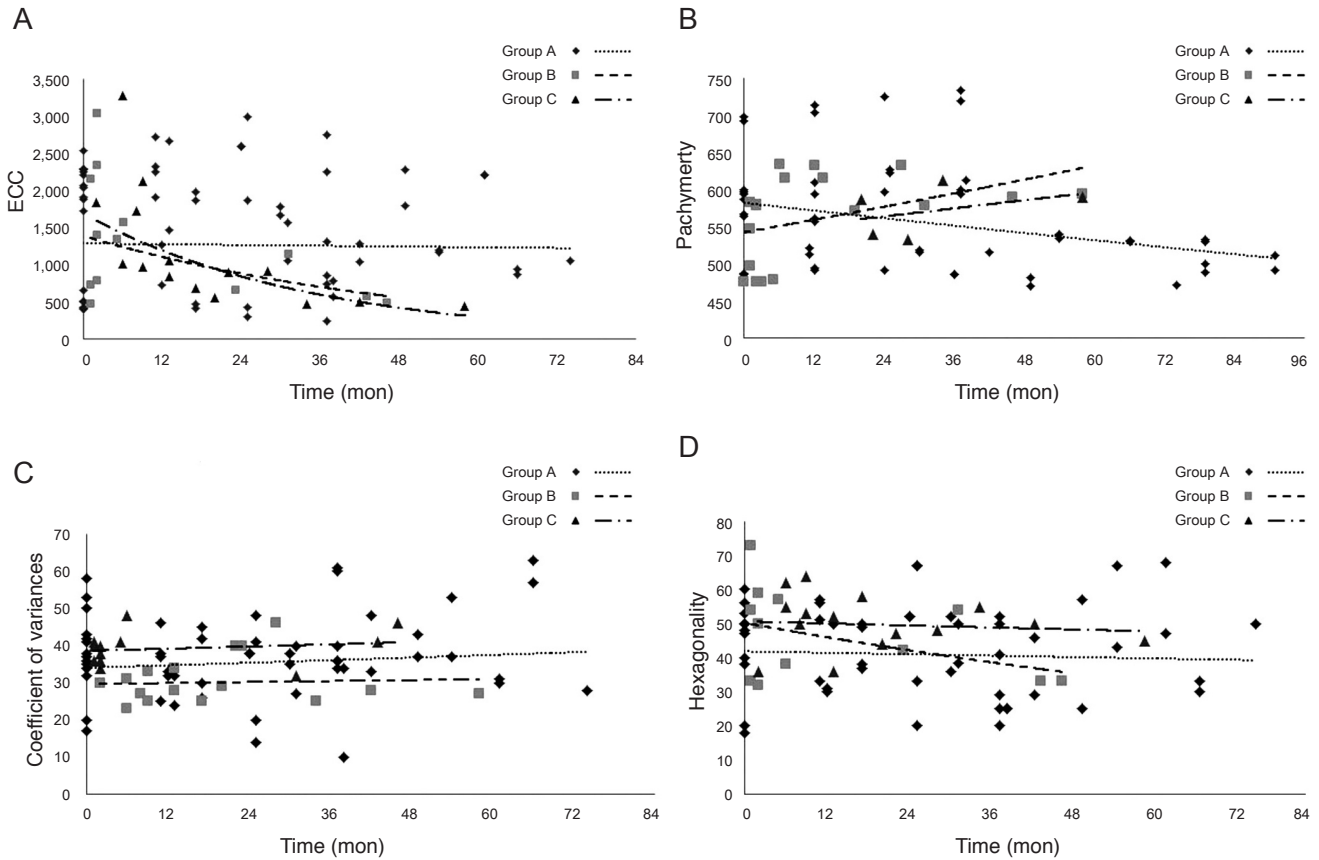


Fig. 1. Exponential curve fitting model. (A) The mean rates of endothelial cell loss were 0.82% per year, 20.39% per year, and 29.27% per year in groups A, B, and C respectively. However, only the rate in group C was statistically significant ($p < 0.05$). (B) The mean rates of pachymetric change were -1.81% per year, +1.21% per year, and +1.89% per year in groups A, B, and C respectively, but showed no statistical significance. (C) The mean rates of coefficient of variances change were +1.94% per year, +1.21% per year, and +0.48% per year in groups A, B, and C respectively, but showed no statistical significance. (D) The mean rates of hexagonality change were -1.04% per year, -8.06% per year, and -1.19% per year in groups A, B, and C respectively, but showed no statistical significance. ECC = endothelial cell count.

A during the follow up period ($p = 0.100$, Wilcoxon rank-sum test). However, there was significant improvement of logMAR visual acuity in group B after surgery (from 0.642 to 0.235, $p = 0.043$, Wilcoxon rank-sum test). The logMAR visual acuity in group C showed a high tendency to deteriorate after surgery, but did not show any statistical significance (from 0.429 to 1.494, $p = 0.068$, Wilcoxon rank-sum test). Taken together, morphologic changes and functional deterioration were not aggravated in an exponential manner in either non-operated FCD patients or those with cataract surgery, but in those with penetrating keratoplasty combined with cataract surgery.

Finally, we checked the exponential changes in endothelium parameters in age and sex-matched non-FCD patients (mean age non-FCD patients, 59.0 ± 6.3 vs. FCD patients, 68.5 ± 5.5 , $p = 0.298$; sex distribution, $p = 0.428$) who underwent penetrating keratoplasty and cataract surgery to

indirectly compare these changes with those in FCD patients (Fig. 2). The mean rate of endothelial cell loss was 19.43% per year (with statistical significance) in non-FCD patients and 29.27% per year in FCD patients. Thus, endothelial density was exponentially reduced in both FCD and non-FCD patients who underwent penetrating keratoplasty and cataract surgery. The mean rates of pachymetric change were +0.13% per year with no significance in non-FCD patients and +1.89% per year in FCD patients. The mean rates of CVs change were +1.21% per year without any significance in non-FCD patients and +0.48% per year in FCD patients. The mean rates of hexagonality change were -0.48% per year without any significance in non-FCD patients and -1.19% per year in FCD patients. This implies that morphologic changes and functional deterioration were not exponentially worse in either group. No patients experienced corneal stromal edema during the study period.

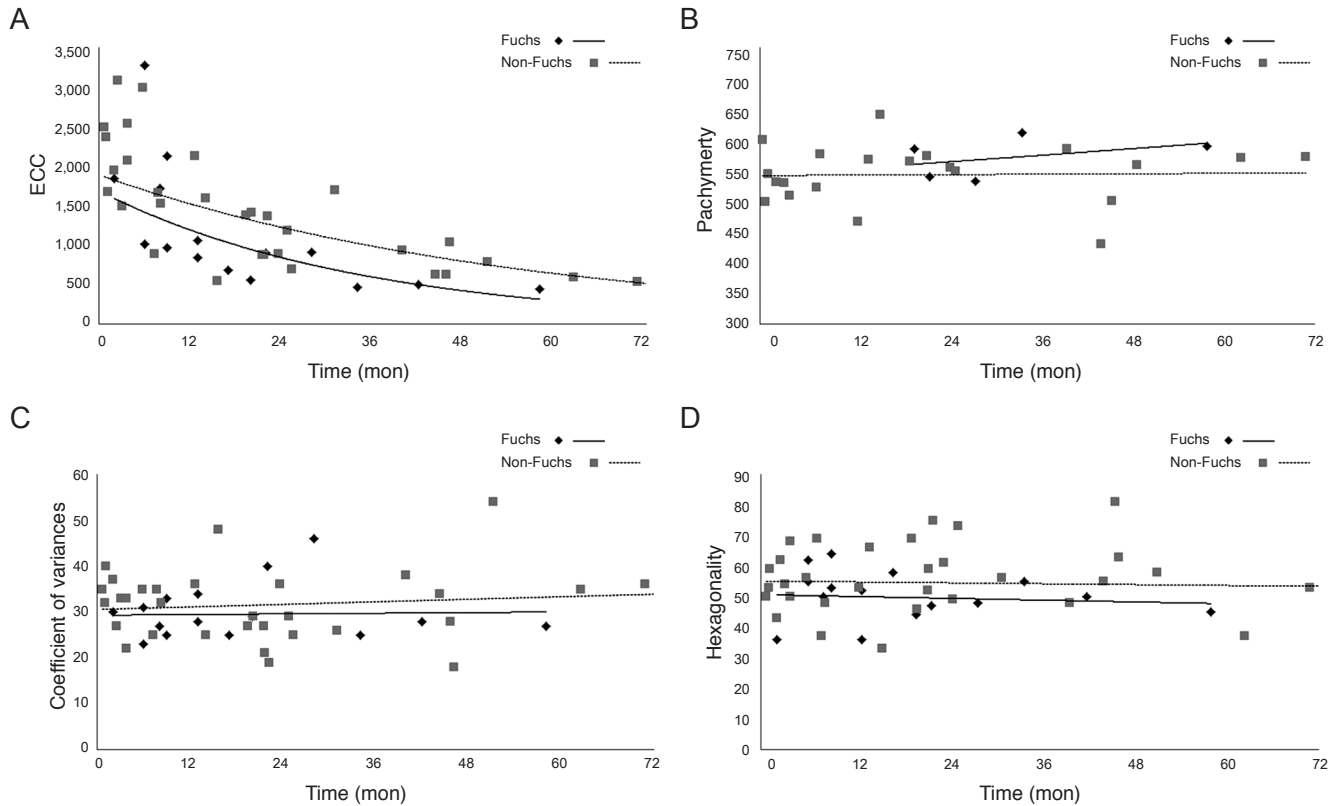


Fig. 2. Exponential curve fitting regression model in non-Fuchs patients who underwent penetrating keratoplasty and cataract surgery. (A) The mean rate of endothelial cell loss was 19.43% per year with statistical significance, while the loss rate was 29.27% per year in group C (Fuchs corneal dystrophy patients who underwent keratoplasty and cataract surgery simultaneously). (B) The mean rate of pachymetric change was +0.13% per year, and in contrast, +1.89% per year in group C. (C) The mean rate of coefficient of variances change was +1.21% per year, and +0.48% per year in group C. (D) The mean rate of hexagonality change was -0.48% per year and -1.19% per year in group C. ECC = endothelial cell count.

Discussion

Our retrospective long-term follow-up data showed that endothelial density did not significantly decrease over the course of four years in middle-aged FCD patients, while changes in pachymetric corneal thickness appeared to increase during the same period. This suggested that endothelial function progressively deteriorated during this period, although the density and morphologic changes were not severely advanced. This outcome supports Seitzman’s suggestion that the pachymetric index should be given more importance when determining whether cataract surgery should be performed in FCD patients [16].

In terms of the semi-quantitative view using exponential curve fitting regression analysis, the mean endothelial cell density loss rate was 1.4-times higher (0.82%/yr) in middle-aged FCD patients (mean age, 62 years) compared to that in the normal population (0.5%/yr) during a mean fol-

low-up of 4.15 years [10]. In addition, the natural course of changes in endothelial density and morphology in FCD patients did not follow an exponential curve; this can provide relief for providers and patients during the long-term follow-up of patients in their fifties.

Another interesting finding was that cataract surgery did not significantly worsen the natural course of FCD patients, although the annual decrease in ECC increased. In addition, visual acuity significantly improved an average of 2 years after the phacoemulsification. This may be explained from the clinical impression that the majority of Korean patients had guttata confined to the central cornea, while those of Caucasians are distributed around the entire cornea. Relatively intact peripheral corneal endothelial cells may have facilitated endurance of the mechanical stress of phacoemulsification. Meanwhile, FCD patients who underwent both penetrating keratoplasty and cataract surgery experienced exponential decreases in endothelial

density similar to those in non-FCD patients. Although we could not directly compare the loss rate between the groups due to small numbers, the annual decrease rates in endothelial density were higher in FCD patients than in non-FCD patients.

Whenever cataracts that disturb vision develop in FCD patients with moderate-to-low ECC densities, ophthalmologists have to decide whether cataract surgery should be immediately performed or postponed until keratoplasty is required. The better option for visual rehabilitation in FCD patients has long been controversial; it is unclear whether cataract surgery alone or cataract surgery combined with keratoplasty should be performed [18-20]. Our data indicated how fast the natural course of ECC changes progress in FCD patients with the intervention of cataract surgery. Compared with combined cataract surgery and keratoplasty, cataract surgery alone appeared to have some benefit in providing less astigmatic visual quality; nevertheless, cataract surgery alone exacerbated ECC loss. In addition, considering that no exponential changes were aggravated after performing cataract surgery alone, cataract surgery would be a preferable option in FCD patients compared to an approach of "wait-and-do" penetrating keratoplasty combined with cataract surgery.

The present study has two major limitations, namely the small population size and the wide variance in follow-up periods among the groups. Although these limitations weaken the statistical power of the present study, we believe it may be worthy of notice considering that it is a first report of long-term quantitative observation of endothelial cell change in FCD patients. Further prospective well-controlled studies with larger patient groups are needed.

Conflict of Interest

No potential conflict of interest relevant to this article was reported.

Acknowledgements

We sincerely appreciate the Medical Research Collaborating Center in Seoul National University Hospital for the aid of statistical analysis in this study.

References

1. Borboli S, Colby K. Mechanisms of disease: Fuchs' endothelial dystrophy. *Ophthalmol Clin North Am* 2002;15:17-25.
2. Adamis AP, Filatov V, Tripathi BJ, Tripathi RC. Fuchs' endothelial dystrophy of the cornea. *Surv Ophthalmol* 1993;38:149-68.
3. Lietman T, Lee J, Costanza S. Those excrescences on Descemet's membrane. *Br J Ophthalmol* 2003;87:515-6.
4. Cross HE, Maumenee AE, Cantolino SJ. Inheritance of Fuchs' endothelial dystrophy. *Arch Ophthalmol* 1971;85:268-72.
5. Magovern M, Beauchamp GR, McTigue JW, et al. Inheritance of Fuchs' combined dystrophy. *Ophthalmology* 1979; 86:1897-923.
6. Li QJ, Ashraf MF, Shen DF, et al. The role of apoptosis in the pathogenesis of Fuchs endothelial dystrophy of the cornea. *Arch Ophthalmol* 2001;119:1597-604.
7. Gottsch JD, Bowers AL, Margulies EH, et al. Serial analysis of gene expression in the corneal endothelium of Fuchs' dystrophy. *Invest Ophthalmol Vis Sci* 2003;44:594-9.
8. Macnamara E, Sams GW, Smith K, et al. Aquaporin-1 expression is decreased in human and mouse corneal endothelial dysfunction. *Mol Vis* 2004;10:51-6.
9. Szentmary N, Szende B, Suveges I. Epithelial cell, keratocyte, and endothelial cell apoptosis in Fuchs' dystrophy and in pseudophakic bullous keratopathy. *Eur J Ophthalmol* 2005;15:17-22.
10. Bourne WM, Nelson LR, Hodge DO. Central corneal endothelial cell changes over a ten-year period. *Invest Ophthalmol Vis Sci* 1997;38:779-82.
11. Roszkowska AM, Colosi P, D'Angelo P, Ferreri G. Age-related modifications of the corneal endothelium in adults. *Int Ophthalmol* 2004;25:163-6.
12. Inoue K, Okugawa K, Oshika T, Amano S. Morphological study of corneal endothelium and corneal thickness in pseudoexfoliation syndrome. *Jpn J Ophthalmol* 2003;47:235-9.
13. Sihota R, Lakshmaiah NC, Titiyal JS, et al. Corneal endothelial status in the subtypes of primary angle closure glaucoma. *Clin Experiment Ophthalmol* 2003;31:492-5.
14. Patel SV, Hodge DO, Bourne WM. Corneal endothelium and postoperative outcomes 15 years after penetrating keratoplasty. *Trans Am Ophthalmol Soc* 2004;102:57-65.
15. Ing JJ, Ing HH, Nelson LR, et al. Ten-year postoperative results of penetrating keratoplasty. *Ophthalmology* 1998;105:1855-65.
16. Seitzman GD, Gottsch JD, Stark WJ. Cataract surgery in patients with Fuchs' corneal dystrophy: expanding recommendations for cataract surgery without simultaneous keratoplasty. *Ophthalmology* 2005;112:441-6.

17. Afshari NA, Pittard AB, Siddiqui A, Klintworth GK. Clinical study of Fuchs corneal endothelial dystrophy leading to penetrating keratoplasty: a 30-year experience. *Arch Ophthalmol* 2006;124:777-80.
18. Seitzman GD. Cataract surgery in Fuchs' dystrophy. *Curr Opin Ophthalmol* 2005;16:241-5.
19. Eghrari AO, Daoud YJ, Gottsch JD. Cataract surgery in Fuchs corneal dystrophy. *Curr Opin Ophthalmol* 2010;21:15-9.
20. Traish AS, Colby KA. Approaching cataract surgery in patients with fuchs' endothelial dystrophy. *Int Ophthalmol Clin* 2010;50:1-11.