

# Rate of Post-traumatic Endophthalmitis with or without Injection of Balanced Salt Solution

Nasrin Rafati<sup>1</sup>, MD; Mohsen Azarmina<sup>1</sup>, MD; Farid Zaeri<sup>2</sup>, PhD  
Shahin Yazdani<sup>1</sup>, MD; Roham Soheilian<sup>3</sup>; Masoud Soheilian<sup>1</sup>, MD

<sup>1</sup>Ophthalmic Research Center, Shahid Beheshti University of Medical Sciences, Tehran, Iran

<sup>2</sup>Department of Biostatistics, Faculty of Paramedical Sciences, Shahid Beheshti University of Medical Sciences, Tehran, Iran

<sup>3</sup>Medical Student, Shahid Beheshti University of Medical Sciences, Tehran, Iran

**Purpose:** In a study complementing a previous multicenter randomized clinical trial on prophylactic injection of intraocular antibiotics during primary repair of penetrating eye injuries (PEIs), we sought to determine whether needle entrance and injection of balanced salt solution (BSS), per se, could increase the rate of acute post-traumatic bacterial endophthalmitis (APBE).

**Methods:** Patients randomized to the BSS injection arm (n=167) of the Traumatic Endophthalmitis Trial, and eligible patients who had refused enrollment and received no intraocular injections during primary repair (n=111) were compared for the development of APBE.

**Results:** APBE occurred in 8 of 167 (4.8%) eyes in the BSS group and in 5 of 111 (4.5%) eyes in the non-injection group (P=0.91). Retained intraocular foreign bodies were present in 46 eyes including 25 (15%) eyes in the BSS injection group and 21 (18.9%) eyes in the non-injection group (P=0.38). Logistic regression analysis showed no significant difference between BSS injected and non-injected eyes in terms of APBE (P=0.69). However, the presence of intraocular foreign bodies was strongly associated with the risk of endophthalmitis (P<0.001, OR=14.1, 95% CI: 4.1-48.5).

**Conclusion:** Needle entrance and intraocular injection of BSS during primary repair of PEIs does not increase the risk of APBE.

**Keywords:** Bacterial Endophthalmitis; Intraocular Injection; Penetrating Eye Injury

*J Ophthalmic Vis Res* 2013; 8 (3): 237-243.

**Correspondence to:** Masoud Soheilian, MD. Professor of Ophthalmology; Labbafinejad Medical Center, Paidarfard St., Boostan 9 St., Pasdaran, Tehran 16666, Iran; Tel: +98 21 2258 5952, Fax: +98 21 2259 0607; e-mail: masoud\_soheilian@yahoo.com

**Received:** August 16, 2012

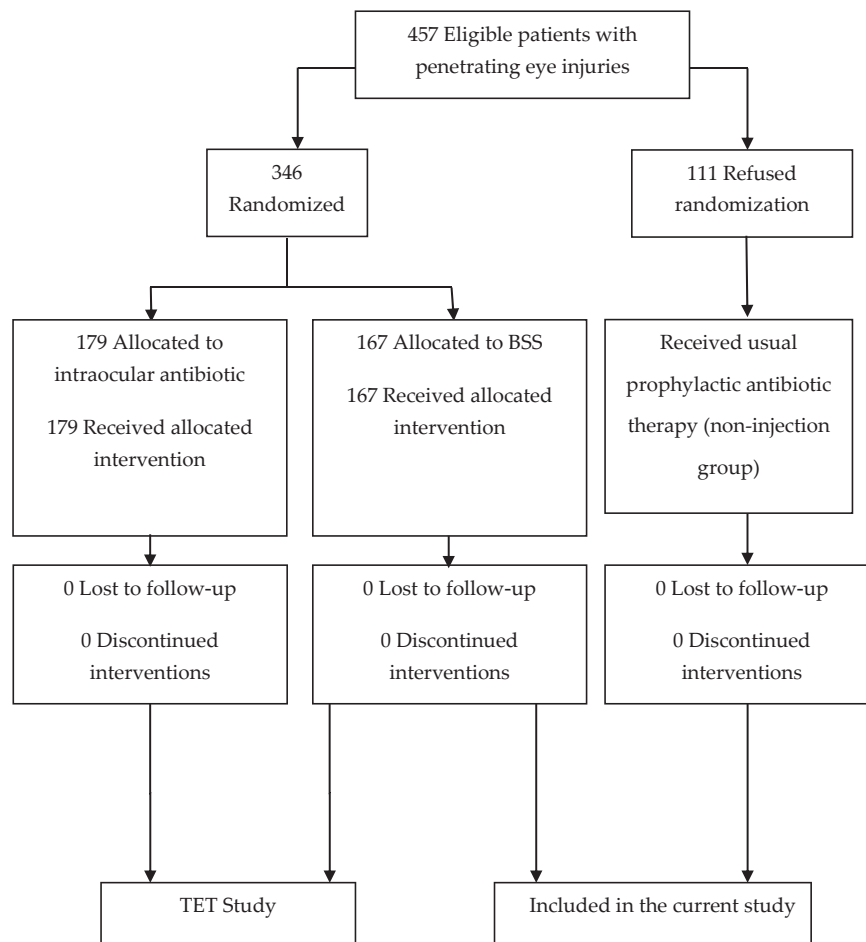
**Accepted:** December 05, 2012

## INTRODUCTION

Intraocular injection is a popular route for administration of gas, antibiotics, steroids, anti-vascular endothelial growth factor agents, and antiviral medications in many ocular conditions.<sup>1,2</sup> Complications including endophthalmitis, uveitis, vitreous hemorrhage, cataracts, ocular hypertension and glaucoma,

and retinal detachment have been reported after intraocular injections.<sup>3</sup>

Although intraocular injection is a fast and simple procedure performed through a small wound, it has been shown that the presence of only a small number of bacteria is sufficient to induce endophthalmitis, the prevalence of which depends on the setting and indication for injection. This is of particular concern in



**Figure 1.** Schema of the current study population. The Traumatic Endophthalmitis Trial (TET)<sup>17,18</sup> protocol required randomized patients to receive injection of intraocular antibiotics versus balanced salt solution (BSS) after primary repair (346 eyes). A total of 111 non-randomized patients (who declined intraocular injection after primary repair) with one month of follow-up served as controls.

penetrating eye injuries (PEIs) where it is a common assumption that dirty lacerations are more likely to become infected, possibly due to inability of the vitreous to clear microorganisms. The incidence of endophthalmitis following intravitreal injections unrelated to trauma or acute post-traumatic bacterial endophthalmitis (APBE) varies from 0.014 to 0.87% per injection and from 0.7 to 2.9% per eye.<sup>4-10</sup>

Intraocular administration of antibiotics for prophylaxis against APBE has recently gained considerable attention.<sup>11-13</sup> This route of administration bypasses the blood-ocular barriers and appears to be the most effective method of achieving high drug concentrations inside the eye without systemic side effects.<sup>6</sup> However, intraocular injection in PEI may entail

more complications as compared to routine injections because of technical issues such as visibility.<sup>14-16</sup> Some investigators believe that prophylactic intraocular medications should be used cautiously because there may be an additional risk of endophthalmitis, particularly following PEI.<sup>13</sup>

The Traumatic Endophthalmitis Trial (TET)<sup>17,18</sup> was a multicenter randomized controlled trial in which four major tertiary eye care centers randomized eligible patients with PEI to prophylactic intravitreal injection of clindamycin and gentamicin versus balanced salt solution (BSS) during primary repair. This study demonstrated a significantly lower rate of APBE in antibiotic injected eyes as compared to BSS injected eyes. However, there were

criticisms that intraocular BSS injection per se could have increased the risk of APBE in the control group.<sup>15</sup>

We undertook this study to revisit the TET trial<sup>17,18</sup> data and compare the rate of APBE in patients who received BSS (control arm of the trial) with that of eligible patients who had refused enrollment and received only standard care (systemic and topical antibiotics) without any intraocular injection (Fig. 1).

## METHODS

The study followed the protocol of the TET trial<sup>17,18</sup> and adhered to the tenets of the declaration of Helsinki.<sup>19</sup> It was approved by the Ethics Committee of the Ophthalmic Research Center and by the Iranian Research Center for Medical Sciences.

### Patients

Patients referred for PEI to four major academic eye care centers in Iran over a 5-year period (July 1999 to September 2004) were reassessed. Data on patients randomized to the BSS injection arm (n=167) of the TET trial<sup>17,18</sup> and eligible patients who had refused enrollment in the trial and had received only standard care (systemic and topical antibiotics) without intraocular injection during primary repair (n=111) were re-evaluated.

Exclusion criteria were absence of light perception, presence of endophthalmitis at the time of initial evaluation, total corneal opacity, age younger than 3 years, severe hyphema, history of intraocular surgery and presence of a corneal ulcer. Monocular patients and the better eye in bilateral injuries were also excluded.

### Initial Management

A complete ocular examination was performed in all patients, details of which have previously been described.<sup>17,18</sup> In brief, all eligible patients were admitted for primary repair and administration of intravenous gentamicin sulfate (3-5mg/kg) every 8 hours along with cefazolin sodium (50mg/kg) every 6 hours, for 5 days following surgery. In the original trial, enrolled case and

control eyes with lacerations anterior to the rectus muscle insertions and an intact lens capsule received intracameral injection of gentamicin sulfate (40 micrograms) and clindamycin (45 micrograms) versus 0.1ml BSS, respectively. Eyes with lacerations limited to or extending posterior to the rectus muscle insertions or those with a ruptured lens capsule received the same injections through an intravitreal route.

For the purpose of the current study, data on a cohort of patients who were eligible for the TET trial but declined enrollment were analyzed. This group received all of the above mentioned standard treatments except for intraocular injection of any nature.

### Surgical Technique

All patients underwent surgery under general anesthesia. Corneal and scleral lacerations were repaired in a standard fashion. In the BSS injection group, intracameral injections were performed through the limbus via a #27 needle. Intravitreal injections were performed through the sclera, 4mm posterior to the limbus in phakic eyes (3.5mm in aphakic eyes).<sup>18</sup> At the conclusion of surgery, 20 mg gentamicin and 4 mg betamethasone were injected subconjunctivally in all patients.

### Postoperative Medications and Follow-up

The postoperative regimen included gentamicin drops four times a day and atropine drops three times a day for 1 week. Topical betamethasone was also administered four times a day for 6 weeks. Oral prednisolone (1mg/kg/day) was initiated 24 hours postoperatively and tapered after approximately 1 week depending on the severity of inflammation.

All patients were hospitalized for 15 days and underwent daily examinations. One masked independent observer examined the patients on days 1, 2, 3, 5, 7 and 14. A complete ophthalmologic examination was performed during each visit to determine the amount of anterior chamber and vitreous reaction, and haziness. In eyes with poor visibility of the posterior segment, echography was performed

24 hours after primary repair to detect posterior segment complications. An orbital x-ray was obtained for all patients as well as a high-resolution orbital computed tomographic scan for those suspected of a retained intraocular foreign body (IOFB).

**Main Outcome Measures**

The primary outcome measure was the development of APBE 2 weeks following primary repair. Endophthalmitis was diagnosed in the setting of pain, lid swelling, decreased visual acuity and 3+ or more cells in the anterior chamber together with any of the following signs: vitritis with loss of red reflex, vitreous involvement detected by echography in eyes with media opacity, or a positive culture of harvested intraocular fluids. The diagnosis of endophthalmitis was confirmed by two other masked independent observers. Secondary outcome measures included the rate and type of additional procedures required during hospitalization.

**Statistical Analysis**

For descriptive purposes, we described quantitative variables in mean ± standard

deviation (SD) and qualitative variable in rates and percentages. For univariate analysis, the chi-square test and independent sample t-test were used. A logistic regression model was utilized to assess the simultaneous effect of treatment modality and presence of IOFB on the development of endophthalmitis. Data management and analysis was conducted by a masked statistician using SPSS software, version 15.0. P-values less than 0.05 were considered as statistically significant.

**RESULTS**

**Characteristics and Initial Status of Patients**

This study included 278 eyes of 278 patients consisting of 167 BSS injected eyes and 111 non-injected eyes. The BSS injection group included 145 (86.8%) male and 22 (13.2%) female subjects; the non-injection group included 92 (82.9%) male and 19 (17.1%) female subjects (P=0.364). Mean±SD age was 22.5±14.6 years in the BSS group and 22.7±12.7 years in the non-injection group (P=0.9). Mean±SD initial visual acuity was 1.59±1.11 logMAR in the BSS group and 1.58±1.02 logMAR in the non-injection group (P=0.938). Overall, initial visual acuity was better than 20/200 in 105 (37.7%) eyes, counting

**Table 1.** Summary of clinical findings associated with eye injury in the study groups

Clinical Findings	Study group		P
	Non-injection No. (%)	BSS No. (%)	
Length of Laceration			
≤5 mm	49 (44.1)	68 (40.7)	0.571
>5 mm	62 (55.9)	99 (59.3)	
Location of Wound			
Sclera	15 (13.6)	22 (13.2)	0.207
Cornea	57 (51.8)	103 (61.7)	
Sclera and Cornea	38 (34.5)	42 (25.1)	
Posterior Segment Involvement	26 (23.9)	23 (19.7)	0.444
Lens Injury	51 (45.9)	78 (46.7)	0.901
Injury to Repair Interval			
≤5 days	4 (3.6)	15 (9.0)	0.080
>5 days	107 (96.4)	151 (91.0)	
Presence of IOFB	21 (18.9)	25 (15.0)	0.386
Vitreous Prolapse	45 (40.5)	63 (37.7)	0.637
Site of Injection			
Intracameral	34 (30.6)	70 (41.9)	0.057
Intravitreal	77 (69.4)	97 (58.1)	

BSS, balanced salt solution; IOFB, intraocular foreign body; No., Number

fingers in 83 (29.8%) eyes, hand motions in 58 (20.9%) eyes, and light perception in 32 (11.6%) eyes. Afferent pupillary defect was present in 35 eyes (12.6%), negative in 178 eyes (64.0%), and not obtainable in 65 eyes (23.4%). The study groups were comparable in terms of length of laceration, location of wound, lens injury, time interval from injury to repair, presence of IOFB, and vitreous prolapse (Table 1).

### Development of Acute Post-traumatic Bacterial Endophthalmitis

Overall, APBE occurred in 13 of 278 eyes (4.7%); these included 8 of 167 (4.8%) BSS injected eyes and 5 of 111 (4.5%) non-injected eyes ( $P=0.912$ ). An IOFB was present in 46 of 278 eyes (16.5%) overall which included 25 eyes (15%) in the BSS group and 21 eyes (18.9%) in the non-injection group ( $P=0.386$ ). Logistic regression analysis considered the presence of IOFB and treatment modality (intraocular BSS injection versus no injection) as explanatory factors and the occurrence of APBE as the response variable. This analysis demonstrated that the presence of IOFB was significantly associated with the occurrence of endophthalmitis ( $P<0.001$ , OR=14.1, 95% CI: 4.1-48.5). However, with presence of an IOFB as an independent risk factor, there was no significant difference between BSS injected and non-injected eyes in terms of endophthalmitis ( $P=0.69$ , OR=1.28, 95% CI: 0.38-4.28). Vitreous culture was positive in 10 of 13 eyes (76.9% with endophthalmitis and the most common isolated microorganism was *Staphylococcus epidermidis*, cultured from seven eyes. *Staphylococcus aureus*, *Propionibacterium acnes*, and mixed cultures were seen each in one eye.

### Additional Procedures

Posterior segment abnormalities were detected by clinical examination and echography when necessary; these included vitreous hemorrhage (85 eyes, 30.6%), retinal detachment (4 eyes, 1.4%), and vitreous hemorrhage with retinal detachment (16 eyes, 5.8%). Secondary operations were performed in 132 eyes (47.5%) before day 15 after primary repair and included IOFB removal,

**Table 2.** Additional surgical procedures in the study groups

Secondary Surgery	Study group	
	Non-injection	BSS
	No. (%)	No. (%)
IOFB Removal	30 (27.0)	0 (0.0)
Vitreoretinal Surgery	12 (10.8)	20 (12.0)
Lensectomy	18 (16.2)	19 (11.4)
Enucleation	8 (7.2)	3 (1.8)
Cataract Extraction	1 (0.9)	2 (1.2)
IOFB Removal+ Vitreoretinal Surgery	2 (1.8)	0 (0.0)
IOFB Removal+ Lensectomy	1 (0.9)	0 (0.0)
Vitreoretinal Surgery+ Lensectomy	0 (0.0)	16 (9.6)

BSS, balanced salt solution; IOFB, intraocular foreign body; No., Number

cataract surgery, vitreoretinal procedures and enucleation. Additional procedures were required in 60 patients (35.9%) in the BSS group versus 72 patients (64.9% in the non-injection group ( $P<0.001$ ). Table 2 details additional surgical procedures in the study groups.

### Post Hoc Power Analysis

The current study showed no significant difference between the study groups regarding APBE. The power of the study was 76.2% for detecting a 10% difference between the study groups and 53% for detecting a 7% difference. Post hoc power analysis revealed that with study power set at 80%, the required sample size for detection of a 10%, 7% and 0.3% intergroup difference (the actual value observed in the current study) would be 131, 232, and 77,242 eyes respectively. In other words if we consider the observed 0.3% intergroup difference in the rate of APBE to be clinically significant, a sample size of over 77,000 eyes would be required to demonstrate it with adequate statistical power.

### DISCUSSION

The current study was performed to address criticisms on our previous multicenter randomized controlled trial<sup>17,18</sup> which compared intraocular antibiotics versus BSS injection and to determine the role of prophylactic intraocular antibiotic injection on the incidence of APBE.



The former study concluded that such injections have a protective role in the development of APBE. However, some opponents believed that the control group in the TET study may have developed a higher rate of infection causing an artifactual benefit in favor of the treatment group, or that we may have unnecessarily exposed our control group to risks of intraocular injection.<sup>15</sup>

We revisited the available data on the control arm of the TET study (eyes receiving intraocular BSS) and data on patients who had been eligible for enrollment but declined to do so. These patients had received a standard treatment protocol of admission, intravenous antibiotics, primary repair, and subconjunctival antibiotics, followed by a 5-day period of intravenous antibiotics and addition of topical antibiotics. The latter group served as a new control group for the present study and were similar to the control arm of the TET study in all aspects except for lack of intraocular injections.

The incidence of APBE in patients who received intraocular injection of BSS and patients who received routine antibiotic therapy without any intraocular injection was remarkably similar (4.8% and 4.5%, respectively). The power of the study to detect this 0.3% difference was low, however this negligible difference is not clinically important.

In line with another report,<sup>18</sup> the presence of an IOFB was a confounder and significantly associated with the occurrence of endophthalmitis, but there was no significant difference between BSS injected eyes and non-injected eyes in rate of APBE after controlling for this independent risk factor.

We could not randomly allocate eyes to BSS injection versus non-injection because some patients had refused intraocular injection in the first place and were thus not enrolled in the TET study. However, baseline data and main factors such as age, sex, initial visual acuity, length and location of the laceration, lens injury, injury to repair interval, presence of IOFB, and vitreous prolapse were comparable between the study groups. The rate of additional procedures was significantly higher in non-injected eyes (64.9%) as compared to BSS injected eyes (35.9%). We are unable to explain this difference, but it further

reinforces the notion that intraocular injections do not impose any additional risk.

The incidence of APBE has been reported to vary from 3.3% to 30% in different series depending on the setting of trauma.<sup>20</sup> Our initial report<sup>18</sup> disclosed a prominent protective role for intraocular antibiotics such that the rate of APBE in eyes harboring an IOFB but receiving prophylactic injections was nil. This is the lowest rate of endophthalmitis in the presence of IOFB in the literature.

One should not underestimate the risk of endophthalmitis following intraocular injection of any type. The cumulative per injection rate of endophthalmitis following intravitreal injection is 0.051%, which is slightly higher than a corresponding rate of 0.04% following incisional procedures such as cataract surgery.<sup>10</sup> This may be due to less strict adherence to aseptic technique during routine intraocular injections, which are becoming an office-based procedure. Pilli and colleagues demonstrated that the incidence of endophthalmitis was reduced by a factor of 4 when rules of surgical asepsis were respected.<sup>21</sup>

To the best of our knowledge, the current study is the first to investigate the risk of endophthalmitis after intraocular injection in patients with PEI. The results of this study showed no significant difference between BSS injected and non-injected eyes in terms of development of APBE. Therefore one may conclude that the introduction of a needle for intraocular injection per se, entails no additional risk for APBE. These findings may further strengthen our previous observations regarding the reduced rate of APBE with prophylactic injection of intraocular antibiotics at the time of primary repair in PEIs, especially in the presence of an IOFB.

### Acknowledgments

The authors would like to thank M. Katibeh, MD and M. Yaseri, PhD for reviewing the manuscript and giving their valuable comments.

### Conflicts of Interest

None.

REFERENCES

1. Ta CN. Minimizing the risk of endophthalmitis following intravitreal injections. *Retina* 2004;24:699-705.
2. Lad EM, Moshfeghi DM. Minimizing the risk of endophthalmitis following intravitreal injections. *Compr Ophthalmol Update* 2006;7:277-284.
3. Aiello LP, Brucker AJ, Chang S, Cunningham ET Jr, D'Amico DJ, Flynn HW Jr, et al. Evolving guidelines for intravitreal injections. *Retina* 2004;24 (5 Suppl):S3-19.
4. Engstrom RE Jr, Holland GN. Local therapy for cytomegalovirus retinopathy. *Am J Ophthalmol* 1995;120:376-385.
5. Heinemann MH. Long-term intravitreal ganciclovir therapy for cytomegalovirus retinopathy. *Arch Ophthalmol* 1989;107:1767-1772.
6. Nelson ML, Tennant MT, Sivalingam A, Regillo CD, Belmont JB, Martidis A. Infectious and presumed noninfectious endophthalmitis after intravitreal triamcinolone acetonide injection. *Retina* 2003;23:686-691.
7. Jager RD, Aiello LP, Patel SC, Cunningham ET Jr. Risks of intravitreal injection: a comprehensive review. *Retina* 2004;24:676-698.
8. Young S, Morlet N, Besen G, Wiley CA, Jones P, Gold J, et al. High-dose (2000-microgram) intravitreal ganciclovir in the treatment of cytomegalovirus retinitis. *Ophthalmology* 1998;105:1404-1410.
9. Baudouin C, Chassain C, Caujolle C, Gastaud P. Treatment of cytomegalovirus retinitis in AIDS patients using intravitreal injections of highly concentrated ganciclovir. *Ophthalmologica* 1996;210:329-335.
10. Schwartz SG, Flynn HW, Scott IU. Endophthalmitis after intravitreal injections. *Expert Opin Pharmacother* 2009;10:2119-2126.
11. Narang S, Gupta V, Gupta A, Dogra MR, Pandav SS, Das S. Role of prophylactic intravitreal antibiotics in open globe injuries. *Indian J Ophthalmol* 2003;51:39-44.
12. Lane SS, Osher RH, Masket S, Belani S. Evaluation of the safety of prophylactic intracameral moxifloxacin in cataract surgery. *J Cataract Refract Surg* 2008;34:1451-1459.
13. Essex RW, Yi Q, Charles PG, Allen PJ. Post-traumatic endophthalmitis. *Ophthalmology* 2004;111:2015-2022.
14. Kelkar A, Kelkar J, Amuaku W, Kelkar U, Shaikh A. How to prevent endophthalmitis in cataract surgeries? *Indian J Ophthalmol* 2008;56:403-407.
15. Essex RW, Lamoureux E, Charles PG, Allen P. Prophylaxis for posttraumatic endophthalmitis. *Arch Ophthalmol* 2008;126:742-743.
16. Meredith TA, Aguilar HE, Miller MJ, Gardner SK, Trabelsi A, Wilson LA. Comparative treatment of experimental *Staphylococcus epidermidis* endophthalmitis. *Arch Ophthalmol* 1990;108:857-860.
17. Soheilian M, Rafati N, Peyman GA. Prophylaxis of acute posttraumatic bacterial endophthalmitis with or without combined intraocular antibiotics: a prospective, double-masked randomized pilot study. *Int Ophthalmol* 2001;24:323-330.
18. Soheilian M, Rafati N, Mohebbi MR, Yazdani S, Habibabadi HF, Fegghi M, et al. Prophylaxis of acute posttraumatic bacterial endophthalmitis: a multicenter randomized clinical trial of intraocular antibiotic injection, report 2. *Arch Ophthalmol* 2007;125:460-465.
19. World Medicine Association. Revising the Declaration of Helsinki. *Bull Med Ethics*. 2000;158:9-11.
20. Boldt HC, Pulido JS, Blodi CF, Folk JC, Weingeist TA. Rural endophthalmitis. *Ophthalmology* 1989;96:1722-1726.
21. Pilli S, Kotsolis A, Spaide RF, Slakter J, Freund KB, Sorenson J, et al. Endophthalmitis associated with intravitreal anti-vascular endothelial growth factor therapy injections in an office setting. *Am J Ophthalmol* 2008;145:879-882.