



Contents lists available at SciVerse ScienceDirect

International Journal for Parasitology: Parasites and Wildlife

journal homepage: www.elsevier.com/locate/ijppaw

Observation of a novel *Babesia* spp. in Eastern Grey Kangaroos (*Macropus giganteus*) in Australia



Kaiser E. Dawood^{a,*}, Jess A.T. Morgan^b, Frances Busfield^c, Mukesh Srivastava^a, Taryn I. Fletcher^d,
Jacqueline Sambono^d, Louise A. Jackson^e, Bronwyn Venus^f, Adrian W. Philbey^a, Ala E. Lew-Tabor^b

^a Elizabeth Macarthur Agricultural Institute, New South Wales Department of Primary Industries, Woodbridge Road, Menangle, NSW 2568, Australia

^b Queensland Alliance for Agriculture & Food Innovation, The University of Queensland, 306 Carmody Road, St. Lucia, Qld 4072, Australia

^c Moruya Veterinary Hospital, 86-88 Queens St. Moruya, NSW 2537, Australia

^d Tick Fever Centre, Queensland Department of Agriculture, Fisheries & Forestry, 280 Grindle Road, Wacol, Qld 4076, Australia

^e Biosecurity Queensland, Queensland Department of Agriculture, Fisheries & Forestry, 39 Kessels Road, Coopers Plains, Qld 4108, Australia

^f Animal Science, Queensland Department of Agriculture, Fisheries & Forestry, 306 Carmody Road, St. Lucia, Qld 4072, Australia

ARTICLE INFO

Article history:

Received 27 September 2012

Revised 4 December 2012

Accepted 13 December 2012

Keywords:

Babesia

Kangaroo

Apicomplexan

Haematology

ABSTRACT

The roles and epidemiological features of tick-borne protozoans are not well elicited in wildlife. *Babesia* spp. are documented in many domestic animals, including cattle, horses, pigs, dogs and cats. Three cases affecting eastern grey kangaroos are described. The kangaroos exhibited neurological signs, depression and marked anaemia, and microscopic examination of blood smears revealed intraerythrocytic piroplasms. One to seven intraerythrocytic spherical, oval, pyriform and irregularly-shaped parasites consistent with *Babesia* spp. were seen in the blood smears and the percentage of infected erythrocytes was estimated to be approximately 7% in each case. Data suggest that the tick vector for this kangaroo *Babesia* sp. is a *Haemaphysalis* species. For Case 2, ultrastructural examination of the erythrocytes of the renal capillaries showed parasites resembling *Babesia* spp. and 18 of 33 erythrocytes were infected. DNA sequencing of the amplified 18S rDNA confirmed that the observed intraerythrocytic piroplasms belong to the genus *Babesia*. The phylogenetic position of this new kangaroo *Babesia* sp. (de novo *Babesia macropus*), as a sister species to the new Australian woylie *Babesia* sp., suggests a close affinity to the described Afro-Eurasian species *Babesia orientalis* and *Babesia occultans* suggesting perhaps a common ancestor for the *Babesia* in kangaroos.

© 2012 Australian Society for Parasitology Published by Elsevier Ltd. All rights reserved.

1. Introduction

Babesia species are arthropod-transmitted intraerythrocytic apicomplexan protozoans that infect a wide range of vertebrates (Ristic, 1988). *Babesia* infection can be subclinical or symptomatic, causing haemolytic anaemia, depression, diarrhoea, neurological signs and abortion. *Babesia* spp. are reported in many domestic animals, including cattle, horses, pigs, dogs and cats (Ristic, 1988).

Babesia bigemina and *Babesia bovis* in cattle are the most important pathogenic *Babesia* spp. in domestic animals (Ristic, 1988). *Babesia* spp. have also been detected in a wide range of wildlife,

including mongooses, hyenas, weasels, polecats, raccoons, elephants, foxes and deer. Nevertheless, most of the detected wildlife *Babesia* spp. produce no clinical signs (Ristic, 1988). The pathogenic importance of *Babesia* spp. in wild animals is still uncertain (Penzhorn and Chaparro, 1994).

Babesia sp. have been described in several species of marsupials, including *Babesia thylacis* in the southern brown bandicoot (*Isodon obesulus*) (Mackerras, 1959; Clark et al., 2004), the agile antechinus (*Antechinus agilis*), brown antechinus (*Antechinus stuartii*), Proserpine rock wallaby (*Petrogale persephone*) (O'Donoghue, 1997; O'Donoghue and Adlard, 2000; Clark et al., 2004) and woylies (*Woylieia penicillata ogilbyi*) (Paparini et al., 2012). *Babesia tachyglossi* and an undescribed *Babesia* sp. have also been reported in the short-beaked echidna (*Tachyglossus aculeatus*) (Backhouse and Bolliger, 1957, 1959; Mackerras, 1959; Bolliger and Backhouse, 1960).

The current study describes a novel *Babesia* sp. in eastern grey kangaroos [Family *Macropodidae*] in Australia, supported by DNA sequencing and electronmicroscopy.

* Corresponding author. Present address: School of Animal and Veterinary Sciences, Charles Sturt University, Wagga Wagga, NSW 2678, Australia. Postal address: P.O. Box: 895, Fairfield, NSW 1860, Australia. Tel.: +61 401930939.

E-mail address: kaiser.dawood@gmail.com (K.E. Dawood).

2. Material and methods

2.1. Cases

2.1.1. Case 1

In February 2006, an eastern grey kangaroo (gender unknown) tended by a carer from Fordsdale (92 km west of Brisbane, capital of the State of Queensland), South Queensland, was presented at a veterinary clinic with oedema in the cloacal region and a history of dehydrated, small faecal pellets. Blood smears and a sample of blood collected into EDTA were submitted to the Animal Disease Surveillance Laboratory, Toowoomba, Queensland for analysis. The blood smears were stained with Giemsa and examined microscopically. The kangaroo recovered after unspecified treatment. Two adult ticks were removed from the kangaroo's skin and identified by the carer, but not formally submitted to a reference laboratory. Specimens of ticks from kangaroos being cared for by the same carer were submitted to the Biosecurity Sciences Laboratory, Coopers Plains, Queensland for identification.

2.1.2. Case 2

In March 2011, a 14 month old male eastern grey kangaroo, weighing 7.9 kg, from a fenced property at Bingie (257 km south-southwest of Sydney, capital of the State of New South Wales) on the south coast of New South Wales (NSW) was first presented to the Moruya Veterinary Hospital, Moruya, southern NSW. The kangaroo had swollen eyes with an increase in intraocular pressure. Blepharitis, conjunctivitis, and increased scleral vascularity were also noted. No corneal ulceration was present and no foreign bodies or ticks were found in the eyes. The pupillary light reflex was reduced in both eyes but menace response was normal in both eyes. Ticks were collected from the kangaroo but were not submitted for identification. Treatment with latanoprost (Xalatan[®], Pfizer) and dexamethasone (Maxidex[®] 0.1%, Alcon) was initiated. The kangaroo was presented for a further examination one day later with acute-onset lethargy, inappetence and suspected blindness. The clinical examination revealed that the kangaroo was unable to stand; there was conjunctival and gingival haemorrhage with cutaneous ecchymoses on the groin and the inner thighs. The pupillary light reflex was normal in both eyes but menace response was absent. Respiration was laboured with an expiratory grunt. Shortly afterwards the kangaroo began to exhibit muscle tremor and seizure-like activity and it was then humanely euthanased. The carer was submitted to the State Veterinary Diagnostic Laboratory, Menangle, NSW, for necropsy and further investigations. Samples from the brain, spinal cord, eyes, heart, spleen, liver, kidney, and intestine were collected into 10% buffered formalin for histopathology. EDTA blood and serum samples were submitted to the Regional Laboratory Services, Benalla, Victoria for biochemical testing. Ultrastructural (electron) microscopy was undertaken from this case utilising blood and kidney.

2.1.3. Case 3

In July 2011, a 12 month old male eastern grey kangaroo, weighing 7 kg, from the same carer as for Case 2, was presented to Moruya Veterinary Hospital, Moruya, NSW. The kangaroo manifested lethargy, pale mucosal membranes, reduction of water and milk intake and swelling of the eyes. Ticks were not collected for identification. The kangaroo was treated with 0.17 ml Imidocarb dipropionate (Coopers[®], 120 mg/mL subcutaneous), and 0.7 ml enrofloxacin (Baytril[®], 100 mg/ml subcutaneous). A second dose of Imidocarb dipropionate was given 24 h later. Seizure-like activity and vocalisation was observed after a few hours. The pupillary light reflex was almost absent but menace response was positive. The kangaroo was humanely euthanased due to the signs of clinical

deterioration. EDTA blood and serum samples were submitted to the Regional Laboratory Services, Benalla, Victoria for biochemical testing. The EDTA blood samples were also submitted to the Veterinary Teaching Hospital, Sydney University, Camden, for haematological analysis. Sufficient material for DNA analysis was not available for Case 3.

Cases 2 and 3 were received by the carer in August 2010 and had recently been moved into a newly constructed pen of approximately 40 × 50 m. They were orphans and were bottle-fed with Wombaroo formula and Impact colostrum supplement.

2.2. Electron microscopy

A 1 cm³ portion of formalin-fixed kidney from Case 2 was recut into 1–2 mm pieces and washed in phosphate buffered saline (PBS) 3 times for 5 min each time. The buffer was drained and the tissue was fixed in freshly prepared Karnovsky's fixative for 6 h. The tissue was then washed in PBS 3 times for 5 min each and post-fixed in 1% buffered osmium tetroxide. The tissue was washed again in PBS and stained with 2% uranyl acetate for 30 min, then dehydrated in a graded series of different concentrations of ethanol and transferred through several changes of acetone. After incubation in 50:50 resin and acetone, the tissue was embedded in pure resin and polymerised at 70 °C for 10 h. Thin sections (80 nm) were placed on 300 mesh copper grids, stained with uranyl acetate and lead citrate, and examined using a Philips 208 transmission electron microscope.

2.3. DNA extraction, PCR and sequencing

DNA was extracted from blood samples collected from Cases 1 and 2, as well as lab strains of *B. bigemina*, *B. bovis* and *Theileria* sp. using a QIAamp DNA Mini Kit (Qiagen) following the manufacturer's instructions. Details of the species and strains used in this study are provided in Table 1.

PCR assays for major piroplasm surface protein (MPSP) p32 of *Theileria* spp., (Tanaka et al. 1993), the MPSP p32 for the *T. orientalis* types Ikeda, Chitose and Buffeli (Zakimi et al., 2006), and the amplification of the cytochrome b genes of *B. bovis* and *B. bigemina* (Buling et al., 2007) were performed as described previously using control positive DNA samples (see Table 1).

Partial nuclear ribosomal 18S DNA sequences were amplified between primers A 5'-AACCTGGTTGATCCTGCCAGT-3' and B 5'-TGATCTTCTGCAGGTTACCTAC-3' (Medlin et al., 1988) with some DNA templates also requiring internal primers Kangabab18SF 5'-TGTAATGGTTAATAGGAACGGT-3' and Kangabab18SR 5'-GACGGTATCTGATCGTCTTCCA-3' (designed by authors). Amplification reactions were carried out in 10 µl volumes containing 1 µM of each primer pair, combined with 10–100 ng of extracted DNA, 10× HotMaster Taq buffer (5 Prime, distributed by Quantum-Scientific Milton, Queensland, Australia, containing 25 mM magnesium), 1 mM dNTP, and 1 unit of HotMaster Taq DNA polymerase (5 Prime, distributed by Quantum-Scientific Milton, Queensland, Australia). Thermal cycling conditions consisted of an initial denaturation (95 °C for 3 min) followed by 30 cycles of 94 °C for 30 s, annealing at 53 °C for 30 s and extension at 72 °C for 1 min 30 s, with a final extension step of 72 °C for 7 min. Cycling was performed in a Mastercycler[®] pro (Eppendorf South Pacific, North Ryde, New South Wales, Australia). PCR products were viewed on a 1% agarose 1× TBE gel stained with GelRed (Biotium, USA). Prior to sequencing, PCR products were either desalted using Exosap-it[®] (USB Corporation distributed by GE Healthcare Bio-Sciences, Rydalmere NSW, Australia) and directly sequenced, or target bands were cut from an agarose gel and purified with a MinElute Gel Extraction Kit (Qiagen, cat # 28604, Doncaster, Victoria, Australia) then transformed into chemically competent One Shot[®] TOP10

Table 1
Parasite strains and isolates for DNA screening and testing in this study.

Species	Vertebrate host	Strain	Lab accession	Origin (Australian state)	Genbank accession (this study)
<i>Babesia bigemina</i>	Cattle	G – vaccine strain	Calf 7720	Queensland	JQ437264
<i>Babesia bigemina</i>	Cattle	Bond strain	S38	Queensland	JQ437261
<i>Babesia bovis</i>	Cattle	Dixie - vaccine strain	Calf 8284	Queensland	JQ437260
<i>Babesia bovis</i>	Cattle	D'Aguilar	H81	Queensland	JQ437262
<i>Theileria</i> sp.	Cattle	S134	J02	NSW	JQ437263
Unknown 1	Kangaroo	Case 1, clone 1	TVL 06-01974	Queensland	JQ437265
Unknown 2	Kangaroo	Case 1, clone 2	TVL 06-01974	Queensland	JQ437266
Unknown 3	Kangaroo	Case 2	M11-04231	NSW	JQ437267

cells using a TOPO® TA Cloning Kit (Invitrogen cat#K450001, Mulgrave, Victoria, Australia). Plasmid DNA was extracted from clones using a QIAprep Spin Miniprep Kit (Qiagen, cat # 27104, Doncaster, Victoria, Australia). Approximately 20 ng of PCR product or 200 ng of plasmid DNA was used in standard ABI Dye Terminator sequencing reactions using Big Dye Vers 3.1 technology (Applied Biosystems, California) and were run on an Applied Biosystems 3130xl Genetic Analyser (Griffith University DNA Sequencing Facility, School of Biomolecular and Biomedical Science, Griffith University, Qld, Australia). Forward and reverse sequences were edited and aligned using Sequencher (Vers 4.7 Gene Codes Corporation, Ann Arbor, MI, USA).

2.4. Phylogenetic analyses

Forty-one additional sequences (Table 2) were downloaded from the GenBank database (Benson et al. 2010) and were included in the phylogenetic analysis based on a nucleotide BLAST search of the kangaroo infecting *Babesia*-like sequence on NCBI (<http://www.ncbi.nlm.nih.gov/BLAST>). Strains of described *B. bovis* and *B. bigemina* were included in the analysis as well as at least one representative of all closely related *Babesia* species for which 18S sequences were available, including the recently described *Babesia* sp. isolated from a woylie (brush-tailed bettong) (Paparini et al., 2012).

Sequences were aligned using ClustalX (Vers 1.81, Thompson et al. 1997) then the alignment was truncated to the shortest sequence (1560 bp alignment). The alignment was manually edited prior to export in nexus format for phylogenetic analyses. Before generating the phylogenetic trees a series of likelihood ratio tests were completed using MrModeltest (Vers 2.3, Nylander 2004) to determine the best nucleotide substitution model to use for likelihood and distance analyses. The best model predicted using the Akaike Information Criterion (AIC) was a general time reversible model (GTR) with a proportion of invariant sites (I) and among site heterogeneity (G) (summarized as GTR + I + G) with the following command block for use in Paup* (Vers 4.0b10, Swofford 2002). BEGIN PAUP; Lset Base=(0.2378 0.2057 0.2614) Nst = 6 Rmat = (0.4315 0.8650 0.6404 0.7132 1.9820) Rates = gamma shape = 0.4865 Pinvar = 0.5983; END.

Phylogenetic trees were constructed using maximum parsimony (P), maximum likelihood (L) and distance matrix analyses (D) in PAUP* (Vers 4.0b10, Swofford 2002). Unweighted trees were found using heuristic searches with random sequence addition and tree-bisection-reconnection (TBR) branch swapping. For the parsimony, analysis gaps were treated as missing data. Other settings used were Mulpars in effect, Maxtrees set to 10000 and heuristic search repetitions set to 100 (P) or one (D and L). Support for nodes was assessed using bootstrap resampling (P 1000 replicates, D 1000 replicates, L 100 replicates) and Bayesian analysis (B 935,000 generations). Bayesian analyses, using posterior probabilities, were completed in MrBayes (Huelsenbeck and Ronquist, 2001). The GTR + I + G nucleotide substitution model was used

but with empirical base frequencies and invariant substitution rates built into the gamma distribution. Four chains were run for 1000,000 generations with the first 65,000 generations removed as burnin prior to constructing the consensus tree. Two representatives of the genus *Theileria* (*Theileria* spp. from Table 1 and *T. buffeli*, Genbank accession DQ104611 from Table 2) were included as outgroup taxa to root all trees.

3. Results

3.1. Case 1

The kangaroo had moderate to marked anaemia with a decrease in erythrocytes ($2.75 \times 10^{12}/L$, normal reference $5.86 \times 10^{12}/L$) and haemoglobin concentration (75 g/L, normal reference 160 g/L). *Babesia* were observed in the blood smear mostly as paired merozoites (Fig. 1). Ticks were collected and informally identified by the carer as *Haemaphysalis* species. Further ticks submitted from other kangaroos from the same carer were identified by the Biosecurity Sciences Laboratory as *Haemaphysalis* species.

3.2. Cases 2 and 3

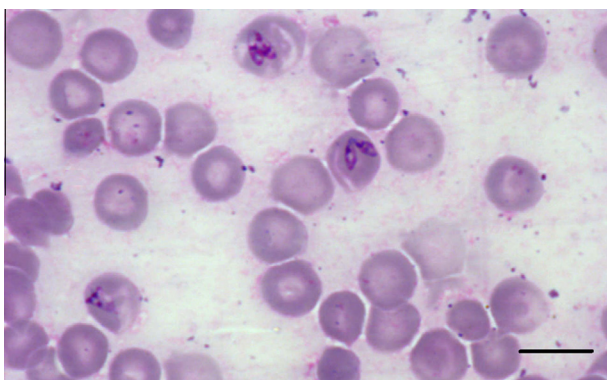
Examination of the blood smears by light microscopy showed up to seven intraerythrocytic spherical, oval, pyriform and irregular-shaped parasites consistent with *Babesia* spp. (Fig. 2) and with the organisms observed in Case 1. Estimation of the percentage of infected erythrocytes in Cases 2 and 3 was 7% and the size of the parasites ranged from 2 to 6 μm in diameter. Spherical or ring-shaped trophozoites (Fig. 2B and C) were common and were mostly present singly in erythrocytes. Pyriform-shaped merozoites, however, were the next most common form found singly, in pairs (Fig. 2A) or in clusters. Rarely, free pyriform-shaped trophozoites were also observed in pairs or clusters (Fig. 2F). The blood smears from all of the cases exhibited a marked decrease in erythrocyte density, marked anisocytosis and polychromasia. A moderate increase of spherocytes and reticulocytes was noticed. Most of the infected erythrocytes appeared markedly enlarged and hypochromatic.

The packed-cell volume (PCV) of Cases 2 and 3 were 30% and 17%, respectively (normal reference 47%). The haematology result of kangaroo 3 also revealed a marked decrease of erythrocytes ($2.44 \times 10^{12}/L$, normal reference $5.86 \times 10^{12}/L$), white blood cells ($2.97 \times 10^9/L$, normal reference $10.13 \times 10^9/L$), and haemoglobin (66 g/L, normal reference 160 g/L).

Histologically in Case 2, the liver showed mild to moderate degeneration of the periportal zone hepatocytes, with golden-brown granular deposits in Küpffer cells. Mild cholestasis was observed occasionally. Abundant siderophages were observed in the spleen. Haemorrhage was evident in the sclera of both eyes. Sections stained with Giemsa-eosin showed multiple dots and pyriform-like basophilic structures in the erythrocytes in the blood vessels, particularly the capillaries of the brain, kidneys and eyes.

Table 2Additional *Babesia* and *Theileria* sequences sourced from Genbank included in the phylogenetic analysis.

Genbank accession #	Description	Vertebrate Host	Origin	Refs.
X59604	<i>Babesia bigemina</i> gene A	Unknown	Mexico	Reddy et al. (1991)
X59605	<i>Babesia bigemina</i> gene B	Unknown	Mexico	Reddy et al., 1991
X59607	<i>Babesia bigemina</i> gene C	Unknown	Mexico	Reddy et al. (1991)
FJ426361	<i>Babesia bigemina</i> isolate BRC02	Cattle	Brazil	Criado-Fornelio et al. (2009a,b)
AY603402	<i>Babesia bigemina</i> isolate Kunming	Bovine	China	Buling et al. (2007)
DQ785311	<i>Babesia bigemina</i> isolate Spain-1	Cattle	Spain	Buling et al. (2007)
HQ840959	<i>Babesia bigemina</i> strain 493	Water buffalo	China	He et al., 2012
HQ840960	<i>Babesia bigemina</i> strain 563	Water buffalo	China	He et al. (2012)
AY150059	<i>Babesia bovis</i> Portugal	Cattle	Portugal	Criado-Fornelio et al. (2003)
AY309955	<i>Babesia caballi</i>	Feral horse	Spain	Criado-Fornelio et al. (2004)
Z15104	<i>Babesia caballi</i>	Horse	South Africa	Criado-Fornelio et al. (2004)
AY534883	<i>Babesia caballi</i> strain EB1	Equine	Spain	Nagore et al. (2004a)
L19079	<i>Babesia canis</i>	Unknown	Unknown	Allsopp et al. (1994)
AY072926	<i>Babesia canis canis</i>	Dog	Croatia	Cacciò et al. (2002)
HM590440	<i>Babesia canis vogeli</i>	Dog	China	Zhang and Li (2010), not published
AY726009	<i>Babesia capreoli</i> isolate BAB1220	Roe deer	France	Slemenda et al. (2004), not published
AY572456	<i>Babesia divergens</i>	Roe deer	Slovenia	Duh et al. (2004), not published
DQ184507	<i>Babesia gibsoni</i>	Dog	USA	James et al. (2005), not published
EU622907	<i>Babesia major</i> isolate France 1	Cattle	France	Criado-Fornelio et al. (2009b)
AY260180	<i>Babesia motasi</i>	Sheep	Netherlands	Schnittger et al., 2003
AY533147	<i>Babesia motasi</i>	Ovine	Spain	Nagore et al. (2004b)
EU376017	<i>Babesia occultans</i>	Sable antelope	South Africa	Oosthuizen et al., 2008
HQ331479	<i>Babesia occultans</i> isolate 68	Unknown	Tunisia	Ros-Garcia et al. (2011)
AY596279	<i>Babesia orientalis</i>	Water buffalo	China	Liu et al. (2005)
HQ840969	<i>Babesia orientalis</i> strain DaYe	Water buffalo	China	He et al. (2012)
AY603400	<i>Babesia ovata</i> isolate Zhangjiachuan	Bovine	China	Luo et al. (2005a)
U09834	<i>Babesia</i> sp.	Cattle	Unknown	Allsopp et al. (1994), direct submission
HQ437690	<i>Babesia</i> sp. Anglona/AA-2011	Wild pig	Anglona	Zobba et al. (2011)
GQ888709	<i>Babesia</i> sp. EU1 isolate Arnhem	Reindeer	Netherlands	Kik et al., 2011
DQ329138	<i>Babesia</i> sp. FP44	Florida panther	USA	Yabsley et al. (2006)
FJ213578	<i>Babesia</i> sp. giraffe 0105	Giraffe	South Africa	Oosthuizen et al. (2009)
FJ213580	<i>Babesia</i> sp. giraffe 229	Giraffe	South Africa	Oosthuizen et al., 2009
FJ213577	<i>Babesia</i> sp. giraffe 544	Giraffe	South Africa	Oosthuizen et al. (2009)
AY726556	<i>Babesia</i> sp. Kashi 1	Bovine	China	Luo et al. (2005b)
DQ159071	<i>Babesia</i> sp. Madang-2005	Ovine	China	Liu et al. (2007)
FJ213581	<i>Babesia</i> sp. roan 571	Roan antelope	South Africa	Oosthuizen et al. (2009)
EU376016	<i>Babesia</i> sp. sable antelope/2005	Sable antelope	Unknown	Oosthuizen et al. (2008)
AB251612	<i>Babesia</i> sp. SAP#131	Raccoon	Japan	Jinnai et al., 2009
DQ159073	<i>Babesia</i> sp. Xinjiang-2005	Ovine	China	Liu et al. (2007)
HQ730762	<i>Babesia</i> sp. ZL-2011	Sheep	China	Ma et al. (2010), not published
JQ682876	<i>Babesia</i> sp. Woylie	Woylie	Australia	Paparini et al. (2012)
DQ104611	<i>Theileria buffeli</i> China	Unknown	China	Liu et al. (2010)

**Fig. 1.** Photomicrograph of a blood smear from an Eastern Grey kangaroo stained with Giemsa and showing the presence of *Babesia* species merozoites. Bar = 10 μ m.

Biochemical results from Cases 2 revealed a marked increase in the level of urea (30.3 mmol/L, normal reference 8.6 nmol/L), the urea:creatinine ratio (0.36, normal reference not found), aspartate aminotransferase (AST, 417 U/L, normal reference 60 U/L), glutamate dehydrogenase (GLDH, 130 U/L, normal reference not found) and creatine kinase (2917 U/L, normal reference 747 U/L). There was a moderate increase in bilirubin (4.6 μ mol/L, normal reference 3 μ mol/L). There was a moderate decrease in protein (41.3 g/L, normal reference 60 g/L) and globulin (17.5 g/L, normal reference 23 g/L).

3.3. Ultrastructural examination

Ultrastructural examination was undertaken using samples from Case 2 and showed that the parasites had morphology consistent with *Babesia* spp. Cases 1 and 3 had insufficient samples and therefore were not examined ultrastructurally. In one kidney section, 18 of the total 33 erythrocytes counted were infected with *Babesia* parasites (5 μ m electron microscope magnification) – results not shown. The intraerythrocytic stage exhibited up to 3 morphologic types including elongated, round, and amoeboid-shaped *Babesia*. Trophozoites were the most common, which corresponded to what was seen by light microscopy examination. Frequently, erythrocytes contained up to 6 parasites of variable size. Trophozoites were generally surrounded by a single plasma membrane although many were doubled segmentally, with the segments separated by a clear space (Fig. 3). The nucleus was a single, round, moderately electron-dense, surrounded by multiple, prominent, irregular, double-membraned cisternae, and located at one end of the cell. No nucleolus was present. The cytoplasm contained endoplasmic reticulum, free ribosomes, mitochondria and vacuoles (Fig. 3). The endoplasmic reticulum was found very close to the nucleus. However, it was not always seen clearly in some of the developmental stages. Most trophozoites contained a large eccentric pseudoinclusion (invagination of the host cytoplasm), that was lighter in density and significantly larger than the nucleus (Fig. 3).

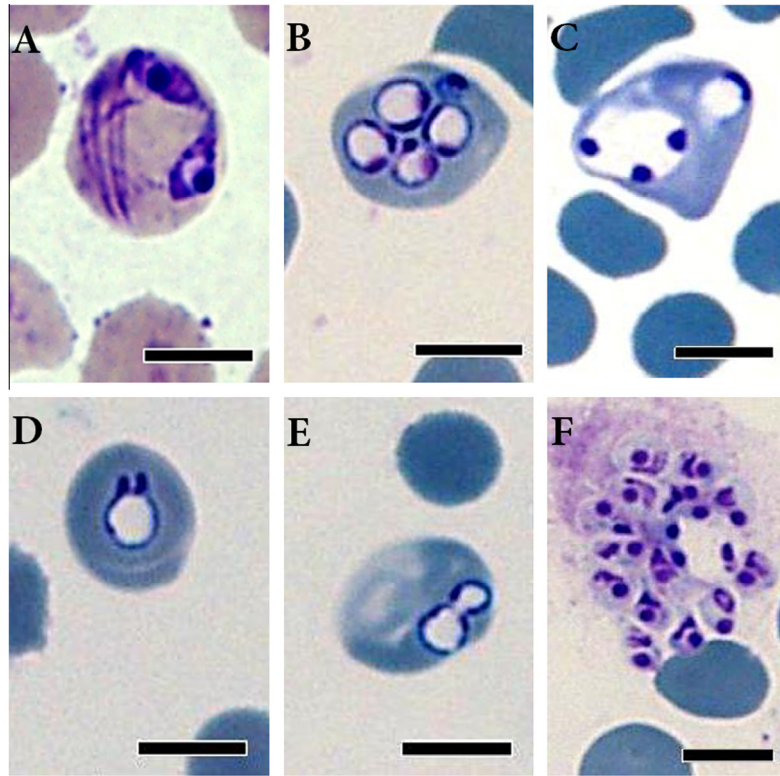


Fig. 2. Photomicrograph of blood smears stained with Diff-Quik (A) and Giemsa (B–F) from eastern grey kangaroos (Cases 2 and 3) showing diverse forms of *Babesia* including paired merozoites (2A), multiple ring-shaped trophozoites with a chromatin dot (2B), a large ring-shaped trophozoite with three chromatin dots (2C), ring-shaped trophozoite with a pair of buds in early dividing stage (2D), two dividing trophozoites with a cytoplasmic bridge (2E), and a clump of diverse forms of extraerythrocytic *Babesia* (3F). Bar = 10 μ m.

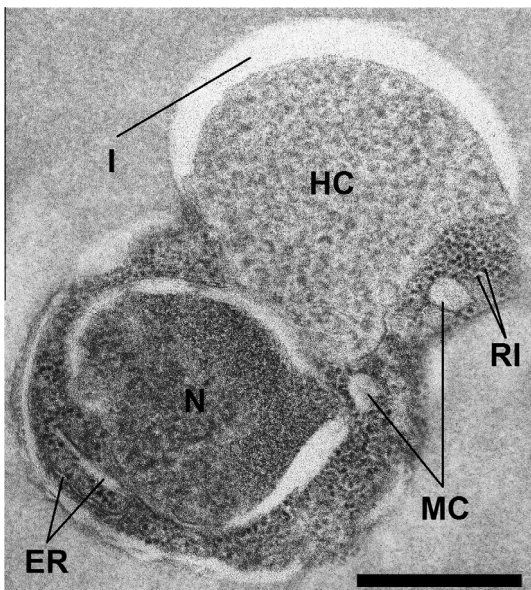


Fig. 3. Electron micrographs of *Babesia* spp. (Case 2) within an erythrocyte. Nucleus (N); host cytoplasm (HC); endoplasmic reticulum (ER); ribosome (RI); mitochondria (MC), and invagination (I). Bar = 0.5 μ m.

3.4. Molecular analysis and DNA sequencing

PCR assays for known piroplasms (*Theileria* spp.-MSP, *B. bovis*, and *B. bigemina*-cytochrome b) did not amplify visible products from the kangaroo samples (Cases 1 and 2) confirming that known *Babesia* species were not co-infecting the kangaroo hosts (results

not shown). A 1633 bp product of partial 18S rRNA was PCR amplified (from DNA prepared from Cases 1 and 2) and sequenced for the *Babesia*-like protozoan parasite found infecting the kangaroos. Two genetically distinct strains of the kangaroo *Babesia* were identified diverging by 0.2% (3 base changes). Both were present in Case 1, and one was present in Case 2. Samples for Case 3 were not available for DNA amplification.

The parsimony analysis of the 1560 bp alignment was based on 331 informative characters. Parsimony analysis found 96 optimal trees of length 1100 steps and consistency index 0.5455. Tree differences were largely due to taxa rearrangements at the tips. Distance analysis identified one optimal tree with minimum evolution score 0.91537 (Fig. 4). Maximum likelihood analysis retained a single tree with $-\ln$ likelihood score 7694.24818. Branch support from all analysis methods is indicated on the distance tree by an asterisk (Fig. 4).

The two strains of kangaroo *Babesia* sp. (Cases 1 and 2) consistently fall in a well supported clade with the woylie *Babesia* sp. recently characterised (Paparini et al., 2012). Lacking bootstrap support, but consistent with Paparini et al. (2012), all analyses grouped the kangaroo and woylie *Babesia* spp. within a clade containing *B. occultans* (ex antelope, South Africa), *B. orientalis* (ex water buffalo, China) and a number of unnamed *Babesia* sp. from sheep, giraffe, antelope and wild pig (Clade 1, Fig. 4). The phylogenetic position of *B. bovis* in Clade 1 is unclear. Distance and parsimony trees place *B. bovis* in a basal position (Fig. 4) while the maximum likelihood tree suggests a more derived position.

All analyses identified a well-supported clade containing *B. bigemina*, *B. ovata*, *B. motasi* and *B. major* (Clade 2, Fig. 4). Clades numbered 3, 4 and 5 form a single clade in the parsimony analysis, two clades using distance analysis (shown) and three clades based on likelihood analysis.

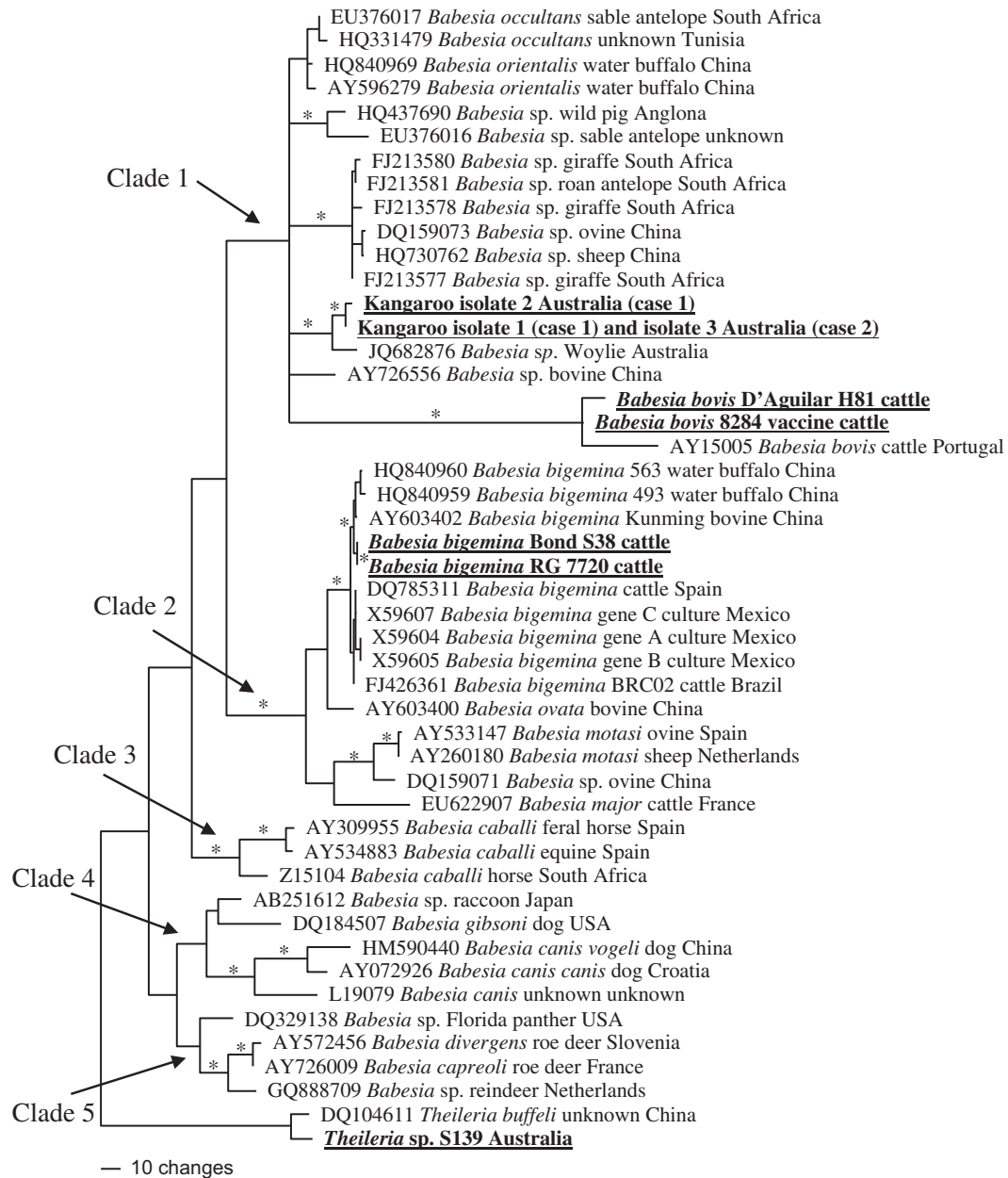


Fig. 4. Minimum evolution phylogenetic tree based on a 1560 bp 18S rRNA alignment for representatives of the genus *Babesia* including the new kangaroo-infecting species (in bold and underlined) originating from Cases 1 and 2. Also underlined and in bold are other species sequenced as part of this study. Branch support is shown with a * where all tree building methods (parsimony, distance and likelihood) had at least 70% bootstrap and Bayesian support.

4. Discussion

In contrast to livestock, diseases in wild animals are not examined. For example, most sick or dead kangaroos are not investigated for haemoprotozoa thoroughly due to difficulty in collecting samples, poor sample collection or lack of appropriate samples. The eastern grey kangaroos in this study had clinical signs of acute anaemia. The laboratory findings in association with the clinical signs suggested that the kangaroos had contracted babesiosis. Abundant organisms resembling *Babesia* spp. were detected on examination of blood smears. Sequencing of the 18S rDNA from 2 of the 3 cases indicated that the kangaroos were infected with a novel *Babesia* sp. distinct from other recognised species. Most *Babesia* sp. species are considered to be host specific, but there is evidence of cross-species transmission, including zoonotic transmission (Ristic, 1988; Gray et al., 2010). This is the first study

describing a novel *Babesia* species in kangaroo and the authors suggest nominating the observed species as *Babesia macropus*, as a potential sister species to the *Babesia* isolated from woylies (Paparini et al., 2012).

Subclinical infection with *Babesia* spp. is relatively common in wild ungulates. Clinical babesiosis in the sable antelope (*Hippotragus niger*), Grevy's zebra (*Equus grevyi*) and black rhinoceros (*Diceros bicornis*) appear to be triggered by the stress of capture, restraint and translocation (Penzhorn, 2006). Among marsupials, clinical babesiosis in the male antechinus is associated with physiological stress in the post-mating period (Barker et al., 1978; Arundel, 1981). The eastern grey kangaroos in this study had a history of translocation (for Cases 2 and 3), confinement in a fenced yard and supplementary feeding. It is possible that the stress of handling, transportation and captivity contributed to the development of disease in the kangaroos (Dennig, 1966; McInnes et al., 1992).

Alternatively, kangaroos hand-reared by carers would lack the maternal antibodies obtained passively from their doe's milk to protect them against this *Babesia* sp. Furthermore hand-reared kangaroos would have less exposure to naturally occurring parasites than wild kangaroos and thus be more susceptible to infection.

It has been suggested that there is little correlation between the percentage of infected erythrocytes with *Babesia* and the severity of clinical signs (Ristic, 1988). For example, 72–96% of erythrocytes were infected with *B. cynicti* in yellow mongooses (*Cynictis penicillata*) without the animals showing evidence of clinical disease (Penzhorn and Chaparro, 1994). However, the pathology of the disease will also influence the parasitemia. In bovine babesiosis, *B. bigemina* will develop a high parasitemia causing severe haemolytic anaemia and *B. bovis* can result in a low parasitemia with disseminated intravascular coagulation leading to severe cerebral babesiosis (Bock et al., 2004; Allred, 2007; Hutchings et al., 2007). This is caused by the sequestering of *B. bovis* infected erythrocytes in the capillaries of organs not usually associated with *B. bigemina* pathology. In the blood smears from the kangaroos with severe clinical signs, it was estimated that 7% of the erythrocytes were infected. Importantly, examination of fixed tissue stained with Giemsa-eosin was valuable for the diagnosis of haemoprotezoans in this study. Kidney, brain and eye were the most useful organs for microscopic diagnosis demonstrating a similar pathology to *B. bovis* infections.

Interestingly, the *Babesia* in the current cases appeared larger than those recorded in previous studies in other animal species. Most of erythrocytes infected with one or more *Babesia* organisms were altered in shape and colour. This is inconsistent with Clark et al. (2004) who stated that one to two *B. thylacis* in an infected erythrocyte caused no such changes to erythrocytes in an unspecified Australian mammal. In our study, the transmission microscope images revealed some structures that are similar to those described for other *Babesia* spp., such as *B. bovis* and *B. microti* (Rudzinska, 1976; Todorovic et al., 1981). The number of infected erythrocytes in the capillaries in the kidney was much higher than that examined by the blood smears. This may be ascribed to the high magnification of the electron microscope which identifies the remains of autolysed *Babesia* and erythrocytes. In *B. bovis*, no food vacuole or host cytoplasm was found (Todorovic et al., 1981). However, in the *Babesia* sp. described here, a large portion or fragment of the host cytoplasm was found in the majority of the merozoites. The authors suggest that host cytoplasm invaginated into the protozoan and that may have participated significantly in the development of anaemia in the kangaroo by increasing the surface area of the parasites that in direct contact with the host cytoplasm, thereby increasing nutrition intake (Rudzinska, 1976). However, the exact role, importance and fate of the invaginated host cytoplasm are not fully elucidated.

The 18S rRNA phylogeny confirms that the *Babesia*-like blood infection found in eastern grey kangaroo is a protozoan parasite belonging to the genus *Babesia*. Although the kangaroo were found in close proximity to domestic cattle, the infection was neither *B. bovis* nor *B. bigemina* but represents a new species of *Babesia* and it has a close affinity to the recently characterised *Babesia* sp. isolated from woylies (brush-tailed bettongs) (Paparini et al., 2012). Woylies [Family *Potoroidae*] are small marsupials (commonly called 'rat kangaroos') whose habitat (mostly western and southern Australia) does not overlap with the habitat of the eastern grey kangaroo [Family *Macropodidae*] in eastern Australia. Two genetically distinct strains of the kangaroo *Babesia* have been identified diverging by 0.2% well within the range of strain divergence found for other species in the genus (strain divergence of up to 5% is found within *B. bovis*, *B. canis* and *B. caballi*). The genetic divergence observed between the kangaroo *Babesia* sp. and the woylie *Babesia*

sp. (20 nucleotide differences, 1.5%) is sufficient to characterise these as distinct but sister species (Schnittger et al., 2003). A similar level of divergence separates *B. occultans* from *B. orientalis* (1.05%) and *B. bigemina* from *B. ovata* (1.6%). Geographic isolation, vector specificity and host specificity are the likely genetic isolating mechanisms maintaining the species.

The phylogenetic position of the marsupial *Babesia* sp. within the genus indicates a close affinity to described Afro–Eurasian species *B. orientalis* and *B. occultans* and suggests an ancestor in common with these Australian marsupial parasites. A phylogeny based on a more variable genetic marker will provide more power to resolve where this marsupial *Babesia* spp. falls with respect to their sister species and may help to unravel the evolutionary origins of this group.

To date, no tick species has been confirmed as the vector of Australian wildlife piroplasms. Bandicoots are known to be carriers of the native Australian *Ixodes holocyclus* ticks (causing tick paralysis of companion animals) which is not known to carry piroplasms but is present in the regions associated with the kangaroo studies here. *Amblyomma triguttatum triguttatum* ticks are described to be present in several marsupial and rodent populations but have also not been implicated as a vector of piroplasms (Waudby et al., 2007). Several species of ticks have been found on a population of kangaroos on an island off the southern coast of Australia including *Bothriocroton concolor*, *Ixodes hirsti* and *Haemaphysalis bancrofti* (Oorebeek and Rismiller, 2007). Our preliminary observations that *Haemaphysalis* spp. ticks were present in the captive area suggest that they may be the vector of the *Babesia* sp. to eastern grey kangaroos. However, further studies need to be undertaken to confirm this supposition.

In conclusion, to the authors' knowledge, this is a first study describes a novel *Babesia* in kangaroos. The authors suggest nominating the observed *Babesia* as *B. macropus*. Eastern grey kangaroo may develop fatal babesiosis characterised by anaemia, lethargy and neurological signs following events such as capture, transportation and relocation. Examination of blood smears from anaemic kangaroos is highly recommended. Additionally, administration of prophylactic doses of anti-protozoan medication before and after translocation could potentially be a preventative measure against clinical *Babesia* infections.

Acknowledgements

The authors would like to thank Chris Butt (senior lecturer in English for Health Profession, Sydney) for editing the manuscript. The authors wish also to thank Leah Simmon and Cassandra Buchanan for preparing the histology and special stains, Graeme Eamens (The State Veterinary Diagnostic Laboratory, NSW) for performing the *Theileria orientalis* PCR technique, Peter Rolls and Bert de Vos (Biosecurity Queensland, Qld Department of Agriculture, Fisheries & Forestry) for supporting this study logistically, Grant Campbell (Biosecurity Queensland) for notifying us of Case 1 and Neil Horadagoda (Sydney University, Camden, NSW) for conducting the haematology and biochemistry.

References

- Allred, D.R., 2007. Dynamics of anemia progression and recovery in *Babesia bigemina* infection is unrelated to initiating parasite burden. *Vet. Parasitol.* 15, 170–174.
- Allsopp, M.T., Cavalier-Smith, T., De Waal, D.T., Allsopp, B.A., 1994. Phylogeny and evolution of the piroplasms. *Parasitology* 108, 147–152.
- Arundel, J., 1981. Wildlife diseases of the Pacific basin – Australia. *Wildlife diseases of the Pacific basin and other Countries*. In: Fowler, M.E. (Ed.), *Proceedings of the 4th International Conference of the Wildlife Disease Association*. Australia, Sydney, pp. 18–22.
- Backhouse, T., Bolliger, A., 1957. A piroplasm of the echidna (*Tachyglossus aculeatus*). *Aust. J. Sci.* 19, 24–25.

- Backhouse, T.C., Bolliger, A., 1959. *Babesia tachyglossi* n. sp. from the echidna *Tachyglossus aculeatus*. J. Protozool. 6, 320–322.
- Barker, I., Beveridge, I., Bradley, A., Lee, A., 1978. Observations on spontaneous stress-related mortality among males of the dasyurid marsupial *Antechinus stuartii* Macleay. Aust. J. Zool. 26, 435–447.
- Benson, D.A., Karsch-Mizrachi, I., Lipman, D.J., Ostell, J., Sayers, E.W., 2010. GenBank. Nucleic Acids Res. 38, D46–D51.
- Bock, R., Jackson, L., de Vos, A., Jorgensen, W., 2004. Babesiosis of cattle. Parasitology 29, 247–269.
- Bolliger, A., Backhouse, T., 1960. Blood studies on the echidna *Tachyglossus aculeatus*. Proceedings of the Zoological Society of London 135, 91–97.
- Buling, A., Criado-Fornelio, A., Asenzo, G., Benitez, D., Barba-Carretero, J.C., Florin-Christensen, M., 2007. A quantitative PCR assay for the detection and quantification of *Babesia bovis* and *B. bigemina*. Vet. Parasitol. 147, 16–25.
- Cacciò, S.M., Antunovic, B., Moretti, A., Mangili, V., Marinculic, A., Baric, R.R., Slemenda, S.B., Pieniazek, N.J., 2002. Molecular characterisation of *Babesia canis canis* and *Babesia canis vogeli* from naturally infected European dogs. Vet. Parasitol. 106, 285–292.
- Clark, P., Adlard, R.D., Spratt, D.M., 2004. Haemoparasites of Australian mammals. In: Clark, P. (Ed.), Haematology of Australian Mammals. CSIRO Publishing, Collingwood, Australia, pp. 147–162.
- Criado-Fornelio, A., Martinez-Marcos, A., Buling-Sarana, A., Barba-Carretero, J.C., 2003. Molecular studies on *Babesia*, *Theileria* and Hepatozoon in southern Europe. Part I. Epizootiological aspects. Vet. Parasitol. 113, 189–201.
- Criado-Fornelio, A., Gonzalez-del-Rio, M.A., Buling-Sarana, A., Barba-Carretero, J.C., 2004. The “expanding universe” of piroplasmids. Vet. Parasitol. 119, 337–345.
- Criado-Fornelio, A., Buling, A., Asenzo, G., Benitez, D., Florin-Christensen, M., Gonzalez-Oliva, A., Henriques, G., Silva, M., Alongi, A., Agnone, A., Torina, A., Madruga, C.R., 2009a. Development of fluorogenic probe-based PCR assays for the detection and quantification of bovine piroplasmids. Vet. Parasitol. 162, 200–206.
- Criado-Fornelio, A., Buling, A., Pingret, J.L., Etievant, M., Boucraut-Baralon, C., Alongi, A., Agnone, A., Torina, A., 2009b. Hemoprotozoa of domestic animals in France. prevalence and molecular characterization. Vet. Parasitol. 159, 73–76.
- Dennig, H., 1966. The isolation of *Babesia* species from wild animals. Proceedings of the First International Congress. Parasitology, 262–263.
- Gray, J., Zintl, A., Hildebrandt, A., Hunfeldt, K.P., Weisse, L., 2010. Zoonotic babesiosis: overview of the disease and novel aspects of pathogen identity. Ticks Tick Borne Dis. 1, 3–10.
- He, L., Feng, H.H., Zhang, W.J., Zhang, Q.L., Fang, R., Wang, L., Tu, X., Zhou, Y.Q., Zhao, J.L., Oosthuizen, M.C., 2012. Occurrence of *Theileria* and *Babesia* species in water buffalo (*Bubalus bubalis*, Linnaeus, 1758) in the Hubei province, South China. Vet. Parasitol. 186, 490–496.
- Huelsenbeck, J.P., Ronquist, F.T., 2001. MRBAYES: Bayesian inference of phylogenetic trees. Bioinformatics 17, 754–755.
- Hutchings, C.L., Li, A., Fernandez, K.M., Fletcher, T., Jackson, L.A., Molloy, J.B., Jorgensen, W.K., Lim, C.T., Cooke, B.M., 2007. New insights into the altered adhesive and mechanical properties of red blood cells parasitized by *Babesia bovis*. Mol. Microbiol. 65, 1092–1105.
- Jinnai, M., Kawabuchi-Kurata, T., Tsuji, M., Nakajima, R., Fujisawa, K., Nagata, S., Koide, H., Matoba, Y., Asakawa, M., Takahashi, K., Ishihara, C., 2009. Molecular evidence for the presence of new *Babesia* species in feral raccoons (*Procyon lotor*) in Hokkaido, Japan. Vet. Parasitol. 162, 241–247.
- Kik, M., Nijhof, A.M., Balk, J.A., Jongejan, F., 2011. *Babesia* sp. EU1 infection in a forest reindeer. The Netherlands Emerg. Infect. Dis. 17, 936–938.
- Liu, A.H., Yin, H., Guan, G.Q., Schnitger, L., Liu, Z.J., Ma, M.L., Dang, Z.S., Liu, J.L., Ren, Q.Y., Bai, Q., Ahmed, J.S., Luo, J.X., 2007. At least two genetically distinct large *Babesia* species infective to sheep and goats in China. Vet. Parasitol. 147, 246–251.
- Liu, Q., Zhao, J.L., Zhou, Y.Q., Liu, E.Y., Yao, B.A., Fu, Y., 2005. Study on some molecular characterization of *Babesia orientalis*. Vet. Parasitol. 130, 191–198.
- Liu, Q., Zhou, Y.Q., He, G.S., Oosthuizen, M.C., Zhou, D.N., Zhao, J.L., 2010. Molecular phylogenetic studies on *Theileria* spp. isolates (China) based on small subunit ribosomal RNA gene sequences. Trop. Anim. Health. Prod. 42, 109–114.
- Luo, J., Yin, H., Guan, G., Yang, D., Liu, A., Ma, M., Liu, Z., Dang, Z., Liu, G., Bai, Q., Lu, W., Chen, P., 2005a. A comparison of small-subunit ribosomal RNA gene sequences of bovine *Babesia* species transmitted by *Haemaphysalis* spp. in China. Parasitol. Res. 95, 145–149.
- Luo, J., Yin, H., Liu, Z., Yang, D., Guan, G., Liu, A., Ma, M., Dang, S., Lu, B., Sun, C., Bai, Q., Lu, W., Chen, P., 2005b. Molecular phylogenetic studies on an unnamed bovine *Babesia* sp. based on small subunit ribosomal RNA gene sequences. Vet. Parasitol. 133, 1–6.
- Mackerras, M., 1959. The haematozoa of Australian mammals. Aust. J. Zool. 7, 105–135.
- McInnes, E., Stewart, C., Penzhorn, B., Meltzer, D., 1992. An outbreak of babesiosis in imported sable antelope (*Hippotragus niger*). J. S. Afr. Vet. Assoc. 62, 30–32.
- Medlin, L., Elwood, H.J., Stickel, S., Sogin, M.L., 1988. The characterization of enzymatically amplified eukaryotic 16S-like rRNA-coding regions. Gene 7, 491–499.
- Nagore, D., Garcia-Sanmartin, J., Garcia-Perez, A.L., Juste, R.A., Hurtado, A., 2004a. Detection and identification of equine *Theileria* and *Babesia* species by reverse line blotting: epidemiological survey and phylogenetic analysis. Vet. Parasitol. 123, 41–54.
- Nagore, D., Garcia-Sanmartin, J., Garcia-Perez, A.L., Juste, R.A., Hurtado, A., 2004b. Identification, genetic diversity and prevalence of *Theileria* and *Babesia* species in a sheep population from Northern Spain. Int. J. Parasitol. 34, 1059–1067.
- Nylander, J.A.A., 2004. MrModeltest 2.3. Program distributed by the author Evolutionary Biology Centre, Uppsala University.
- O’Donoghue, P., 1997. Protozoan parasites of wildlife in south-east Queensland. Proceedings of the Australian Association of Veterinary Conservation Biologists Conference, Brisbane, Queensland, Australia, 119–135.
- O’Donoghue, P., Adlard, R., 2000. Catalogue of protozoan parasites recorded in Australia. Memoirs of the Queensland Museum 45, 1–163.
- Oorebeek, M., Rismiller, P., 2007. *Bothriocroton concolor* (Acari: Ixodidae) on the Kangaroo Island kangaroo: a new host-parasite relationship. J. Med. Entomol. 44, 901–902.
- Oosthuizen, M.C., Zweygarth, E., Collins, N.E., Troskie, M., Penzhorn, B.L., 2008. Identification of a novel *Babesia* sp. from a sable antelope (*Hippotragus niger* Harris, 1838). J. Clin. Microbiol. 46, 2247–2251.
- Oosthuizen, M.C., Allsopp, B.A., Troskie, M., Collins, N.E., Penzhorn, B.L., 2009. Identification of novel *Babesia* and *Theileria* species in South African giraffe (*Giraffa camelopardalis*, Linnaeus, 1758) and roan antelope (*Hippotragus equinus*, Desmarest 1804). Vet. Parasitol. 163, 39–46.
- Paparini, A., Ryan, U.M., Warren, K., McInnes, L.M., de Tores, P., Irwin, P.J., 2012. Identification of novel *Babesia* and *Theileria* genotypes in the endangered marsupials, the woylie (*Bettongia penicillata ogilbyi*) and boodie (*Bettongia lesueur*). Exp. Parasitol. 131, 25–30.
- Penzhorn, B., Chaparro, F., 1994. Prevalence of *Babesia cynicti* infection in three populations of yellow mongooses (*Cynictis penicillata*) in the Transvaal, South Africa. J. Wildl. Dis. 30, 557–559.
- Penzhorn, B., 2006. Babesiosis of wild carnivores and ungulates. Vet. Parasitol. 138, 11–21.
- Reddy, G.R., Chakrabarti, D., Yowell, C.A., Dame, J.B., 1991. Sequence microheterogeneity of the three small subunit ribosomal RNA genes of *Babesia bigemina*: expression in erythrocyte culture. Nucleic Acids Res. 19, 3641–3645.
- Ristic, M., 1988. Babesiosis of Domestic Animals and Man. CRC Press, Boca Raton, Florida, USA, 255.
- Ros-Garcia, A., M’Ghirbi, Y., Bouattour, A., Hurtado, A., 2011. First detection of *Babesia occultans* in *Hyalomma* ticks from Tunisia. Parasitology 138, 578–582.
- Rudzinski, M.A., 1976. Ultrastructure of intraerythrocytic *Babesia microti* with emphasis on the feeding mechanism. J. Eukaryot. Microbiol. 23, 224–233.
- Schnitger, L., Yin, H., Gubbels, M.J., Beyer, D., Niemann, S., Jongejan, F., Ahmed, J.S., 2003. Phylogeny of sheep and goat *Theileria* and *Babesia* parasites. Parasitol. Res. 91, 398–406.
- Swofford, D.L., 2002. PAUP* phylogenetic analysis using parsimony (* and other methods). Sinauer Associates, Sunderland, Massachusetts.
- Tanaka, M., Onoe, S., Matsuba, T., Katayama, S., Yamanaka, M., Yonemich, H., Hiramatsu, K., Baek, B.K., Sugimoto, C., Onuma, M., 1993. Detection of *Theileria* sergenti infection in cattle by polymerase chain reaction amplification of parasite-specific DNA. J. Clin. Microbiol. 31, 2565–2569.
- Thompson, J.D., Gibson, T.J., Plewniak, F., Jeanmougin, F., Higgins, D.G., 1997. The CLUSTAL_X windows interface. flexible strategies for multiple sequence alignment aided by quality analysis tools. Nucleic Acids Res. 25, 4876–4882.
- Todorovic, R., Wagner, G., Kopf, M., 1981. Ultrastructure of *Babesia bovis* (BABES, 1888). Vet. Parasitol. 8, 277–290.
- Waudby, H.P., Petit, S., Dixon, B., Andrews, R.H., 2007. Hosts of the exotic ornate kangaroo tick, *Amblyomma triguttatum* triguttatum Koch, on southern Yorke Peninsula, South Australia. Parasitol. Res. 101, 1323–1330.
- Yabsley, M.J., Murphy, S.M., Cunningham, M.W., 2006. Molecular detection and characterization of *Cytauxzoon felis* and a *Babesia* species in cougars from Florida. J. Wildl. Dis. 42, 366–374.
- Zakimi, S., Kim, J.Y., Oshiro, M., Hayashida, K., Fujisaki, K., Sugimoto, C., 2006. Genetic diversity of benign *Theileria* parasites of cattle in the Okinawa prefecture. J. Vet. Med. Sci. 68, 1335–1338.
- Zobba, R., Parpaglia, M.L., Spezzigu, A., Pittau, M., Alberti, A., 2011. First molecular identification and phylogeny of a *Babesia* sp. from a symptomatic sow (*Sus scrofa* Linnaeus 1758). J. Clin. Microbiol. 49, 2321–2324.