

Available online at www.sciencedirect.com

SciVerse ScienceDirect

journal homepage: www.elsevier.com/locate/mjafi

Case report

Livedoid vasculopathy managed with hyperbaric oxygen therapy

Surg Lt Cdr Sourabh Bhutani^{a,*}, Surg Lt Cdr Rohit Verma^b,
Surg Capt George Verghese^c

^a Graded Specialist Marine Medicine, INS Shankul, C/o Fleet Mail Office, Mumbai 400001, India

^b Graded Specialist Marine Medicine & PMO, Diving School, Naval Base, Kochi 682004, India

^c Former Senior Advisor Marine Medicine, 4A Pragati's Royale, Facors Layout, Waltair Uplands, Vishakhapatnam 530003, Andhra Pradesh, India

ARTICLE INFO

Article history:

Received 6 July 2011

Accepted 15 January 2012

Available online 17 July 2012

Keywords:

Hyperbaric oxygenation

Livedoid vasculopathy

Atrophie blanche

ABSTRACT

Livedoid vasculopathy is an uncommon condition resulting in painful lower extremity ulceration and scarring. This condition presents as purpuric macules and papules that progress to painful, irregular ulcers of the lower legs and dorsal feet. These ulcerations are often recurrent and chronic with spontaneous remissions and exacerbations that may be seasonal.

The first case, a 22-year-old female presented with three-year history of recurrent multiple non-healing ulcers involving feet and ankles. The ulcers were associated with severe debilitating pain and paraesthesia, as a result of which she was unable to walk without support. Patient was administered HBOT at pressure of 2.5ATA for 1 h daily, six days a week. After ten sittings of HBOT, patient reported a drastic reduction in the pain along with reduction in the dose of analgesic by half and a definite improvement in her walking. The second case was a 49-year-old male who also had history of recurrent ulceration on the dorsum of feet and ankles associated with severe pain. With HBOT, the patient felt an improvement in pain and ambulation by the 8th sitting and complete relief from pain by the 17th sitting.

HBOT is a recognized modality of treatment of various problem wounds and non-healing ulcers due to various etiologies. The above two cases show that it can be a useful treatment modality for livedoid vasculopathy where other treatment modalities have failed and therefore could be given to a larger number of patients in hospitals where it is available.

© 2012, Armed Forces Medical Services (AFMS). All rights reserved.

* Corresponding author. Tel.: +91 9833274227.

E-mail address: bhutani.sourabh@gmail.com (S. Bhutani).

0377-1237/\$ – see front matter © 2012, Armed Forces Medical Services (AFMS). All rights reserved.

doi:10.1016/j.mjafi.2012.01.002

Introduction

Livedoid vasculopathy (or atrophie blanche, as it was previously known) is an uncommon condition resulting in painful lower extremity ulceration and scarring. Women are affected more often than men, with a ratio of 4:1 with peak incidence from 30 to 60 years. This condition presents as purpuric macules and papules that progress to painful, irregular ulcers of the lower legs and dorsal feet. These ulcerations are often recurrent and chronic with spontaneous remissions and exacerbations that may be seasonal. They often progress to scarring with firm, ivory-white stellate plaques. The condition is believed to result from coagulation and fibrinolytic disorders causing occlusion of dermal vessels. Rarely, it may be seen in association with systemic lupus erythematosus, scleroderma, and arteriosclerosis. Histopathology examination demonstrates a vasculopathy with endothelial proliferation, and dermal vessel occlusion with fibrinoid material or erythrocytes.^{1,2}

Treatment of livedoid vasculopathy is challenging, as no single form of therapy has been consistently effective in ameliorating the disease. Modalities are often aimed at anti-platelet, anti-coagulant and fibrinolytic effects. Therapies with demonstrated benefit include aspirin, coumadin, dipyridamole, low molecular weight heparin, pentoxifylline, enoxaparin, nifedipine, and tissue plasminogen activator.^{1,2} In addition, hyperbaric oxygen therapy (HBOT) has also been used for the treatment.²⁻⁴

Case reports

The first case, a 22-year-old female presented with a three-year-old history of recurrent multiple non-healing ulcers involving feet and ankles (Fig. 1). The ulcers were associated with severe debilitating pain and paraesthesia, as a result of which she was unable to walk without support. Patient did not give any history of any other medical illness, or any systemic complaints. The ulcers were discrete, irregular in shape, erythematous, and surrounded by areas of inflammation.

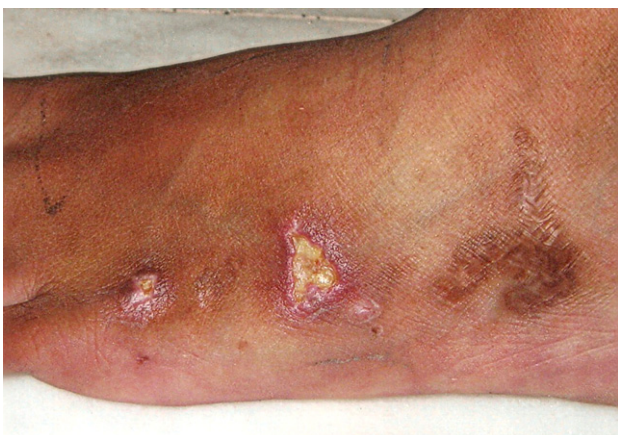

Fig. 1 – Ulcers on the left foot of the first patient before HBOT. Old scar from healed ulcers can also be seen.

Base of the ulcers was filled with necrotic material, and palpation revealed extreme tenderness and purulent discharge. Examination also revealed evidence of previous ulceration in the form of multiple hyperpigmented scars on the feet and ankles. All haematological and biochemical parameters were essentially normal. Protein C, protein S, anti-cardiolipin antibody, lupus anti-coagulant, and rheumatoid factor were also within normal limits. Biopsy revealed deep perivascular lymphocytic infiltration, with fibrin deposition in the walls of venules, and thrombi in the lumen of venules in the upper dermis. Patient was being managed with pentoxifylline with methyl prednisolone, and aspirin. She was in addition taking Tab. Ibuprofen 400 mg three times a day to keep the pain under control.

Patient was administered HBOT in a Multiplace chamber at pressure of 2.5ATA for 1 h daily, six days a week. At the end of ten sittings of HBOT, patient reported a drastic reduction in the pain along with reduction in the dose of analgesic by half and a definite improvement in her walking. Ulcers in the feet and ankles showed signs of healing in the form of appearance of granulation tissue in the base, shrinking margins, reduced inflammation and reduced tenderness (Fig. 2). By the end of 15 sittings, the ulcers had completely healed and by the 18th sitting, the patient could walk comfortably without any analgesic. Treatment was terminated at 25 sittings when ulcers had healed completely. Patient was followed till three months during which no recurrence of ulcers was noted.

The second case was that of a 49-year-old male who also had history of recurrent ulceration on the dorsum of feet and ankles associated with severe pain. He had had these ulcers since the past 8 years during which he had been given pentoxifylline, danazol, low molecular weight heparin, methyl prednisolone, with variable relief.

This patient also was given HBOT in the Multiplace chamber at 2.5ATA pressure for 1 h daily, six days a week. Patient started feeling an improvement in pain and improved ambulation by the 8th sitting and complete relief from pain was obtained by the 17th sitting. Ulcers healed by the 28th sitting and HBOT was stopped after 30 sittings. A follow up at six months did not reveal any recurrence of ulceration.

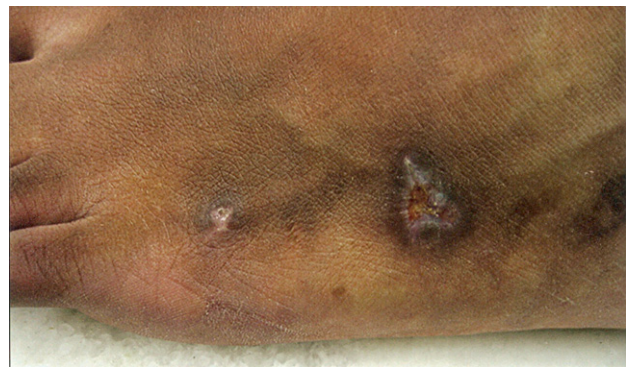


Fig. 2 – Healing of ulcers seen at the end of 15 sittings of HBOT. Shrinking margins and reduced necrotic material in the ulcer base can be clearly seen.

Discussion

Hyperbaric oxygen therapy is a recognized modality of treatment of various problem wounds and non-healing ulcers due to various etiologies. The group Non-healing ulcers forms the single largest group of indications for which HBOT is being administered. This group includes various indications like diabetic foot ulcers, arterial insufficiency ulcers, ulcers due to venous stasis, decubitus ulcers and fungal infections of the foot such as Madura foot. These disorders have a common pathology in having ischaemia and infection as the most common causes of non-healing.^{5,6} HBOT has also been advocated for treatment of reperfusion injuries where it reduces WBC adhesion and the consequent free radical-induced endothelial damage.⁷

Livedoid vasculopathy has been seen to be a result of increased white cell aggregation followed by release of proteolytic enzymes, and superoxide radicals. It has also been postulated that there could be development of microvascular fibrin thrombi which lead to hypoxia of the skin leading to ulceration.² It is possible that one or both these etiological factors might be affected and improved by hyperbaric oxygenation.

Yang et al³ had first used HBOT for the management of livedoid vasculopathy with rapid healing of ulcers and significant reduction in pain. Thereafter, Juan et al⁴ administered HBOT to 12 patients of livedoid vasculopathy. Resumption of ambulation and reduction in analgesics in these patients was achieved at an average of 4.9 HBO sessions and healing of leg ulcers was seen at mean of 3.4 weeks.

In our first patient, analgesics were stopped by the 18th sitting and healing of ulcers was seen after 25 sittings. In the second patient, it took 17 sittings for cessation of analgesic intake and 28 sittings for ulcer healing.

The above two cases show that hyperbaric oxygen can be a very useful treatment modality for the management of livedoid vasculopathy where other treatment modalities have failed and therefore could be given to a larger number of patients in hospitals where it is available.

Conflicts of interest

All authors have none to declare.

REFERENCES

1. Leonard A, Pomeranz MK, Franks Andrew G. A case of livedoid vasculopathy in a 22-year-old man. *J Drugs Dermatol*. Available from: http://findarticles.com/p/articles/mi_m0PDG/is_6_3/ai_n12418282/?tag=content;coll1; 2004 Nov–Dec.
2. Scheinfeld NS. Livedoid Vasculopathy. Available from: <http://emedicine.medscape.com/article/1082675-overview>; 2010 Sep.
3. Yang CH, Ho HC, Chan YS, Liou LB, Hong HS, Yang LC. Intractable livedoid vasculopathy successfully treated with hyperbaric oxygen. *Br J Dermatol*. 2003 Sep;149(3):647–652.
4. Juan WH, Chan YS, Lee JC, Yang LC, Hong HS, Yang CH. Livedoid vasculopathy: long-term follow-up results following hyperbaric oxygen therapy. *Br J Dermatol*. 2006 Feb;154(2):251–255.
5. Faglia E, Favales F, Aldeghi A, et al. Adjunctive systemic hyperbaric oxygen therapy in treatment of severe prevalently ischemic diabetic foot ulcer. A randomized study. *Diabetes Care*. 1996;19(12):1338–1343.
6. Mathieu D. Role of hyperbaric oxygen therapy in the management of lower extremity wounds. *Int J Low Extrem Wounds*. 2006;5(4):233–235.
7. Gill AL, Bell CAN. Hyperbaric oxygen: it's uses, mechanisms of action, and outcomes. *QJ Med*. 2004;97:385–395.