

A Natural Meliorate: Revolutionary Tissue Engineering in Endodontics

I.B. GEETA¹, GIRISH GALAGALI², KULKARNI SANGEETA³, SURAN PUSHPA⁴, FAIZAL NOUSHIN⁵

ABSTRACT

Platelet-Rich Fibrin (PRF) was first described by Choukroun et al., (2001). It has been referred to as a second-generation platelet concentrate, which has been shown to have several advantages over traditionally prepared platelet-rich plasma. PRF has a physiologic architecture that is very favourable to the healing process, obtained due to the slow polymerization process. The development of platelet concentrate as bioactive surgical additives that are applied locally to promote wound healing stems from the use of fibrin adhesive. Developments in the field of tissue engineering have made the generation of artificial substitutes in several areas of medicine. Various clinical applications in endodontics include Periapical surgeries, Revascularisation procedures, Regenerative pulpotomy, Perforation repair. This article aims to discuss the various applications of PRF in the field of Endodontics with few case reports.

Keywords: Platelet rich fibrin, Apexification, Pulpotomy, Tissue engineering

CASE 1

PRF for revascularization of nonvital immature teeth

A 26-year-old male patient reported to Department of Conservative Dentistry and Endodontics, Rajarajeswari Dental college, Bangalore with chief complaint of discolored and fractured upper central incisors [Table/Fig-1]. Patient had given H/o Trauma 15 years back. Pulp vitality gave negative response. Since, the lesion was diffuse and the absence of cystic lining, it was diagnosed as Chronic periapical abscess with immature apex 11,21.

After informed consent was obtained, the teeth were anesthetized using 2% lidocaine with 1:100,000 epinephrine, isolated with rubber dam and access cavity prepared 11,21. The canals irrigated with 3% NaOCl and saline. After drying the canals, a triple antibiotic paste –metronidazole, ciprofloxacin and minocyclin at a concentration of 20mg of each antibiotic per ml was inserted. Temporary restoration was done with zinc oxide eugenol. The patient was recalled 3 weeks later. The tooth was again anesthetized, triple antibiotic paste removed and the canals dried. Using an endodontic explorer and hand file, bleeding was induced into the canal space and allowed to clot. PRF was placed into the teeth by using a blunt instrument [Table/Fig-2].

MTA was placed over PRF. The access cavity was restored by using Glass Ionomer Cement. The patient was recalled every 3 months for review. After 1 year follow up, the size of the lesion is reduced along with the dentine thickening in the apical region [Table/Fig-3].

Platelet-rich fibrin might serve as a potentially ideal scaffold in revascularization of immature permanent teeth with necrotic pulps as it is rich in growth factors, enhances cellular proliferation and differentiation, and acts as a matrix for tissue ingrowth [1].

CASE 2

PRF as apical barrier for apexification of nonvital immature tooth

A 29-year-old male patient reported to with chief complaint of discoloured and broken 21 [Table/Fig-4]. Patient gives H/o Trauma 15 years back. Pulp vitality gave negative response in relation to. Diagnosis was Chronic periapical abscess with immature apex 21.

Treatment protocol followed was the same as case 1. Instead of placing PRF into the canal, here it is used as apical barrier [Table/Fig-5]. MTA placed for apexification and back filling done with thermoplasticized guttapercha technique [Table/Fig-6].

The combination of PRF membrane as a matrix and MTA can prove to be an effective alternative for creating artificial root-end barriers and to induce faster periapical healing in cases with large periapical lesions [2].

CASE 3

Regenerative pulpotomy using PRF

A 19-year-old male patient reported with established pulpitis in 46 with carious pulp exposure and sharp, intermittent pain [Table/Fig-7].

Teeth was first anaesthetized by using Lidocaine 2% with adrenaline and isolated. Caries excavation done with round bur using slow speed hand piece. Pulpotomy was performed with a sharp spoon excavator. Coronal pulp was removed to the level of pulp chamber floor [Table/Fig-8]. Haemostasis achieved by irrigating the cavity with sterile saline and cotton pellets. The pulpal wound was covered with PRF [Table/Fig-9].

A 2 mm thick layer of MTA placed over the PRF and an interim restoration of glass-ionomer cement placed [Table/Fig-10].

At the first recall after 1 day no post-operative pain was reported. At 6 months, the tooth responded positively to pulp sensibility tests, and radiographic examination revealed a normal periodontal ligament space [Table/Fig-11,12].

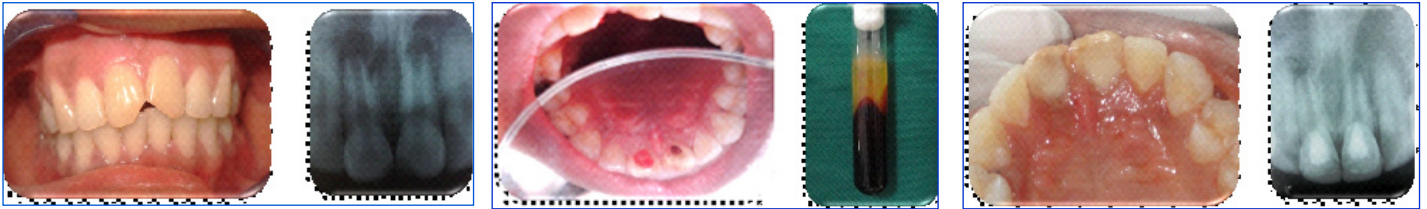
The pulp cells residing in pulp clinically diagnosed with pulpitis might still have stem cell potential similar to healthy pulp cells and therefore might be a resource for autologous pulp regeneration [3].

CASE 4

Application of PRF in periapical surgery

A 29-year-old female patient reported to with chief complaint of pain in the 31,41 [Table/Fig-13]. radiograph revealed extruded GP into the periapex. Periapical surgery was scheduled. Rectangular flap incision given [Table/Fig-14], extruded GP was removed, granulation tissue curetted. PRF was placed over the bony defect. Sutures given [Table/Fig-15].

Using autologous platelet rich fibrin matrix in the bony defects has benefits for organizing the osteoblasts, formation of neovascularization and more rapid and faster apposition of bone matrix with its mineralization process [4].



[Table/Fig-1]: Discolored and broken upper front teeth with preoperative radiographic view

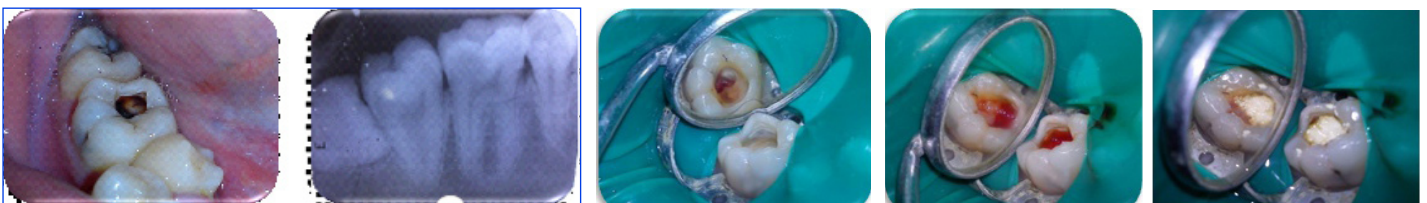
[Table/Fig-2]: PRF was placed into the teeth using a blunt instrument and the Prepared PRF

[Table/Fig-3]: One year recall view clinical and radiographic

[Table/Fig-4]: Discolored and broken upper front teeth and the preoperative radiographic view

[Table/Fig-5]: PRF placed as apical barrier

[Table/Fig-6]: MTA placed for apexification and back filling done with thermoplasticized gutta percha technique

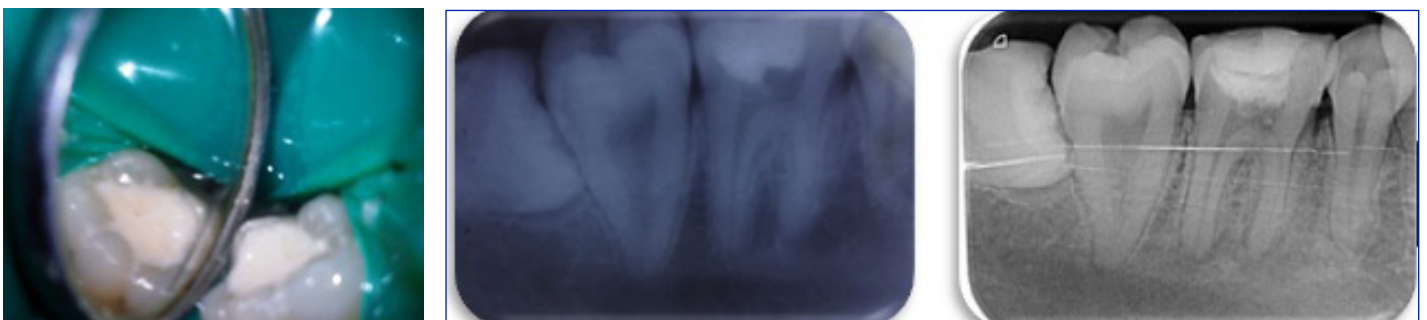


[Table/Fig-7]: The tooth deep dentinal caries and pre operative radiographic view

[Table/Fig-8]: Coronal pulp tissue was removed to the level of pulp chamber

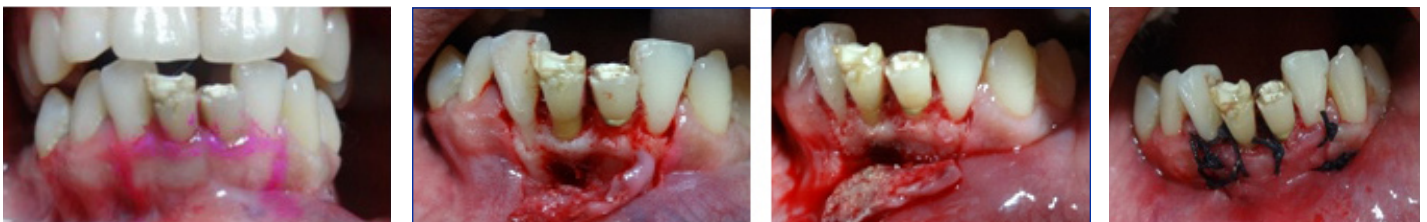[Table/Fig-9]: Pulpal wound was covered with a small piece of PRF

[Table/Fig-10]: MTA placed over the pulpal wound



[Table/Fig-11]: Temporary restoration given with GIC

[Table/Fig-12]: Post operative radiographs, One month, Six months



[Table/Fig-13]: Pre operative view

[Table/Fig-14]: Flap raised, extruded GP seen through the apex, PRF placed into the lesion

[Table/Fig-15]: Sutures placed

DISCUSSION

In Greek mythology, Prometheus stole fire from Zeus and gave it to mankind. As punishment, Zeus had him chained to a rock where a great vulture tore at his liver every day. During the night, the liver grew whole again, only to have the vulture devour it again the next day [5].

Today, the regrowth of Prometheus' liver has become a symbol to medical researchers for the possible renewal of damaged human organs through the use of human stem cells. Developments in the

field of tissue engineering have made the generation of artificial substitutes in several areas of medicine.

Platelet-Rich Fibrin (PRF) was first described by Choukroun et al. It has been referred to as a second-generation platelet concentrate. PRF is a matrix of autologous fibrin, in which are embedded a large quantity of platelet and leukocyte cytokines during centrifugation [6]. The success rate of regenerative endodontics with its long term prognosis needs to be evaluated and improved before it can replace the conventional root canal treatment and restorations. In spite of

the directed efforts in dealing with various complexities associated with regenerating tissues, the field is still largely in its infancy.

The concept of Revascularization was introduced by Ostby in 1961, where in pulp space requires complete disinfection of the canal, a scaffold for new tissue to grow, stem cells and growth factors [7].

PRF as a scaffolding material in an infected necrotic immature tooth for pulpal regeneration and tooth revitalization as it satisfies many criteria of an ideal physical scaffold [1]. Triple antibiotic paste was used for disinfection of the canal because this particular combination is effective in addressing the diverse flora present in the root canal. Sato et al., investigated this drug combination in vitro and found it to be very effective in the sterilization of carious lesions, necrotic pulps, infected root dentin and periapical lesions. This drug combination is also effective in killing the bacteria in the deep layers of root canal dentin [8,9].

Directly over the PRF clot the MTA was packed and condensed to obtain a tight coronal seal as it is hydrophilic and needs moisture to set, which is a favorable property when there is potential for moisture contamination in the clinical setting, and also MTA by itself provides signaling molecules for the growth of the stem cells [10].

The potential theory behind the success of the presented case could be attributed to a study conducted by Huang et al., who concluded that the PRF causes proliferation of human Dental Pulp Cells and increases the protein expression of Osteoprotegerin (OPG) and Alkaline Phosphatase (ALP) activity. Some amounts of human dental pulp cells present in the apical papilla usually remain vital even in case of a large periapical lesion [2].

Pulpotomy is a universally accepted treatment for teeth with incompletely formed roots involving pulpal exposure. In permanent teeth, it has been postulated that extirpating pulpal tissue and undertaking root canal treatment in many cases is not cost-effective as it is time-consuming and difficult for both patient and clinician. In addition, failure of a vital pulp therapy would not reduce the outcome of future root canal treatment for the tooth.

The potential theory behind the success of the presented case could be attributed to a study conducted by Wang et al., that the pulp cells residing in pulp clinically diagnosed with pulpitis might still have stem cell potential similar to healthy pulp cells and therefore might be a resource for autologous pulp regeneration [3].

Bone regeneration after surgical intervention takes place in a very slow manner. Hence, to enhance these processes a number of bone substitutes are being tried out. The objective of using a bone graft is to achieve successful and complete healing of the bone. Bone

grafting is the most common form of regeneration therapy. A variety of materials are available for bone regeneration, which are highly osteoconductive or osteoinductive like, freeze dried bone graft, bioactive glass, emdogain, PTR polymer, MTA, tricalcium phosphate, and octacalcium phosphate. PRF is an osteoinductive material that enhances osteogenesis in the extraction tooth socket in comparison to the physiological healing process. It also provides a significant postoperative protection of the surgical site and seems to accelerate the integration and remodeling of the grafted biomaterial [11].

CONCLUSION

PRF has a physiologic architecture that is favourable to the healing, obtained due to the slow polymerization process. It is the responsibility of the clinician to gain a thorough understanding of this biotechnology and to use it wisely for the benefit of our patients. PRF with immense regenerative potential will definitely revolutionize the surgical dentistry in the near future. More histologic evaluations are required to assess the success rate of PRF.

REFERENCES

- [1] Keswani D, Pandey RK. Revascularization of an immature tooth with a necrotic pulp using platelet-rich fibrin: a case report. *Int Endod J*. 2013 Nov;46(11):1096-1104.
- [2] Ambica Kathuria, Sarika Chaudhry, Sangeeta Talwar, Mahesh Verma. *J Clin Exp Dent*. 2011;3(5):e487-90. Management of immature mandibular second molar using MTA and PRF membrane barrier.
- [3] Hiremath, et al. Second generation platelet concentrate as a pulpotomy medicament in human molar with pulpitis. *IntEndod*. 2012;45:105-112.
- [4] Simon BI, Zatcoff AL, Kong JJW, O'Connell SM. Clinical and histological comparison of extraction socket healing following the use of Autologous Platelet-rich Fibrin Matrix (PRFM) to ridge preservation procedures employing demineralized freeze dried bone allograft material and membrane. *Open Dent J*. 2009; 3: 92-9.
- [5] en.wikipedia.org/wiki/Prometheus
- [6] Dohan DM, Choukroun J, Diss A, Dohan AJ, Mouhyi J, et al. Platelet-Rich Fibrin (PRF): a second-generation platelet concentrate. Part I: technological concepts and evolution. *Oral Surg Oral Med Oral Pathol Oral RadiolEndod*. 2006; 101: e37-44.
- [7] Ostby BN. The role of the blood clot in endodontic therapy: an experimental histologic study. *Acta Odontol Scand*. 1961;19:324-53.
- [8] Windley 3rd W, Teixeira F, Levin L, Sigurdsson A, Trope M. Disinfection of immature teeth with a triple antibiotic paste. *Journal of Endodontics*. 2005;31:439-43.
- [9] Sato I, Ando-Kurihara N, Kota K, Iwaku M, Hoshino E. Sterilization of infected root-canal dentine by topical application of a mixture of ciprofloxacin, metronidazole and minocycline in situ. *Int Endod J*. 1996;29:118-24.
- [10] Torabinejad M, Parirokh M. Mineral trioxide aggregate: A comprehensive literature review--part II: Leakage and biocompatibility investigations. *J Endod*. 2010;36:190-202.
- [11] Athraa Y, Alhijazi BDS, MSc, Ph.D, Siba A. Mohammed. Evaluation the effect of platelet rich fibrin matrix on bone healing. *J Bagh College Dentistry*. Vol. 23(4), 2011.

PARTICULARS OF CONTRIBUTORS:

1. Professor and HOD, Department of Conservative Dentistry and Endodontics, Rajarajeswari Dental College, Bangalore, Karnataka, India.
2. Professor and HOD, Department of Prosthodontics Including Crown and Bridge, Navodaya Dental College, Raichur, Karnataka, India.
3. Senior Lecturer, Department of Conservative Dentistry and Endodontics, Al Badad Dental College, Gulbarga, Karnataka, India.
4. Reader, Department of Conservative Dentistry and Endodontics, Government Dental College, Bellary, Karnataka, India.
5. Post Graduate, Department of Conservative Dentistry And Endodontics, Rajarajeswari Dental College, Bangalore, Karnataka, India.

NAME, ADDRESS, E-MAIL ID OF THE CORRESPONDING AUTHOR:

Dr. Girish Galagali,
Professor and Head, Department of Prosthodontics,
Navodaya Dental College and Hospital, Navodaya Nagar, Manthralayam Road, Raichur-584103, India.
Phone: 8147904239, E-mail: drgirish232@gmail.com

FINANCIAL OR OTHER COMPETING INTERESTS: None.

Date of Submission: **Jul 10, 2013**
Date of Peer Review: **Aug 02, 2013**
Date of Acceptance: **Oct 12, 2013**
Date of Publishing: **Nov 10, 2013**