

Case Report

Macular hole in juvenile X-linked retinoschisis



Nayef Al-Swaina, MD^a; Sawsan R. Nowilaty, MD^{b,*}

Abstract

An 18 year-old male with no antecedent of trauma, systemic syndrome or myopia was referred for surgical treatment of a full thickness macular hole in the left eye. A more careful inspection revealed discrete foveal cystic changes in the fellow eye and subtle peripheral depigmented retinal pigment epithelial changes in both eyes. A spectral-domain optical coherence tomography (SD-OCT) scan confirmed, in addition to the full thickness macular hole in the left eye, microcystic spaces in the nuclear layers of both retinae. The diagnosis of X-linked retinoschisis was confirmed with a full field electroretinogram displaying the typical negative ERG. Macular holes are uncommon in the young and those complicating X-linked retinoschisis are rare. This report highlights the importance of investigating the presence of a macular hole in a young patient and illustrates the clinical and SD-OCT clues beyond the foveal center which led to the correct diagnosis of X-linked juvenile retinoschisis.

Keywords: Macular hole, Retinoschisis, Spectral-domain optical coherence tomography

© 2013 Production and hosting by Elsevier B.V. on behalf of Saudi Ophthalmological Society, King Saud University.
<http://dx.doi.org/10.1016/j.sjopt.2013.05.001>

Introduction

Idiopathic full-thickness macular holes are common in the elderly.¹ In the young however, and in the absence of trauma or high myopia, macular holes are rare. We report a case of a macular hole complicating X-linked juvenile retinoschisis, and highlight the clinical and optical coherence tomographic features that led to the diagnosis.

Case report

This case report was approved by the Human Ethics Committee/Internal Review Board of the King Khaled Eye Specialist Hospital. An 18 year old male was referred for surgical treatment of a macular hole in the left eye. Past ocular history was positive for slow visual decline in both eyes over several years which was worse in the left eye. The patient denied

prior trauma or night blindness. Past medical history and family history were negative.

On examination, visual acuity was 20/50 in the right eye and 20/160 in the left eye. Intraocular pressures were 14 mmHg bilaterally. The external and anterior segment examinations were normal in both eyes. Fundus examination of the left eye revealed a large full-thickness round macular hole, approximately 1000 μm wide, surrounded by a shallow cuff of subretinal fluid. White spots were visible under the subretinal fluid and on the retinal pigment epithelium (RPE) surface at the center of the hole (Fig. 1-A). Fundus examination of the right eye disclosed discrete cystic changes in the center of the macula (Fig. 1-B). The inferior peripheral retina in both eyes harbored de-pigmented RPE changes. The rest of the fundus was unremarkable. With these signs, the possibility of a hereditary retinal degeneration as a cause for the macular hole was suspected. A spectral domain optical coherence tomography (SD-OCT) (HRA Spectralis, Heidel-

Received 27 April 2013; accepted 21 May 2013; available online 30 May 2013.

^a Residency in Ophthalmology Program – Riyadh Area, Saudi Arabia

^b Vitreoretinal Division, King Khaled Eye Specialist Hospital, Riyadh, Saudi Arabia

* Corresponding author. Address: Vitreoretinal Division, King Khaled Eye Specialist Hospital, P.O. Box 7191, Riyadh 11462, Saudi Arabia. Tel.: +966 11 4821234x3773.

e-mail address: snwilaty@kkesh.med.sa (S.R. Nowilaty).



Peer review under responsibility of Saudi Ophthalmological Society, King Saud University



Production and hosting by Elsevier

Access this article online:
www.saudiophthaljournal.com
www.sciencedirect.com

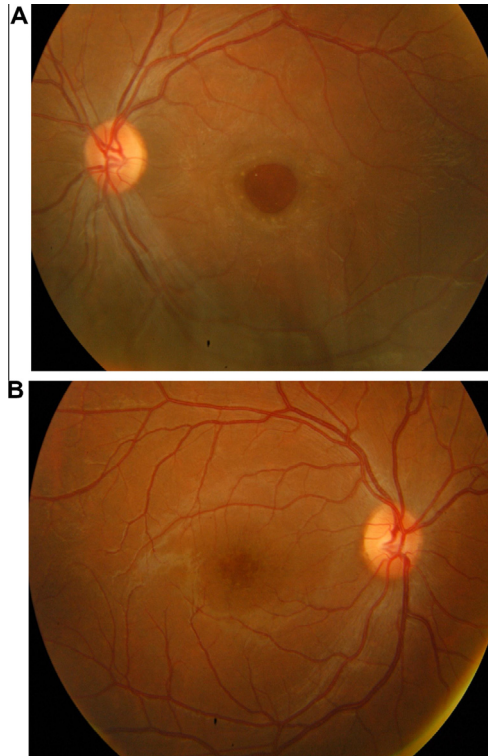


Figure 1. Fundus pictures of the right and left eyes. A (top): The left eye shows a large full thickness macular hole with surrounding subretinal fluid. B (bottom): The right fovea displays a cystic appearance.

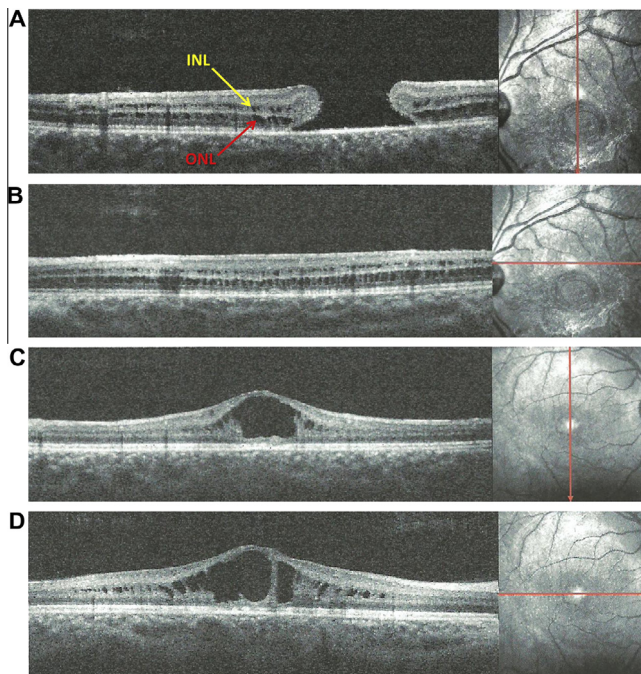


Figure 2. Macular spectral domain optical coherence tomography (SD-OCT) scan of the right and left eyes. (A, top): The vertical scan of the left macula shows a full thickness macular hole. Microcystic cavities located in the inner nuclear layer (INL, yellow arrow) and outer nuclear layer (ONL, red arrow) are visible beyond the fovea on the vertical and horizontal scans (B). The vertical (C) and horizontal (D) scans of the right macula show large cystoid spaces in the fovea and similar microcystic changes beyond it.

berg Engineering, Heidelberg, Germany) scan confirmed the full-thickness macular hole in the left eye without signs of vitreomacular traction (Fig. 2-A). However, it also depicted microcystic spaces along the inner and outer nuclear layers on either side of the hole (Fig. 2-A and B). In the right eye, the SD-OCT showed similar inner nuclear cavities that coalesced into large cystoid spaces at the foveal center (Fig. 2-C and D).

Fundus fluorescein angiography, performed to rule out cystoid macular edema in the right eye, confirmed the absence of leakage in and around the fovea, and showed discrete staining at the foveal center in the late phase of the angiogram (Fig. 3-A). In the left eye, the foveal changes were consistent with the macular hole (Fig. 3-B).

Based on the clinical examination, SD-OCT and angiographic findings, the diagnosis of idiopathic or post traumatic macular hole was unlikely, and X-linked juvenile retinoschisis was considered. The diagnosis was confirmed by the typical negative electroretinogram (ERG) appearance displaying a normal a-wave and reduced b-wave (Fig. 4).

Discussion

The vast majority of full-thickness macular holes are idiopathic, where tangential vitreous traction is implicated as the underlying mechanism.¹ These holes generally occur beyond the 5th decade of life. Other common causes of macular holes are ocular trauma, inflammation and degenerative myopia.¹ Much rarer causes are macular holes complicating the Alport syndrome,²⁻⁴ X-linked juvenile retinoschisis⁵ or the Goldmann-Favre syndrome.⁶

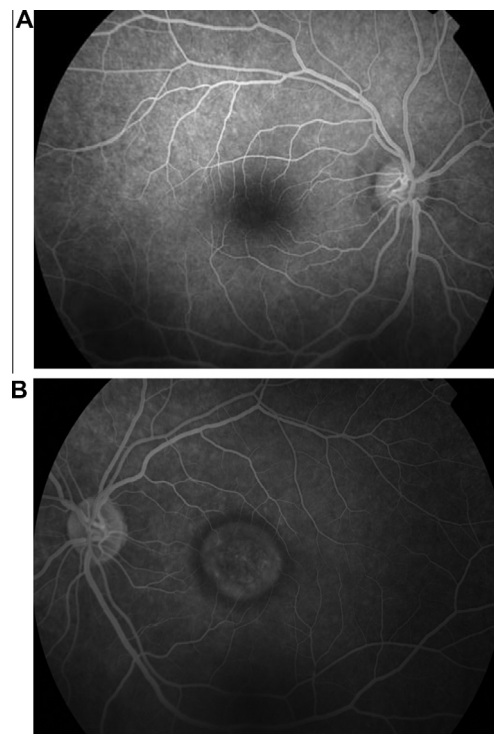


Figure 3. Fundus fluorescein angiography of the right and left eyes. A (top): Note the absence of dye leakage at the right fovea. B (bottom): A circular area of transmission defect corresponds to the macular hole in the left eye.

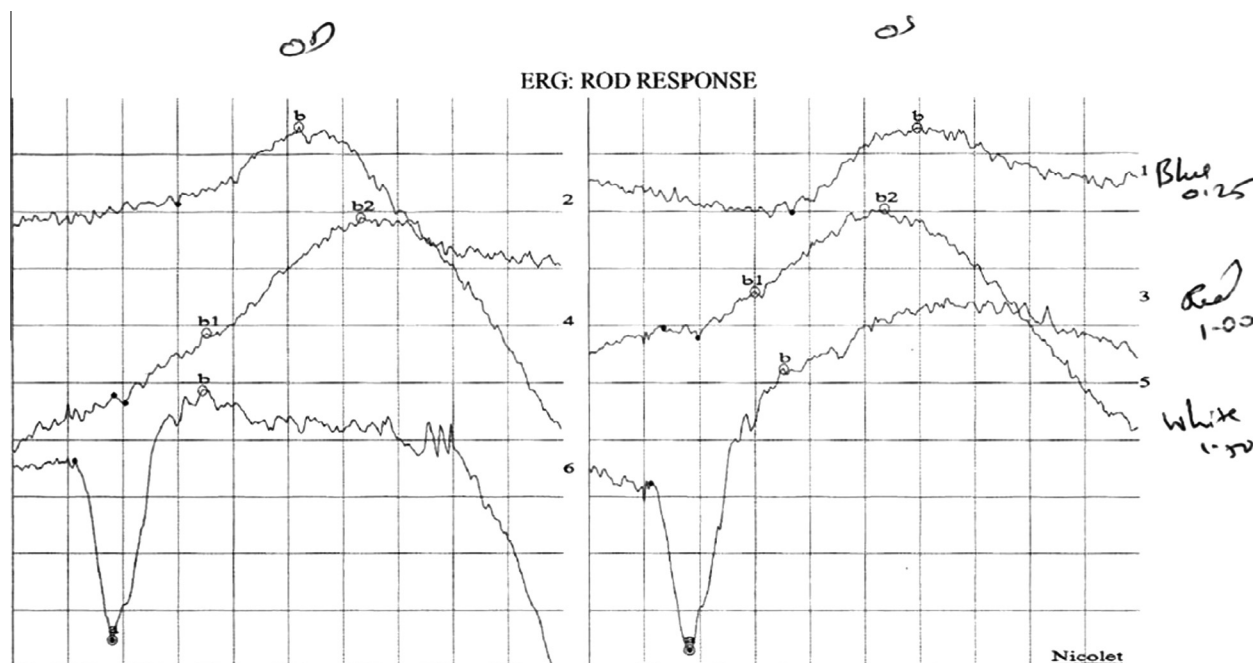


Figure 4. Electrophoretogram. The scotopic response of both eyes shows a large negative a-wave with a reduced b-wave.

In our patient, although on initial examination the macular hole was the only remarkable finding, in view of the patient's young age and the absence of signs of previous ocular trauma or myopia, the diagnosis of idiopathic macular hole was less convincing. This prompted the search for other causes for the macular hole.

Large macular holes have been rarely reported as a manifestation of the Alport syndrome, an X-linked inherited disorder, but in which autosomal dominant and recessive pedigrees have been described. Progressive renal insufficiency and neurosensory deafness characterize this syndrome.² The ocular signs of the Alport syndrome typically include dot-and-fleck retinopathy in 85% and anterior lenticonus in 25%.⁴ The etiology of the large macular holes is unclear. Mete et al. have hypothesized that the passage of fluid through a dysfunctional Bruch's membrane may create small cystic cavities in the retinal layers with subsequent disruption leading to a full thickness retinal hole.³ With the exception of the relatively large size of the macular hole in our patient, there were no signs of the Alport syndrome.

The clues that permitted to lead to the correct diagnosis in this case lied firstly in the subtle foveal changes of the fellow eye, and secondly in the findings of the SD-OCT of the eye with the macular hole. The importance of a careful clinical examination of both eyes cannot be overemphasized. The discrete cystic appearance at the fovea had been overlooked in previous evaluations. This clue, however, pointed in the direction of X-linked juvenile retinoschisis. On the other hand, the careful interpretation of the SD-OCT, depicting small cyst-like cavities in the nuclear layers beyond the obvious full thickness macular hole, was highly suggestive of retinal splitting, a finding that had also been overlooked but which was further confirmed in the macular SD-OCT scan of the fellow eye. The final confirmation of the diagnosis was offered by the characteristic "negative" ERG.

X-linked retinoschisis is a known cause of macular degeneration in male children. Presenting symptoms include poor vision, strabismus and nystagmus, but the clinical presentation and degree of visual loss can be highly variable.⁷ A Foveal schisis seen as a cartwheel pattern of folds radiating out from the fovea is characteristic and present in 98–100% of cases.⁷ More than half of the patients also have a peripheral retinoschisis. This was not present in our patient. Recurrent vitreous hemorrhages in up to a third of patients and retinal detachment in up to 20% of patients are additional features.⁸ Macular holes on the other hand are rare.

Optical coherence tomography, a non-invasive imaging modality, has become an indispensable tool in the diagnosis of retinal diseases. It is extremely valuable in detecting subtle intraretinal or subretinal changes or fluid collections, permitting an accurate anatomical analysis, and hence, diagnosis in many cases. In this case, the SD-OCT permitted to confirm not only the full thickness features of the macular hole in the left eye, but also the discrete cystic changes in the inner and outer nuclear layers of the retina which were not detectable on biomicroscopy. The presence of these changes in the left eye alone was sufficient to evoke a retinal degenerative process extending beyond the foveal center. Intraretinal cystic collections are commonly associated with inflammatory or retinal vascular diseases, such as diabetic retinopathy,⁹ but in these scenarios they occur mostly in the outer plexiform layer and are associated with fluorescein leakage on angiography, which was not the case in our patient. In other conditions however, such as retinal degenerative diseases, idiopathic juxtafoveal telangiectasis type 2,¹⁰ and papillomacular folds in high hyperopia,¹¹ the cyst-like cavities occur primarily in the inner nuclear layers and do not leak fluorescein. Although the splitting of the retina in X-linked retinoschisis has been classically considered to occur in the ganglion cell and nerve fiber layers,¹² modern SD-OCT has confirmed that the schisis

cavities exist mostly at the inner nuclear layer, with occasional involvement of the outer retina (outer plexiform layer/outer nuclear layer).^{13,14} This was clearly demonstrated in our case as well.

Full-thickness macular hole secondary to X-linked retinoschisis is a rare occurrence. A handful of cases have been reported in the literature.^{5,15–17} The exact mechanism is not well known. Ocular trauma and vitreomacular traction have been suggested as a possible cause.⁵ A de-roofing mechanism has been suggested in one report.¹⁶ In the absence of ocular trauma and obvious vitreomacular traction, as in this case, continuous degenerative changes in a schitic neurosensory retina may be the contributor for the macular hole formation.⁵

In conclusion, we report a case of macular hole complicating X-linked retinoschisis. This case emphasizes the necessity to fully investigate the presence of a full thickness macular hole in a young patient. This case also highlights the diagnostic clues provided by the examination of the fellow eye and the OCT findings beyond the macular hole which permitted to establish the diagnosis.

Conflict of interest

The authors declared that there is no conflict of interest.

References

1. Ezra E. Idiopathic full thickness macular hole: natural history and pathogenesis. *Br J Ophthalmol* 2001;**85**:102–8.
2. Shah SN, Weinberg DV. Giant macular hole in Alport syndrome. *Ophthalmic Genet* 2010;**31**:94–7.
3. Mete UO, Karaaslan C, Ozbilgin MK, et al. Alport's syndrome with bilateral macular hole. *Acta Ophthalmol Scand* 1996;**74**:77–80.
4. Colville DJ, Savige J. Alport syndrome: a review of the ocular manifestations. *Ophthalmic Genet* 1997;**18**:161–73.
5. Brasil OF, da Cunha AL, de Castro MB, Japiassú RM. Macular hole secondary to X-linked juvenile retinoschisis. *Ophthalmic Surg Lasers Imaging* 2011;**1**:42, Online:e4–5.
6. Theodossiadis PG, Koutsandrea C, Kollia A-C, Theodossiadis GP. Optical coherence tomography in the study of the Goldmann–Favre syndrome. *Am J Ophthalmol* 2000;**129**:542–4.
7. Tantri A, Vrabec TR, Cu-Unjieng A, Frost A, Annesley Jr WH, Donoso LA. X-linked retinoschisis: a clinical and molecular genetic review. *Surv Ophthalmol* 2004;**49**:214–30.
8. Sikkink SK, Biswas S, Parry NRA, Stanga PE, Trump D. X-linked retinoschisis: an update. *J Med Genet* 2007;**44**:225–32.
9. Pelzek C, Lim JI. Diabetic macular edema: review and update. *Ophthalmol Clin North Am* 2002;**15**:555–63.
10. Paunescu LA, Ko TH, Duker JS, et al. Idiopathic juxtafoveal retinal telangiectasis: new findings by ultrahigh-resolution optical coherence tomography. *Ophthalmology* 2006;**113**:48–57.
11. Nowilaty SR, Mousa A, Ghazi NG. The posterior pole and papillomacular fold in posterior microphthalmos: novel spectral-domain optical coherence tomography findings. *Ophthalmology* 2013. <http://dx.doi.org/10.1016/j.ophtha.2013.01.026>.
12. Yanoff M, Kertesz Rahn E, Zimmerman LE. Histopathology of juvenile retinoschisis. *Arch Ophthalmol* 1968;**79**:49–53.
13. Yu J, Ni Y, Keane PA, Jiang C, Wang W, Xu G. Foveomacular schisis in juvenile X linked retinoschisis: an optical coherence tomography study. *Am J Ophthalmol* 2010;**149**:973–8, e2.
14. Gregori NZ, Berrocal AM, Gregori G, Murray TG, Knighton RW, Flynn Jr HW, et al. Macular spectral-domain optical coherence tomography in patients with X linked retinoschisis. *Br J Ophthalmol* 2009;**93**:373–8.
15. Shanmugam MP, Nagpal A. Foveal schisis as a cause of retinal detachment secondary to macular hole in juvenile X-linked retinoschisis. *Retina* 2005;**25**:373–5.
16. Shukla D, Naresh KB, Rajendran A, Kim R. Macular hole secondary to X-linked retinoschisis. *Eye* 2006;**20**:1459–61.
17. Gautam M, Muralidhar NS, Murthy H. Bilateral macular holes in X-linked retinoschisis: now the spectrum is wider. *Indian J Ophthalmol* 2011;**59**:507–9.