

## Coronary-cameral fistulas in adults: Acquired types (second of two parts)

Salah AM Said, Rikke HM Schiphorst, Richard Derksen, Lodewijk J Wagenaar

Salah AM Said, Department of Cardiology, Hospital Group Twente, 7555 DL Hengelo, The Netherlands

Rikke HM Schiphorst, Department of Cardiology, Thoraxcentrum Twente, Medisch Spectrum Twente, 7513 ER Enschede, The Netherlands

Richard Derksen, Department of Cardiology, Rijnstate Hospital, 6815 AD Arnhem, The Netherlands

Lodewijk J Wagenaar, Department of Cardiology, Thoraxcentrum Twente, Medisch Spectrum Twente, 7513 ER Enschede, The Netherlands

**Author contributions:** Said SAM, Schiphorst RHM, Derksen R contributed to this paper. Schiphorst RHM collected the data; Derksen R provided the case with the congenital coronary cameral fistula described in part I; Said SAM prepared the manuscript and the literature review; Wagenaar LJ revised the manuscript; all the authors approved the final version of the paper.

**Correspondence to:** Salah AM Said, MD, PhD, FESC, Department of Cardiology, Hospital Group Twente, Geerdinksweg 141, 7555 DL Hengelo, The Netherlands. [samsaid@home.nl](mailto:samsaid@home.nl)  
Telephone: +31-74-2905286 Fax: +31-74-2905289

Received: May 24, 2013 Revised: August 25, 2013

Accepted: October 17, 2013

Published online: December 26, 2013

### Abstract

Acquired coronary artery fistulas (CCFs) are infrequently detected during conventional coronary angiography. To delineate the characteristics of congenital (first part) and acquired (second part) CCFs in adults, a PubMed search was conducted for papers dealing with congenital or acquired CCFs. None of the publications describing patients with coronary-vascular fistulas were included. Papers dealing with pediatric subjects were excluded. From the world literature, a total of 243 adult patients were selected who had congenital ( $n = 159/243$ , 65%) and acquired ( $n = 84/243$ , 35%) CCFs. Among the acquired types ( $n = 72$ , 85.7%) were traumatic (iatrogenic ( $n = 65/72$ , 90%), accidental ( $n = 7/72$ , 10%) and ( $n = 12$ , 14.3%) spontaneously developing in relation to severe coronary atherosclerosis or myocardial infarction. A high incidence of spontaneous

resolution of iatrogenic CCFs resulting from endomyocardial biopsy or following post-septal myectomy was reported. Spontaneous CCFs associated with myocardial ischemia or infarction resolved completely in 8% of the subjects. Early surgical intervention was the treatment of choice in acquired traumatic accidental CCFs. The congenital types are addressed in a previous issue of this journal (first part). In this review (second of two parts, part II), we describe the acquired coronary-cameral fistulas.

© 2013 Baishideng Publishing Group Co., Limited. All rights reserved.

**Key words:** Acquired coronary-cameral fistulas; Accidental coronary-cameral fistulas; Iatrogenic coronary-cameral fistulas; Spontaneous coronary-cameral fistulas; Coronary angiography, Spontaneous resolution; Surgical treatment

**Core tip:** The literature addressing acquired coronary artery fistulas (CCFs) is reviewed. A detailed classification of acquired CCFs is attempted. Acquired coronary artery fistulas are subdivided into spontaneous and traumatic types. The traumatic fistulas encounter iatrogenic and accidental subtypes. The iatrogenic fistulas are secondary to non-surgical interventions (endomyocardial biopsy, permanent pacing and implantable cardioverter-defibrillator leads, radiofrequency cardioablation, baro-trauma and transseptal puncture) and cardiac surgical procedures (septal myectomy and other cardiac surgical procedures). Diagnosis of acquired CCFs is suspected by clinical history and recurrence of symptoms, occurrence of a new continuous machinery cardiac murmur and a palpable thrill. Watchful waiting and supportive medical management may be advocated in the majority of acquired CCFs. Acquired traumatic accidental CCFs are indications for emergent surgical procedures. Within this entity of CCFs, each subtype has its own specific characteristics such as age of the subjects, origin, termination of fistulas or mechanism

of injury and its specific treatment modality.

Said SAM, Schiphorst RHM, Derksen R, Wagenaar LJ. Coronary-cameral fistulas in adults: Acquired types (second of two parts). *World J Cardiol* 2013; 5(12): 484-494 Available from: URL: <http://www.wjgnet.com/1949-8462/full/v5/i12/484.htm> DOI: <http://dx.doi.org/10.4330/wjc.v5.i12.484>

## INTRODUCTION

Congenital coronary-cameral fistulas (CCFs) include solitary and coronary-ventricular multiple micro-fistulas. Congenital CCFs have been described in the first part of this review<sup>[1]</sup>. Acquired CCFs are rare disorders. In this part (second of two parts), we present the acquired traumatic iatrogenic, acquired traumatic accidental and spontaneously occurring CCFs<sup>[2-4]</sup>. The acquired types are defined as single or multiple, direct communications arising from one or more coronary arteries entering into one of the four cardiac chambers (right atrium (RA) and ventricle (RV) and left atrium (LA) and ventricle (LV)) elucidating arterio-venous or arterio-arterial connection, giving rise to left-right or left-left shunt, respectively. Acquired traumatic accidental CCFs as a result of penetrating chest injuries have been reported since 1935<sup>[5]</sup>. Acquired traumatic accidental fistulas usually occur when the continuity or the vicinity of a coronary artery is lacerated subsequent to severe blunt or sharp chest trauma.

Acquired traumatic accidental fistulas may develop secondary to exogenous injuries such as deceleration traumas<sup>[6]</sup> or sharp chest injuries<sup>[7]</sup> in civilian practice due to violence and physical assault<sup>[8-10]</sup> and warfare<sup>[11]</sup> situations during military combat<sup>[12]</sup>. On the other hand, acquired traumatic iatrogenic fistulas may occur following endogenous (intravascular or extra-vascular) diagnostic<sup>[13,14]</sup> or therapeutic interventions<sup>[15-17]</sup>.

Furthermore, iatrogenic fistulas may be acquired secondary to surgical<sup>[3,18]</sup> or non-surgical interventions<sup>[19,20]</sup>. Rarely, CCFs may occur spontaneously in association with severe obstructive atherosclerotic lesions or myocardial infarction<sup>[21,4]</sup>. Diagnosis of acquired CCFs is suspected by clinical history and recurrence of symptoms, occurrence of a new continuous machinery cardiac murmur and a palpable thrill<sup>[8]</sup>.

The entity of CCFs characterized by various manifestations and etiologies, congenital (first part) and acquired (second part), are discussed and the international literature is briefly reviewed. The acquired traumatic iatrogenic, acquired traumatic accidental and spontaneously developing types are presented.

## LITERATURE RESEARCH

PubMed and Google Scholar were searched for the terms “coronary-cameral fistulas (CCFs)”, “congenital” and “acquired” combined with “adult”. The English and non-English medical literature were screened for both

types of congenital (first of two parts, part 1) and acquired (second of two parts, part 2) CCFs in an adult population. The related articles shown on the side page were explored and references were checked for relevant papers, as illustrated in the flow diagram (Figure 1). The definition used for acquired traumatic iatrogenic acquired and traumatic accidental CCFs was adopted from a previous publication<sup>[22]</sup>. The following criteria were stipulated to include homogenous subsets for analysis: acquired traumatic accidental, acquired traumatic iatrogenic and spontaneous CCFs. Manuscripts were checked for completeness and a meticulous search was performed for recognition of fistula termination into any of the four cardiac chambers. Patients were tabulated according to the etiology, age, gender, clinical presentations, complications and management (Table 1 and Figure 2). Publications dealing with adult patients with congenital or acquired coronary-vascular fistulas were not included. Publications considering a pediatric population were excluded.

## Definitions

Acquired traumatic (accidental or iatrogenic) coronary-cameral fistulas are secondary to exogenous or endogenous thoracic trauma, accidental (penetrating or non-penetrating) or iatrogenic (intravascular or extravascular, surgical or non-surgical diagnostic or therapeutic procedures). Furthermore, a direct communication occurs between one or more epicardial coronary arteries and a cardiac chamber, bypassing the myocardial capillary network, which was not present on a prior coronary angiographic study (when available) and not congenital in origin<sup>[22]</sup>.

Iatrogenic coronary-cameral fistulas (surgical and non-surgical procedures) (Figure 3A) develop subsequent to surgical septal myectomy<sup>[3]</sup> or other cardiac surgical procedures (bypass grafting, valvular repair and surgery for congenital anomalies)<sup>[2,23,24]</sup>. The varieties of non-surgical interventions are caused by repeated endomyocardial biopsy<sup>[15,13]</sup>, permanent pacing and ICD implantation<sup>[16,20]</sup> or electrophysiological procedures<sup>[17,25]</sup> and following barotrauma<sup>[19,26]</sup> or subsequent to vessel rupture after coronary stent placement<sup>[27]</sup>.

Accidental coronary-cameral fistulas (penetrating and non-penetrating injuries) (Figure 3B) may occur due to sharp chest wounds such as shrapnel<sup>[11]</sup>, stab wound<sup>[7]</sup> or gunshot<sup>[8]</sup>, and blunt thoracic injury due to deceleration trauma (car and motorcycle accidents)<sup>[6,28]</sup>.

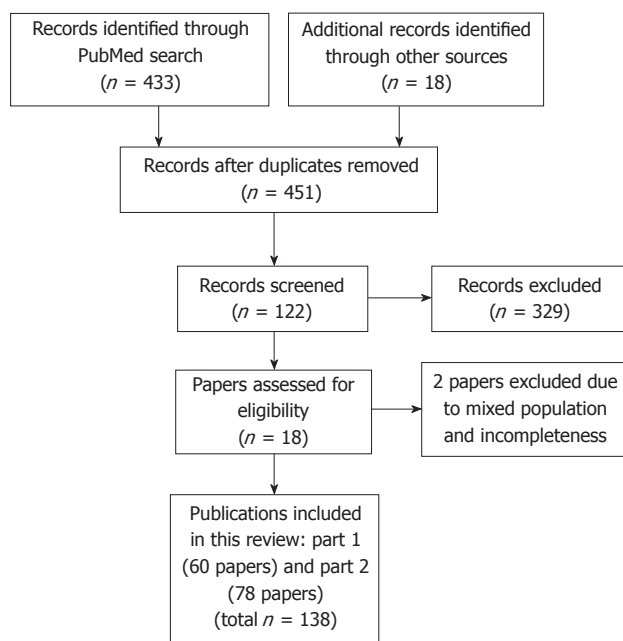
Spontaneous CCFs are coronary-cameral fistulas, spontaneously emerging, associated with severe atherosclerotic lesions<sup>[29]</sup> or develop following myocardial infarction<sup>[4,21]</sup>, resulting in direct communication between the culprit coronary artery and an adjacent cardiac chamber.

## Descriptive analyses

Descriptive analyses were expressed as means and ranges and categorical data were presented as percentages.

## RESEARCH

From the world literature, 243 adult patients were selected



**Figure 1** Flow diagram of literature search of coronary cameral fistulas in adult population.

with congenital ( $n = 159/243$ , 65%) or acquired ( $n = 84/243$ , 35%) CCFs. Among the reviewed subjects with acquired fistulas, ( $n = 65/84$ , 77.4%) were traumatic iatrogenic of origin, ( $n = 7/84$ , 8.3%) were traumatic accidental and ( $n = 12/84$ , 14.3%) presented with spontaneous occurrence of fistulas developing post-MI.

This review focuses on the different aspects with regard to etiology, clinical presentation and management of congenital (first part)<sup>[1]</sup> or acquired (second part) coronary-cameral fistulas (Table 1).

Summary of literature review (Figure 1): Acquired coronary artery fistulas are subdivided into spontaneous ( $n = 12/84$ , 14.3%) and traumatic ( $n = 72/84$ , 85.7%). The traumatic fistulas encounter iatrogenic ( $n = 65/72$ , 90%) and accidental ( $n = 7/72$ , 10%) subtypes. The iatrogenic fistulas are secondary to non-surgical interventions (endomyocardial biopsy, permanent pacing and implantable cardioverter-defibrillator (ICD) leads and radiofrequency cardio-ablation) and cardiac surgical procedures (septal myectomy and other cardiac surgical procedures).

Traumatic fistulas: ( $n = 72/84$ , 85.7%), acquired traumatic iatrogenic ( $n = 65/72$ , 90%), non-surgical interventions: ( $n = 40/65$ , 61%).

Acquired traumatic iatrogenic: Electrophysiological procedures (permanent pacing and ICD leads, transseptal puncture and percutaneous cardio-ablation procedures): These CCFs involve complications of permanent pacing and implantable cardioverter-defibrillator leads, transseptal puncture and electro-physiological procedures ( $n = 8/65$ , 12%)<sup>[14,16,17,20,23,25,30]</sup>. The data of 8 patients (5 male and 3 female) were analyzed. The mean age was 55.8 years (range 46-73). The termination sites were RA<sup>[14]</sup>, LA<sup>[23]</sup>, RV<sup>[16,20]</sup> and LV<sup>[17]</sup>. Regardless of their termination site, conservative medical management was sufficient to relieve symptoms in these acquired fistulas and spontaneous res-

olution occurring following RF cardio-ablation after 9-10 mo was observed<sup>[17,23]</sup>.

Acquired traumatic iatrogenic (baro-trauma): These CCFs occur subsequent to non-surgical therapeutic interventions *e.g.*, baro-trauma. Subsequent to percutaneous coronary intervention (PCI) procedures, fistulous communications between the native left coronary artery and RV<sup>[19]</sup> or LV<sup>[26]</sup> were reported in 7 ( $n = 7/65$ , 11%) patients (5 males and 2 females) with a mean age of 66.6 (range 58-75). Moreover, these complications were described after PTCA of a distal anastomosis of a totally occluded venous graft<sup>[31]</sup>. The donor artery was the left anterior descending coronary artery (LAD) in most of the cases. As the shunt magnitude was trivial without hemodynamic consequences and spontaneous closure was observed, conservative medical management (CMM) was commonly employed.

Post-endomyocardial biopsy (EMB) following heart transplantation ( $n = 25/65$ , 38%): The iatrogenic fistulas occurred after repeated EMB<sup>[32]</sup> or interrelated<sup>[33]</sup> with the applied surgical procedure. The mean age was 50.8 years (range 43-64) with 22% female subjects.

### **Surgical procedures: 25/65 = 38%**

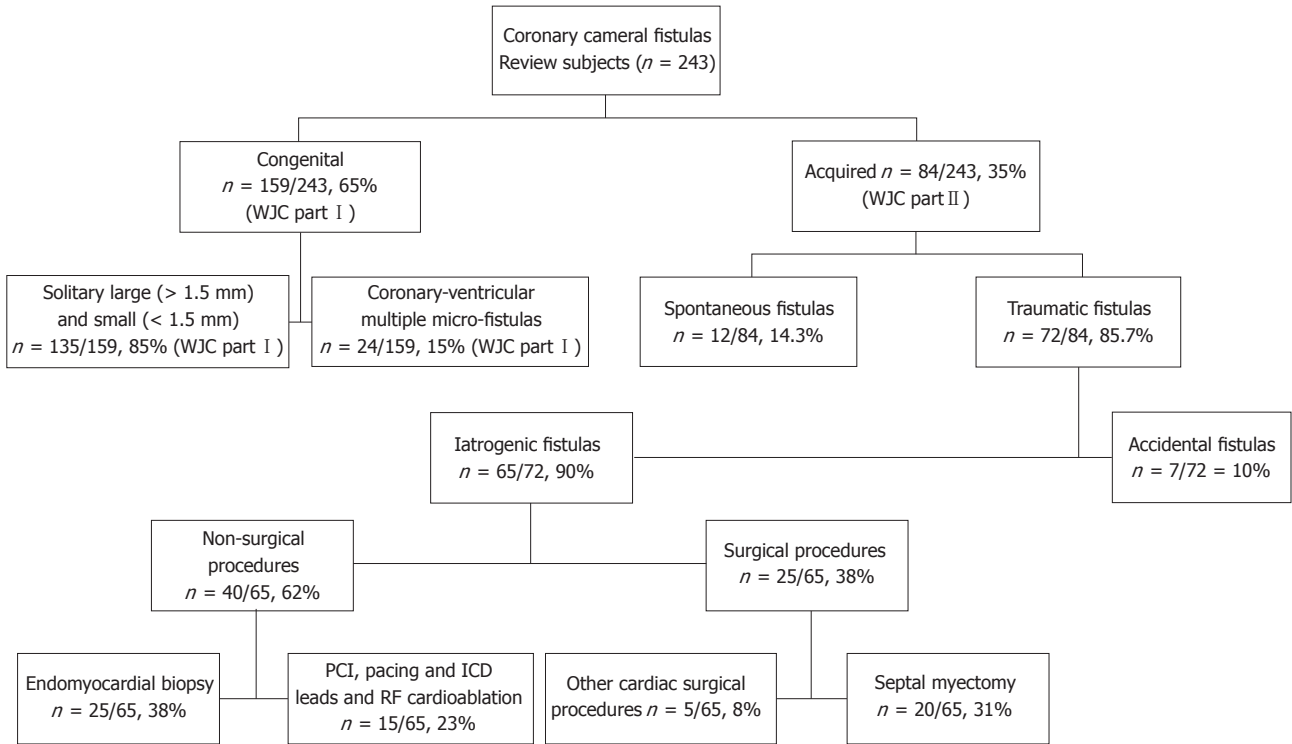
Acquired traumatic iatrogenic after bypass surgery, valvular repair and surgical procedures for congenital heart anomalies: These CCFs occur subsequent to surgical procedures<sup>[2,18,34-36]</sup>. Five adult patients were selected ( $n = 5/65$ , 8%) with a mean age of 61 years (range 40-78). CCFs occurring after heart surgery were reported post-aortic valve<sup>[36]</sup> and mitral valve<sup>[35]</sup> replacement.

Acquired CCFs have been observed after surgical septal myectomy (SM) for hypertrophic cardiomyopathy (HCM) ( $n = 20/65$ , 31%)<sup>[3,18,37-40]</sup>. Twenty patients were selected with a mean age of 45 years (range 32-74). Acquired CCFs following surgical intervention may occur after SM alone<sup>[39]</sup> or after combined aortic valve replacement and SM for hypertrophic cardiomyopathy<sup>[18]</sup>. The drainage site was always the LV. The majority were asymptomatic and disappeared spontaneously (78%). The management is usually a conservative medical strategy and percutaneous therapeutic embolization (PTE) was rarely needed to close the acquired fistula in a symptomatic patient<sup>[3]</sup>.

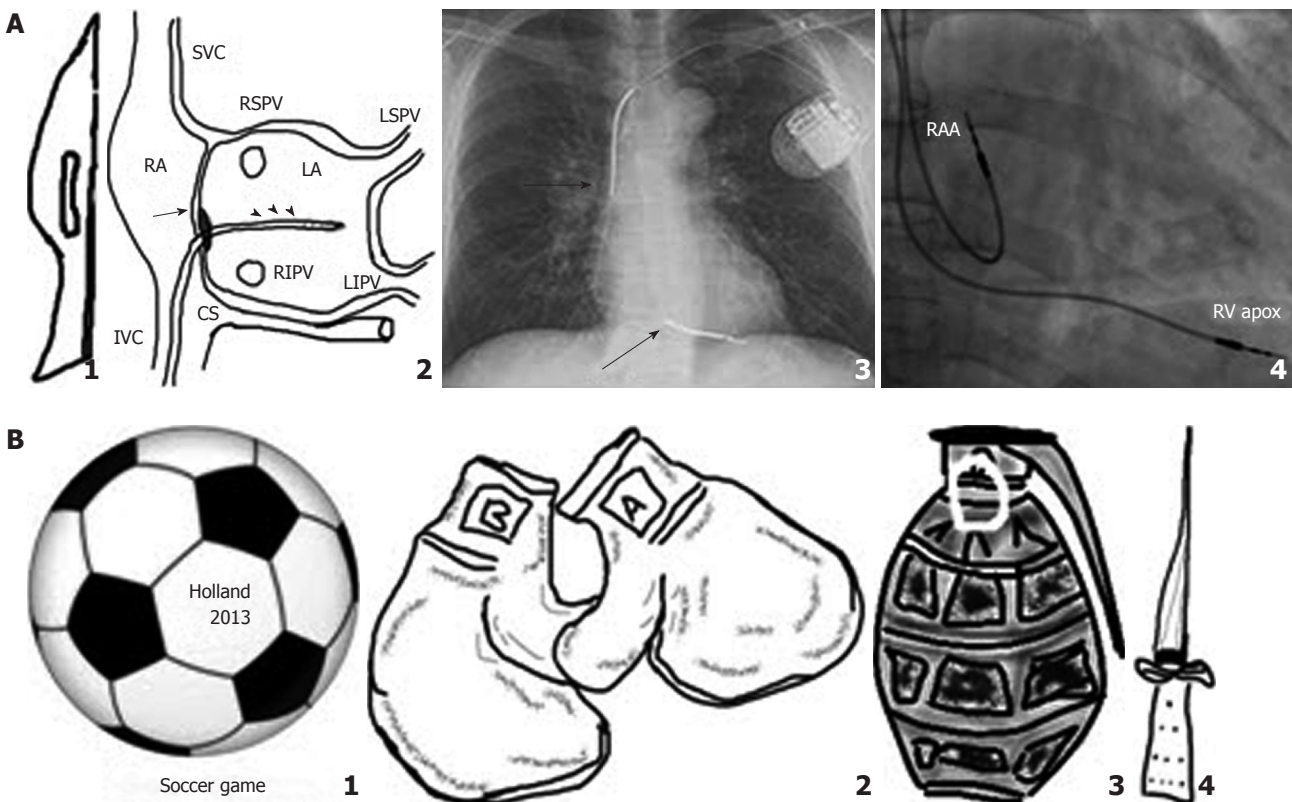
Acquired traumatic accidental CCFs ( $n = 7/72$ , 10%)<sup>[6-8,28,41-43]</sup>. The mean age of the 7 reviewed male subjects was 24.1 years (range 17-38). CCFs occurred following penetrating ( $n = 3$ ) or non-penetrating chest injuries ( $n = 4$ ). They presented with chest pain, angina pectoris, palpitation, dyspnea, congestive heart failure and hemoptysis. The origin was the LAD ( $n = 4$ ) and the right coronary artery (RCA) ( $n = 3$ ). The CCFs terminated into the RA ( $n = 1$ ), RV ( $n = 4$ ) and LV ( $n = 2$ ). All 7 reviewed patients were treated surgically. The surgical procedures included ligation and coronary artery bypass grafting, valvular repair and closure of ventricular septal defects. In three patients, reoperation was necessary for a complete repair.

### **Spontaneous fistulas**

Spontaneously occurring: These are CCFs associated with



**Figure 2** Schematic representation of review subjects with congenital and acquired coronary-cameral fistulas. ICD: Implantable cardioverter-defibrillator; PCI: Percutaneous coronary intervention; RF: Radiofrequency.



**Figure 3** Schematic examples of some of the conditions, procedures and attributes involved in the development of (A) acquired traumatic iatrogenic and (B) acquired traumatic accidental coronary-cameral fistulas. A: 1: Surgical scalpel; 2: Radiofrequency cardio-ablation (arrow heads), and transseptal puncture (arrow); 3: ICD lead (arrows); and 4: Pacing leads; B: 1 Soccer game; 2 Boxing; 3: Shrapnel; and 4: Knife. CS: Coronary sinus; ICD: Internal cardioverter defibrillator; IVC: Inferior vena cava; LA: Left atrium; LIPV: Left inferior pulmonary vein; LSPV: Left superior pulmonary vein; RA: Right atrium; RAA: Right atrial appendage; RIPV: Right inferior pulmonary vein; RSPV: Right superior pulmonary vein; RV: Right ventricular; SVC: Superior vena cava.



**Table 1** Fistula characteristics in congenital and acquired coronary cameral fistulas of 243 reviewed subjects

| Aetiology               | Acquired <i>n</i> = 84 (35%)             |                                   |  |                |                                       | Spontaneous <i>n</i> = 12 (14.3%) |
|-------------------------|--|-----------------------------------|--|----------------|---------------------------------------|-----------------------------------|
|                         | Solitary 85%                             |                                   | Traumatic CCFs <i>n</i> = 72 (85.7%)             |                | Accidental CCFs <i>n</i> = 7/72 (10%) |                                   |
|                         | Congenital 65%                           |                                   | Iatrogenic CCFs <i>n</i> = 65/72 (90%)           |                |                                       |                                   |
| Female percentage       | 50%                                      | 63%                               | 20%  | 22%            | 0%                                    | 0%                                |
| Mean age                | 46.2 (18-85)                             | 62.7 (39-85)                      | 61 (40-78)                                       | 50.8 (43-64)   | 24.1 (17-38)                          | 61 (29-75)                        |
| Prevalence/incidence    | 135/159 (85%)                            | 24/159 (15%)                      | 5/65 (8%)  | 25/65 (38%)    | 10%                                   | 14.30%                            |
| Management              | CMM 22%,<br>SL 56%, PTE 22%              | CMM 100%,<br>incidentally ICD     | CMM 11%, PTE 11%,<br>WW 40%, CMM 40%,<br>PTE 20% | CMM 73%        | Surgical repair 100%                  | CMM 17%,<br>SL 58%                |
| Fistula characteristics |  |                                   |  |                |                                       |                                   |
| Origin                  | Proximal segment<br>Any cardiac chambers | Mid- or distal segment<br>LV > RV | Septal perforators<br>LCA or RCA                 | RCA > LAD > Cx | RCA or LAD                            | RCA or LAD                        |
| Termination             | Occasionally                             | Not reported                      | Any cardiac chambers                             | RV             | RV or LV                              | RV or LV                          |
| Spontaneous resolution  | Occasionally                             | Not reported                      | Not reported                                     | High rate      | Not reported                          | 8%                                |

CCFs: Coronary cameral fistulas; CMM: Conservative medical management; EMB: Endomyocardial biopsy; EP: Electrophysiological procedures; ICD: Implantable cardioverter-defibrillator; LA: Left atrium; LAD: Left anterior descending artery; LCA: Left coronary artery; LV: Left ventricle; MI: Myocardial infarction; MMs: Coronary artery-ventricular multiple micro-fistulas; PCI: Percutaneous coronary intervention; PTE: Percutaneous therapeutic embolization; RA: Right atrium; RCA: Right coronary artery; RV: Right ventricle; SL: Surgical ligation; SM: Septal myectomy; WW: Watchful waiting follow-up.

severe atherosclerotic stenotic lesions or myocardial infarction (*n* = 12/84, 14.3%)<sup>[42,44-51]</sup>. Twelve male subjects with a mean age of 61 years (range 29-75) were selected. The RCA<sup>[21]</sup> (*n* = 4) and LCA<sup>[44]</sup> (*n* = 8) participated in the formation of the acquired CCFs. Acquired CCFs (LAD-LV fistula) were noticed following anterior MI<sup>[46]</sup> and complicating neovascularization of mural thrombus formation<sup>[51]</sup>. The right<sup>[47]</sup> (*n* = 3), left ventricular<sup>[48]</sup> (*n* = 5) lumen, right atrium (*n* = 1) and left atrium (*n* = 3) may be the site of cameral termination. Among these patients, spontaneous resolution occurred in (*n* = 1/12, 8%)<sup>[47]</sup>, surgical ligation of the fistula was conducted in (*n* = 7/12, 58%) and CMM was implemented in (*n* = 2/12, 17%). Death was reported in one case<sup>[45]</sup> and the management was not reported in another<sup>[44]</sup>.

## COMMENTS

CCFs encompass a group of infrequently detected solitary or multiple *micro* or *macro* coronary cameral communications, either congenital<sup>[1]</sup> or acquired traumatic subsequent to accidental injuries<sup>[43]</sup>, and iatrogenic secondary to surgical<sup>[3]</sup> or non-surgical interventions<sup>[15,16]</sup> that are increasingly recognized due to material sophistication and wide spread application of non-invasive and invasive angiographic imaging modalities<sup>[2,16,52]</sup>. CCFs may rarely also occur spontaneously after MI<sup>[44]</sup>. CCFs may be subdivided into congenital and acquired types, the former making up the vast majority.

As was found in the current review, 35% of the subjects presented with an acquired type. In 1997, on reviewing the world literature 36% of the fistulas were found to have an acquired etiology<sup>[22]</sup>.

Within this entity of CCFs, each subtype has its own specific characteristics, such as age of the subjects, origin, termination of fistulas or mechanism of injury and its specific treatment modality.

The precise incidence of acquired traumatic accidental CCFs is unknown due to a lack of data and literature has been essentially limited to case reports and small series of patients<sup>[43]</sup>. Acquired traumatic iatrogenic CCFs may occur due to trans-venous<sup>[16,20]</sup> or trans-arterial<sup>[19,26]</sup> endovascular diagnostic (endomyocardial biopsy) or therapeutic procedures (percutaneous coronary intervention and pacemaker implantation)<sup>[20,53]</sup>. In the current era, it is believed that technical developments, material sophistications, procedural refinements and the enhanced gain in experience have resulted in a great reduction or abolishing of acquired traumatic iatrogenic CCFs post percutaneous coronary intervention (PCI) and spontaneously developing post-MI<sup>[53,54]</sup>.

Acquired iatrogenic CCFs may occur after heterogeneous causes of endogenous or exogenous traumas such as sharp<sup>[7,12]</sup> and blunt chest injury. Endogenous surgical or non-surgical trauma, such as baro-trauma after PCI<sup>[19,26,31,55]</sup>, and following permanent endocardial ventricular pacing lead placement<sup>[20]</sup> may cause CCFs. Acquired accidental CCFs develop after non-penetrating<sup>[42]</sup> or penetrating thoracic injuries<sup>[7,56]</sup>. They may also occur after surgical septal myectomy<sup>[3]</sup> and radio-frequency cardio-ablation<sup>[17]</sup>. They are sometimes characterized by the appearance of a novel continuous cardiac murmur or by recurrence of symptoms<sup>[6,9,34]</sup>.

### Traumatic fistulas

**Acquired traumatic iatrogenic CCFs (non-surgical):** secondary to electrophysiological procedures (permanent pacing and implantable cardioverter-defibrillator (ICD) leads, transseptal puncture and radiofrequency cardio-ablation).

**Etiology and incidence:** They formed 12% of the traumatic fistulas. These are very rare complications of permanent pacing and ICD leads, transseptal puncture and electrophysiological procedures that have been observed. Only a few cases have been reported in the literature. Recently, Tamura *et al*<sup>[14]</sup> reported the occurrence of acquired iatrogenic CCFs between the Cx and the RA following transseptal puncture. Surgical<sup>[23,30]</sup> and non-surgical<sup>[17,25]</sup> electro-physiological interventions (*e.g.*, radio-frequency cardio-ablation) may lead to acquired CCFs. The potential risk of coronary vessel lesions during the cardio-ablation is associated with the close relationship between the RCA and Cx to the site of ablation on the atrioventricular annulus. After percutaneous radiofrequency ablation, in the majority of reviewed subjects, the origin of CCFs was the Cx<sup>[23,30,57]</sup>.

**Mechanism:** Acquired traumatic iatrogenic CCFs develop secondary to mechanical and thermal injuries. The application of radiofrequency cardio-ablation may be complicated with the occurrence of a communication between an adjacent coronary artery and a cardiac chamber which is thought to result from thermal and mechanical injury<sup>[23,14,25]</sup>. Most of the reported acquired CCFs have

their exit to the RV, but outflow to the LA<sup>[30]</sup> and LV<sup>[17]</sup> have also been described.

**Management and prognosis:** Pharmacological or supportive therapy is sufficient to relieve symptoms in these acquired fistulas, and spontaneous resolution occurring after 9-10 mo has been reported<sup>[23,17]</sup>. In the current review, regardless of their termination site, they were all treated medically except two in whom spontaneous resolution occurred. Conservative management was advised for acquired CCFs entering the RV complicating endocardial active fixation of an ICD lead<sup>[16]</sup> and of permanent ventricular pacing leads<sup>[20]</sup>.

### Acquired traumatic iatrogenic CCFs secondary to baro-trauma

**Etiology and incidence:** They formed 11% of the iatrogenic fistulas. These coronary-cameral fistulas occur subsequent to baro-trauma (non-surgical therapeutic procedures). These complications have infrequently been reported in Asian<sup>[31]</sup> and Caucasian patients<sup>[26]</sup>. Subsequent to PTCA procedures, fistulous communications between the native left coronary artery and RV<sup>[19]</sup> or LV<sup>[26]</sup> have been reported. Moreover, these complications have been described after PTCA of a distal anastomosis of a totally occluded venous graft<sup>[31]</sup>. The donor artery was the LAD in most of the cases.

**Mechanism:** Several mechanisms are responsible, alone or together. It is thought to be based on mechanical injury to the vessel wall in the vicinity of a cardiac chamber, resulting in a direct communication. Moreover, they may occur due to subsequent rupture of a false aneurysm following PTCA, besides inappropriate wire tracking, artery-balloon size mismatch and involvement of calcified lesions with vessel wall cracking and curved segment<sup>[19,26,27,31,55]</sup>.

Earlier reports documented acquired traumatic iatrogenic CCFs caused by baro-trauma that were associated with a high mortality rate (29%, 2 of the 7 reported cases in literature) which were published in the eighties and nineties. In 1996, Karim<sup>[55]</sup> reported the first case of an acquired iatrogenic fistula between RCA and RA, complicating stent placement in a tight lesion, after which it was rarely reported following vessel rupture after coronary stenting<sup>[27]</sup> or subsequent to coronary artery pseudo-aneurysm late post-stenting<sup>[53]</sup>. Not only acquired CCFs could occur between a coronary artery and a cardiac chamber following PCI procedure, but also it may develop after PCI to saphenous vein graft which was treated by a covered stent<sup>[58]</sup>.

**Management and prognosis:** As the shunt magnitude was trivial without hemodynamic consequences and spontaneous closure was observed, CMM was commonly employed. Complete and spontaneous resolution of an acquired fistula complicating PCI occurring between a branch of the RCA and RV has been documented<sup>[59]</sup>. In the current era, such complications following PCI proce-

dures are rarely reported<sup>[53,54]</sup>.

### **Acquired iatrogenic CCFs following endomyocardial biopsy in the heart transplant population**

**Etiology and incidence:** They formed 38% of the iatrogenic fistulas. The reported angiographic prevalence varies from 2.8% to 23.2%<sup>[13,15,60-63]</sup>. Two decades ago, Sauer *et al*<sup>[64]</sup> reported an incidence of 80%. The majority of these CCFs have their origin from the RCA (52%), followed by the LAD (43%) and finally by the Cx (5%)<sup>[15]</sup>. They nearly all terminate into the RV<sup>[13,32,60,62,65]</sup>. Rarely, repeated endomyocardial biopsy induced a fistula from an atrial branch of the Cx to the LA<sup>[61]</sup>.

**Mechanism:** They occur subsequent to arterial trauma with neovascularization during the phase of granulation and tissue organization at the biopsy site following frequent and repeated RV endomyocardial biopsies and in relation to the applied surgical techniques of cardiac implantation<sup>[13,15,61]</sup>.

**Management and prognosis:** Spontaneous disappearance is a more common occurrence in biopsy-related CCFs. Spontaneous closure is reported to occur in post-biopsy CCFs in heart transplant patients with an estimated rate of 27%<sup>[15]</sup>. The majority demonstrate a benign evolution and non-surgical management is usually the treatment of choice due to lack of severe symptoms and small shunt magnitude<sup>[13,15,52]</sup>. However, in some symptomatic patients, closure of the fistula may be obtained surgically<sup>[32]</sup> or achieved by placement of a covered stent<sup>[65]</sup> or a detachable balloon<sup>[66]</sup> using percutaneous catheter techniques<sup>[65,66]</sup>.

### **Surgical procedures**

Acquired traumatic iatrogenic CCFs following surgical septal myectomy

**Etiology and prevalence:** They formed 31% of the iatrogenic fistulas. After surgical septal myectomy for hypertrophic cardiomyopathy, CCFs have been reported<sup>[3,18,37-40]</sup>. Asymptomatic acquired CCFs draining into the LV following surgical intervention may occur after SM alone<sup>[39]</sup> or after combined aortic valve replacement with SM for HCM<sup>[18]</sup>. The prevalence of acquired post-SM CCFs varies from 19% to 23%<sup>[3,37]</sup>.

**Mechanism:** The proposed mechanism of fistula formation after surgical SM for treatment of hypertrophic cardiomyopathy: It is postulated that they originate secondary to injury of one or more septal perforator branches of the left anterior descending coronary artery, resulting in a direct communication between the lacerated vessel and the left ventricular cavity<sup>[3,37-39]</sup>.

**Management and prognosis:** Surgical or percutaneous interventions were rarely needed to close the acquired fistula in a symptomatic patient since spontaneous clo-

sure is reported to be very high, accounting for 78%<sup>[3]</sup>. With the introduction of alcohol septal ablation in 1994, acquired CCFs are currently not seen after percutaneous procedures for treatment of HCM with an outflow gradient<sup>[67-69]</sup>.

### **After other cardiac surgical procedures (coronary artery bypass grafting, valvular repair and surgery for congenital heart anomalies)**

**Etiology and incidence:** These CCFs occur after aortic or mitral valvular replacement<sup>[34,35]</sup> or surgical procedures for congenital cardiac anomalies. Chiu *et al*<sup>[2]</sup> reported an incidence of 0.44% following surgery for tetralogy of Fallot, ventricular septal defect (VSD), double chamber RV and transposition of the great arteries with VSD. In the current review, the acquired traumatic iatrogenic fistulas ( $n = 5/65$ , 8%) developed subsequent to other cardiac surgical procedures.

**Clinical presentation:** The majority was asymptomatic but recurrence of congestive heart failure was reported. Audible continuous murmur or continuous Doppler flow on echocardiography was prevalent.

**Mechanism:** The postulated mechanisms were subsequent to right atrial artery injured at the site of access for cardiopulmonary bypass, damage to the precapillary arteriole of the circle of Vieussens<sup>[2]</sup>, injury to the RCA at reoperation<sup>[35]</sup> or possibly secondary to hypoxia-induced angiogenesis<sup>[36]</sup>. Chiu *et al*<sup>[2]</sup> identified risk factors for acquired CCFs as re-do procedures and RV myocardial resection of hypertrophic muscle bundles in ventricular septal defect.

**Management and prognosis:** Watchful waiting follow-up and CMM were the strategies in all except a case described in 2004, by Mestre Barceló *et al*<sup>[34]</sup> who performed percutaneous occlusion using coated stent of an acquired iatrogenic CCF between LAD and RV.

### **Acquired traumatic accidental CCFs**

**Etiology and incidence:** They formed 10% of the acquired traumatic fistulas. They occur secondary to penetrating and non-penetrating thoracic injuries and are infrequently reported<sup>[43,10]</sup>. The mean age was 24.1 years, which was found to be lower than the patients presented with congenital solitary CCFs (46.2) or congenital coronary artery left ventricular multiple micro-fistulas (62.7)<sup>[1]</sup>.

**Clinical presentation:** Three presented with sharp and four with blunt chest traumas. Dyspnea, angina pectoris, chest pain, palpitation, congestive heart failure and hemoptysis were reported. Machinery cardiac murmur was audible in four, diastolic in one and holosystolic murmur in two of the patients.

**Mechanism:** Myocardial contusion, laceration and tissue damage in blunt chest trauma and secondary to transfer



of kinetic energy in case of gunshot wounds associated with penetrating and non-penetrating injuries were the suggested mechanisms.

**Management and prognosis:** The management of acquired accidental CCFs, whether subsequent to penetrating or non-penetrating injury, is always an emergent surgical intervention. In 1965, Jones and Jahnke described the first surgical repair of a traumatic CCFs<sup>[10]</sup>.

As early as 1975, a few papers were published regarding CCFs, with twelve traumatic CCFs reported in the world's literature; the penetrating injuries were prevalent<sup>[70]</sup>. In 2000, Hancock Friesen *et al*<sup>[43]</sup> reviewed 28 patients, published between 1958-1998, with acquired accidental CCFs and added one of their own. All were surgically repaired. Origin from the RCA was twice as common as origin from the LAD. Five of them had blunt chest trauma and 24 were presented with sharp thoracic injury. Termination into right-sided atrial or ventricular cardiac chambers was prevalent. The first reported successful repair of a traumatic CCF was in 1965 by Jones *et al*<sup>[10]</sup>. Blunt trauma to the anterior chest wall may cause laceration of the RCA<sup>[42]</sup> or LAD<sup>[6,28]</sup>, associated with or without myocardial contusion. Regardless of their origin, they usually communicate with the RV or RA due to traumas directed to the anterior chest wall<sup>[6,28,42,43]</sup> but they sometimes communicate with the LV cavity<sup>[41]</sup>. These CCFs usually manifest itself by the presentation of a new continuous cardiac murmur<sup>[71]</sup>. Early intervention was recommended, applying surgical ligation with<sup>[72]</sup> or without a coronary artery bypass graft (CABG) and direct repair from within a recipient chamber<sup>[8,43]</sup>. In the review of Haas *et al*<sup>[9]</sup>, surgical repair was performed in all 19 patients with acquired traumatic accidental CCFs resulting from penetrating and non-penetrating chest injuries. Of these, 5 required reoperation due to recurrence of murmur after an interval varying from 24 h to 7 mo<sup>[8]</sup>. In our current literature review, the origin was equally distributed between the LAD and the RCA. All seven reviewed patients were treated surgically. Reoperation for complete repair was needed in three subjects. No spontaneous closure was observed among the reviewed subjects with acquired traumatic accidental CCFs.

### Spontaneous CCFs

Spontaneously acquired CCFs as a result of severe stenotic lesions or myocardial infarction have been reported<sup>[4,21,29]</sup>.

**Etiology and incidence:** They formed 14.3% (12/84) of the acquired fistulas. In the last century, reports have rarely been published incriminating myocardial ischemia or infarction for the occurrence of spontaneous CCFs<sup>[4,21]</sup>. Currently, such complications are rarely published. Two reports were cited in the literature of acquired CCFs secondary to anterior MI with a fistula entering into the RV<sup>[44]</sup> or LV<sup>[45]</sup>. Acquired CCFs were reported after anterior<sup>[44,45,48]</sup>, inferior<sup>[4,21]</sup> or posterior MI<sup>[47,50]</sup>. They may also be associated with inferior<sup>[49]</sup> or anterior myocardial ischemia<sup>[73]</sup>.

**Mechanism:** It has been postulated that an aberrant

pathway of newly developed collaterals, neo-vascularization of left ventricular mural thrombus formation post-MI, ruptures of localized micro-necrosis subsequent to destruction of the microvasculature or by reopening of the Thebesian vessels probably may lead to the fistula formation into the lumen of a cardiac chamber<sup>[4,45,47-50]</sup>. Furthermore, it has been suggested that as collaterals lose their way, acquired fistulas may develop following MI or in association with severe atherosclerotic obstructive lesions<sup>[74]</sup>. In contrast to congenital CCFs between the LAD and LV which may cause angina pectoris secondary to myocardial ischemia documented with myocardial perfusion test<sup>[75]</sup>, acquired CCFs may develop and emerge secondary to MI or severe atherosclerotic lesions. The precise mechanisms by which congenital or acquired CCFs could enhance atherosclerosis are not yet known.

**Management and prognosis:** In the current review, the majority of patients (58%) were treated surgically. Angiographically documented spontaneous closure was seen in 8% and CMM was the treatment modality in 17% of subjects. One death (8%) secondary to intractable congestive heart failure occurred in a 63 year old Asian patient who developed CCF between LCA and LV following anterior MI.

### Patients considered for the potential diagnosis of acquired CCFs:

Although acquired CCFs are incidentally detected on routine CAG, the diagnosis should be expected, with a high index of suspicion, in subjects who develop new symptoms or show recurrence of symptoms or develop a novel cardiac murmur. Treatment is reserved for symptomatic patients with a hemodynamically significant shunt. Management of asymptomatic patients is controversial. In contrast to congenital CCFs, high spontaneous disappearance of the acquired CCFs has been reported. Watchful waiting and supportive medical management may be advocated in the majority of acquired CCFs. With amenable fistulous morphological anatomy, percutaneous therapeutic embolization or surgical closure may be applied. Acquired traumatic accidental CCFs are indications for emergent surgical procedures. Furthermore, indications for surgery, as suggested by Konno *et al*<sup>[76]</sup> and others for congenital types, are: large L-R shunt > 30%, ischemia or volume overload, pulmonary hypertension or congestive heart failure, the presence of an aneurysm, and infective endocarditis<sup>[77,78]</sup>.

## CONCLUSION

Acquired CCFs are infrequent coronary artery anomalies which are often asymptomatic and found incidentally on routine coronary catheter angiography. The majority of acquired CCFs are secondary to iatrogenic trauma resulting from various interventional surgical or non-surgical endovascular or extravascular procedures. Acquired traumatic accidental CCFs are associated with a younger age (between second and fourth decade of life) compared with congenital fistulas<sup>[1]</sup> or acquired iatrogenic



CCFs (fifth decade of life). They usually originate from the RCA or LAD and all end in the RV. Early surgical intervention is always indicated in these subjects. The termination site of acquired iatrogenic CCFs resulting from endomyocardial biopsy in post-heart transplantation subjects is nearly always the RV associated with reported high spontaneous resolution. The prevalence of acquired post-SM CCFs is also high and they possess the highest rate of spontaneous disappearance.

## ACKNOWLEDGMENTS

During the preparation of the manuscript, the assistance of the librarian, Mrs. A. Geerdink, and Mr. D. Maas of hospital group Twente is gratefully acknowledged. The authors thank Prof. Dr. Clemens von Birgelen, Department of Cardiology, Thoraxcentrum Twente, Medisch Spectrum Twente, Enschede, the Netherlands for his intellectual suggestions for the manuscript.

## REFERENCES

- Said SA, Schiphorst RH, Derksen R, Wagenaar L. Coronary-cameral fistulas in adults (first of two parts). *World J Cardiol* 2013; **5**: 329-336 [PMID: 24109496]
- Chiu SN, Wu MH, Lin MT, Wu ET, Wang JK, Lue HC. Acquired coronary artery fistula after open heart surgery for congenital heart disease. *Int J Cardiol* 2005; **103**: 187-192 [PMID: 16080979 DOI: 10.1016/j.ijcard.2004.09.005]
- Sgalambro A, Olivotto I, Rossi A, Nistri S, Baldini K, Baldi M, Stefano P, Antonucci D, Garbini F, Cecchi F, Yacoub MH. Prevalence and clinical significance of acquired left coronary artery fistulas after surgical myectomy in patients with hypertrophic cardiomyopathy. *J Thorac Cardiovasc Surg* 2010; **140**: 1046-1052 [PMID: 20471659 DOI: 10.1016/j.jtcvs.2010.02.020]
- Ryan C, Gertz EW. Fistula from coronary arteries to left ventricle after myocardial infarction. *Br Heart J* 1977; **39**: 1147-1149 [PMID: 911568 DOI: 10.1136/hrt.39.10.1147]
- Beck CS. Two cardiac compression triads. *JAMA* 1935; **104**: 714-716 [DOI: 10.1001/jama.1935.02760090018005]
- Lowe JE, Adams DH, Cummings RG, Wesley RL, Phillips HR. The natural history and recommended management of patients with traumatic coronary artery fistulas. *Ann Thorac Surg* 1983; **36**: 295-305 [PMID: 6615068 DOI: 10.1016/S0003-4975(10)60132-4]
- Forker AD, Morgan JR. Acquired coronary artery fistula from nonpenetrating chest injury. *JAMA* 1971; **215**: 289-291 [PMID:4923342 DOI: 10.1001/jama.1971.03180150071018]
- Cheng TO, Adkins PC. Traumatic aneurysm of left anterior descending coronary artery with fistulous opening into left ventricle and left ventricular aneurysm after stab wound of chest. Report of case with successful surgical repair. *Am J Cardiol* 1973; **31**: 384-390 [PMID: 4687853 DOI: 10.1016/0002-9149(73)90273-7]
- Haas GE, Parr GV, Trout RG, Hargrove WC. Traumatic coronary artery fistula. *J Trauma* 1986; **26**: 854-857 [PMID: 3489105 DOI: 10.1097/00005373-198609000-00015]
- Jones RC, Jahnke EJ. Coronary artery-atrioventricular fistula and ventricular septal defect due to penetrating wound of the heart. *Circulation* 1965; **32**: 995-1000 [PMID: 5846104 DOI: 10.1161/01.CIR.32.6.995]
- Heller RF, Rahimtoola SH, Ehsani A, Johnson S, Boyd DR, Tatooles CJ, Loeb HS, Rosen KR. Cardiac complications. Results of penetrating chest wounds involving the heart. *Arch Intern Med* 1974; **134**: 491-496 [PMID: 4850883 DOI: 10.1001/archinte.134.3.491]
- Tsagaris TJ, Bustamante RA. Coronary arteriovenous fistula and myocardial infarction due to trauma. *Am J Cardiol* 1966; **18**: 777-780 [DOI: 10.1016/0002-9149(66)90098-1]
- Fitchett DH, Forbes C, Guerraty AJ. Repeated endomyocardial biopsy causing coronary arterial-right ventricular fistula after cardiac transplantation. *Am J Cardiol* 1988; **62**: 829-831 [PMID: 3048074 DOI: 10.1016/0002-9149(88)91237-4]
- Tamura A, Naono S, Kadota J. A fistula from the coronary artery into the right atrium caused by transeptal puncture. *Eur Heart J* 2008; **29**: 2472 [PMID: 18436558 DOI: 10.1093/eurheartj/ehn175]
- Sandhu JS, Uretsky BF, Zerbe TR, Goldsmith AS, Reddy PS, Kormos RL, Griffith BP, Hardesty RL. Coronary artery fistula in the heart transplant patient. A potential complication of endomyocardial biopsy. *Circulation* 1989; **79**: 350-356 [PMID: 2644055 DOI: 10.1161/01.CIR.79.2.350]
- Härle T, Reimers J, Schaumann A. Coronary artery fistula caused by an endocardial active fixation ICD lead. *Europace* 2008; **10**: 458 [PMID: 18292123 DOI: 10.1093/europace/eun034]
- Shalaby A, Refaat M, Lacomis JM, Amidi M. Iatrogenic coronary-cameral fistula after left ventricular radiofrequency ablation. *Heart Rhythm* 2009; **6**: 720-721 [PMID: 18848504 DOI: 10.1016/j.hrthm.2008.08.013]
- López-Candales A, Kumar V. Coronary artery to left ventricle fistula. *Cardiovasc Ultrasound* 2005; **3**: 35 [PMID: 16277656 DOI: 10.1186/1476-7120-3-35]
- Meng RL, Harlan JL. Left anterior descending coronary artery-right ventricle fistula complicating percutaneous transluminal angioplasty. *J Thorac Cardiovasc Surg* 1985; **90**: 387-390 [PMID: 3162067]
- Saeian K, Vellinga T, Troup P, Wetherbee J. Coronary artery fistula formation secondary to permanent pacemaker placement. *Chest* 1991; **99**: 780-781 [PMID: 1995248 DOI: 10.1378/chest.99.3.780]
- Chapman RW, Watkins J. Rupture of right coronary artery aneurysm into the right atrium. *Br Heart J* 1978; **40**: 938-939 [PMID: 687496 DOI: 10.1136/hrt.40.8.938]
- Said SA, el Gamal MI, van der Werf T. Coronary arteriovenous fistulas: collective review and management of six new cases—changing etiology, presentation, and treatment strategy. *Clin Cardiol* 1997; **20**: 748-752 [PMID: 9294664 DOI: 10.1002/clc.4960200907]
- Nguyen-Do P, Bannon P, Leung DY. Coronary artery to the left atrial fistula after resection of atrial appendages. *Ann Thorac Surg* 2004; **78**: e26-e27 [PMID: 15276584 DOI: 10.1016/j.athoracsur.2003.10.117]
- de Marchena E, Musial B, Wozniak P, Schob A, Chakko S, Kessler KM. Iatrogenic internal mammary artery to coronary vein fistula. *Chest* 1990; **97**: 251-252 [PMID: 2295253 DOI: 10.1378/chest.97.1.251]
- Wieczorek M, Braun P, Schoels W. Acquired arteriovenous fistula and chronic occlusion of the left anterior descending coronary artery in a patient with previous ablation of a left-sided accessory pathway. *Pacing Clin Electrophysiol* 2005; **28**: 874-876 [PMID: 16105019 DOI: 10.1111/j.1540-8159.2005.00170.x]
- Iannone LA, Iannone DP. Iatrogenic left coronary artery fistula-to-left ventricle following PTCA: a previously unreported complication with nonsurgical management. *Am Heart J* 1990; **120**: 1215-1217 [PMID: 2239674 DOI: 10.1016/0002-8703(90)90139-O]
- Korpas D, Acevedo C, Lindsey RL, Gradman AH. Left anterior descending coronary artery to right ventricular fistula complicating coronary stenting. *J Invasive Cardiol* 2002; **14**: 41-43 [PMID: 11773695]
- Zamani J, Amirghofran AA, Moaref AR, Afifi S, Rezaian GR. Posttraumatic coronary artery-right ventricular fistula with multiple ventricular septal defects. *J Card Surg* 2010; **25**: 670-671 [PMID: 20412356 DOI: 10.1111/j.1540-8191.2010.01032.x]
- King SB, Schoonmaker FW. Coronary artery to left atrial fistula in association with severe atherosclerosis and mitral stenosis: report of surgical repair. *Chest* 1975; **67**: 361-363 [PMID: 1112134 DOI: 10.1378/chest.67.3.361]
- Wada T, Ohara T, Nakatani S, Sumita Y, Kobayashi J, Kitakaze M. A case of coronary artery fistula between a coronary artery and the left atrium following maze procedure. *J Am Soc Echo-*

- cardiogr* 2009; **22**: 323.e3-323.e6 [PMID: 19153027 DOI: 10.1016/j.jecho.2008.12.019]
- 31 **el-Omar MM**, Hargreaves MR, Venkataraman A, Been M. Coronary ventricular fistula as a complication of PTCA: a case report and literature review. *Int J Cardiol* 1995; **51**: 113-116 [PMID: 8522405 DOI: 10.1016/0167-5273(95)02417-U]
- 32 **Uchida N**, Baudet E, Roques X, Laborde N, Billes MA. Surgical experience of coronary artery-right ventricular fistula in a heart transplant patient. *Eur J Cardiothorac Surg* 1995; **9**: 106-108 [PMID: 7748569 DOI: 10.1016/S1010-7940(05)80030-2]
- 33 **Vermeulen T**, Haine S, Paelinck BP, Rodrigus IE, Vrints CJ, Conraads VM. Coronary artery-pulmonary artery fistula in a heart-transplanted patient. *Eur J Echocardiogr* 2010; **11**: 80-81 [PMID: 19749198 DOI: 10.1093/ejehocard/jep113]
- 34 **Mestre Barceló JL**, Salido Tahoces L, del Río del Busto A, Camino López A, Moya Mur JL, Pey Illera J. [Closure of an iatrogenic coronary artery fistula with a PTFE-coated stent]. *Rev Esp Cardiol* 2004; **57**: 699-701 [PMID: 15274856]
- 35 **Lee RT**, Mudge GH, Colucci WS. Coronary artery fistula after mitral valve surgery. *Am Heart J* 1988; **115**: 1128-1130 [PMID: 3364344 DOI: 10.1016/0002-8703(88)90089-0]
- 36 **Rudraiah L**, Dhar G, Thatai D. Acquired coronary cameral fistula—a report of two cases. *Int J Cardiol* 2008; **123**: e40-e42 [PMID: 17303268 DOI: 10.1016/j.ijcard.2006.11.117]
- 37 **Chenzbraun A**, Pinto FJ, Meyer B, Stinson EB, Popp RL. Frequency of acquired coronary-cameral fistula after ventricular septal myectomy in hypertrophic cardiomyopathy. *Am J Cardiol* 1993; **71**: 1244-1246 [PMID: 8480661]
- 38 **Awasthi A**, Wormer D, Heggum PS, Obeid A. Long-term follow-up of acquired coronary artery fistula after septal myectomy for hypertrophic cardiomyopathy. *J Am Soc Echocardiogr* 2002; **15**: 1104-1107 [PMID: 12373254 DOI: 10.1067/mje.2002.122632]
- 39 **Choi YJ**, You CW, Park MK, Park JI, Kwon SU, Lee SC, Lee HJ, Park SW. Spontaneous closure of iatrogenic coronary artery fistula to left ventricle after septal myectomy for hypertrophic obstructive cardiomyopathy. *J Korean Med Sci* 2006; **21**: 1111-1114 [PMID: 17179697 DOI: 10.3346/jkms.2006.21.6.1111]
- 40 **Garber PJ**, Hussain F, Koenig JK, Maycher B, Jassal DS. Multimodality imaging of a coronary artery fistula after septal myectomy in hypertrophic cardiomyopathy. *J Am Coll Cardiol* 2011; **57**: e95 [PMID: 21349395 DOI: 10.1016/j.jacc.2010.04.077]
- 41 **Renzulli A**, Wren C, Hilton CJ. Coronary artery-left ventricular fistula and multiple ventricular septal defects due to blunt chest trauma. *Thorax* 1989; **44**: 1055-1056 [PMID: 2617447 DOI: 10.1136/thx.44.12.1055]
- 42 **Lynn RB**, Fay JE. Post-traumatic cardiocoronary fistula. *Can J Surg* 1971; **14**: 335-336 [PMID: 5113538]
- 43 **Hancock Friesen C**, Howlett JG, Ross DB. Traumatic coronary artery fistula management. *Ann Thorac Surg* 2000; **69**: 1973-1982 [PMID: 10892970 DOI: 10.1016/S0003-4975(00)01207-8]
- 44 **Radomski M**, Kubica J, Sukiennik A, Wojtowicz A, Lewicka-Nowak E, Dorniak W, Skarzyński P, Nowak A, Ciećwierz D, Rynkiewicz A, Świątecka G. Left anterior descending coronary artery to the right ventricle fistula: an unusual complication of myocardial infarction. Case report. *Folia Cardiol* 1999; **6**: 399-403
- 45 **Shimizu M**, Yoshio H, Ino H, Takeda R, Okada Y. Histopathologic findings of a left coronary artery fistula to the left ventricle after myocardial infarction. *Cardiology Elderly* 1993; **1**: 335-336
- 46 **Yu R**, Sharma B, Franciosa JA. Acquired coronary artery fistula to the left ventricle after acute myocardial infarction. *Am J Cardiol* 1986; **58**: 557-558 [PMID: 3751920 DOI: 10.1016/0002-9149(86)9003-6]
- 47 **Schanzenbächer P**, Bauersachs J. Acquired right coronary artery fistula draining to the right ventricle: angiographic documentation of first appearance following reperfusion after acute myocardial infarction, with subsequent spontaneous closure. *Heart* 2003; **89**: e22 [PMID: 12860888 DOI: 10.1136/heart.89.8.e22]
- 48 **Lucca MJ**, Tomlinson GC. Acquired coronary artery fistula: a sign of mural thrombus. *Cathet Cardiovasc Diagn* 1988; **15**: 273-276 [PMID: 2465831 DOI: 10.1002/ccd.1810150413]
- 49 **Ray SG**, Cowan MD, Kennedy JA. Spontaneously acquired fistula from the right coronary artery to the right ventricular cavity. *Br Heart J* 1992; **67**: 323-324 [PMID: 1389709 DOI: 10.1136/hrt.67.4.323]
- 50 **Lee KM**, Pichard AD, Lindsay J Jr. Acquired coronary artery-left ventricular pseudoaneurysm fistula after myocardial infarction. *Am J Cardiol* 1989; **64**: 824-825 [PMID: 2801541 DOI: 10.1016/0002-9149(89)90778-9]
- 51 **Cipriano PR**, Guthaner DF. Organized left atrial mural thrombus demonstrated by coronary angiography. *Am Heart J* 1978; **96**: 166-169 [PMID: 676977]
- 52 **Jacob S**, Feigenbaum H. Acquired coronary-cameral fistula. *Clin Cardiol* 2009; **32**: E70 [PMID: 19610122 DOI: 10.1002/clc.20507]
- 53 **Hagau AM**, Dudea SM, Hagau R, Hagau N. Large coronary pseudoaneurysm with pulmonary artery fistula, six months after left main trunk stenting with paclitaxel-eluting stent. *Med Ultrason* 2013; **15**: 59-62 [PMID: 23486626 DOI: 10.11152/mu.2013.2066.151.ah1lcp2]
- 54 **Ahmed TAN**. Innovative therapies for optimizing outcomes of coronary artery disease. Thesis. Leiden: LUMC, 2011
- 55 **Karim MA**. Coronary artery aneurysmal fistula: a late complication of stent deployment. *Int J Cardiol* 1996; **57**: 207-209 [PMID: 9024907 DOI: 10.1016/S0167-5273(96)02809-4]
- 56 **Lemos AE**, Araújo AL, Belém Lde S, Mejia JA, Cruz A, Evangelista NL, Oliveira LS. Traumatic fistula between the right coronary artery and right atrial chamber. *Arq Bras Cardiol* 2007; **88**: e66-e67 [PMID: 17533462]
- 57 **Mabo P**, Le Breton H, De Place C, Daubert C. Asymptomatic pseudoaneurysm of the left ventricle and coronary artery fistula after closed-chest ablation of an accessory pathway. *Am Heart J* 1992; **124**: 1637-1639 [PMID: 1462930 DOI: 10.1016/0002-8703(92)90089-E]
- 58 **El Hosienny A**, Hui W. Fistula between right coronary artery vein graft and right atrium as an immediate complication of percutaneous coronary intervention. *Catheter Cardiovasc Interv* 2012; **80**: 71-74 [PMID: 22234898 DOI: 10.1002/ccd.23371]
- 59 **Diego-Nieto A**, Cuellas-Ramón C, Pérez de Prado A, Fernández-Vázquez F. [Iatrogenic coronary-cameral fistula after percutaneous intervention on the right coronary artery]. *Rev Esp Cardiol* 2008; **61**: 434-435 [PMID: 18405529 DOI: 10.1157/13117741]
- 60 **Martí V**, Bailén JL, Augé JM, Bordes R, Crexells C. [Coronary fistula to the right ventricle in heart transplant patients as a complication of repeated endomyocardial biopsies]. *Rev Esp Cardiol* 1991; **44**: 320-323 [PMID: 1852961]
- 61 **Gascuña R**, de Lombera F, Fernández S, Santos M, Delgado J, Escribano P, Gómez MA. Left circumflex coronary artery-to-left atrium fistulas detected by transesophageal echocardiography in heart transplant recipients. *Echocardiography* 2000; **17**: 443-445 [PMID: 10979018 DOI: 10.1111/j.1540-8175.2000.tb01161.x]
- 62 **Saraiva F**, Matos V, Gonçalves L, Antunes M, Providência LA. Complications of endomyocardial biopsy in heart transplant patients: a retrospective study of 2117 consecutive procedures. *Transplant Proc* 2011; **43**: 1908-1912 [PMID: 21693299 DOI: 10.1016/j.transproceed.2011.03.010]
- 63 **Gasser S**, Gasser R, Bareza N, Klein W. Iatrogenic coronary fistula in post transplant patients: pathogenesis, clinical features and therapy. *J Clin Basic Cardiol* 2003; **6**: 19-21
- 64 **Sauer HU**, Regitz V, Thierstein T, Schüler S, Warnecke H, Hetzer R, Fleck E. [Coronary fistulas—high prevalence in patients with heart transplantation]. *Herz* 1991; **16**: 46-54 [PMID: 2026383]
- 65 **Lee CH**, Lemos PA, Serruys PW. Acquired coronary artery fistula leading to acute myocardial infarction after endomyocardial biopsy. *Heart* 2003; **89**: 495 [PMID: 12695449 DOI: 10.1136/heart.89.5.495]
- 66 **Hartog JM**, van den Brand M, Pieterman H, di Mario C. Closure of a coronary cameral fistula following endomyocardial biopsies in a cardiac transplant patient with a detachable balloon. *Cathet Cardiovasc Diagn* 1993; **30**: 156-159 [PMID: 8221871 DOI: 10.1002/ccd.1810300215]

- 67 **Khouzam RN**, Naidu SS. Alcohol septal ablation for symptomatic hypertrophic obstructive cardiomyopathy in patients with prior coronary revascularization. *J Invasive Cardiol* 2010; **22**: E220-E224 [PMID: 21127375]
- 68 **Lyne JC**, Kilpatrick T, Duncan A, Knight CJ, Sigwart U, Fox KM. Long-term follow-up of the first patients to undergo transcatheter alcohol septal ablation. *Cardiology* 2010; **116**: 168-173 [PMID: 20616549 DOI: 10.1159/000318307]
- 69 **Kovacic JC**, Khanna D, Kaplish D, Karajgikar R, Sharma SK, Kini A. Safety and efficacy of alcohol septal ablation in patients with symptomatic concentric left ventricular hypertrophy and outflow tract obstruction. *J Invasive Cardiol* 2010; **22**: 586-591 [PMID: 21127363]
- 70 **Sutherland RD**, Gholston DE, Gulde RE, Martinez HE. Traumatic fistula between left anterior descending coronary artery and right ventricle. Case report with successful surgical repair. *J Thorac Cardiovasc Surg* 1975; **70**: 692-695 [PMID: 1177482]
- 71 **Allen RP**, Liedtke AJ. The role of coronary artery injury and perfusion in the development of cardiac contusion secondary to nonpenetrating chest trauma. *J Trauma* 1979; **19**: 153-156 [PMID: 458879 DOI: 10.1097/00005373-197903000-00004]
- 72 **Wańczura P**, Stecko W, Kukla P, Kuźniar J. [A continuous murmur in female patient after traffic injury]. *Kardiol Pol* 2012; **70**: 1283-1285 [PMID: 23264249]
- 73 **Sibille L**, Boudousq V, Soullier C, Rossi M, Mariano-Goulart D. Tc-99m tetrofosmin SPECT in coronary cameral fistula. *Clin Nucl Med* 2009; **34**: 473-474 [PMID: 19542962 DOI: 10.1097/RLU.0b013e3181a7cfa2]
- 74 **Said SA**, van der Werf T. Acquired coronary cameral fistulas: are these collaterals losing their destination? *Clin Cardiol* 1999; **22**: 297-302 [PMID: 10198740 DOI: 10.1002/clc.4960220409]
- 75 **Sengul C**, Ciftci R, Ertem FU, Cevik C. Coronary cameral fistula: A rare cause of coronary ischemia. *Ach latr* 2012; **31**: 159-161
- 76 **Konno S**, Endo M. [Congenital coronary artery diseases]. *Kokyu To Junkan* 1973; **21**: 397-409 [PMID: 4580425]
- 77 **Sethuratnam R**, Srinivasan B, Menon A, Anbarasu M, Pillai RS, Dhruv T, Davidson Y. Unusual presentation of a coronary cameral fistula. *Ind J Thorac Cardiovasc Surg* 2007; **23**: 28-30 [DOI: 10.1007/s12055-007-0006-9]
- 78 **Chiu CZ**, Shyu KG, Cheng JJ, Lin SC, Lee SH, Hung HF, Liou JY. Angiographic and clinical manifestations of coronary fistulas in Chinese people: 15-year experience. *Circ J* 2008; **72**: 1242-1248 [PMID: 18654007 DOI: 10.1253/circj.72.1242]

**P- Reviewers:** Kounis GN,

Panduranga P, Raja SG, Rognoni A, Ye YC

**S- Editor:** Wen LL **L- Editor:** Roemmele A **E- Editor:** Liu XM







百世登

**Baishideng**®

Published by **Baishideng Publishing Group Co., Limited**

Flat C, 23/F., Lucky Plaza,

315-321 Lockhart Road, Wan Chai, Hong Kong, China

Fax: +852-65557188

Telephone: +852-31779906

E-mail: [bpgoffice@wjgnet.com](mailto:bpgoffice@wjgnet.com)

<http://www.wjgnet.com>

