

## Expression of Cyclooxygenase-2 and Bcl-2 in Human Gastric Adenomas

Jee Hyun Park, M.D., Kyung Hee Kang, M.D.<sup>2</sup>, Se Hwan Kim, M.D.<sup>2</sup>,  
Jong Hyup Lee, M.D.<sup>2</sup>, Chang Min Cho, M.D.<sup>2</sup>, Young Oh Kweon, M.D.<sup>2</sup>,  
Sung Kook Kim, M.D.<sup>2</sup>, Yong Hwan Choi, M.D.<sup>2</sup>,  
Han Ik Bae, M.D.<sup>3</sup> and Mi Sung Kim<sup>3</sup>

*Department of Internal Medicine, Kumi Cha Medical Center, Gumi, Korea; Departments of Internal Medicine<sup>2</sup> and Pathology<sup>3</sup>, Kyungpook National University School of Medicine, Daegu, Korea*

---

**Background** : Cyclooxygenase (COX)-2 is the rate-limiting enzyme in prostaglandin synthesis. An increased expression has been implicated in the development and progression of human gastric cancers and colorectal adenomas and cancers. This study aimed to determine the involvement and association of COX-2 and Bcl-2 in precancerous gastric adenomas.

**Methods** : Seventy-nine gastric polyps were obtained by endoscopic mucosal resection or polypectomy from January, 2000 to July, 2003. Immunohistochemical expression of COX-2 and Bcl-2 was observed, and their relationships with various clinicopathological factors were analyzed.

**Results** : Histologically, 13 hyperplastic polyps and 66 tubular adenomas, of which 17 showed high-grade dysplasia, were observed. Increased COX-2 expression was observed in low-grade and high-grade tubular adenomas compared to hyperplastic polyps ( $p=0.004$  and  $p=0.001$ , respectively). COX-2 expression was significantly higher in larger ( $>1$  cm) compared with smaller ( $\leq 1$  cm) tubular adenomas ( $p=0.034$ ), but no relation was observed in hyperplastic polyps. While Bcl-2 expression differed significantly according to histology, increased Bcl-2 expression was observed especially in COX-2 positive low-grade tubular adenomas.

**Conclusion** : COX-2 expression increased in a size-dependent manner in tubular adenomas, suggesting a role in polyp growth. The increased expression of Bcl-2 in tubular adenomas, especially in COX-2 positive tubular adenomas, suggests that COX-2 action may be related to Bcl-2 expression.

**Key Words** : Cyclooxygenase-2, Bcl-2, Stomach neoplasms, Adenoma

---

### INTRODUCTION

Gastric cancer is still one of the major causes of cancer death in the world, although its incidence is decreasing. Gastric adenomas, a relatively common benign neoplasm of the glandular epithelium, are widely considered to be precursor lesions with an increased risk of malignancy<sup>1,2</sup>. While a correlation between the colonic adenoma-carcinoma sequence and multi-step genetic alterations has been reported, the exact pathways of gastric carcinogenesis are still unknown, though a

large number of genetic alterations have been found to regulate the initiation and progression of gastric cancer<sup>3</sup>.

Epidemiologic studies have shown that the use of aspirin and other non-steroidal anti-inflammatory drugs (NSAIDs) are associated with a reduced risk of colorectal, breast, esophageal, gastric and lung cancer<sup>4,5</sup>. Furthermore, clinical trials have shown that NSAIDs cause regression of colorectal adenomatous polyps in patients with familial adenomatous polyposis (FAP)<sup>6,7</sup>. Increased COX-2 expression has been reported in colorectal adenomas and adenocarcinomas<sup>8-11</sup>. Recently,

---

• Received : February 11, 2004

• Accepted : May 24, 2005

• Correspondence to : Jee Hyun Park, M.D. Kumi Cha Medical Center, 855 Hyungkok-dong, Gumisi, Kyungbuk, 730-728, Korea  
Tel : 82-54-450-9542, Fax : 82-54-452-5098, E-mail : ishawe@hanmail.net

**Table 1.** Clinical features of the cases

Clinical Features	Hyperplastic polyp (n=13)	Tubular Adenoma (n=66)		<i>p</i>
		Low-Grade (n=49)	High-Grade (n=17)	
Age (mean, yrs)	62.38±12.94	62.4±7.40	63.24±9.90	0.78
Sex (M : F)	2 : 11 (0.18:1)	35 : 14 (2.5:1)	15 : 2 (7.5:1)	<0.001
Size				0.185
≤1 cm	7 (53.8%)	15 (30.6%)	4 (23.5%)	
>1 cm	6 (46.2%)	34 (69.4%)	13 (76.5%)	
Location				0.501
Fundus	0	1 (2%)	0	
Body	5 (38.5%)	7 (14.3%)	3 (17.6%)	
Angle	0	6 (12.2%)	2 (11.8%)	
Antrum	8 (61.5%)	35 (71.4%)	12 (70.6%)	

COX-2 expression has been reported in human gastric adenomas and adenocarcinomas, suggesting that COX-2 plays an important role in gastric tumorigenesis as well<sup>12-19</sup>.

Several mechanisms by which COX-2 may contribute to tumorigenesis have been suggested<sup>20</sup>. Increased COX-2 expression has been shown to inhibit apoptosis and may be modulated by Bcl-2 expression<sup>21</sup>. Increased COX-2 expression may also promote angiogenesis<sup>10, 22</sup>, enhance cell motility and adhesion<sup>23</sup>, and inhibit immune surveillance<sup>20</sup>.

The aim of this study was first, to examine the relationship between COX-2 and Bcl-2 expression and clinical characteristics in precancerous gastric adenomas and second, to determine the correlation of COX-2 and Bcl-2 expression in gastric adenomas.

## MATERIALS AND METHODS

### Patients and tissue samples (Table 1)

Seventy-nine gastric polyps were obtained from patients that received an endoscopic mucosal resection or polypectomy from January, 2000 to July, 2003 at Kyungpook National University Hospital. Patient characteristics were obtained from medical records. The patient pool consisted of 52 males and 27 females. The mean age was 62.91±8.92 years. No patients had been treated with any non-steroidal anti-inflammatory drugs (NSAIDs) or COX-2 inhibitors. Histologically, there were 13 hyperplastic polyps and 66 tubular adenomas, of which 17 showed high grade dysplasia. In addition, gastric mucosa specimens from five healthy volunteers were examined as normal controls.

### Tissue microarray preparation

The specimens were fixed in 10% buffered formalin and processed into paraffin blocks according to established protocols. All hematoxylin and eosin (H&E) stained slides for each specimen were reviewed and a slide displaying a characteristic finding was selected from each case. Using a

tissue microarray, a tissue cylinder with a diameter of 2 mm was punched through the selected tumor areas from each "donor" tissue block. Tissue cylinders were then inserted into "recipient" tissue array agarose blocks. Finally, the agarose blocks were embedded into paraffin. Sections of the recipient paraffin block were cut at 5 μm, and dried in a 60°C oven for 2 to 4 hours.

### Immunohistochemistry

The tissue sections were deparaffinized with xylene and rehydrated with grading ethanol. Antigen retrieval was performed with a 0.01M, pH 6.0 citrate buffer in a pressure cooker for 10 minutes, and the slides were then cooled down to room temperature. The slides were incubated with 3% H<sub>2</sub>O<sub>2</sub> in methanol for 10 minutes to block endogenous peroxidase activity. Next, the specimens were blocked with a blocking solution (Zymed, San Francisco, California, USA) for 30 minutes and incubated overnight at 4°C with the primary antibody Cox-2 (1:100, Transduction Laboratories, Lexington, Kentucky, USA) and Bcl-2 (1:30, Zymed, San Francisco, California, USA). The specimens were incubated with a secondary antibody (Zymed, San Francisco, California, USA) for 30 minutes following multiple rinses. After rinsing with PBS three times, excess liquid was gently tapped off and streptavidin peroxidase conjugate (Zymed, San Francisco, California, USA) was applied for 30 minutes. A chromogen reaction was performed with diaminobenzidine (Zymed, South San Francisco, California, USA) for 10-20 minutes, which produced a strong brown color for positive staining. Sections were counterstained with Mayer's hematoxylin for 30 seconds. Stained slides were dehydrated and cleared with grading ethanol, xylene. Finally, the slides were mounted with malinol.

### Scoring methods

The immunostaining was evaluated by two independent observers. COX-2 immunostaining was graded on a scale of 5 based on the intensity and extent of perinuclear and

**Table 2.** Relationship between histological category and COX-2/Bcl-2 expression

Histologic type	COX-2 (%)		p	Bcl-2 (%)		p
	+	-		+	-	
Hyperplastic polyp	3 (23.1%)	10 (76.9%)	]†	0	13 (100%)	]†
Adenoma						
LG <sup>§</sup>	33 (67.3%)	16 (32.7%)		39 (79.6%)	10 (20.4%)	
HG <sup>  </sup>	14 (82.4%)	3 (17.6%)	9 (52.9%)	8 (47.1%)		

<sup>†</sup> $p < 0.001$ , <sup>\*</sup> $p < 0.005$ , <sup>‡</sup> $p < 0.05$

<sup>§</sup>LG, low-grade, <sup>||</sup>HG, high-grade

cytoplasmic staining of the gastric epithelial cells: 0=no staining, 1=weak or moderate intensity in less than 10% of the tumor area, 2=weak or moderate intensity in 10~50% of the tumor or strong intensity in less than 10% of the tumor area, 3=weak or moderate intensity in the majority of the tumor or strong intensity in 10~50% of the tumor area and 4=strong intensity in the majority of the tumor area. Specimens with a grade of more than 2 were regarded as having a positive expression.

Bcl-2 immunostaining was regarded as positive when expressing a cytoplasmic or perinuclear staining of more than 50% of the tumor cells.

#### Statistical analysis

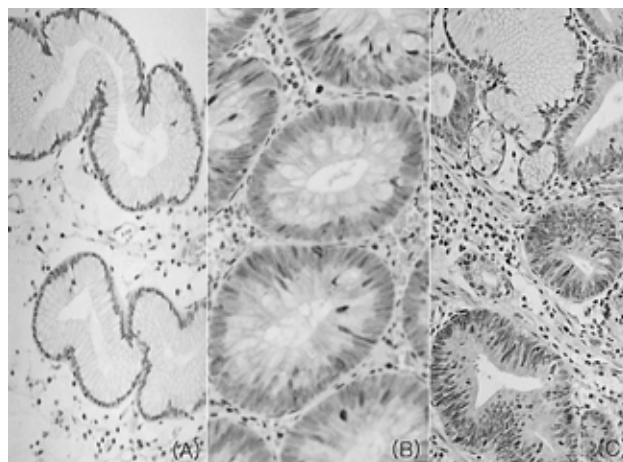
The  $\chi^2$  test and Fisher's exact probability test, where appropriate, were used to compare the expression of COX-2 and Bcl-2 with various clinicopathological parameters. The relationship between COX-2 and Bcl-2 were analyzed by the Pearson correlation coefficient. All statistical analyses were performed by SPSS (version 11.0 SPSS Inc., IL, USA) and  $p$  values  $< 0.05$  were considered to be statistically significant.

## RESULTS

#### Expression of COX-2

In normal gastric mucosa, no COX-2 immunoreactivity was observed in gastric epithelial cells, but fibroblasts and inflammatory cells located mainly in the upper lamina propria were immunoreactive. In hyperplastic polyps, COX-2 immunoreactivity was rarely observed in gastric epithelial cells (Figure 1A). In tubular adenomas, COX-2 immunoreactivity was observed not only in fibroblasts and inflammatory cells but also in dysplastic gastric epithelial cells (Figure 1B, 1C).

Positive expression of COX-2 was observed in 3 of 13 (23.1%) hyperplastic polyps, 33 of 49 (67.3%) low-grade tubular adenomas and 14 of 17 (82.4%) high-grade tubular adenomas (Table 2). Increased COX-2 expression was observed in low-grade and high-grade tubular adenomas compared to hyperplastic polyps ( $p=0.004$  and  $p=0.001$ , respectively).



**Figure 1.** COX-2 immunostaining in hyperplastic polyps and tubular adenomas of the stomach. (A) In hyperplastic polyps, no immunoreactivity was observed in epithelial cells but positive staining was observed in fibroblasts and inflammatory cells located in the upper portion of the lamina propria ( $\times 200$ ). (B, C) Positive immunoreactivity was observed focally in the cytoplasm and perinuclear area of gastric epithelial cells in low-grade (B,  $\times 200$ ) and high-grade tubular adenomas (C,  $\times 200$ ).

#### Association between COX-2 and clinicopathological features (Table 3)

COX-2 expression significantly increased in tubular adenomas  $> 1$  cm compared to tubular adenomas  $\leq 1$  cm ( $p=0.034$ ). This difference was especially prominent in low-grade tubular adenomas, which displayed a positive COX-2 expression in 7 of 15 (46.7%) adenomas  $\leq 1$  cm and 26 of 34 (76.5%) adenomas  $> 1$  cm ( $p=0.04$ ). There was no correlation between COX-2 expression and the size of hyperplastic polyps.

COX-2 expression was not associated with age, sex or location in both hyperplastic polyps and tubular adenomas.

#### Expression of Bcl-2

In normal gastric mucosa and hyperplastic polyps, Bcl-2 immunoreactivity was limited to minimal staining in the gastric epithelial regenerative compartments, the intestinal crypt bases and the gastric mucous neck region and strong staining in lymphocytes in the lamina propria (Figure 2A). In tubular

**Table 3.** Association between COX-2 expression and clinical parameters

Clinical parameters	Hyperplastic polyp (%)			Tubular adenoma (%)					
	+	-	<i>p</i>	LG <sup>†</sup>		<i>p</i>	HG <sup>†</sup>		<i>p</i>
				+	-		+	-	
Age			0.913			0.426			0.290
≤60 yrs	1 (25)	3 (75)		12 (75)	4 (25)		4 (100)	0	
>60 yrs	2 (22.2)	7 (77.8)		21 (63.6)	12 (36.4)		10 (76.9)	3 (23.1)	
Sex			0.40			0.773			0.486
Male	0	2 (100)		24 (68.6)	11 (31.4)		12 (80)	3 (20)	
Female	3 (27.3)	8 (72.7)		9 (64.3)	5 (35.7)		2 (100)	0	
Size			0.416			0.04			0.659
≤1 cm	1 (14.3)	6 (85.7)		7 (46.7)	8 (53.3)		3 (75)	1 (25)	
>1 cm	2 (33.3)	4 (66.7)		26 (76.5)	8 (23.5)		11 (84.6)	2 (15.4)	
Location			0.101			0.268			0.676
Fundus	0	0		1 (100)	0		0	0	
Body	2 (40)	3 (60)		3 (42.9)	4 (57.1)		2 (66.7)	1 (33.3)	
Angle	0	0		5 (83.3)	1 (16.7)		2 (100)	0	
Antrum	1 (12.5)	7 (87.5)		24 (68.6)	11 (31.4)		10(83.3)	2 (16.7)	

<sup>†</sup>LG, low-grade, <sup>†</sup> HG, high-grade

adenomas, Bcl-2 immunoreactivity was observed in a diffuse cytoplasmic or focal nuclear pattern in most gastric epithelial cells (Figure 2B, 2C).

Positive expression of Bcl-2 was not observed in any of the 13 (0%) hyperplastic polyps, 39 of 49 (79.6%) low-grade tubular adenomas and 9 of 17 (52.9%) high-grade tubular adenomas (Table 2). Bcl-2 expression differed significantly according to histology ( $p < 0.001$ ).

#### Association between Bcl-2 and clinicopathological features (Table 4)

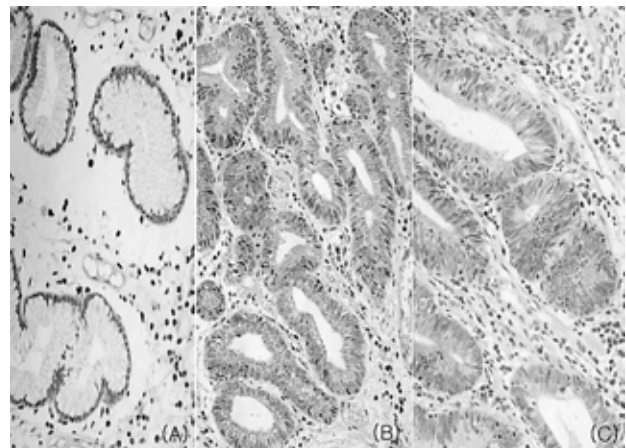
There was no statistically significant relationship between Bcl-2 expression and age, sex, location or size of both hyperplastic polyps and tubular adenomas.

#### Relationship between COX-2 and Bcl-2 (Figure 3)

In low-grade tubular adenomas, positive Bcl-2 expression was observed in 29 of 33 (87.9%) COX-2 positive tubular adenomas compared to 10 of 16 (62.5%) COX-2 negative adenomas, showing a significantly increased Bcl-2 expression in COX-2 positive tubular adenomas ( $p = 0.039$ ). Though not statistically significant, a tendency of increased Bcl-2 expression in COX-2 positive high-grade tubular adenomas was observed ( $p = 0.072$ ).

## DISCUSSION

Cyclooxygenase (COX) is the rate-limiting enzyme in prostaglandin (PG) synthesis and two isoforms have been identified<sup>24</sup>. COX-1 is constitutively expressed in most normal tissues and plays an important role in maintaining the integrity



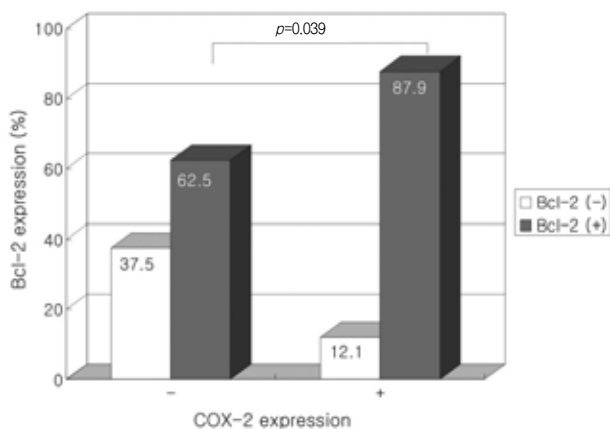
**Figure 2.** Bcl-2 immunostaining in hyperplastic polyps and tubular adenomas of the stomach. (A) In hyperplastic polyps, focal minimal immunoreactivity was limited to epithelial regenerative compartments and strong immunoreactivity was observed in lymphocytes located in the lamina propria ( $\times 200$ ). (B) Diffuse strong positive immunoreactivity was observed in most of the gastric epithelial cells in low-grade tubular adenomas ( $\times 200$ ). (C) In high-grade tubular adenomas, positive immunoreactivity was observed in a focal nuclear and cytoplasmic pattern ( $\times 200$ ).

of gastrointestinal mucosa, renal function, and platelet aggregation. COX-2 is undetectable in most tissues, but is induced by various stimuli such as mitogens, cytokines and tumor promoters thus contributing to the synthesis of PGs in inflamed and malignant tissues. Increased COX-2 expression has been observed in various cancers, especially gastrointestinal cancers. Though a number of studies have reported the increased expression of COX-2 in gastric cancer, limited data are available on COX-2 expression in gastric adenomas. This

**Table 4.** Association between Bcl-2 expression and clinical parameters

Clinical parameters	Hyperplastic polyp (%)			Tubular adenoma (%)					
	+	-	<i>p</i>	LG <sup>†</sup>			HG <sup>†</sup>		
				+	-	<i>p</i>	+	-	<i>p</i>
Age			-			0.339			0.893
≤60 yrs	0	4 (100)		14 (87.5)	2 (12.5)		2 (50)	2 (50)	
>60 yrs	0	9 (100)		25 (75.8)	8 (24.2)		7 (53.8)	6 (46.2)	
Sex			-			0.911			0.929
Male	0	2 (100)		28 (80)	7 (20)		8 (53.3)	7 (46.7)	
Female	0	11 (100)		11 (78.6)	3 (21.4)		1 (50)	1 (50)	
Size			-			0.470			0.576
≤1 cm	0	7 (100)		11 (73.3)	4 (26.7)		3 (75)	1 (25)	
>1 cm	0	6 (100)		28 (82.4)	6 (17.6)		6 (46.2)	7 (53.8)	
Location			-			0.691			0.772
Fundus	0	0		1 (100)	0		0	0	
Body	0	5 (100)		5 (71.4)	2 (28.6)		1 (33.3)	2 (66.7)	
Angle	0	0		4 (66.7)	2 (33.3)		1 (50)	1 (50)	
Antrum	0	8 (100)		29 (82.9)	6 (17.1)		7 (58.3)	5 (41.7)	

<sup>†</sup>LG, low-grade, <sup>†</sup>HG, high-grade

**Figure 3.** Correlation between COX-2 and Bcl-2 expression in low-grade tubular adenomas.

study demonstrated the expression and influence of COX-2 in gastric adenomas.

In the present study, COX-2 expression increased in tubular adenomas compared to hyperplastic polyps. In addition, although not statistically significant, an increased expression of COX-2 was observed in high-grade compared to low-grade tubular adenomas. Einspahr et al.<sup>11)</sup> reported similar results to ours in a study of colorectal adenomas, where an increased expression, though not statistically significant, of COX-2 was noted in high-grade dysplasia compared with mild- to moderate-grade dysplasia, which provided contrary results to previous studies<sup>5)</sup> where the degree of dysplasia was not related to COX-2 expression. Van Rees et al.<sup>18)</sup> reported an increased expression of COX-2 in parallel with the progression of reactive epithelium to the highest degree of epithelial

dysplasia in the human stomach. Our results suggest that the expression of COX-2 may be related to the progression of the neoplastic process, but further studies with a larger size of high-grade tubular adenomas are needed.

Though there are few reports on the correlation of COX-2 expression and gastric adenoma size, many reports on the size-dependent expression of COX-2 in colorectal adenomas<sup>11, 25)</sup> support the hypothesis that increased COX-2 expression provides a growth advantage for adenomas. In the present study, COX-2 expression was significantly higher in larger (>1 cm) compared to smaller (≤1 cm) tubular adenomas. This difference was especially prominent in low-grade tubular adenomas. This result suggests that COX-2 expression may have a similar role in adenoma growth in both gastric adenomas and colorectal adenomas.

COX-2 expression is not only related to cell growth promotion but increased COX-2 expression has also been shown to inhibit apoptosis<sup>21)</sup>. Bcl-2 is a proto-oncogene, which inhibits apoptosis and prolongs cell life span<sup>26)</sup>. Bcl-2 was expressed in 65% of the cases of chronic atrophic gastritis with intestinal metaplasia, in 81% of gastric epithelial dysplasia<sup>27)</sup> and in 72% of gastric adenocarcinomas<sup>28)</sup>. The incidence of Bcl-2 expression, based on cytoplasmic expression, is generally higher in both colonic<sup>29-31)</sup> and gastric adenomas<sup>32-34)</sup> than carcinomas<sup>29-34)</sup>, implicating a potential role for Bcl-2 in the early phase of the adenoma-carcinoma sequence. In the present study, Bcl-2 expression differed according to histology and was significantly higher in low-grade tubular adenomas compared to high-grade tubular adenomas. While various results have been reported on the relationship between Bcl-2 expression and the degree of dysplasia<sup>27, 35)</sup>, our results were compatible with that

of Uesugi et al.<sup>35)</sup> who also reported an increased expression of Bcl-2 in mild compared to severe dysplasia. Bcl-2 overexpression has been suggested to prevent apoptosis in adenomas leading to extended survival and prolonged exposure of proliferative cells to carcinogenic stimuli, increasing the chance of mutations progressing to carcinomas. Afterwards, other genes, such as p53, may dominate the process and suppress the expression of Bcl-2 in carcinomas. The increased expression of Bcl-2 in low-grade compared to high-grade tubular adenomas in this study supports the hypothesis of a potential role for Bcl-2 in the early stage of adenoma progression.

Accumulating evidence indicates that induction of COX-2 correlates with increased Bcl-2 expression. Sheng et al.<sup>21)</sup> demonstrated that PGE<sub>2</sub> inhibited apoptosis and induced Bcl-2 expression in human colon cancer cells, suggesting that apoptosis inhibition by COX-2 expression may be modulated by Bcl-2 expression. The increased expression of Bcl-2 especially in COX-2 positive low-grade tubular adenomas seen in this study suggests that this hypothesis may be applicable in gastric adenomas as well, especially in the early stages of adenoma formation.

The above results suggest that overexpression of COX-2 constitutes an early event in gastric tumorigenesis. NSAIDs and COX-2 inhibitors have been shown to reduce polyp burden in patients with FAP<sup>6, 7)</sup>. Recently, Saukkonen et al.<sup>36)</sup> showed that inhibition of COX-2 with a COX-2 inhibitor, celecoxib, disturbed the integrity of gastric adenomas. These findings support further studies on the possible role of COX-2 inhibitors as a chemotherapeutic modality against gastric tumorigenesis.

In summary, increased COX-2 expression was observed in precancerous tubular adenomas and COX-2 expression increased in a size-dependent manner in tubular adenomas, suggesting a role in polyp growth. The increased expression of Bcl-2 in tubular adenomas, especially in COX-2 positive low-grade tubular adenomas, suggests that Bcl-2 may contribute to the adenoma-carcinoma sequence in the early phase and that COX-2 action may be related to Bcl-2 expression.

## REFERENCES

- 1) Antonioli DA. *Precursors of gastric carcinoma: a critical review with a brief description of early (curable) gastric cancer. Hum Pathol* 25:994-1005, 1994
- 2) Oberhuber G, Stolte M. *Gastric polyps: an update of their pathology and biological significance. Virchows Arch* 437:581-590, 2000
- 3) Tahara E, Semba S, Tahara H. *Molecular biological observations in gastric cancer. Semin Oncol* 23:307-315, 1996
- 4) Thun MJ, Nambodiri MM, Heath CW Jr. *Aspirin use and reduced risk of fatal colon cancer. N Engl J Med* 325:1593-1596, 1991
- 5) Thun MJ, Nambodiri MM, Calle EE, Flanders WD, Heath CW Jr. *Aspirin use and risk of fatal cancer. Cancer Res* 53:1322-1327, 1993
- 6) Giardiello FM, Hamilton SR, Krush AJ, Piantadosi S, Hyland LM, Celano P, Booker SV, Robinson CR, Offerhaus GJ. *Treatment of colonic and rectal adenomas with sulindac in familial adenomatous polyposis. N Engl J Med* 328:1313-1316, 1993
- 7) Oshima M, Dinchuk JE, Kargman SL, Oshima H, Hancock B, Kwong E, Trzaskos JM, Evans JF, Taketo MM. *Suppression of intestinal polyposis in APC<sup>Δ716</sup> knockout mice by inhibition of cyclooxygenase 2 (COX-2). Cell* 87:803-809, 1996
- 8) Eberhart CE, Coffey RJ, Radhika A, Giardiello FM, Ferrenbach S, DuBois RN. *Up-regulation of cyclooxygenase 2 gene expression in human colorectal adenomas and adenocarcinomas. Gastroenterology* 107:1183-1188, 1994
- 9) Sano H, Kawahito Y, Wilder RL, Hashiramoto A, Mukai S, Asai K, Kimura S, Kato H, Kondo M, Hla T. *Expression of cyclooxygenase-1 and -2 in human colorectal cancer. Cancer Res* 55:3785-3789, 1995
- 10) Cianchi F, Cortesini C, Bechi P, Fantappie O, Messerini L, Vannacci A, Sardi I, Baroni G, Boddi V, Mazzanti R, Masin E. *Up-regulation of cyclooxygenase 2 gene expression correlates with tumor angiogenesis in human colorectal cancer. Gastroenterology* 121:1339-1347, 2001
- 11) Einspahr JG, Krouse RS, Yochim JM, Danenberg PV, Danenberg KD, Bhattacharyya AK, Martinez ME, Alberts DS. *Association between cyclooxygenase expression and colorectal adenoma characteristics. Cancer Res* 63:3891-3893, 2003
- 12) Ristimäki A, Honkanen N, Jankala H, Sipponen P, Harkonen M. *Expression of cyclooxygenase-2 in human gastric carcinoma. Cancer Res* 57:1276-1280, 1997
- 13) Lim HY, Joo HJ, Choi JH, Yi JW, Yang MS, Cho DY, Kim HS, Nam DK, Lee KB, Kim HC. *Increased expression of cyclooxygenase-2 protein in human gastric carcinoma. Clin Cancer Res* 6:519-525, 2000
- 14) Saukkonen K, Nieminen O, van Rees B, Vilkkii S, Harkonen M, Juhola M, Mecklin JP, Sipponen P, Ristimäki A. *Expression of cyclooxygenase-2 in dysplasia of the stomach and in intestinal-type gastric adenocarcinoma. Clin Cancer Res* 7:1923-1931, 2001
- 15) Uefuji K, Ichikura T, Mochizuki H. *Expression of cyclooxygenase-2 in human gastric adenomas and adenocarcinomas. J Surg Oncol* 76:26-30, 2001
- 16) Chae SW, Sohn JH, Shin HS, Park YE. *Expression of cyclooxygenase-2 protein in gastric carcinogenesis. Cancer Res Treat* 34:252-257, 2002
- 17) Joo YE, Oh WT, Rew JS, Park CH, Choi SK, Kim SJ. *Cyclooxygenase-2 expression is associated with well-differentiated and intestinal-type pathways in gastric carcinogenesis. Digestion* 66:222-229, 2002
- 18) van Rees BP, Saukkonen K, Ristimäki A, Polkowski W, Tytgat GN, Drilenburg P, Offerhaus GJ. *Cyclooxygenase-2 expression during carcinogenesis in the human stomach. J Pathol* 196:171-179, 2002
- 19) Saukkonen K, Rintahaka J, Sivula A, Buskens CJ, van Rees BP, Rio MC, Haglund C, van Lanschoot JJ, Offerhaus GJ, Ristimäki A. *Cyclooxygenase-2 and gastric carcinogenesis. APMIS* 111:915-925, 2003
- 20) Cao Y, Prescott SM. *Many actions of cyclooxygenase-2 in cellular dynamics and in cancer. J Cell Physiol* 190:279-286, 2002

- 21) Sheng H, Shao J, Morrow JD, Beauchamp RD, DuBois RN. Modulation of apoptosis and Bcl-2 expression by prostaglandin E<sub>2</sub> in human colon cancer cells. *Cancer Res* 58:362-366, 1998
- 22) Kawada M, Seno H, Wada M, Suzuki K, Kanda N, Kayahara T, Fukui H, Sawada M, Kajiyama T, Sakai M, Chiba T. Cyclooxygenase-2 expression and angiogenesis in gastric hyperplastic polyp: association with polyp size. *Digestion* 67:20-24, 2003
- 23) Sheng H, Shao J, Washington MK, DuBois RN. Prostaglandin E<sub>2</sub> increases growth and motility of colorectal carcinoma cells. *J Biol Chem* 276:18075-18081, 2001
- 24) Williams CW, DuBois RN. Prostaglandin endoperoxide synthase: why two isoforms? *Am J Physiol* 270:G393-G400, 1996
- 25) Azumaya M, Kobayashi M, Ajioka Y, Honma T, Suzuki Y, Takeuchi M, Narisawa R, Asakura H. Size-dependent expression of cyclooxygenase-2 in sporadic colorectal adenomas relative to adenomas in patients with familial adenomatous polyposis. *Pathol Int* 52:272-276, 2002
- 26) Hockenbery D, Nunez G, Millman C, Schreiber RD, Korsmeyer SJ. Bcl-2 is an inner mitochondrial membrane protein that blocks programmed cell death. *Nature* 348:334-336, 1990
- 27) Lauwers GY, Scott GV, Hendricks J. Immunohistochemical evidence of aberrant bcl-2 protein expression in gastric epithelial dysplasia. *Cancer* 73:2900-2904, 1994
- 28) Lauwers GY, Scott GV, Karpeh MS. Immunohistochemical evaluation of bcl-2 protein expression in gastric adenocarcinomas. *Cancer* 75:2209-2213, 1995
- 29) Hao XP, Ilyas M, Talbot IC. Expression of Bcl-2 and p53 in the colorectal adenoma-carcinoma sequence. *Pathobiology* 65:140-145, 1997
- 30) Saleh HA, Jackson H, Khatib G, Banerjee M. Correlation of bcl-2 oncoprotein immunohistochemical expression with proliferation index and histopathologic parameters in colorectal neoplasia. *Pathol Oncol Res* 5:273-279, 1999
- 31) Nomura M, Watari J, Yokota K, Saitoh Y, Obara T, Kohgo Y. Morphogenesis of nonpolypoid colorectal adenomas and early carcinomas assessed by cell proliferation and apoptosis. *Virchows Arch* 437:17-24, 2000
- 32) Kim YS, Kim BK, Shim SI. Expression of bcl-2 protein in gastric adenoma and adenocarcinoma. *Korean J Pathol* 32:248-254, 1998
- 33) Kyokane K, Ito M, Sato Y, Ina K, Ando T, Kusugami K. Expression of Bcl-2 and p53 correlates with the morphology of gastric neoplasia. *J Pathol* 184:382-389, 1998
- 34) Lee SS, Cho KJ, Hong SI, Myoung NK, Jang JJ. Nuclear overexpression of bcl-2 oncoprotein during the progression of human stomach cancer. *J Korean Med Sci* 13:153-158, 1998
- 35) Uesugi H, Saegusa M, Takano Y, Okayasu I. Different expression of Bcl-2 protein in gastric adenomas and carcinomas. *Pathol Int* 46:274-280, 1996
- 36) Saukkonen K, Tomasetto C, Narko K, Rio MC, Ristimaki A. Cyclooxygenase-2 expression and effect of celecoxib in gastric adenomas of trefoil factor 1-deficient mice. *Cancer Res* 63:3032-3036, 2003