

A Case of Neuromyelitis Optica Misdiagnosed as Cervicogenic Headache

Department of Anesthesiology and Pain Medicine, Ajou University College of Medicine, Suwon, Korea

Soo Il Choi, Yeon Ju Lee, Do Wan Kim, and Jong Yeun Yang

Neuromyelitis optica (NMO) is an inflammatory demyelinating disease of the central nervous system associated with longitudinally extensive myelitis and optic neuritis. It is characterized by relapses that lead to blindness and paralysis sequelae. But, this is rare disease; therefore high clinical suspicion for a correct diagnosis and proper examinations are not easy. However, early diagnosis is essential to prevent sequelae. We report the case of NMO with headache. A 30-year male patient who suffered headache visited our pain clinic because of aggravated pain despite treatment. The cause of the pain was revealed as NMO by more detailed previous history and examination. (Korean J Pain 2014; 27: 77-80)

Key Words:

headache, myelitis, neuromyelitis optica, optic neuritis.

Headache is a common symptom seen at a medical institution and is diagnosed based on the information obtained from the patient and physical examination [1-3]. It is more helpful to make a more accurate diagnosis if a diagnostic workup like MRI or CSF analysis is performed, but most headaches are primary headaches that show relatively good outcomes, and secondary headaches are rare, so it is not economical to perform these tests for all cases [3,4]. However, the condition may worsen if a fast diagnosis is not achieved, so doctors treating headaches always need to be well aware of the progress of the patient's disease as well as the presenting symptoms, and perform further tests when necessary. The case below is a patient who was considered to have an ordinary headache but was found to have a rare myelopathy by performing a complete

medical examination by listening carefully to the past medical history of the patient and observing his progress.

CASE REPORT

A 33-year-old male patient came to the hospital complaining of headache that had been occurring for two weeks prior to his visit. One week before visiting the hospital, he received a cervical facet joint block and drug treatment in another hospital, but the pain continued so he visited the pain clinic at our hospital. In the first medical examination, the patient said that he did not have any unusual past history. The headache began at the left occipital region and then gradually spread to the posterior neck, where numbness and aching developed; there was no

Received June 30, 2013. Revised October 25, 2013. Accepted October 25, 2013.

Correspondence to: Jong Yeun Yang

Department of Anesthesiology and Pain Medicine, Ajou University College of Medicine, 164 World Cup-ro, Yeongtong-gu, Suwon 443-380, Korea
Tel: +82-31-219-5689, Fax: +82-31-219-5579, E-mail: jyhy@hanmail.net

© This is an open-access article distributed under the terms of the Creative Commons Attribution Non-Commercial License (<http://creativecommons.org/licenses/by-nc/3.0/>), which permits unrestricted non-commercial use, distribution, and reproduction in any medium, provided the original work is properly cited.

Copyright © The Korean Pain Society, 2014

paresthesia. Additionally, during the same period, the patient had blurred vision as a symptom. The physical examination performed at the time of the hospital visit appeared to be normal.

At first, it was suspected to be a general cervicogenic headache, so a bilateral greater occipital nerve block was performed as a diagnostic block and his progress was monitored. Three days later in the clinic, the ache in the head area had slightly decreased, but the numbness had spread from the face to the posterior neck, both shoulders, and both arms. In addition, during the physical examination performed this time, the Lhermitte sign appeared to be positive. Hence, a more detailed past history was examined, and it was found that 15 years ago the patient's eyesight suddenly failed so he was diagnosed with optic neuritis, and during the same period, he also suffered from myelitis. Secondary headache due to central pain was suspected from the progress of the disease, past history, and physical examination, and thus C-spine MRI was performed. As a result, an extensive intramedullary high signal intensity was observed from the medulla oblongata to the C5 (Fig. 1). Visual acuity test, color vision test, visual field test, and fundus examination performed in ophthalmology to check for anomalies in the optic nerve all appeared to be normal, but in the subsequent goggle VEPS (visual evoked potentials), a bilateral ocular or prechiasmatal lesion and suspicious bilateral upper brainstem lesion were

observed. In addition, the oligoclonal band IgG appeared negative in the CSF analysis. There were no abnormalities in the brain MRI, and the NMO-Ab test was negative.

Based on the past medical history and test results above, the patient was diagnosed with neuromyelitis optica, and steroid pulse therapy was performed for 5 days in which 1 g of solumedrol was given on each day. Subsequently, the neurological symptoms and MRI observations improved, so the drugs were changed to oral steroids and the patient was discharged (Fig. 2).

DISCUSSION

Secondary headache is a headache that occurs in connection to other diseases. Therefore, it is important to reveal the reasons. Among secondary headache types, it is important to differentiate those caused by central pain. Central pain is pain from a disease or lesion in the central nervous system, and a disease that can especially occur in relation to headache is myelopathy [5]. When secondary causes due to structural abnormalities or accidents are excluded, the major causes for myelopathy are multiple sclerosis and neuromyelitis optica. Multiple sclerosis is a representative autoimmune disease that occurs in the central nervous system such as the brain, spine, and optic nerves [6]. Mostly, it is asymmetrical, and characteristically invades only part of the ascending or descending course of the spine. In addition, cerebrum invasion is commonly ob-

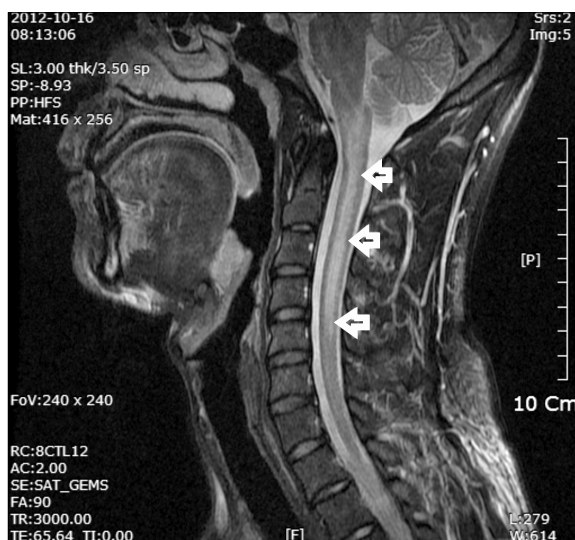


Fig. 1. Extensive intramedullary high signal intensity at medulla oblongata and C-spine (between medulla oblongata and C5).

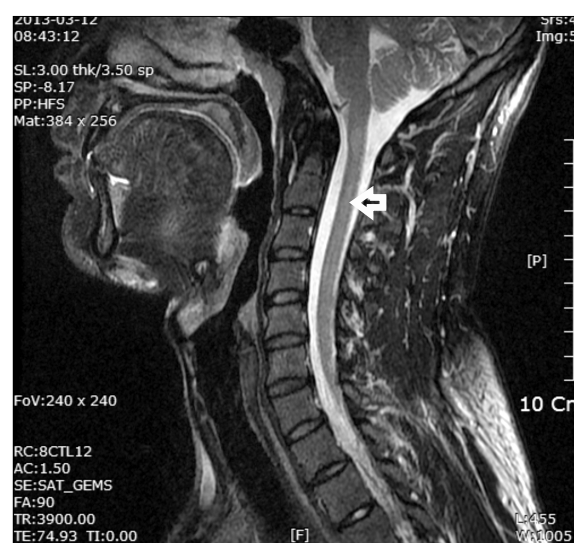

Fig. 2. Marked improvement of previous intramedullary high signal intensity at cervical spinal cord, since last MRI.

served in brain MRIs, and oligoclonal band IgG is detected in the CSF analysis [6,7].

In the same way, neuromyelitis optica is an inflammatory disease in the central nervous system due to an autoimmune mechanism. Once it was considered a type of multiple sclerosis; however, it became an independent autoimmune disease with the discovery of NMO-Ab in 2004 [8–10]. It occurs in 1 per every hundred thousand and occurs more in females, and the mean age of onset is in the late 30s. However, the age range is diverse from young children to the elderly, and it is largely unrelated to family history. The incidence rate is slightly different according to race, and it appears to be higher in black people, Asians, and Indians [11,12].

Clinically, its characteristics are optic neuritis on one or both sides, and myelitis invading 3 or more segments of the spinal cord. Neuromyelitis optica should be suspected especially when optic neuritis appears on both sides simultaneously and myelitis symptoms appear extensively on both sides [9–14]. This disease was found to experience severe visual impairment or motor disturbance within 5 years of onset in 50% of the cases, and the mortality rate within 5 years also reaches 2.9–25%. Poor prognostic factors are when recurrence is frequent within 5 years of onset, when symptoms were severe in the first onset and recovery was slow, and when there other accompanying autoimmune diseases [9,11].

In the diagnosis of neuromyelitis optica, the absolute criteria is that optic neuritis and acute myelitis exist, and the support criteria is that 2 or more of the following is satisfied: negative brain MRI at disease onset, spinal cord MRI with contiguous T2-weighted signal abnormality extending over 3 or more vertebral segments, and NMO-IgG seropositive status [15].

In relatively young patients, it repeatedly causes optic neuritis and myelitis; thus, it can lead to blindness and quadriplegia when it is not treated properly. Hence, recently, there is the view that treatment should be started straight away when neuromyelitis optica is suspected. Therefore, when amblyopia and myelitis symptoms occur together, neuromyelitis optica should be suspected, and diagnostic tests and subsequent treatment should be carried out quickly for a good prognosis [16,17].

In the case of our patient, a cervicogenic headache was suspected when he was treated in the local clinic; however, there had been no effect when he visited the pain

clinic at our hospital. At first, it was thought to be a cervicogenic headache but the response was slight to a diagnostic block and the headache symptoms continued to progress. An MRI was performed based on an additional physical examination and a detailed past medical history which led to the discovery of central damage in the patient. Although NMO-Ab was not detected, clinically, the numbness and aching progressed from the head to the bilateral upper extremities and goggle VEPs and MRI confirmed an optic nerve lesion and myelitis across five levels, respectively. The brain MRI showed no abnormal lesions and there was a history of myelitis and optic neuritis, which had currently recurred, and the oligoclonal band IgG was negative in the CSF test. From the above results, multiple sclerosis was excluded and the patient was diagnosed with neuromyelitis optica and steroid treatment was started. Subsequently, the symptoms improved and the patient was transferred to neurology for further evaluation.

Headaches can be divided into primary headaches where the headache itself is the disease and secondary headaches caused by other diseases. The most basic method of differentiation is taking the patient's history. Most headaches show good results, so taking of the medical history may be neglected in a busy clinic because it takes a long time. However, the severity of the underlying disease and the headache is not proportionate, and even though it may respond well to simple painkillers, severe underlying diseases cannot be excluded.

Therefore, when there are systemic symptoms like fever or weight loss, decline in consciousness, neurological symptoms such as sensory or motor abnormalities that are rapidly progressing and newly occurring in old patients of 50 years or older, and when papilledema occurs, more attention must be given to detailed history taking and to carrying out the necessary tests [18,19]. Especially contrary to other departments, pain clinics use invasive interventions in the treatment of headaches. If intervention is performed in a headache patient with central damage as above without a detailed history and examination, not only is a sufficient treatment effect not obtained, but there is also the possibility of a legal dispute regarding the cause of central damage. Therefore, detailed history taking should be performed when examining patients and examiners should always be aware of dangerous symptoms that could suggest secondary headache, and progress should be observed closely.

REFERENCES

1. De Klippel N, Jansen JP, Carlos JS. Survey to evaluate diagnosis and management of headache in primary care: Headache Management Pattern programme. *Curr Med Res Opin* 2008; 24: 3413–22.
2. Hasse LA, Ritchey PN, Smith R. Predicting the number of headache visits by type of patient seen in family practice. *Headache* 2002; 42: 738–46.
3. Kim YJ. Diagnosis and treatment of headache in primary practice: a brief review. *J Korean Med Assoc* 2010; 53: 807–14.
4. Kim BK. A diagnostic imaging in headache patients. *Korean J Headache* 2007; 8: 16–9.
5. Attal N. Neuropathic pain: mechanisms, therapeutic approach, and interpretation of clinical trials. *Continuum (Minneapolis)* 2012; 18: 161–75.
6. Kim W, Kim HJ. Multiple sclerosis. *J Korean Med Assoc* 2009; 52: 665–76.
7. Myhr KM. Diagnosis and treatment of multiple sclerosis. *Acta Neurol Scand Suppl* 2008; 188: 12–21.
8. Barnett MH, Sutton I. Neuromyelitis optica: not a multiple sclerosis variant. *Curr Opin Neurol* 2012; 25: 215–20.
9. Fazio R, Radaelli M, Furlan R. Neuromyelitis optica: concepts in evolution. *J Neuroimmunol* 2011; 231: 100–4.
10. Jarius S, Wildemann B. The history of neuromyelitis optica. *J Neuroinflammation* 2013; 10: 8.
11. Kim W, Kim SH, Kim HJ. New insights into neuromyelitis optica. *J Clin Neurol* 2011; 7: 115–27.
12. Matà S, Lolli F. Neuromyelitis optica: an update. *J Neurol Sci* 2011; 303: 13–21.
13. Asgari N, Owens T, Frøkiaer J, Stenager E, Lillevang ST, Kyvik KO. Neuromyelitis optica (NMO)—an autoimmune disease of the central nervous system (CNS). *Acta Neurol Scand* 2011; 123: 369–84.
14. Lana-Peixoto MA, Callegaro D. The expanded spectrum of neuromyelitis optica: evidences for a new definition. *Arq Neuropsiquiatr* 2012; 70: 807–13.
15. Wingerchuk DM, Lennon VA, Pittock SJ, Lucchinetti CF, Weinshenker BG. Revised diagnostic criteria for neuromyelitis optica. *Neurology* 2006; 66: 1485–9.
16. Wingerchuk DM. Diagnosis and treatment of neuromyelitis optica. *Neurologist* 2007; 13: 2–11.
17. Wingerchuk DM, Weinshenker BG. Neuromyelitis optica: clinical predictors of a relapsing course and survival. *Neurology* 2003; 60: 848–53.
18. Friedman BW, Lipton RB. Headache emergencies: diagnosis and management. *Neurol Clin* 2012; 30: 43–59.
19. Nahas SJ. Diagnosis of acute headache. *Curr Pain Headache Rep* 2011; 15: 94–7.