

The First Korean Case of Nontuberculous Mycobacterial Lung Disease Caused by *Mycobacterium abscessus* Subspecies *bolletii* in a Patient with Bronchiectasis

Byeong-Ho Jeong, M.D.^{1,*}, Su-Young Kim, Ph.D.^{1,*}, Kyeongman Jeon, M.D.¹, Hee Jae Huh, M.D.², Chang-Seok Ki, M.D.², Nam Yong Lee, M.D.², Sung Jae Shin, Ph.D.³ and Won-Jung Koh, M.D.¹

¹Division of Pulmonary and Critical Care Medicine, Department of Medicine, ²Department of Laboratory Medicine and Genetics, Samsung Medical Center, Sungkyunkwan University School of Medicine, ³Department of Microbiology, Yonsei University College of Medicine, Seoul, Korea

We report the first Korean case of lung diseases caused by *Mycobacterium abscessus* subsp. *bolletii* in a previously healthy male, except for a previous history of pulmonary tuberculosis and bronchiectasis. All serial isolates are identified as *M. abscessus* subsp. *bolletii* by multi-locus sequence analysis based on the *hsp65*, *rpoB*, and 16S rRNA fragments. At the genetic level, the isolate has the *erm*(41) gene with a T28 sequevar, associated with clarithromycin resistance, and no *rrl* mutation. The isolate is resistant to clarithromycin. Although the symptoms and radiographic findings have improved after combination of antibiotics, the follow-up sputum cultures are persistently positive.

Keywords: Bronchiectasis; Mycobacterium Infections, Nontuberculous; Nontuberculous Mycobacteria; Sequence Analysis, DNA

Introduction

Rapidly growing mycobacteria (RGM) are relatively common pathogens of lung disease caused by nontuberculous

mycobacteria (NTM) in Korea¹. Of the RGM species, *Mycobacterium abscessus* complex is most commonly associated with NTM lung disease. Although subspeciation of *M. abscessus* complex is still controversial, *M. abscessus* complex is currently divided into three subspecies: *M. abscessus* subsp. *abscessus*, *M. abscessus* subsp. *massiliense* and *M. abscessus* subsp. *bolletii*².

In Korea, *M. abscessus* subsp. *bolletii* is identified in only 1.3–1.6% of clinical strains of *M. abscessus* complex³. Although a case with disseminated infection of *M. abscessus* subsp. *bolletii* was reported⁴, there has been no report of NTM lung disease caused by *M. abscessus* subsp. *bolletii* in Korea. Here, we describe a case of chronic pulmonary disease caused by *M. abscessus* subsp. *bolletii*.

Address for correspondence: Won-Jung Koh, M.D.

Division of Pulmonary and Critical Care Medicine, Department of Medicine, Samsung Medical Center, Sungkyunkwan University School of Medicine, 81 Irwon-ro, Gangnam-gu, Seoul 135-710, Korea

Phone: 82-2-3410-3429, **Fax:** 82-2-3410-3849

E-mail: wjkoh@skku.edu

*Byeong-Ho Jeong and Su-Young Kim contributed equally to this work.

Received: Aug. 7, 2013

Revised: Sep. 4, 2013

Accepted: Sep. 16, 2013

©It is identical to the Creative Commons Attribution Non-Commercial License (<http://creativecommons.org/licenses/by-nc/3.0/>).

Copyright © 2014

The Korean Academy of Tuberculosis and Respiratory Diseases.

All rights reserved.

Case Report

A 66-year-old male was referred to our hospital for management of probable NTM lung disease. He was an ex-smoker and had a history of previous treatment for pulmonary tuber-

culosis 10 years prior. Six months before his visit to our hospital, the patient reported chronic cough and sputum. He was initially diagnosed with acid-fast bacilli (AFB) smear-positive pulmonary tuberculosis and received isoniazid, rifampin,

ethambutol, and pyrazinamide for 6 months. However, AFB smears were persistently positive, and NTM were cultured from his sputum specimens. He was then referred to our hospital.

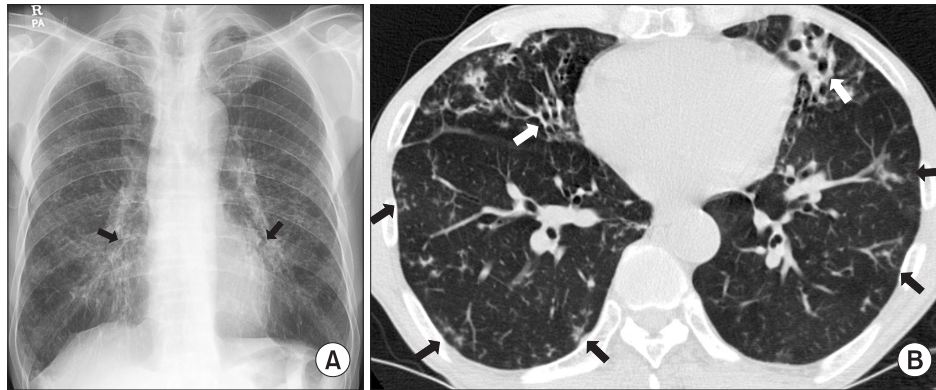


Figure 1. A 66-year-old male with bronchiectasis and nontuberculous mycobacterial lung disease caused by *Mycobacterium abscessus* subsp. *bolletii*. (A) Chest radiography revealed bilateral multifocal tram-track signs (black arrows), suggesting bronchiectasis. (B) A transverse chest computed tomography scan (3.0-mm-section thickness) revealed bilateral bronchiectasis (white arrows) in the middle right lobe and the lingular segment of the upper left lobe as well as multiple tree-in-bud appearances (black arrows), suggesting bronchiolitis in both lungs.

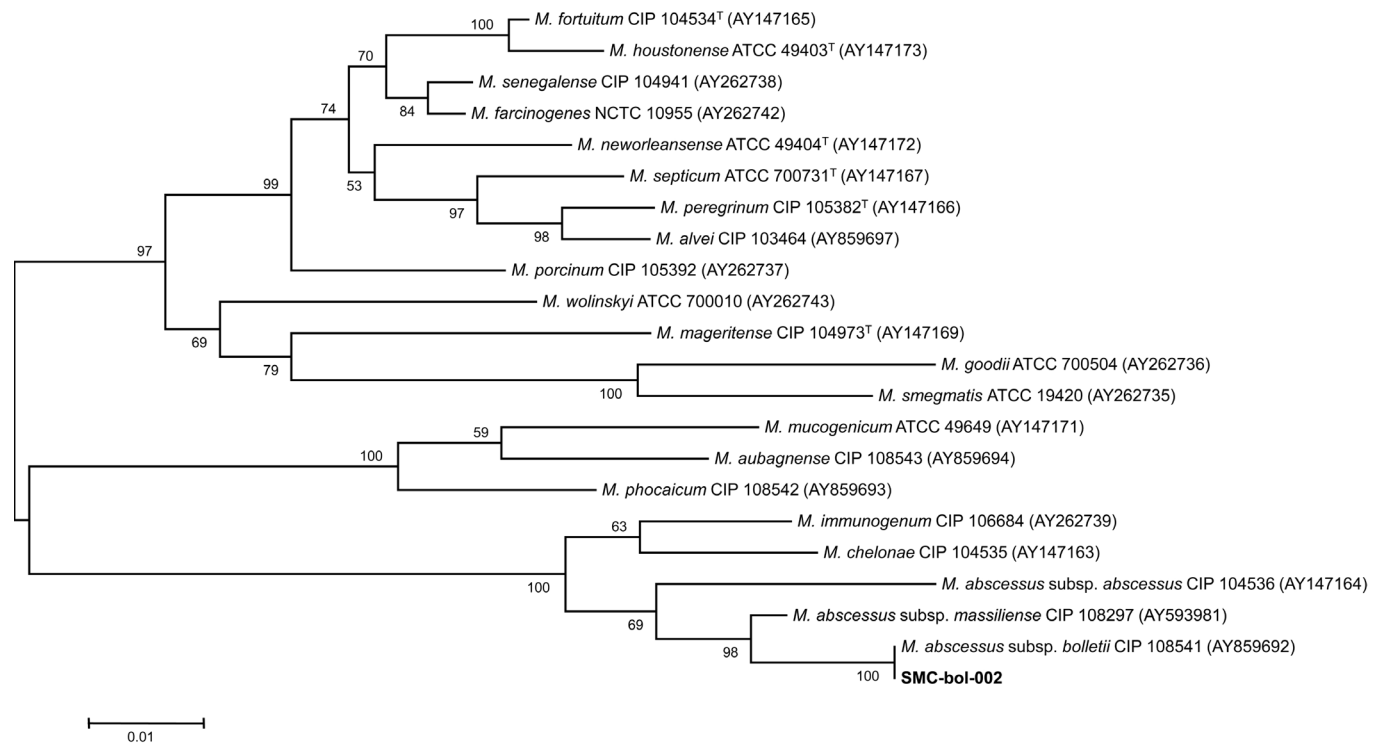


Figure 2. The phylogenetic position of isolate SMC-bol-002 and other species belong to the rapidly growing mycobacteria are based on *rpoB* sequences. This tree was constructed by using the neighbor-joining method and visualized with MEGA 5.0. The percentages at the nodes represent bootstrap levels which are supported by 1,000 re-sampled datasets. Scale bars indicate evolutionary distances in base substitutions per site. *M.*: *Mycobacterium*.

Table 1. Antimicrobial drugs and MIC breakpoints

Drugs	MIC ($\mu\text{g/mL}$) for category			MIC of the isolate ($\mu\text{g/mL}$)
	Susceptible	Intermediate	Resistant	
Amikacin	≤ 16	32	≥ 64	8
Cefoxitin	≤ 16	32–64	≥ 128	32
Imipenem	≤ 4	8–16	≥ 32	32
Clarithromycin	≤ 2	4	≥ 8	8
Ciprofloxacin	≤ 1	2	≥ 4	16
Moxifloxacin	≤ 1	2	≥ 4	8
Doxycycline	≤ 1	2–4	≥ 8	>32

Drug susceptibility testing was performed by using a broth microdilution method, according to the guidelines of the Clinical and Laboratory Standards Institute (CLSI)⁷.

MIC: minimum inhibitory concentration.

Physical examination showed that the patient was 172.3 cm tall and weighed 56.1 kg. Laboratory tests results were unremarkable. A human immunodeficiency virus antibody test was negative. The chest radiograph and computed tomography (CT) scan revealed multifocal bronchiectasis and bronchiolitis in both lungs that suggested the nodular bronchiectatic form of NTM lung disease (Figure 1).

The patient's sputum was positive for AFB staining, and NTM were isolated more than three times in a liquid culture system (Bactec MGIT 960 system; BD Diagnostics, Sparks, MD, USA). To identify the etiological agent, bacteria were initially propagated in 7H9 broth (Difco Laboratories, Detroit, MI, USA) supplemented with 10% (vol/vol) oleic acid-albumin-dextrose-catalase (BD Diagnostics) for 7 days at 37°C, sub-cultured in egg-based 3% Ogawa solid media (Shinyang, Seoul, Korea), and genomic DNA was extracted from the cultured bacteria. Initial species identification using a polymerase chain reaction-restriction fragment length polymorphism (PCR-RFLP) method based on the *rpoB* gene (Myc-ID; M&D Inc., Wonju, Korea) was *M. abscessus* complex⁵.

To speciate the isolates, sequencing analysis of the nearly complete 16S rRNA gene, partial *hsp65*, and *rpoB* sequences were performed using GenBank (<http://blast.ncbi.nlm.nih.gov/>) with the BLAST algorithm⁶. The 16S rRNA sequences showed 100% identity with *M. abscessus* subsp. *abscessus* (GenBank accession no. NR074427), *M. abscessus* subsp. *massiliense* (GenBank accession no. NR074421), *M. chelonae* (GenBank accession no. AY457082), and *M. abscessus* subsp. *bolletii* (GenBank accession no. NR043236). The *hsp65* and *rpoB* sequences were 100% identical to those of the *M. abscessus* subsp. *bolletii* type strain (GenBank accession nos. FJ607778 and AY859692). Phylogenetic analysis based on the *rpoB* sequences from the isolate SMC-bol-002 and from those of closely related species within the RGM showed that this strain belonged to *M. abscessus* subsp. *bolletii* (Figure 2).

Drug susceptibility testing was performed using a broth

microdilution method (Table 1)⁷. At the genetic level, the isolate was genotyped for *erm*(41) polymorphism and for *rrl* mutations; these are known as the two main mechanisms of macrolide resistance⁸. The isolate had the *erm*(41) gene with a T28 sequevar and no *rrl* mutation acquisition.

The patient received oral clarithromycin and moxifloxacin, along with an initial 4-week course of intravenous amikacin and cefoxitin. During 4 weeks of initial antibiotic treatment, his symptoms and CT lesions were improved and sputum culture results were negative after 2, 3, and 4 weeks after treatment. Although he took oral clarithromycin and moxifloxacin for a total duration of 24 months, follow-up sputum cultures were persistently positive after 2 months after antibiotic treatment.

Discussion

This is the first reported case of *M. abscessus* subsp. *bolletii* lung disease in Korea. Previous reports showed that patients with *M. abscessus* subsp. *bolletii* lung disease had mild compromised respiratory function, as was seen in the current report^{9,10}. The reported number of patients with *M. abscessus* subsp. *bolletii* lung disease was less than 10 before this case^{9,10}. The limited number of reports makes it difficult to characterize patients with *M. abscessus* subsp. *bolletii* lung disease.

The *M. abscessus* complex has undergone many taxonomic classification changes since its first description in 1953¹¹. The dramatic change in mycobacterial taxonomy came with the availability and reliability of DNA sequencing, including 16S rRNA, *rpoB*, and *hsp65*. Adekambi et al.¹² suggested that the *M. abscessus* complex should be divided into three species, *M. abscessus* sensu stricto, *M. massiliense*, and *M. bolletii*, according to the results of *rpoB* sequencing. Recent evidence based on comparative analysis of whole genome sequences has suggested that *M. abscessus* can be divided into three sub-

species: *M. abscessus* subsp. *abscessus*, *M. abscessus* subsp. *massiliense*, and *M. abscessus* subsp. *bolletii*¹³. It is important to distinguish the three subspecies of *M. abscessus* complex, because of their differences in susceptibility to clarithromycin³. Commonly, *M. abscessus* subsp. *abscessus*, *M. abscessus* subsp. *massiliense*, and *M. abscessus* subsp. *bolletii* are inducible resistant, susceptible, and resistant to clarithromycin, respectively³.

The combination of macrolide, cefoxitin (or imipenem), and amikacin has been recommended as the first line antimicrobial drug treatment for *M. abscessus* lung disease¹⁴. However, the appropriate duration of intravenous antibiotic therapy or combination of oral antibiotics is not known. We used intravenous antibiotics for 4 weeks as previously reported cases of *M. abscessus* lung disease¹⁵, because of the phenotypic similarities between *M. abscessus* subsp. *abscessus* and *M. abscessus* subsp. *bolletii*. Although drug susceptibility testing showed *in vitro* resistance, clarithromycin and moxifloxacin were prescribed during outpatient treatment following the previous report^{3,15}. We finally achieved improvement in his respiratory symptoms and prevented progression of radiological findings, although we were unable to achieve negative conversion of sputum AFB culture.

In summary, we report the first case of *M. abscessus* subsp. *bolletii* lung disease in Korea. *M. abscessus* subsp. *bolletii* lung disease should be considered when the pathogen is identified as *M. abscessus* complex by a non-sequencing method, such as PCR-RFLP, and has resistance to clarithromycin. In such cases, further molecular techniques may be needed to accurately identify the specific subspecies.

Acknowledgements

This work was supported by the Mid-career Researcher Program through a National Research Foundation grant funded by the Ministry of Education, Science and Technology (2011-0015546).

References

1. Koh WJ, Kwon OJ, Jeon K, Kim TS, Lee KS, Park YK, et al. Clinical significance of nontuberculous mycobacteria isolated from respiratory specimens in Korea. *Chest* 2006;129:341-8.
2. Macheras E, Roux AL, Bastian S, Leao SC, Palaci M, Sivadon-Tardy V, et al. Multilocus sequence analysis and *rpoB* sequencing of *Mycobacterium abscessus* (sensu lato) strains. *J Clin Microbiol* 2011;49:491-9.
3. Koh WJ, Jeon K, Lee NY, Kim BJ, Kook YH, Lee SH, et al. Clinical significance of differentiation of *Mycobacterium massiliense* from *Mycobacterium abscessus*. *Am J Respir Crit Care Med* 2011;183:405-10.
4. Koh WJ, Kwon OJ, Lee NY, Kook YH, Lee HK, Kim BJ. First case of disseminated *Mycobacterium bolletii* infection in a young adult patient. *J Clin Microbiol* 2009;47:3362-6.
5. Lee H, Park HJ, Cho SN, Bai GH, Kim SJ. Species identification of mycobacteria by PCR-restriction fragment length polymorphism of the *rpoB* gene. *J Clin Microbiol* 2000;38:2966-71.
6. Kim H, Kim SH, Shim TS, Kim MN, Bai GH, Park YG, et al. Differentiation of *Mycobacterium* species by analysis of the heat-shock protein 65 gene (*hsp65*). *Int J Syst Evol Microbiol* 2005;55(Pt 4):1649-56.
7. Clinical and Laboratory Standards Institute. Susceptibility testing of mycobacteria, nocardiae, and other aerobic actinomycetes: approved standard. 2nd ed. Document no. M24-A2. Wayne: CLSI; 2011.
8. Bastian S, Veziris N, Roux AL, Brossier F, Gaillard JL, Jarlier V, et al. Assessment of clarithromycin susceptibility in strains belonging to the *Mycobacterium abscessus* group by *erm*(41) and *rml* sequencing. *Antimicrob Agents Chemother* 2011;55:775-81.
9. Adekambi T, Drancourt M. *Mycobacterium bolletii* respiratory infections. *Emerg Infect Dis* 2009;15:302-5.
10. van Ingen J, de Zwaan R, Dekhuijzen RP, Boeree MJ, van Soolingen D. Clinical relevance of *Mycobacterium chelonae-abscessus* group isolation in 95 patients. *J Infect* 2009;59:324-31.
11. Moore M, Frerichs JB. An unusual acid-fast infection of the knee with subcutaneous, abscess-like lesions of the gluteal region; report of a case with a study of the organism, *Mycobacterium abscessus*, n. sp. *J Invest Dermatol* 1953;20:133-69.
12. Adekambi T, Berger P, Raoult D, Drancourt M. *rpoB* gene sequence-based characterization of emerging non-tuberculous mycobacteria with descriptions of *Mycobacterium bolletii* sp. nov., *Mycobacterium phocaicum* sp. nov. and *Mycobacterium aubagnense* sp. nov. *Int J Syst Evol Microbiol* 2006;56(Pt 1):133-43.
13. Bryant JM, Grogono DM, Greaves D, Foweraker J, Roddick I, Inns T, et al. Whole-genome sequencing to identify transmission of *Mycobacterium abscessus* between patients with cystic fibrosis: a retrospective cohort study. *Lancet* 2013;381:1551-60.
14. Griffith DE, Aksamit T, Brown-Elliott BA, Catanzaro A, Daley C, Gordin F, et al. An official ATS/IDSA statement: diagnosis, treatment, and prevention of nontuberculous mycobacterial diseases. *Am J Respir Crit Care Med* 2007;175:367-416.
15. Jeon K, Kwon OJ, Lee NY, Kim BJ, Kook YH, Lee SH, et al. Antibiotic treatment of *Mycobacterium abscessus* lung disease: a retrospective analysis of 65 patients. *Am J Respir Crit Care Med* 2009;180:896-902.