

Transcutaneous insertion of the Chitwood® clamp in case of minimally invasive cardiac surgery. Personal experience

F. SANSONE, F. CERESA, F. PATANÈ

SUMMARY: Transcutaneous insertion of the Chitwood® clamp in case of minimally invasive cardiac surgery. Personal experience.

F. SANSONE, F. CERESA, F. PATANÈ

We describe a simple trick consisting of an insertion of a trans-tho-

racic Chitwood® clamp (Scanlan International, Inc, St Paul, MN, USA) through a small skin incision (<1cm), via the second intercostal space along the anterior axillary line, in case of minimally invasive mitral surgery, through right thoracotomy. This trick has been used in more than 100 patients and no complication or discomfort have been reported so far.

KEY WORDS: Chitwood clamp - Minimally invasive surgery.

Introduction

As it is nowadays well accepted, the minimally invasive approach for the cardiac valve surgery should be the standard of care. The advantages of the minimally invasive approaches are widely accepted for a faster postoperative outcome with lower incidence of bleeding, discomfort and in hospital stay. As the clinical practice in minimally invasive surgery is increasing, some tricks have been proposed to obtain a smaller surgical access. In case of minimally invasive approach both for mitral and tricuspid surgery, a small right thoracotomy (6-8 cm) in the sub-mammary fold along the anterior clavicular line through the fourth intercostal space yields an excellent direct-vision. The cardiopulmonary bypass is usually established amongst the right femoral artery and a Y shaped venous line among the right femoral vein and the right jugular vein. The aortic vent and the aortic clamp are usually inserted through the thoracotomy and this may worsen the surgical view, requiring a larger skin incision. Since we have routinely used the minimally invasive approaches for the mitral, tricuspid and inter-atrial diseases, we have tried to minimize the skin incision with

a concomitant improvement of the surgical vision, reducing the devices inserted through the right thoracotomy. The use of the Heart Port System with the endoaortic clamp is an attractive alternative, despite the risk of some pitfalls. Unfortunately, this innovative device is quite expensive and it is not easily available.

In order to address this matter with a contained cost, we present a simple trick using a trans-thoracic Chitwood® clamp (Scanlan International, Inc, St Paul, MN, USA).

Patients and methods

We have used this simple trick in more than 100 patients, operated on for valve or inter-atrial diseases. Chitwood® clamp is inserted through a small skin incision (<1 cm) via the second intercostal space along the anterior axillary line (Fig. 1).

After the thoracotomy and the pericardial incision, the great vessels and the atrium are exposed. Thus, the trans-thoracic clamp is inserted to check the correct position, allowing a safe aortic clamp with no surgical vision impairment. After cardiopulmonary bypass establishment, the aorta was clamped (no dissection around the aorta is required) and the heart protected by a blood cardioplegia.

Results

No complication has been reported so far and the trans-thoracic positioning of the Chitwood® clamp does not interfere with the surgical view, since it is away from

“Ospedali Riuniti Papardo-Piemonte” Hospital, Messina, Italy
Division of Cardiac Surgery

© Copyright 2013, CIC Edizioni Internazionali, Roma

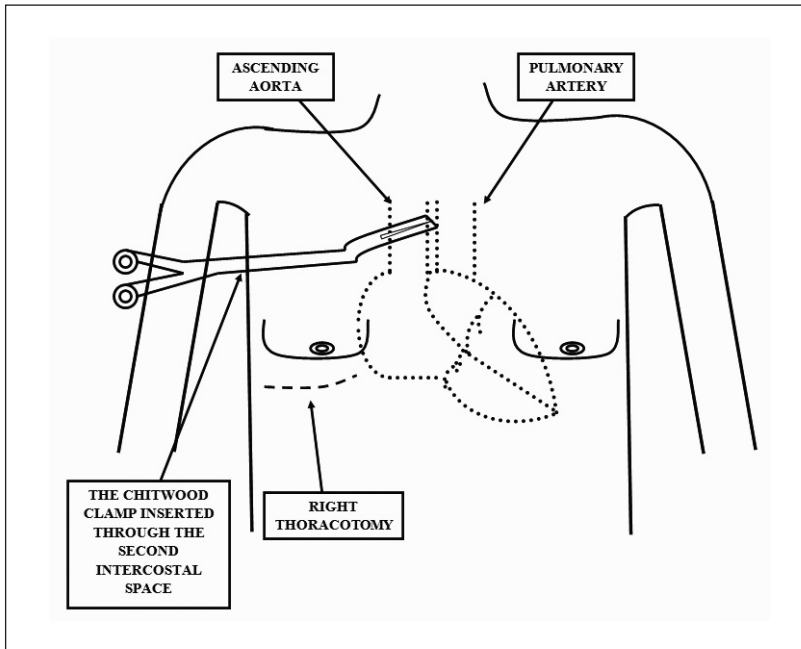


Fig. 1 - Schematic presentation of the trans-thoracic Chitwood® clamp, inserted through a small access (< 1 cm) via the second intercostal space along the anterior axillary line.

the surgical field. Moreover, the risk of interweaving of the stitches used for surgery is almost absent because the clamp is away.

Discussion and conclusion

In our experience, the use of a trans-thoracic clamp has allowed a progressive reduction of the dimension of the skin incision, from the initial 8-9 cm to the 6-7 cm now. Moreover, this additional skin incision is used as

an access for the chest drain at the end of the procedure and it is usually closed by a U silk stitch (after chest drain removal).

The use of trans-thoracic Chitwood® clamp has been already reported from authors involved in minimally invasive surgery in case of dysfunction of the Heart Port endoclamp (1) or in case of video-assisted surgery. The use of the trans-thoracic clamp even in case of non-video assisted right thoracotomy is a simple trick leading to a reduction of the skin incision and to an improvement of the surgical procedure.

References

1. Aybek T, Dogan S, Wimmer-Greinecker G, Westphal K, Mortiz A. The micro-mitral operation comparing the Port-Access technique and the transthoracic clamp technique. *J Card Surg* 2000;15:76-81.