

Transient attenuation of the amplitude of the QRS complexes in the diagnosis of Takotsubo syndrome

John E Madias^{1,2}

European Heart Journal: Acute Cardiovascular Care
2014, Vol. 3(1) 28–36

© The European Society of Cardiology 2013

Reprints and permissions:

sagepub.co.uk/journalsPermissions.nav

DOI: 10.1177/2048872613504311

acc.sagepub.com



Abstract

Background and objectives: Currently, there are no specific diagnostic electrocardiogram (ECG) signs for Takotsubo syndrome (TTS) to differentiate it from acute coronary syndromes (ACS). Myocardial oedema has been detected by cardiac magnetic resonance imaging in patients with TTS. Recently it has been postulated that myocardial oedema may be the cause of low QRS voltage (LQRSV) in the admission ECG and attenuation of the amplitude of the QRS complexes (AAQRS) in serial ECGs, noted in a few published cases of patients with TTS. The objective of this study was to evaluate whether the admission ECG of patients with documented TTS reveals LQRSV and whether AAQRS is found when serial ECGs are compared in such patients.

Methods: This study evaluated the prevalence of LQRSV in the admission ECG and AAQRS in serial ECGs in patients with TTS. ECGs of 368 patients with TTS from published reports in the international literature were evaluated for LQRSV (≤ 5 mm in limb leads and/or ≤ 10 mm in precordial leads) and AAQRS in serial ECGs.

Results: LQRSV was seen in 91.5% of 200 patients with TTS and one ECG, with a distribution of 49.0, 42.8, 51.0, 52.0, and 46.9%, in lead aVR, and inferior, anterior, lateral, and high lateral ECG lead groups, respectively. AAQRS was seen in 93.5% of 168 patients with TTS and two or more ECGs, with a distribution of 78.3, 74.5, 60.1, 70.7, and 74.5% in lead aVR, and inferior, anterior, lateral, and high lateral ECG lead groups, respectively.

Conclusions: LQRSV and AAQRS are highly prevalent ECG signs in patients with TTS, and should be useful in aiding in its diagnosis and differentiation from ACS, on first contact with the patient on admission to the hospital, and the ensuing 24 hours, in conjunction with echocardiography and coronary arteriography.

Keywords

Attenuation of the QRS complexes, cardiac magnetic resonance imaging, diagnosis, electrocardiogram, low ECG QRS voltage, myocardial oedema, Takotsubo syndrome

Received: 14 May 2013; accepted: 18 August 2013

Introduction

Takotsubo syndrome (TTS) is an acute reversible cardiomyopathy affecting primarily the left ventricle (LV), encountered most often in postmenopausal women shortly after exposure to mental or physical stress, resembling an acute coronary syndrome (ACS) in its clinical presentation, frequently not associated with traditional risk factors for ACS, and characterized by electrocardiogram (ECG) changes indistinguishable from those seen in ACS, modest release of cardiac biomarkers, normal or nonobstructive coronary arteries, and depressed LV function with akinesis/dyskinesis ('ballooning') of the apex, hypokinesis/akinesis of the medial LV wall, and hyperkinesis of the LV base. In spite of the stormy presentation of TTS,

clinical outcome is benign, with full recovery of LV function realized by most patients in the few days to weeks after hospital admission, although there seem to be some patients experiencing a so-called delayed recovery of the region of the left ventricular dysfunction, and recurrence is rare. However,

¹Icahn School of Medicine at Mount Sinai, New York, USA

²Elmhurst Hospital Center, Elmhurst, USA

Corresponding author:

John E Madias, Division of Cardiology, Elmhurst Hospital Center, 79-01 Broadway, Elmhurst, NY 11373, USA.

Email: madiasj@nychhc.org

morbidity is substantial, and occasionally TTS leads to mortality. Although the condition was known for many decades,¹ it was systematically characterized in Japan in 1990s,^{2,3} where its distinctive LV wall motion abnormalities in cardiac systole resembling 'takotsubo', a traditional fishing pot used in Japan to capture octopuses, was described. Perusal of the vast international literature (1754 entries, in PubMed in response to the MeSH term 'takotsubo'; www.ncbi.nlm.nih.gov/pubmed/?term=takotsubo, consulted September 2013) indicates that presentation of patients with TTS covers the entire gamut of conceivable patient-physician encounters, transcending specific medical, surgical, paediatric, gynaecological, and psychiatric subspecialties, and thus knowledge about this disease, and a high index of suspicion, is required by all physicians.^{4,5}

It is important to make the diagnosis of TTS, and particularly to distinguish TTS from ACS [typically acute anterior ST-elevation myocardial infarction (STEMI) but also non-STEMI], since management of these two conditions differ substantially after clarification of the coronary artery status [thrombolysis or mechanical treatment (percutaneous coronary intervention with coronary stenting for STEMI or non-STEMI) or conservative (in the case of TTS)], although pharmacological treatment strategies in the acute phase of TTS or ACS are not different at all, presently. Cardiac catheterization and transthoracic echocardiography (ECHO) are essential and invariably provide the solution, but it would be advantageous if, early after clinical presentation, the ECG (the first test employed) could offer a diagnostic aid. The ECG in patients with TTS shows transient ST-segment elevation (+ST) or ST-segment depression (-ST), followed by persistent T-wave inversion changing in amplitude and prolongation of the QTc interval.⁴⁻¹¹ However, currently there are no specific ECG signs distinguishing TTS from ACS, and specifically from acute STEMI.⁴⁻¹³ Recently it has been noted that TTS is associated with transient attenuation in the amplitude of QRS of the ECG voltage (AAQRS);¹⁴ the observation was based on a comparison of serial ECGs of five reported patient cases with TTS, who were also found to have myocardial oedema, diagnosed by cardiac magnetic resonance imaging (MRI), early in their clinical course.^{15,16} A link between myocardial oedema and AAQRS in the ECG has been previously postulated,¹⁷ based on a canine experimental heart failure model,¹⁸ and provided the impetus to evaluate this hypothesis in a large cohort of patients with TTS.

Methods

Database

This study reviewed all 614 papers, spanning the time interval 2000-13, identified in PubMed via the MeSH search term 'electrocardiogram in takotsubo syndrome' (www.ncbi.nlm.nih.gov/pubmed/?term=electrocardiogram+i+tak

otsubo+syndrome, consulted January 2013). The papers were read, and categorized in the following four groups: (1) papers whose whole article could not be accessed via the Icahn School of Medicine at Mount Sinai Levy Library online collections; (2) papers which did not include ECGs, but only a description of ECG findings; (3) papers with one ECG recorded on admission of patients; and (4) papers with two or more ECGs, with at least one obtained on admission to the hospital. Papers describing patients with two or more ECGs had such tracings recorded on admission, with one or more additional ECGs obtained during hospitalization, at outpatient follow up, or prior to the TTS attack (usually shortly prior to the inception of the TTS, e.g. preoperatively or preprocedurally, or for TTS suffered in the hospital, or in patients admitted for other medical reasons).

Electrocardiogram analysis

The tracings were magnified in gradation of increasing magnification on the screen of the computer for review of the entire ECG and then of individual ECG leads. For patients with only one ECG, the tracing was evaluated regarding low voltage of the QRS complexes (≤ 5 mm in limb leads or ≤ 10 mm in precordial leads) (LQRSV),¹⁹ Almost all the ECGs from the published reports used in the analysis included a calibration signal; in the rare occasion that this was missing the ECG grid (distance from thick-to-thick lines) was used to assess amplitude of QRS complexes or difference (if any) of the degree of magnification between the two ECGs under comparison. LQRSV was evaluated in any of the inferior (II, III, aVF), anterior (V1-V3), lateral (V4-V5), and high lateral (I, aVL) leads. Also lead aVR was evaluated, as a representative ECG index of all limb leads,²⁰ due to its location opposite the cardiac apex which often is involved in TTS ('takotsubo' search). When two or more ECGs were available, the tracings were evaluated regarding the presence of AAQRS during serial ECGs during hospitalization, or in comparison with the ECG obtained prior to the illness, or at follow up, and diagnosis of AAQRS was made even if the ECG with the lowest voltage had not attained the level of LQRSV. Comparison between ECGs was based on the two ECGs showing the largest difference in the QRS amplitudes. AAQRS was evaluated in any of the inferior, anterior, lateral, and high lateral ECG lead groups, and lead aVR (*vide supra*). A positive diagnosis for AAQRS in the subgroup of patients with two or more ECGs was only made when two of the three ECG leads, comprising the inferior, anterior, and lateral ECG lead groups, both ECG leads comprising the high lateral group, and lead aVR, showed AAQRS. Although it was visually feasible to categorize ECGs as showing LQRSV in the magnified ECG tracings on the computer screen, by comparing the total QRS amplitude in each ECG lead with the distance between the thick lines (i.e. 5 mm) of the ECG grid, characterization of

AAQRS in comparisons of two ECGs employing a quantitative approach (in mm) was not feasible, and a semiquantitative assessment was employed instead, which was based on the appreciation of gross, unmistakable AAQRS between the QRS amplitude of the same ECG lead in the two tracings under comparison, by repeatedly toggling on the two ECG tracings on the computer screen and examining at each time lead aVR and specific ECG lead groups. The time interval between the two ECGs compared for AAQRS in patients with two or more ECGs was considered in days, assuming all months having 30 days, when the paper referred to the time interval between ECGs, in months. Assessment of two ECGs, when the morphology was abnormal, for AAQRS was carried out only when both ECGs showed similar changes in morphologies [i.e. intraventricular conduction delay (IVCD), bundle branch block (BBB), or pacemaker-based activity (PACER)]. Recurrences of TTS were considered as new cases.

Imaging analysis

Data on ECHO, cardiac contrast ventriculography in the setting of cardiac catheterization, computed tomographic angiography, and cardiac MRI data were evaluated regarding regional or global hypokinesis/akinesis/dyskinesis, and the few cases of patients with myocardial oedema diagnosed by cardiac MRI were reviewed. The presence or absence of apical LV akinesis/dyskinesis was noted, and the cases with TTS involving the medial LV, base of LV ('inverse TTS'), or right ventricle, were noted. No correlations between LQRSV or AAQRS and different types of LV wall motion abnormalities were carried out; also no correlations between LQRSV or AAQRS and different LV location of the wall motion abnormalities were carried out, due to paucity of patients with TTS involving the medial and basal regions of LV.

Results

From the 614 papers whose abstracts were initially reviewed, 118 were electronically unavailable in their entirety (mostly non-English literature), two were animal studies, one described a patient with hypertrophic cardiomyopathy, one described a patient with myocarditis, 185 did not include an ECG, and one included a patient who had a Holter ambulatory ECG recording. The remaining 306 consisted of 151 papers with one ECG, and 161 papers with two or more ECGs. The reason that these two subgroups totalled 312, instead of 306, is that six of the papers with two or more ECGs included also patient cases with one ECG, and thus were counted under both categories. Papers often included case presentations and ECGs of more than one patient. The total number of patients for whom there was one ECG was 200 and the total number of patients for whom there were two or more ECGs was 168.

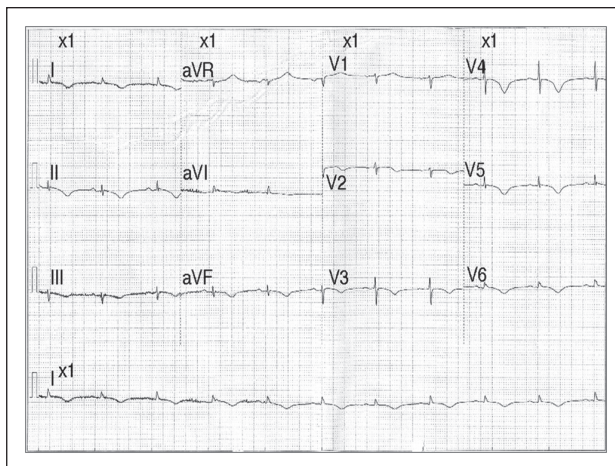


Figure 1. Admission ECG of a 79-year-old woman who suffered an unprovoked attack of Takotsubo syndrome, showing low QRS voltage in all leads except V3 and V4.

Reproduced from Teo B. A mimicry of an acute coronary syndrome. *Emerg Med J* 2007; 24: e25, with the permission of BMJ Publishing Group.

Patients with one ECG

From the 200 patients with one ECG, TTS involved the LV apex in 183 patients, did not involve the LV apex [but the midventricular and/or basal territory(ies)] in 15 patients, was not clearly stated whether there was such an involvement in one patient, and involved the right ventricle exclusively in one patient; one patient had a recurrence of TTS, and one patient's ECG revealed left BBB. In six patients, only precordial ECGs were available. LQRSV was seen in all 12 ECG leads in 21 (10.5%) patients, involved all six limb leads in 47 (23.5%), patients, and all six precordial leads in 52 (26.0%) patients. If the six patients with only precordial ECG leads were excluded from the total of 200 patients, LQRSV in all 12 ECG leads was found in 10.8%, and in all six ECG limb leads in 24.2% of patients. No ECG leads showed LQRSV in 19 patients. Figures 1 and 2 show representative ECGs of the patients with TTS with one ECG, used in the analysis. Table 1 shows patients who had a LQRSV in lead aVR and anterior, inferior, lateral, and high lateral leads in the cohort of patients with TTS and one ECG. Thus LQRSV was present in ~40–50% of patients with TTS in lead aVR and the four ECG lead groups analysed. The 15 patients with TTS involving myocardial territory(ies) other than the LV apex had a lower frequency of LQRSV in lead aVR (five cases), and inferior (four cases) than the overall group of patients with one ECG (Table 1). In four patients, a comment about myocardial oedema noted in cardiac MRI was included, and LQRSV was present in all ECG group leads and lead aVR except the lateral leads in one patient, in all ECG group leads and lead aVR except the anterior leads in one patient, in all ECG group leads except the inferior and lateral leads and lead aVR in one patient, and none of the ECG leads in one patient.

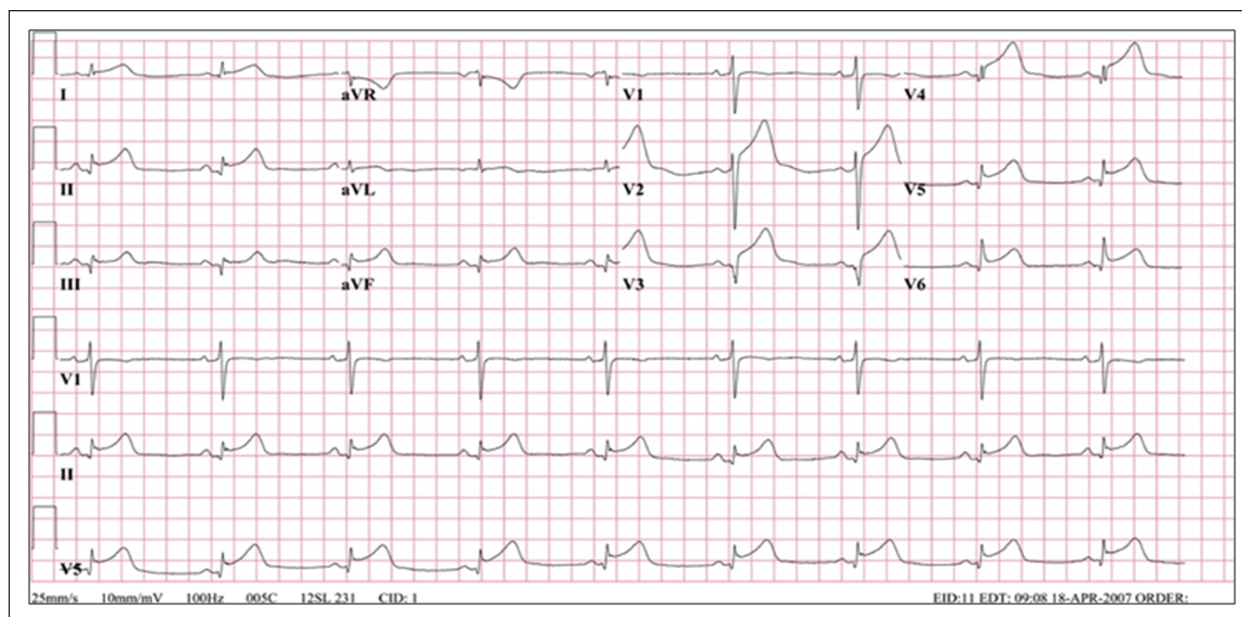


Figure 2. Admission ECG of an 80-year-old woman who developed an attack of Takotsubo syndrome 30 minutes after attempting to resuscitate her husband who had suffered a cardiac arrest, showing low QRS voltage in all limb and V3–V6 ECG leads, along with ST-segment elevations and Q-waves.

Reproduced from Van Der Bilt IAC, Van Dijk J, Van Den Brink RBA, et al. Examining the octopus pot: multimodality imaging of a typical Takotsubo cardiomyopathy. *Echocardiography* 2008; 25: 794–796, with the permission of John Wiley & Sons.

Table 1. Low-voltage ECG and attenuation of ECG voltage in lead aVR and anterior, inferior, lateral, and high lateral ECG leads in patients with Takotsubo syndrome.

	aVR	INF	ANT	LAT	HLAT
Patient cases with one ECG (n=200)	95 (49.0) ^a	83 (42.8) ^a	102 (51.0)	104 (52.0)	91 (46.9) ^a
Patient cases with two or more ECGs, (n=168)	123 (78.3) ^a	117 (74.5) ^a	101 (60.1)	118 (70.7) ^b	117 (74.5) ^a

Values are n (%).

^aPercentage calculated on the basis of 194 total cases for the patients with one ECG and 157 total cases for the patients with two or more ECGs.

^bPercentage calculated on the basis of 167 total cases of patients with two or more ECGs.

ANT, anterior ECG lead group; aVR, ECG lead aVR; HLAT, high lateral ECG lead group; INF, inferior ECG lead group; LAT, lateral ECG lead group.

Patients with two or more ECGs

From the 168 patients with two or more ECGs, TTS did not involve the LV apex in eight patients, it was not clearly stated whether there was such an involvement in two patients, one patient's ECG revealed right BBB, and two patients had a PACER. In 11 patients, only precordial ECGs were available. In one patient, the lateral precordial leads were not included in the ECGs. AAQRS was seen in all the ECG leads between two ECGs, in 63 patients, and 11 patients did not show AAQRS in any of the ECG leads between their two ECGs. Figures 3 and 4 show representative ECGs of the patients with TTS with two or more ECGs, used in the analysis. Table 1 shows patients who had AAQRS in lead aVR and anterior, inferior, lateral, and high lateral leads in the cohort of patients with TTS and two or more ECGs. For the cohort of patients with two or more ECGs, AAQRS was present in ~60–80% of patients with TTS, in lead aVR and the four

ECG lead groups analysed. Time interval between ECGs was (mean±SD) 15.0±27.66 days (range 0.003–180 days; n=165). In three patients, specific information about such time interval was not provided (in one patient no mention, in one patient 'several days', and in one patient 'admission–discharge' statements were included); in one patient, the time interval was 4 min, during an exercise treadmill test. In seven patients, a comment about myocardial oedema noted in cardiac MRI was included and AAQRS was present in all ECG group leads and lead aVR in five patients and in all ECG group leads and lead aVR except the anterior in two patients.

Discussion

What is novel about the present study is the description of a high prevalence of LQRSV and/or AAQRS in the ECGs of patients with TTS. Before elaborating further on this, an outline of current status of the field is in order.

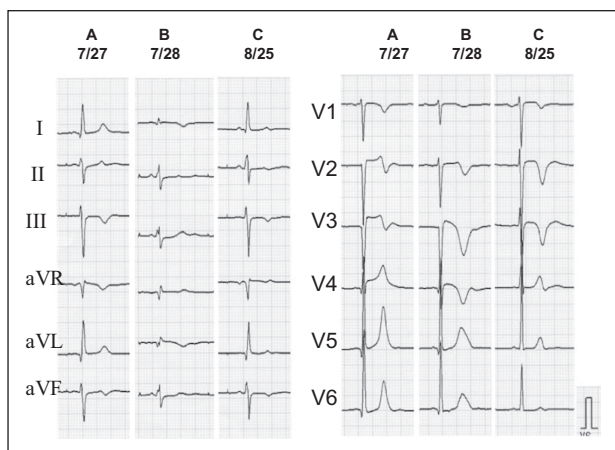


Figure 3. ECGs on days 1 and 2 of hospitalization and at 30 days follow up (A–C, respectively) of a 59-year-old woman who suffered Takotsubo syndrome in the setting of an epileptic seizure. The reversible attenuation of the amplitude of the QRS complexes (day 2) in the ECG leads, is clearly shown in the limb leads and leads V1 and V2, in comparison with the QRS amplitude on days 1 and 30.

Reproduced and adapted from Sakuragi S, Tokunaga N, Okawa K, et al. A case of takotsubo cardiomyopathy associated with epileptic seizure: reversible left ventricular wall motion abnormality and ST-segment elevation. *Heart Vessels* 2007; 22: 59–63, with the permission of Springer.

prolongation. The T-wave inversion in the precordial leads V2–V4 is referred to as the Wellens' ECG pattern, and is also seen in the setting of a life-threatening presentation of ACS due to left main or anterior descending coronary artery occlusion.^{15,21–23} Occasionally patients with TTS present with T-wave inversions in their first ECG; it is conceivable that in such patients a brief phase of +ST, at the onset of the illness, is missed. Rarely transient T-wave peaking and Q-waves may be seen in the ECG. Also some patients have developed transient BBBs, or IVCDs, or complete AV block ('takotsubo' search). Some authors have attempted to devise ECG indices allegedly more sensitive or specific for TTS, by using the +ST/–ST magnitude in different specific ECG leads or groups of leads. Thus they have attempted to distinguish TTS from acute (particularly anterior) STEMI by the lower rate of Q-waves,^{4,5} absence or rarity, of reciprocal ST-segment changes,^{4,5,9,12} more frequent +ST in the inferior leads,⁵ and higher ratio of the sums of +STs in leads V4–V6 to the sums of +STs in leads in V1–V3, and longer QTc in patients with the former than the latter.⁴ Others have reported mild +ST (<1.5 mm), absence of –STs, and a summated amplitude of the S-wave in V1 plus the R-wave in V6 <1.5 mV.⁹ Four phases in the ECG evolution have been described in patients with TTS starting from +ST, and followed by T-wave inversion, decrease in the depth of the

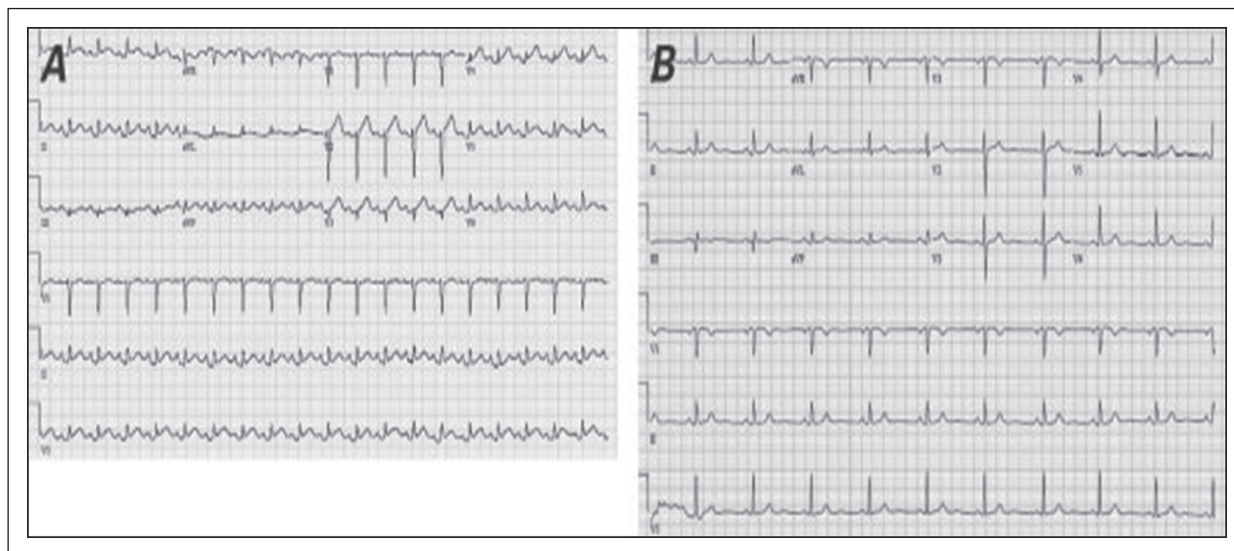


Figure 4. ECGs of an 84-year-old woman on presentation with her fourth attack of Takotsubo syndrome after being emotionally distressed for 2 days, on the anniversary of her husband's death. Note the attenuation of the amplitude of the QRS complexes in the admission ECG (A) in comparison with an ECG recorded 1 year earlier (B) in all ECG leads except V1 and V2, although partially this is due to magnification in B which is greater than it is in A, as appreciated from the calibration signal and the ECG grid thick-to-thick lines distance. Reproduced from Vittala SS, Najib MQ, Click RL, et al. Left anterior descending coronary artery stenosis in a patient with Takotsubo cardiomyopathy. *Tex Heart Inst J* 2012; 39: 125–128, with the permission of the Texas Heart Institute.

Previous work on ECG in TTS

ECG in patients presenting with TTS is indistinguishable from that associated with ACS, and consists of +STs or –STs, with rapid conversion to T-wave inversions, and QTc

inverted T waves, and giant inverted T waves with QTc prolongation, which persisted 2 or more months until recovery.⁷ Prolongation of the QTc was significantly associated with the occurrence of ventricular arrhythmias.¹¹ Although

patients with TTS have less prominent +STs in the anterior precordial ECG leads than patients with anterior STEMI, such finding is not sufficient for reliable emergency differentiation of these two conditions.^{12,13,24,25} Less frequent association with +ST in V1 and more frequent association with +ST in the inferior limb leads and -ST in aVR,²⁶ +ST in V3-V5 and no +ST in V1,²⁶ and deeper and more widely distributed T-wave inversions with positive T-waves in aVR and no negative T-waves in V1²⁷ have been noted in TTS than in patients with acute anterior STEMI, although the last may not apply to Caucasian patients.²⁸ Absence of -ST or +ST in inferior leads, especially if the +ST in lead II \geq lead III²⁹ or +ST in leads V2 <1.75 mm and V3 <2.5 mm,³⁰ are highly suggestive of TTS. Some have suggested that the extent and magnitude of +STs are potentially useful predictors of in-hospital complications in patients with TTS.³¹ The reverse type of TTS is characterized by the less frequent occurrence of T-wave inversions.¹⁰ The problem of distinguishing TTS from other syndromes is further compounded by reports revealing ECG similarities in TTS and acute pericarditis.³² It appears that distinguishing TTS from ACS and other acute pathology employing the ECG is problematic.^{30,32,33} Although transient AAQRS is noted in the ECG examples in figures of published reports,⁷ the authors have failed to recognize its diagnostic significance.

Present study

This study showed a high prevalence of LQRSV in patients with TTS and one ECG (Table 1). Although it is implied that there was AAQRS in comparison with previous ECGs in these 200 patients and thus the admission ECG revealed LQRSV, such AAQRS was not documented but presumed. Only 19 of 200 patients (9.5%) had ECGs with no LQRSV in aVR or any of the groups of the ECG leads analysed. LQRSV is found in patients with pulmonary pathology, pericardial effusion, amyloidosis, obesity, as a normal variant, and in the elderly.¹⁹ However, what was observed in the ECG of these 200 patients with TTS (Table 1) was above what is expected in the ECGs of cohorts of elderly, primarily women, in the general population.¹⁹ Normal values of amplitudes of the R-waves and S-waves have been published, but these sources do not include amplitudes of the total QRS complexes, or prevalence of LQRSV or provide data for mean values and ranges for the amplitudes of R-waves, and S-waves for Caucasians, Chinese, and Japanese subjects.¹⁹ There are no data on the amplitude of the total QRS complexes of patients with ACS, which would be relevant for comparison with what was observed in patients with TTS in this study. The decreased summated S in V1 and R in V6, noted previously,⁹ may be a reflection of the LQRSV described in this study. The data on the dynamic changes of the ECG from the subgroup of patients with TTS and two or more ECGs, revealed a very prevalent

transient AAQRS of the ECG in lead aVR, and many, or sometimes all 12, ECG leads (Table 1). Only 11 of 168 patients (6.5%) had ECGs with no AAQRS in aVR or any of the groups of the ECG leads analysed. Such AAQRS was as a rule significant, and easily perceivable visually at a glance, while occasionally AAQRS was marked (Figure 3). The transient nature of AAQRS was shown in patients with two or more ECGs, when an ECG from follow up was available (Figure 3). The importance of lead aVR, noted by others in terms of the presence of -ST and positive T-waves,^{25,27} was shown by the highest percentage of AAQRS in the patients of this study (Table 1) and underscores the diagnostic importance of its location facing the LV apex, the main region involved in TTS. Also the more prevalent AAQRS in the lateral than anterior precordial ECG leads (Table 1) reflects a parallel of the higher +ST previously noted in lateral than anterior precordial ECG leads in patients with TTS.^{4,30} The results shown on Table 1 should be contemplated in the context of the strict characterization of LQRSV and AAQRS, as described in the Methods. The high sensitivity of LQRSV and AAQRS, shown by the high prevalence of these indices in the ECGs of the analysed patient cohort, suggest that these ECG signs may be useful in the diagnosis of TTS. Although specificity was not formally evaluated by inclusion of a non-TTS cohort (e.g. a subgroup of patients with ACS), vast experience with patients presenting with ACS has not shown such reversible ECG changes as the ones presented herein. However, it would be prudent to scrutinize the ECGs of patients with ACS regarding transient LQRSV and AAQRS. The value of this work would be enhanced if there was a control group of patients with ACS to ascertain whether LQRSV and AAQRS have only a high prevalence in patients with TTS. However, it should be emphasized herein that TTS is associated with reversible LQRSV and AAQRS, and such ECG changes in the setting of myocardial necrosis of the ACS are intuitively expected to be more stable or permanent. It is conceivable that the prevalence of LQRSV and AAQRS noted in this study is underestimated, considering that it was based on the ECGs available in the literature, often acquired far apart and at different in-between time intervals and not on recorded serial daily ECGs. On the other hand, the present study investigated cases of TTS from the literature and thus this design may suffer from publication bias (more cases with impressive ECG changes may be published compared to cases that occur in daily practice). The importance of the ECG diagnostic criteria for TTS, proposed herein, will be undoubtedly further enhanced by observations of serial daily (or even more frequent during the acute phase of the illness) ECGs starting from the first ECG at the site of first medical contact to the last follow-up ECG. Specificity of the LQRSV for TTS can be increased by considering the presence of this ECG sign in patients with suspected TTS and the absence of other factors which could have led to LQRSV

(obesity, chronic obstructive lung disease and emphysema, pericardial effusion, peripheral oedema, and lung congestion). However, new-onset LQRSV (comparison with the most recent available prior to the hospital admission ECG) or AAQRS documented by comparison of serial ECGs recorded during the first 24 hours following hospital admission would ensure that the LQRSV and AAQRS are very specific for the diagnosis of TTS.

Mechanism of AAQRS in TTS

Data using cardiac MRI have documented the presence of transient myocardial oedema in patients with TTS.^{15,16,22,23,34–37} Pertinent to the hypothesis that LQRSV and AAQRS are mechanistically related to myocardial oedema is the high prevalence of these ECG changes in the 11 patients who had myocardial oedema diagnosed by cardiac MRI in the present study. Also, the lower rate of LQRSV in lead aVR and the inferior leads in the 15 patients with other than apical TTS involvement than in the total cohort which included patients with primarily apical involvement (Table 1) provides a parallel to the recently reported ‘apicobasal gradient of LV myocardial oedema’,²² which implies that ECG leads oriented along the LV anatomical axis [right superior to left inferior (aVR), and superior to inferior (inferior leads)] are expected to be more impacted by the apicobasal gradient of myocardial oedema than leads reflecting other than LV apical involvement. Interestingly, myocardial oedema is paralleled by persisting T-wave inversions in the ECG, which persist many weeks after restoration of LV function,^{15,16,22} and the reverse type of TTS (with normally contracting LV apex and presumably no myocardial oedema in that site) is associated with less frequent occurrence of T-wave inversions.¹⁰ It has been postulated recently that LQRSV or AAQRS is due to myocardial oedema.¹⁴ Although LQRSV and AAQRS is usually attributed to a decrease in the electrical resistance of the passive volume conductor (extracardiac phenomenon),³⁸ based on Ohm’s law ($V=I \times R$, where V =voltage, I =current, R =resistance), previous work has shown that myocardial ischaemia or heart failure also leads to transient decrease in the voltage of myocardial electrograms recorded from the epicardial surface.¹⁸ Thus myocardial oedema *per se* probably results in LQRSV or AAQRS in addition to such change due to lung congestion, pleural effusion, and other extracardiac influences.¹⁷ Future correlations of ECG, cardiac MRI, and ECHO (transient regional LV wall thickening) findings will undoubtedly confirm the causative role of myocardial oedema in LQRSV and AAQRS in TTS. LQRSV may also partially be due to counterbalancing of the depolarization vectors from opposite myocardial planes, since in TTS the topography of myocardial involvement is circumferential, in contrast to segmental involvement in patients with ACS with occlusion of a particular coronary artery. However, in the case of ECG lead aVR, LQRSV

should be attributed only to myocardial oedema, since this lead is positioned opposite the myocardial apex, without any other intervening myocardial territory which would have interacted with the apical region, with resultant counterbalancing of the depolarization vectors. However, since the percentage of LQRSV of prevalence in lead aVR was not higher than the one noted in the other four ECG lead groups (Table 1), myocardial oedema, rather than counterbalancing of opposite myocardial depolarization vectors, appears to be the reason for LQRSV. However, this issue can be further dissected by quantitative data on the effect of AAQRS in different ECG leads in patients with TTS, based on comparisons of serial ECGs, before, during, and after the inception of the clinical episode.

A detailed literature research in PubMed, employing the MeSH term ‘electrocardiogram voltage and catecholamines’ (www.ncbi.nlm.nih.gov/pubmed/?term=electrocardiogram+voltage+and+catecholaamines), consulted September 2013), yielded 54 entries, with most of the available data referring to ST-segment, T-wave, and QTc repolarization changes attributed to catecholamines. Remarkably, there was a letter to the Editor published 16 years ago³⁹ describing reversible AAQRS in a woman with pheochromocytoma, with identical ECG changes to the ones depicted in Figure 3 of this report. If such catecholamine effects do exist, therapy with β -blockers would be relevant, potentially alleviating the catecholamine influence. Several patients in this series were treated with β -blockers during the acute phase of TTS, hospitalization, and follow up, or were on maintenance β -blocker therapy prior to the admission with TTS, but no numerical data were gathered about this because the authors of the published reports were not systematic in the description of the provided therapy, which varied from detailed to sketchy or missing.

Clinical implications

LQRSV or AAQRS in repeat ECGs in patients admitted with chest pain, dyspnoea, fatigue, unexplained heart failure or symptoms/signs of ACS, particularly in elderly patients, postmenopausal women, or subjects exposed to any physical or mental stress, should alert physicians about the possibility that the underlying affliction may be TTS. AAQRS measured over 24 hours in serial ECGs may be considered as coming far too late as a diagnostic tool in patients with suspected TTS, which may actually be ACS, and certainly such patients as per recent guidelines, should be referred for diagnostic arteriography within 24 hours or as soon as possible for patients with STEMI. Although prompt ECHO and coronary arteriography are confirmatory of TTS diagnosis, the first ECG by showing LQRSV or serial ECGs recorded at frequent time intervals after admission showing AAQRS may steer the clinician to the right diagnosis. Moreover, patients with TTS due to ambivalence about the correct cause by the patients or physicians often tend to present to the hospital with some delay and thus, by

that time, LQRSV is already registered in the first ECG. However, it remains unclear to which extent the diagnostic accuracy can be improved by these ECG criteria of TTS over ECHO and coronary arteriography. At the very least these ECG signs could raise suspicion of TTS as patients are first encountered. It should be firmly kept in mind that TTS is currently an exclusion diagnosis, and it is likely that this would always be the case. Thus the ECG should be used as complementary information to the coronary arteriography and ECHO in the diagnosis and clinical decision making. It is conceivable that the diagnostic value of these ECG findings could be enhanced by more frequent recording of ECGs early after admission and when previous ECGs of patients admitted with suspected TTS are available or actively sought. Furthermore, when the anticipated availability of an ECG along with other health data on medical smart cards for all prospective patients is realized, comparisons of the ECG on the card with an ECG recorded upon admission may provide insight about underlying TTS prior to performance of an ECHO or resort to coronary arteriography. Incidentally, ‘several countries – including South Africa, the United Kingdom and Zambia – already have implemented medical smart card systems’ (www.ihealthbeat.org/articles/2011/6/16/medical-smart-cards-could-boost-portability-of-patient-health-data.aspx, consulted September 2013). In the same vein, and in reference to the comparison of the first ECG upon hospital admission of a patient with suspected TTS with previous ECG(s) of the same patient recorded in other institutions or in any geographical locations, “cloud computing” is expected to provide a solution; accordingly, any ECG recorded anywhere on the planet will be instantly accessible, via “tablet PCs (Apple iPad) and smart phones”, since it will be stored in the “cloud”, “allowing any authorized user to access” it, without resort to the data centers of a particular hospital, clinic, or doctor’s office.⁴⁰ For the time being, current diagnostic strategies for investigation of patients with suspected TTS are not expected to change, although this new ECG insight may introduce some intensification of exploration for an improved diagnostic model, in which the ECG may have a more substantial role.

Recommendations for future practice and research

Data gathered from the international literature for the purposes of this study included in half of the presented patients one ECG, or when two or more ECGs were provided, a widely varying time interval between the two ECGs with the largest AAQRS. To fully evaluate the prevalence of LQRSV and the phenomenon of AAQRS and its course, both in practice and research, frequently recorded and timed ECGs with notice of the time/date of onset of the illness need to be implemented. In addition, when authors report on patients with TTS, they should consider including

in their reports one or more ECG per reported patient case, with information on the times/dates of the ECG recordings and the onset of the illness, and with inclusion of all 12 ECG leads. Undoubtedly, these ECG findings need to be tested in a prospective cohort of patients with proven TTS and contrasted with a control population of patients with ACS, particularly anterior STEMI. In such a prospective undertaking, a quantitative approach in assessing the amplitude of the QRS complexes, instead of the LQRSV voltage cut-off characterization used herein, should be implemented for patients with both TTS and ACS.

Conclusions

LQRSV or AAQRS in repeat ECGs in patients admitted with a clinical picture suggestive of acute LV failure should prompt considerations that the underlying pathology may occasionally be TTS, although ACS is most often the culprit to be ruled out. Such information may aid, along with immediate investigations via ECHO and coronary arteriography, in the differentiation between TTS and ACS.

Conflicts of interest

The author declares that there are no conflicts of interest.

Funding

This research received no specific grant from any funding agency in the public, commercial, or not-for-profit sectors.

References

1. Jeremy R. Neurogenic heart disease: from Voodoo to Takotsubo. *Heart Lung Circ* 2010; 19: 61–62.
2. Sato H, Tateishi H, Uchida T, et al. Takotsubo-like left ventricular dysfunction due to multivessel coronary spasm. In: Kodama K, Haze K, Hon M (eds) *Clinical aspect of myocardial injury: from ischemia to heart failure*. Tokyo: Kagakuhyouronsya, 1990. pp. 56–64.
3. Dote K, Sato H, Tateishi H, et al. Myocardial stunning due to simultaneous multivessel coronary spasms: a review of 5 cases. *J Cardiol* 1991; 21: 203–214.
4. Ogura R, Hiasa Y, Takahashi T, et al. Specific findings of the standard 12-lead ECG in patients with ‘Takotsubo’ cardiomyopathy: comparison with the findings of acute anterior myocardial infarction. *Circ J* 2003; 67: 687–690.
5. Inoue M, Shimizu M, Ino H, et al. Differentiation between patients with takotsubo cardiomyopathy and those with anterior acute myocardial infarction. *Circ J* 2005; 69: 89–94.
6. Kawai S, Kitabatake A and Tomoike H; Takotsubo Cardiomyopathy Group. Guidelines for diagnosis of takotsubo (ampulla) cardiomyopathy. *Circ J* 2007; 71: 990–992.
7. Mitsuma W, Kodama M, Ito M, et al. Serial electrocardiographic findings in women with Takotsubo cardiomyopathy. *Am J Cardiol* 2007; 100: 106–109.
8. Prasad A, Lerman A and Rihal CS. Apical ballooning syndrome (Tako-Tsubo or stress cardiomyopathy): a mimic of acute myocardial infarction. *Am Heart J* 2008; 155: 408–417.

9. von Korn H, Yu J, Lotze U, et al. Tako-Tsubo-like cardiomyopathy: specific ECG findings, characterization and clinical findings in a European single center. *Cardiology* 2009; 112: 42–48.
10. Song BG, Chun WJ, Park YH, et al. The clinical characteristics, laboratory parameters, electrocardiographic, and echocardiographic findings of reverse or inverted takotsubo cardiomyopathy: comparison with mid or apical variant. *Clin Cardiol* 2011; 34: 693–699.
11. Madias C, Fitzgibbons TP, Alsheikh-Ali AA, et al. Acquired long QT syndrome from stress cardiomyopathy is associated with ventricular arrhythmias and torsades de pointes. *Heart Rhythm* 2011; 8: 555–561.
12. Bybee KA, Motiei A, Syed IS, et al. Electrocardiography cannot reliably differentiate transient left ventricular apical ballooning syndrome from anterior ST-segment elevation myocardial infarction. *J Electrocardiol* 2007; 40: 38, e1–e6.
13. Sharkey SW, Lesser JR, Menon M, et al. Spectrum and significance of electrocardiographic patterns, troponin levels, and thrombolysis in myocardial infarction frame count in patients with stress (Tako-tsubo) cardiomyopathy and comparison to those in patients with ST-elevation anterior wall myocardial infarction. *Am J Cardiol* 2008; 101: 1723–1728.
14. Madias JE. Electrocardiogram in myocardial edema due to Takotsubo syndrome. *J Electrocardiol* 2012; 45: 795–796.
15. Migliore F, Zorzi A, Marra MP, et al. Myocardial edema underlies dynamic T-wave inversion (Wellens' ECG pattern) in patients with reversible left ventricular dysfunction. *Heart Rhythm* 2011; 8: 1629–1634.
16. Zorzi A, Migliore F, Perazzolo Marra M, et al. Electrocardiographic J waves as a hyperacute sign of Takotsubo syndrome. *J Electrocardiol* 2012; 45: 353–356.
17. Madias JE. QRS voltage changes in heart failure: A 3-compartment mechanistic model and its implications. *Indian Pacing Electrophysiol J* 2010; 10: 464–473.
18. Salisbury PF, Cross CE, Rieben PA, et al. Physiologic and electrocardiographic correlations in experimental left heart failure. *Am J Physiol* 1965; 209: 928–934.
19. Macfarlane PW, van Oosterom A, Pahlm O, et al. (eds) *Comprehensive electrocardiology*, 2nd ed. London: Springer, 2010. pp. 914, 2058, 2084.
20. Madias JE. aVR, an index of all ECG limb leads, with clinical utility for monitoring of patients with edematous states, including heart failure. *Pacing Clin Electrophysiol* 2009; 32: 1567–1576.
21. De Zwaan C, Bar FW and Wellens HJ. Characteristic electrocardiographic pattern indicating a critical stenosis high in left anterior descending coronary artery in patients admitted because of impending myocardial infarction. *Am Heart J* 1982; 103: 730–736.
22. Perazzolo Marra M, Zorzi A, Corbetti F, et al. Apicobasal gradient of left ventricular myocardial edema underlies transient T-wave inversion and QT interval prolongation (Wellens' ECG pattern) in Tako-Tsubo cardiomyopathy. *Heart Rhythm* 2013; 10: 70–77.
23. Tada H. Unraveling the riddle of transient T-wave inversion (Wellens' ECG pattern): T2-weighted magnetic resonance imaging identifies myocardial edema. *Heart Rhythm* 2011; 8: 1635–1636.
24. Seth PS, Aurigemma GP, Krasnow JM, et al. A syndrome of transient left ventricular apical wall motion abnormality in the absence of coronary disease: a perspective from the United States. *Cardiology* 2003; 100: 61–666.
25. Kosuge M, Ebina T, Hibi K, et al. Simple and accurate electrocardiographic criteria to differentiate takotsubo cardiomyopathy from anterior acute myocardial infarction. *J Am Coll Cardiol* 2010; 55: 2514–2516.
26. Tamura A, Watanabe T, Ishihara M, et al. A new electrocardiographic criterion to differentiate between Takotsubo cardiomyopathy and anterior wall ST-segment elevation acute myocardial infarction. *Am J Cardiol* 2011; 108: 630–633.
27. Kosuge M, Ebina T, Hibi K, et al. Differences in negative T waves between takotsubo cardiomyopathy and reperfused anterior acute myocardial infarction. *Circ J* 2012; 76: 462–468.
28. Núñez-Gil IJ, Luaces M, Garcia-Rubira JC, et al. Electrocardiographic criteria in Takotsubo cardiomyopathy and race differences: Asians versus Caucasians. *J Am Coll Cardiol* 2010; 56: 1433–1434.
29. Jim MH, Chan AO, Tsui PT, et al. A new ECG criterion to identify takotsubo cardiomyopathy from anterior myocardial infarction: role of inferior leads. *Heart Vessels* 2009; 24: 124–130.
30. Johnson NP, Chavez JF, Mosley WJ 2nd, et al. Performance of electrocardiographic criteria to differentiate Takotsubo cardiomyopathy from acute anterior ST elevation myocardial infarction. *Int J Cardiol* 2013; 164: 345–348.
31. Takashio S, Yamamuro M, Kojima S, et al. Usefulness of SUM of ST-segment elevation on electrocardiograms (limb leads) for predicting in-hospital complications in patients with stress (takotsubo) cardiomyopathy. *Am J Cardiol* 2012; 109: 1651–1656.
32. Zhong-Qun Z, Chong-Quan W, Sclarovsky S, et al. ST-segment deviation pattern of takotsubo cardiomyopathy similar to acute pericarditis: Diffuse ST-segment elevation. *J Electrocardiol* 2013; 46: 84–89.
33. Kittisupamongkol W. Electrocardiogram in Takotsubo cardiomyopathy. *Am J Med* 2009; 122: e17.
34. Abdel-Aty H, Cocker M and Friedrich MG. Myocardial edema is a feature of Tako-Tsubo cardiomyopathy and is related to the severity of systolic dysfunction: insights from T2-weighted cardiovascular magnetic resonance. *Int J Cardiol* 2009 20; 132: 291–293.
35. Joshi SB, Chao T, Herzka DA, et al. Cardiovascular magnetic resonance T2 signal abnormalities in left ventricular ballooning syndrome. *Int J Cardiovasc Imaging* 2010; 26: 227–232.
36. Fernández-Pérez GC, Aguilar-Arjona JA, de la Fuente GT, et al. Takotsubo cardiomyopathy: assessment with cardiac MRI. *AJR Am J Roentgenol* 2010; 195: W139–W45.
37. Eitel I, von Knobelsdorff-Brenkenhoff F, Bernhardt P, et al. Clinical characteristics and cardiovascular magnetic resonance findings in stress (takotsubo) cardiomyopathy. *JAMA* 2011 20; 306: 277–286.
38. Madias JE, Bazaz R, Agarwal H, et al. Anasarca-mediated attenuation of the amplitude of electrocardiogram complexes: a description of a heretofore unrecognized phenomenon. *J Am Coll Cardiol* 2001; 38: 756–764.
39. Kokkonen JO, Lammintausta O and Luomanmäki K. Acute heart failure and transient low voltage in electrocardiogram after massive catecholamine release from a pheochromocytoma. *Eur Heart J* 1997; 18: 1357.
40. Bond RR, Finlay DD, Nugent CD, et al. Methods for presenting and visualising electrocardiographic data: From temporal signals to spatial imaging. *J Electrocardiol* 2013; 46: 182–196.