

# Challenges and Outcome of Left-lobe Liver Transplants in Adult Living Donor Liver Transplants

S Sudhindran\*, Ramachandran N Menon\*, Dinesh Balakrishnan\*

\*Department of Solid Organ Transplantation, Amrita Institute of Medical Sciences and Research Centre, Kochi, Kerala – 682041

**Adult-to-adult living donor liver transplant (LDLT) frequently depend on using the right-lobes of the donor for obtaining adequate graft-to-recipient weight ratio (GRWR) of over 0.8% in the recipient. However, left-lobes remain an important option in adults, since the morbidity in the donor is considerably less with left donor hepatectomy when compared with right side liver resection. Further benefits of left-lobes in LDLT include more predictable anatomy of the left hepatic duct and left portal vein, which are usually long and single resulting in easier anastomosis in the recipient. Likewise, left-lobe grafts are easier to implant with an excellent venous outflow through the combined orifice of left and middle hepatic vein, as opposed to the complex hepatic vein reconstruction required in right-lobe grafts. However, left hepatic artery is often multiple unlike the right hepatic artery. The holy grail of left-lobe transplants is avoidance of small for size syndrome (SFSS) in the recipients. The strategies for overcoming SFSS currently depend on circumventing portal hyperperfusion in the graft. Measurement of portal pressure and modulating it if high, by splenic artery ligation, splenectomy, or hemiportocaval shunts are proving successful in avoiding SFSS. The future aim in adult LDLT should be to use the left-lobe as much as possible for the benefit of the donor at the same time avoiding SFSS even at very low GRWR for the benefit of the recipient. (J CLIN EXP HEPATOL 2012;2:181–187)**

The initial venture into living donor liver transplantation (LDLT) started with pediatric recipients using the left lateral segment of the liver (Couinaud segments 2 and 3).<sup>1,2</sup> Excellent results of pediatric LDLT led to an explosion of its use, especially in Asia where deceased donors were a rarity.<sup>3,4</sup> In liver transplantation, a liver mass amounting to approximately 1% of the weight of the recipient is required to be implanted for maintaining basic metabolic functions of the liver in the postoperative period. This is usually expressed as a graft-to-recipient weight ratio (GRWR) of 1%.<sup>5</sup> A left lateral segment of a 60 Kg adult typically weighs around 250 g (20% of the total liver weight) and would suffice for children weighing up to 25 Kg. This would still leave almost 80% of liver in the donor and not result in any major untoward consequences.

**Keywords:** Advantages, disadvantages, graft-to-recipient weight ratio, GRWR, hemiportocaval shunt, left lobe, living donor liver transplants, portal hyper perfusion, results, small for size syndrome, splenectomy, splenic artery ligation

**Received:** 13.03.2012; **Accepted:** 24.05.2012

**Address for correspondence:** S Sudhindran, Department of Solid Organ Transplantation, Amrita Institute of Medical Sciences, Kochi, Kerala – 682041

**E-mail:** sudhi@aims.amrita.edu

**Abbreviations:** GRWR: graft-to-recipient weight ratio; ITU: intensive therapy unit; IVC: inferior vena cava; LDLT: living donor liver transplantation; LHV: left hepatic vein; MHV: middle hepatic vein; RHV: right hepatic vein; SFSS: small for size syndrome

**doi:** 10.1016/S0973-6883(12)60106-6

Intuitively, LDLT using the left lateral segment of a donor seemed to be a sound procedure and did not lead to much controversy. This was soon followed by the use of whole left-lobe grafts (segments 2, 3, and 4) and left-lobe with caudate lobe (segments 2, 3, 4, and 1) for larger children, again without much dispute in the transplant community, as all this entailed equally small surgical risk to the central individual, the donor.

Subsequently, the first successful adult LDLT was performed in Japan in 1993, by transplanting a whole left-lobe.<sup>6</sup> Application of LDLT for larger adolescents and adults led to unearthing of the ‘small for size syndrome’ (SFSS), which merely denoted early liver dysfunction due to inadequate hepatocyte mass.<sup>5,7</sup> Small for size syndrome, hitherto unheard of, in whole liver transplants referred to the constellation of persistent ascites, cholestasis, coagulopathy, and encephalopathy in the setting of a partial liver graft with GRWR <0.8% without a technical cause. Small for size syndrome resulted in higher incidence of septic complications and increased mortality. By and large, it is agreed that SFSS can be avoided if GRWR is greater than 1%, and there is an increased frequency of SFSS when GRWR is <0.8%.<sup>5,7,8</sup> So, the obvious way to avoid SFSS would be to use right-lobe grafts that would increase GRWR but on the other hand create a higher risk to the donor, a contradictory setting!

This review focuses on the pros and cons of left-lobe grafts and ways to ameliorate SFSS when used for adult LDLT.

## DONOR SAFETY IN RIGHT AND LEFT HEPATECTOMY

Do we have any evidence that right hepatectomy carries more risk than left hepatectomy in a living donor setting? As the transection plane for right and left hepatectomies is more or less the same, hypothetically the blood loss and resultant complications of both procedures should be comparable. Nonetheless, the remnant liver volume in a donor is much less after the right hepatectomy and there could be an association between residual liver volume and complications. Unfortunately, there is a comparative data vacuum on our knowledge of the catastrophic complications arising from live donor hepatectomy.<sup>9-13</sup> Four recent reports did specifically look at complications between the left- and right-lobe donations.<sup>14-17</sup> Although the incidence of major complications following the right-lobe donation is significantly more when compared with the left-lobe donation (17% vs 2.6%), the mortality risk did not vary significantly (3.3/1000 vs 2.8/1000).<sup>14,15</sup> In the latest A2ALL report, left-lobe donation was unexpectedly associated with a higher risk of complications (Hazard ratio=1.55; 95% confidence interval 0.96-2.51; *P* value 0.08).<sup>16</sup> Nevertheless, it can be generalized that right-lobe donors entail greater surgical stress, take longer to recover, and face higher risk of major complications, liver failure, and mortality than the nonright-lobe donors.

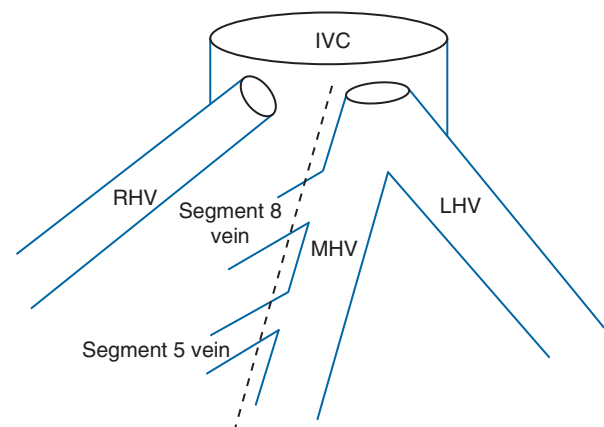
Needless to mention, while performing LDLT, balancing the risk to the donor with the safety for the recipient is paramount too. There is some evidence that the use of left-lobe grafts with comparable graft weight and GRWR to right-lobe grafts still resulted in higher mortality in recipients (6.9% for the right vs 18.8% for the left) and raised the query of gram-to-gram equivalence of the right- and left-liver grafts.<sup>18</sup> This article by Chan et al additionally showed that the left-lobe recipients took significantly longer duration (455 minutes vs 405 minutes), sustained more blood loss (405 mL vs 300 mL), and had prolonged intensive therapy unit (ITU) stay (8.5 days vs 4 days) as compared with the right-lobe graft recipients.<sup>18</sup> However, on closer scrutiny of their data, the right-lobe (*n*=29) and left-lobe (*n*=16) recipient groups do not appear to be similar. Left-lobe donation comprised only 16 of the total 213 LDLT (7%), which probably imply unfamiliarity with the procedure as attested by the authors. The left-lobe group had higher number of high urgency transplants (56% vs 34%), higher number of acute liver failures (31% vs 0%), and lesser number of transplants for hepatocellular carcinoma which usually have better preserved underlying liver function (6% vs 34%).<sup>18</sup> These confounding factors could have contributed to the ostensibly poorer outcomes in the left-lobe group like a self-fulfilling prophecy and may not reflect the true superiority of the right-lobe grafts as suggested by the authors.

## Advantages of Left-lobe Grafts

Left-lobe grafts may be harvested in three ways: (a) left-lobe without middle hepatic vein (MHV), (b) left-lobe with MHV (extended left-lobe), and (c) extended left-lobe with the caudate lobe.<sup>19</sup> Although the addition of caudate lobe may increase the left-lobe graft weight by 5-10%, this has not been a routine practice in most centers due to its technical complexity.

The outflow of the left-lobe is via the left hepatic vein (LHV) and MHV. Uniformly good drainage of the graft is crucial for the satisfactory function of the graft in the recipient, particularly for avoidance of SFSS. The MHV is almost always included in the left-lobe grafts, since the MHV typically joins the LHV before entering into the inferior vena cava (IVC). Even if the MHV opens separate from the LHV into IVC, their reconstruction into a single wide orifice for implantation into the recipient IVC is relatively straightforward and results in excellent graft outflow.<sup>19</sup> For similar good drainage of right-lobe grafts, particularly the anterior segments 5 and 8, either harvesting of MHV or separate drainage of segments 5 and 8 would be required, making the procedure infinitely more complex (Figure 1). Furthermore, the inclusion of MHV along with right-lobe grafts does affect the donor recovery in terms of the alteration of prothrombin time, bilirubin, and transaminases.<sup>17</sup> On the other hand, while using the extended left-lobe with caudate lobe, additional reconstruction of the vein draining caudate lobe is often required.<sup>19</sup> This technical intricacy probably precludes most living donor surgeons from using the caudate lobe along with extended left-lobe grafts.

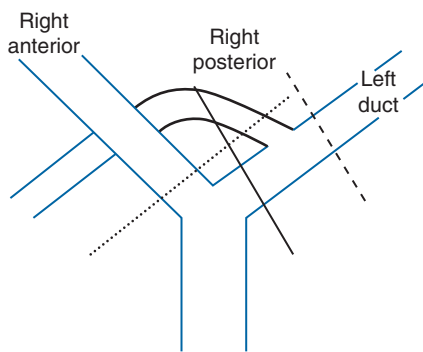
Biliary complication is Achilles' heel of LDLT. This is primarily due to the smaller luminal diameter and short length of the hepatic ducts. Biliary anatomical variations requiring multiple anastomoses are more frequently encountered



**Figure 1** Usual anatomy of hepatic veins. Dashed line—standard transection line for the right and left hepatectomies. For the right-lobes, reconstruction of segment 5 and 8 veins would be required for complete drainage. For the left lobe, no complex reconstruction is required as the MHV joins the LHV.

IVC: inferior vena cava; LHV: left hepatic vein; MHV: middle hepatic vein; RHV: right hepatic vein.

in the right-lobe grafts than in the left-lobe grafts. For instance, >20% of the right posterior sectoral bile duct joins the left duct, necessitating multiple biliary anastomoses if the right-lobe is chosen as the graft.<sup>20</sup> Conversely, almost all left-lobe grafts have a single left hepatic duct orifice, resulting in a technically easier biliary anastomosis and a much lower incidence of bile leaks.<sup>21</sup> There is, however, an increased risk of damage to the remnant right posterior



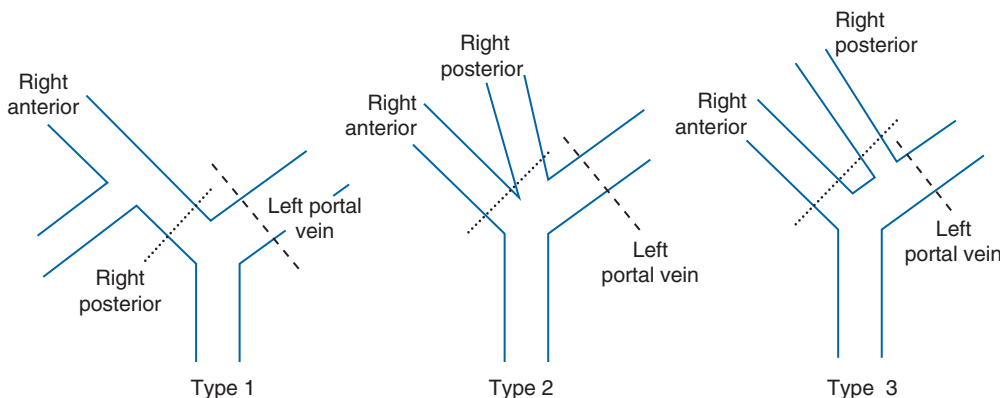
**Figure 2** Right posterior bile duct joining left duct. Dashed line—transection for left-lobe giving one duct for anastomosis. Dotted line—transection for right-lobe will have two ducts for anastomosis. Black solid line—if on left-lobe donation, transection is made here, injury to right posterior duct occurs in the donor.

segmental duct by the unwary in cases where it opens into the left duct, if the left duct division is unknowingly made distal to its entry into the left hepatic duct (Figure 2).

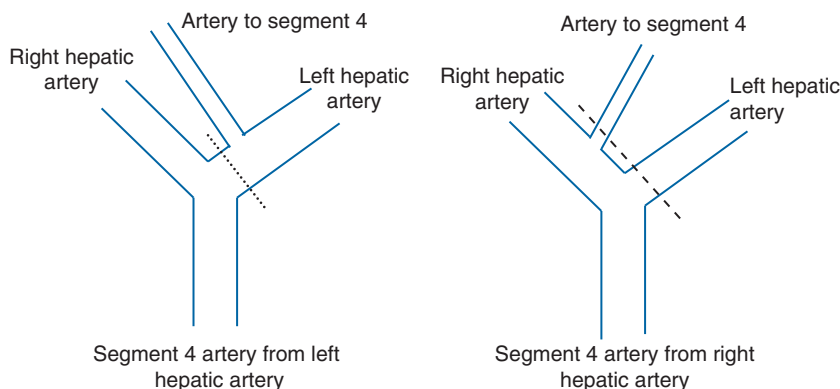
Like the bile ducts, multiple portal veins are more common on the right while the left portal vein is usually single and longer ensuing an easier anastomosis in the recipient.<sup>22</sup> As shown in Figure 3, the anterior and posterior branches of the right portal vein often do not join to form a single right portal vein (type 2 and 3 portal vein), in which case complex bench reconstruction would be required if the right graft is used.<sup>22</sup> Such situation is extremely rare with the left-lobe grafts.

### Disadvantages of Left-lobe Grafts

Origin of the segment 4 artery, usually termed the middle hepatic artery, can be from the right hepatic or the left hepatic artery in almost equal proportions (Figure 4).<sup>23</sup> If arising from the right hepatic artery, using the left-lobe would necessitate two arterial reconstructions (one to the left hepatic artery and another to the segment 4 artery). Typically, the diameter of the left hepatic artery is smaller even when single, compared with the right and can result in higher incidence of hepatic artery thrombosis.



**Figure 3** Types of portal vein. Dashed line—transection for left-lobe giving one portal vein in all types. Dotted line—transection for right-lobe will have two portal veins in types 2 and 3.



**Figure 4** Origin of hepatic artery to segment 4. Dotted line—transection for left-lobe giving one hepatic artery. Dashed line—transection for left-lobe will give two arteries.

The positioning of the left liver graft could be challenging during the transplant operation, particularly in the presence of splenomegaly. The left-lobe is usually one-third of the size of the whole liver and when used on a smaller sized recipient than the donor, the new graft becomes larger than the original left-lobe producing significant space constraint.

Hepatic outflow block is one of the major complications leading to severe graft dysfunction after LDLT. Left-lobe grafts are prone to pivoting around the IVC if the graft is not held tightly in its position by fixing the falciform ligament in the graft to the anterior abdominal wall.<sup>18</sup> Rotation of the left-lobe grafts to the vacant right subphrenic space in the postoperative period can result in a functional Budd-Chiari like effect due to kinking of the hepatic vein orifice. Moreover, the left-lobe grafts seem to have more active regeneration after surgery and they rotate further from their position at implantation than the right-lobe grafts, because the smaller left-lobe grafts regenerate toward the right and posterior side. This again can cause a horizontal shift in the lie of the MHV and LHV resulting in kinks and outflow issues.<sup>24</sup> In contrast, the right-lobe graft resides comfortably in the limited right subphrenic cavity and regenerates toward the left and anteromedial sides with little positional change of the graft hepatic veins.

In extended left-lobe grafts, MHV is usually harvested with the graft and therefore the liver on the recipient side is free of any congestion. However, the remnant liver in the donor can have congestion of the anterior sectors 5 and 8 if their predominant drainage was through the MHV. This can lead to transient dysfunction in the donor and poor regeneration.<sup>25</sup>

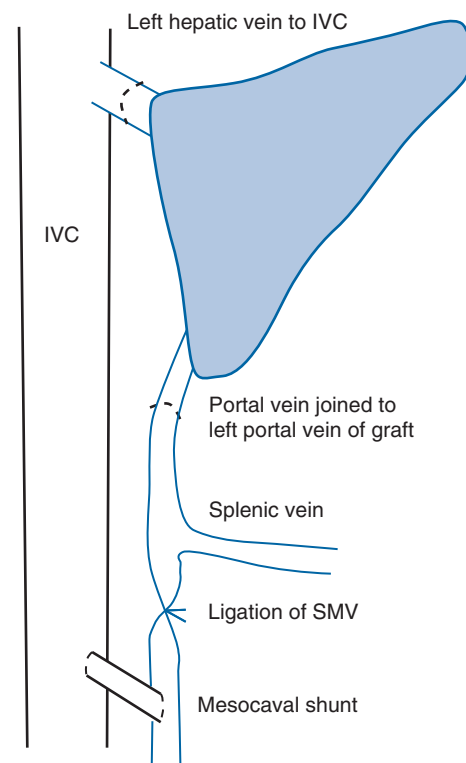
### Ways to Avoid Small for Size Syndrome

The holy grail of the left-lobe grafts is the avoidance of SFSS. Small for size syndrome represents a distinct disease entity related to partial liver grafts denoting its inability to meet the functional demands of the recipient resulting in hepatic dysfunction. This usually manifests as coagulopathy, ascites, hyperbilirubinemia, and encephalopathy and is often associated with pulmonary failure, renal failure, and sepsis, leading to higher mortality of the recipient. There is no doubt that the incidence of SFSS is higher when smaller grafts with GRWR < 0.8% is used.<sup>5,7</sup> Inadequate hepatic venous outflow of partial grafts can lead to a situation similar to SFSS but this is a problem more often seen in right-lobe grafts. In any case, outflow obstruction is a technical problem and all such surgical issues need to be excluded before the diagnosis of SFSS can be made.

An essential factor that influences the functional capacity of the partial graft is the presence of steatosis.<sup>26</sup> When using left-lobes for adult LDLT, it is critical that good quality livers devoid of any degree of steatosis should

be chosen to avoid SFSS. Otherwise, the pitfalls of an inherently low GRWR of the left-lobe graft would be compounded by its steatosis.

There is considerable human and animal evidence implicating portal hyperperfusion in the pathogenesis of graft injury in SFSS.<sup>27-29</sup> The partial grafts in LDLT are subjected to the portal flow destined for a whole liver, resulting in portal hyperperfusion. Recipient hemodynamics too plays a part, as cirrhotic recipients demonstrate higher portal flow due to splanchnic vasodilatation. Animal models have demonstrated multiple microvascular injuries after reperfusion inversely related to graft size while diversion of portal flow to graft showed an absence of microvascular injury and improved graft function.<sup>27,28</sup> Hence, most clinical strategies to avoid SFSS have focused on ways to decrease portal hyperperfusion in the new graft. Boillot first made use of this hypothesis to overcome SFSS successfully by diverting the excessive portal flow through a mesocaval shunt after ligation of recipient superior mesenteric vein (Figure 5).<sup>29</sup> Others have used similar methods for portal flow diversion such as inferior mesenteric vein to the left renal vein shunts or the innovative hemiportocaval shunts (Figure 6), where the right branch of the portal vein (which is free in the left-lobe transplants) is connected to the IVC either directly or using interposition grafts such as recipient portal vein or synthetic grafts.<sup>30-34</sup> However, sometimes the diverted

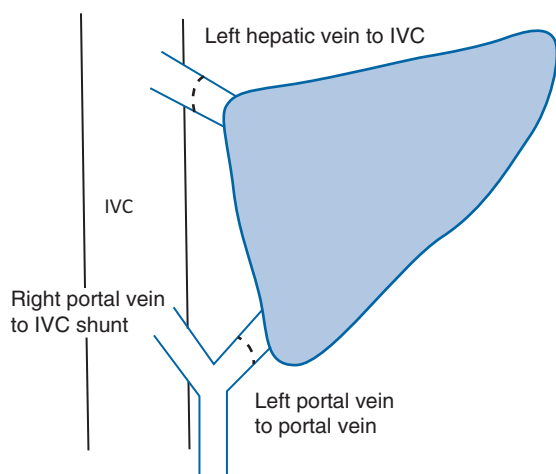


**Figure 5** Boillot shunt. IVC: inferior vena cava; SMV: superior mesenteric vein.

**Table 1** Salient differences between right- and left-lobe grafts.

Characteristics	Left-lobe	Right-lobe
Donor		
Sex	Male preponderance	Female preponderance
Postoperative liver function	Less rise of prothrombin time, bilirubin, and transaminases	Significantly higher values, especially if MHV is included
Hospital stay	Shorter	Longer
Morbidity	Probably less	Probably more
Graft		
Weight	Less than right (average 450g)	More than left (average 600g)
Bile duct	Usually one	Multiple in 50%
Portal vein	Usually one	Two in 30%
Hepatic artery	40% have two when segment 4 artery arises from the right	Usually one
Hepatic vein	Simple reconstruction into single common orifice of LHV and MHV	Complex reconstruction of segment 5 and 8 veins or of MHV required
Recipient		
Body weight	Lower than the right-lobe (usually around 55 Kg)	More (usually > 65 Kg)
Positioning in recipient	Difficult due to lack of space on the left	Easier due to space on the right side
GRWR or GV/SLV	Lower than the right (usually GRWR around 0.8 or GV/SLV 40%)	More than the left (usually GRWR around 0.95 or GV/SLV 50%)
MELD score	? Lower scores	? Higher scores
SFSS occurrence	Higher risk (20%)	Lower risk (10%)

GRWR: graft-to-recipient weight ratio; GV/SLV: graft volume/standard liver volume; LHV: left hepatic vein; MELD: model for end-stage liver disease; MHV: middle hepatic vein; SFSS: small for size syndrome.



**Figure 6** Hemiportocaval shunt. IVC: inferior vena cava.

flow through the shunts away from the graft liver maybe too excessive resulting in gradual liver atrophy and may even necessitate subsequent surgical closure of the shunts. The novel use of ligamentum teres of the recipient containing the umbilical vein as the interposition graft may obviate the need for subsequent closure of the shunt.<sup>35</sup> In the immediate postoperative period, the high portal pressure in the graft will keep the ligamentum teres shunt open and prevent SFSS. Later as the liver regenerates, the portal pressure will come down. This will gradually obliterate the ligamentum teres, spontaneously close the portocaval shunt and prevent liver atrophy later.

By far the simplest method to decrease portal pressure is ligation of splenic artery to reduce the prograde flow through splenic vein into the portal vein, but its effect on portal pressure may not be strong enough.<sup>36,37</sup> Splenectomy is probably the most widely practiced modality now for portal flow modulation as it is technically familiar to most surgeons.<sup>38,39</sup>

Measurement of portal pressure on the table after implantation, to make a decision regarding necessity for maneuvers to reduce portal pressure, has become a routine practice in many liver-transplant centers. Attaining a portal pressure < 15 mmHg has been claimed to be the key to avoiding SFSS.<sup>39</sup> Nonetheless, the requirement and the type of intentional techniques to reduce portal pressure as well as the success of the different procedures in obviating mortality due to SFSS still remain a moot question. Sufficiently robust data for the use of low GRWR grafts along with portal pressure modulation for satisfactory outcome of the recipient are still lacking. There is scope for lot more research!

### Use of Dual Left-lobes

Use of two donors, each of whom donated their left-lobe, was initially performed in Korea to avoid the use of right-lobe for recipients who require large grafts.<sup>40</sup> This was based on the assumption that the right hepatectomy is more dangerous than the left hepatectomy for the donor. Although that maybe true, does the morbidity and mortality risk of one right hepatectomy outweigh that of two left hepatectomies? The recipient surgery is extremely complex and may not be applicable to most centers.

## CONCLUSION

Left-lobe grafts harvesting cause much less morbidity in the donor when compared with the right-lobe grafts. Probably, the risk of life-threatening complications such as liver dysfunction and mortality too is lower in the left-lobe donors. Left-lobe grafts have the additional benefit of better anatomy of the left bile duct and left portal vein which usually being long and single result in easier anastomosis in the recipient. Likewise, the left-lobe grafts are easier to implant with a better venous outflow through the combined orifice of LHV and MHV. However, the left-lobe grafts may have more chance of having multiple hepatic artery anastomosis. The biggest disadvantage of the left-lobe grafts is smaller graft weight and possibility of SFSS in the recipient. The primary strategy for this currently depends on circumventing portal hyperperfusion in the graft. The future aim in adult LDLT should be to use the left-lobe as much as possible for the benefit of the donor, at the same time avoiding SFSS even at very low GRWR for the benefit of the recipient.

## CONFLICTS OF INTEREST

All authors have none to declare.

## REFERENCES

- Raia S, Nery JR, Mies S. Liver transplantation from live donors. *Lancet* 1989;2:497.
- Strong RW, Lynch SV, Ong TH, Matsunami H, Koido Y, Balderson GA. Successful liver transplantation from a living donor to her son. *N Engl J Med* 1990;322:1505–7.
- Ueda M, Oike F, Ogura Y, et al. Long-term outcomes of 600 living donor liver transplants for pediatric patients at a single center. *Liver Transpl* 2006;12:1326–36.
- Oh SH, Kim KM, Kim DY, et al. Long-term outcomes of pediatric living donor liver transplantation at a single institution. *Pediatr Transpl* 2010;14:870–8.
- Kiuchi T, Kasahara M, Uryuhara K, et al. Impact of graft size mismatching on graft prognosis in liver transplantation from living donors. *Transplantation* 1999;67:321–7.
- Hashikura Y, Makuuchi M, Kawasaki S, et al. Successful living-related partial liver transplantation to an adult patient. *Lancet* 1994;343:1233–4.
- Chui AK, Rao AR, Island ER, Lau WY. Critical graft size and functional recovery in living donor liver transplantation. *Transpl Proc* 2004;36:2277–8.
- Dahm F, Georgiev P, Clavien PA. Small-for-size syndrome after partial liver transplantation: definition, mechanisms of disease and clinical implications. *Am J Transpl* 2005;5:2605–10.
- Trotter JF, Adam R, Lo CM, Kenison J. Documented deaths of hepatic lobe donors for living donor liver transplantation. *Liver Transpl* 2006;12:1485–8.
- Ghobrial RM, Freise CE, Trotter JF, et al. Donor morbidity after living donation for liver transplantation. *Gastroenterology* 2008;135:468–76.
- Patel S, Orloff M, Tsoulfas G, et al. Living-donor liver transplantation in the United States: identifying donors at risk for perioperative complications. *Am J Transpl* 2007;7:2344–9.
- Brown RS Jr, Russo MW, Lai M, et al. A survey of liver transplantation from living adult donors in the United States. *N Engl J Med* 2003;348:818–25.
- Hwang S, Lee SG, Lee YJ, et al. Lessons learned from 1,000 living donor liver transplantations in a single center: how to make living donations safe. *Liver Transpl* 2006;12:920–7.
- Iida T, Ogura Y, Oike F, et al. Surgery-related morbidity in living donors for liver transplantation. *Transplantation* 2010;89:1276–82.
- Muzaale AD, Dagher NN, Montgomery RA, Taranto SE, McBride MA, Segev DL. Estimates of early death, acute liver failure, and long-term mortality among live liver donors. *Gastroenterology* 2012;142:273–80.
- Abecassis MM, Fisher RA, Olthoff K M, et al, and the A2ALL Study Group. Complications of living donor hepatic lobectomy—a comprehensive report. *Am J Transpl* 2012;5:1208–17.
- Soejima Y, Shirabe K, Taketomi A, et al. Left lobe living donor liver transplantation in adults. *Am J Transpl* 2012.
- Chan SC, Fan ST, Lo CM, Liu CL. Effect of side and size of graft on surgical outcomes of adult-to-adult live donor liver transplantation. *Liver Transpl* 2007;13:91–8.
- Takayama T, Makuuchi M, Kubota K, Sano K, Harihara Y, Kawarasaki H. Living-related transplantation of left liver plus caudate lobe. *J Am Coll Surg* 2000;190:635–8.
- Testa G, Malagó M, Valentín-Gamazo C, Lindell G, Broelsch CE. Biliary anastomosis in living related liver transplantation using the right liver lobe: techniques and complications. *Liver Transpl* 2000;6:710–4.
- Suehiro T, Ninomiya M, Shiotani S, et al. Hepatic artery reconstruction and biliary stricture formation after living donor adult liver transplantation using the left lobe. *Liver Transpl* 2002;8:495–9.
- Atri M, Bret PM, Fraser-Hill MA. Intrahepatic portal venous variations: prevalence with US. *Radiology* 1992;184:157–8.
- Jin GY, Yu HC, Lim H, et al. Anatomical variations of the origin of the segment 4 hepatic artery and their clinical implications. *Liver Transpl* 2008;14:1180–4.
- Shirouzu Y, Ohya Y, Hayashida S, Asonuma K, Inomata Y. Difficulty in sustaining hepatic outflow in left lobe but not right lobe living donor liver transplantation. *Clin Transpl* 2011;25:625–32.
- Fukuhara T, Umeda K, Toshima T, et al. Congestion of the donor remnant right liver after extended left lobe donation. *Transpl Int* 2009;22:837–44.
- Morioka D, Kubota T, Sekido H, et al. Prostaglandin E1 improved the function of transplanted fatty liver in a rat reduced-size liver transplantation model under conditions of permissible cold preservation. *Liver Transpl* 2003;9:79–86.
- Kelly DM, Demetris AJ, Fung JJ, et al. Porcine partial liver transplantation: a novel model of the “small-for-size” liver graft. *Liver Transpl* 2004;10:253–63.
- Wang HS, Ohkohchi N, Enomoto Y, et al. Excessive portal flow causes graft failure in extremely small-for-size liver transplantation in pigs. *World J Gastroenterol* 2005;11:6954–9.
- Boillot O, Delafosse B, Mechet I, Boucaud C, Pouyet M. Small-for-size partial liver graft in an adult recipient; a new transplant technique. *Lancet* 2002;359:406–7.
- Takada Y, Ueda M, Ishikawa Y, et al. End-to-side portocaval shunting for a small-for-size graft in living donor liver transplantation. *Liver Transpl* 2004;10:807–10.
- Sato Y, Yamamoto S, Takeishi T, et al. Inferior mesenteric venous left renal vein shunting for decompression of excessive portal hypertension in adult living related liver transplantation. *Transpl Proc* 2004;36:2234–6.
- Troisi R, Ricciardi S, Smeets P, et al. Effects of hemi-portocaval shunts for inflow modulation on the outcome of small-for-size grafts in living donor liver transplantation. *Am J Transpl* 2005;5:1397–404.
- Botha JF, Langnas A, Campos BD, et al. Changing the landscape of adult to adult living donor liver transplantation: the role of small for size grafts. *Liver Transpl* 2010;16:649–57.

34. Yamada T, Tanaka K, Uryuhara K, Ito K, Takada Y, Uemoto S. Selective hemi-portocaval shunt based on portal vein pressure for small-for-size graft in adult living donor liver transplantation. *Am J Transpl* 2008;8:847–53.
35. Sato Y, Oya H, Yamamoto S, et al. Method for spontaneous constriction and closure of portocaval shunt using a ligamentum teres hepatitis in small-for-size graft liver transplantation. *Transplantation* 2010;90:1200–3.
36. Lo CM, Liu CL, Fan ST. Portal hyperperfusion injury as the cause of primary nonfunction in a small-for-size liver graft-successful treatment with splenic artery ligation. *Liver Transpl* 2003;9: 626–8.
37. Ito T, Kiuchi T, Yamamoto H, et al. Changes in portal venous pressure in the early phase after living donor liver transplantation: pathogenesis and clinical implications. *Transplantation* 2003;75:1313–7.
38. Sato Y, Yamamoto S, Oya H, et al. Splenectomy for reduction of excessive portal hypertension after adult living-related donor liver transplantation. *Hepatogastroenterology* 2002;49:1652–5.
39. Ogura Y, Hori T, El Moghazy W, et al. Portal pressure <15 mm Hg is a key for the successful adult living donor liver transplantation utilizing smaller grafts than before. *Liver Transpl* 2010;16:718–28.
40. Lee SG, Hwang S, Park KM, et al. Seventeen adult-to-adult living donor liver transplantations using dual grafts. *Transpl Proc* 2001; 33:3461–3.