

---

# MacLean–Mueller Prize

## Prix MacLean–Mueller

---

### AN ANALYSIS OF OPEN REDUCTION OF IRREDUCIBLE SUPRACONDYLAR FRACTURES OF THE HUMERUS IN CHILDREN

Philip Fleuriau-Chateau, MD;\* William McIntyre, MD; Mervyn Letts, MD

**OBJECTIVES:** To review experience with irreducible supracondylar fractures requiring open reduction in children, and to propose guidelines for an open approach to supracondylar fractures.

**DESIGN:** A chart review.

**SETTING:** The Children's Hospital of Eastern Ontario (CHEO), a pediatric centre with a large referral base.

**PATIENTS:** Forty-one children (18 boys 23 girls, average age 7 years), who had open reduction of irreducible supracondylar fractures at the CHEO over a 10-year period (1985 to 1995). Of these 41 children, 7 were lost to direct follow-up.

**INTERVENTIONS:** After closed reduction of displaced supracondylar fractures of the humerus failed, all patients underwent open reduction and percutaneous fixation in the operating room. Before operation, 6 had no radial pulse, 5 lost their pulse with flexion after reduction and 4 had unstable fracture patterns.

**MAIN OUTCOME MEASURES:** Assessment of elbow range of motion and carrying angle, distal neurovascular status and radiographic measurement of the Baumann angle and the humerocapitellar angle.

**RESULTS:** In 25 children, the humerus was found to have "buttonholed" through the brachialis muscle; 1 had entrapment of the common flexor muscle at its origin and 1 had entrapment of the triceps. In 15 children there was entrapment or tethering of the median nerve and radial nerve or brachial artery, or both, but this was not predictive of preoperative neurovascular deficit, which was recorded in 21 patients (fully recovered). At follow-up, the Baumann angle and the humerocapitellar angle differed by an average of 2° and 5.3° respectively compared with the unaffected arm. Range of motion was satisfactory in 94% of patients, and there was no significant cubitus varus.

**CONCLUSION:** Open reduction of supracondylar fractures is a safe and effective procedure, for which orthopedists should lower their threshold, given certain appropriate indicators.

---

**OBJECTIFS :** Revoir l'expérience des fractures supracondyliennes irréductibles qu'il a fallu réduire chirurgicalement chez les enfants et proposer des lignes directrices sur une approche chirurgicale des fractures supracondyliennes.

**CONCEPTION :** Étude de dossiers.

**CONTEXTE :** L'Hôpital pour enfants de l'est de l'Ontario (HEEO), centre pédiatrique qui a un important bassin de présentations.

**PATIENTS :** Quarante-et-un enfants (18 garçons et 23 filles, âgés en moyenne de 7 ans) qui ont subi une réduction chirurgicale de fractures supracondyliennes irréductibles à l'HEEO sur une période de 10 ans (1985 à 1995). Sur ces 41 enfants, 7 ont été perdus au suivi direct.

**INTERVENTIONS :** Lorsque la réduction fermée de fractures supracondyliennes déplacées de l'humérus n'a pas réussi, tous les patients ont subi une réduction chirurgicale et une fixation percutanée à la salle d'opération. Avant l'intervention, 6 n'avaient pas de pouls radial, le pouls disparaissait dans 5 cas avec la flexion après réduction et 4 avaient une fracture instable.

*From the Division of Orthopaedic Surgery, Children's Hospital of Eastern Ontario, University of Ottawa, Ottawa, Ont.*

*\*Winner of the 1997 MacLean-Mueller Prize*

*Accepted for publication Nov. 25, 1997*

*Correspondence to: Dr. R. Mervyn Letts, Division of Orthopaedics, Children's Hospital of Eastern Ontario, 401 Smyth Rd., Ottawa ON K1H 8L1*

*© 1998 Canadian Medical Association (text and abstract/résumé)*

PRINCIPALES MESURES DE RÉSULTATS : Évaluation de l'amplitude du mouvement du coude et angle huméro-cubital physiologique, statut neurovasculaire distal et mesure radiographique de l'angle de Baumann et de l'angle huméro-condylien.

RÉSULTATS : Chez 25 enfants, on a constaté que l'humérus avait «perforé» le muscle brachial. Dans un cas, le muscle flexeur commun était emprisonné à son point d'origine et dans un autre, il y avait emprisonnement du triceps. Chez 15 enfants, on a constaté un emprisonnement ou une fixation du nerf médian et du nerf radial ou de l'artère brachiale, ou des deux, mais il ne s'agissait pas d'un facteur prédictif d'un déficit neurovasculaire préopératoire que l'on a constaté chez 21 patients (ils se sont rétablis entièrement). Au suivi, l'angle de Baumann et l'angle huméro-condylien différaient en moyenne de 2° et de 5,3° respectivement comparativement au bras intact. L'ampleur du mouvement était satisfaisante chez 94 % des patients et il n'y avait pas de cubitus varus significatif.

CONCLUSION : La réduction chirurgicale des fractures supracondyliennes est une intervention sûre et efficace à l'égard de laquelle les orthopédistes devraient abaisser leur seuil compte tenu de certains indicateurs appropriés.

The treatment of extension-type supracondylar fractures of the distal humerus remains subject to debate. Type III displaced fractures (widely displaced fractures with no contact between bone fragments as opposed to partially displaced type II fractures) pose the greatest dilemma. Closed reduction with traction,<sup>1-3</sup> percutaneous pinning<sup>4-6</sup> and open reduction with pinning<sup>7-9</sup> are just some of many options.

Some controversy still seems to shroud open reduction, arising from Blount's statement that "while the results are sometimes good, permanent limitation of motion is all too frequent; this method cannot be justified."<sup>10</sup> Whereas most would agree with Blount's statement with respect to routine open reduction of supracondylar fractures, there is a small group of fractures for which open reduction is really the most conservative approach and is frequently less traumatic than repeated attempts at closed reduction.

Open reduction has been a last resort, mainly because of the misplaced fear of stiffness, infection and myositis ossificans.<sup>8,11</sup> However, in patients with open fractures, those with nerve or vascular injury and those with irreducible fractures,<sup>12-14</sup> open reduction need not be associated with these complications.

The purpose of this paper is to review our experience with irreducible supracondylar fractures requiring open reduction, and to propose

guidelines for an open approach to supracondylar fractures.

**PATIENTS AND METHODS**

Through a 10-year chart review we assessed elbow function in children who had open reduction with internal or percutaneous fixation of supracondylar fractures of the humerus, excluding T-type or Y-type fractures. Between 1985 and 1995, 41 children (12% of all supracondylar fractures) underwent open reduction of supracondylar fractures of the humerus at the Children's Hospital of Eastern Ontario. There were 18 boys (44%) and 23 girls (56%). The average age was 7 years (ranging from 2 years to 16 years 8 months). There was only 1 flexion-type injury (2%). There were 26 left-arm fractures (63%) and 15 right-arm fractures (37%).

All the fractures resulted from falls onto the outstretched hand; 14 from the child's own height, 3 from a tree or monkey bars, 7 from a bicycle, tricycle or all terrain vehicle, 13 from a chair or couch, 3 down 4 or 5 stairs and 1 from a friend's shoulders. All open reductions were done by a group of 6 pediatric orthopedic surgeons, with the senior author (W.M.) performing the majority (44%). We approached 38 fractures (93%) anteriorly, over the metaphyseal spike. The goal was anatomic reduction and stable fixation with pinning (Table I, Fig. 1).

Patients without any radiologic signs of complication or clinical deficit were routinely discharged, so follow-up averaged only 7 months (ranging from 1.5 to 18 months); of the 41 children, 7 were lost to direct follow-up.

The preoperative clinical examination concentrated on 3 points: the condition of the skin (Fig. 2), the presence or absence of a radial pulse (by touch or with Doppler examination) and the neurologic status of the forearm and hand. All the fractures were classified radiologically according to the system of Gartland<sup>15</sup> with modifications suggested by Pirone, Graham and Krajbich<sup>16</sup> (Table II).

In all the children, closed reduction was tried in the operating room under general anesthesia. The results were recorded, as were intraoperative findings contributing to the irreducibility of the fractures. Each child's radi-

**Table I**  
Type of Pinning Used in 41 Children With Supracondylar Humeral Fractures

Type of pinning	No. (and %) of children
Medial, lateral	29 (71)
Medial, lateral, longitudinal	3 (7)
Medial, lateral, cannulated screw	1 (2)
Medial × 1	1 (2)
Lateral × 2	6 (15)
Lateral × 1	1 (2)

ographs were studied, and the fracture displacement was measured (Fig. 3), as well as the Baumann angle and the humerocapitellar angle (Fig. 4) in the normal and affected arms, intraoperatively and at the last follow-up visit.

In all 34 patients who returned for follow-up, radiologic assessment was done, range of elbow motion was measured, neurologic and vascular status was assessed, and the presence of varus or valgus deformity noted.

## RESULTS

Although none of the fractures in our series was open, the metaphyseal fragment was subcutaneous in most, as indicated by skin bruising (13 [32%] children) and puckering of the skin (12 [29%] children). There was no discernible pulse, either manually or by Doppler, in 6 patients (15%).

Pain and anxiety prevented 1 child from complying with the neurologic examination. Some form of deficit was seen in 15 (37%) children, the most

common being the sensory component of the median nerve (Table III). Complete resolution of the deficit was noted in 14 children at the last follow-up visit, and 1 was improving.

Failure of closed treatment was found to be related to 4 different clinical settings. After attempts at gentle closed reduction, 4 (10%) children had unstable reductions because of a very oblique fracture line, 6 (15%) had no pulse before or after reduction and 5 (12%) lost their pulse with reduction and flexion of the elbow. In 25 (61%) children, anatomic reduction was not possible.

Some degree of interfragmentary soft-tissue interposition was noted at operation in all but 2 children (Table IV). However, both of those had open reduction because of lost pulse after reduction of the fracture.

In 9 (22%) children, tenting of the brachial artery, median nerve or radial nerve over the metaphyseal fracture surface was significant enough to cause visible bruising of the vessel or

nerve. In 31 (76%) children, there was entrapment of soft tissue between the fracture fragments. "Buttonholing" (penetration of the bony spike through a traumatic rent in enveloping muscle, making reduction difficult, even impossible) of the metaphyseal spike through the brachialis muscle was the most common finding.

Of the 41 fractures, 1 was type II, and 40 (98%) were type III, with an average separation between fragments of 7.72 mm (ranging from 2 to 20 mm). The distal fragment was displaced posteromedially in 56% of cases and posterolaterally in 26%, with 7% pure lateral, 7% pure posterior and 2%

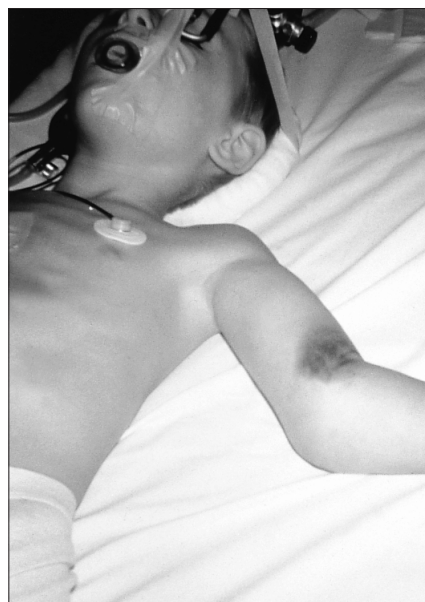


FIG. 2. Severe bruising associated with anterior displacement of the distal humeral metaphysis.

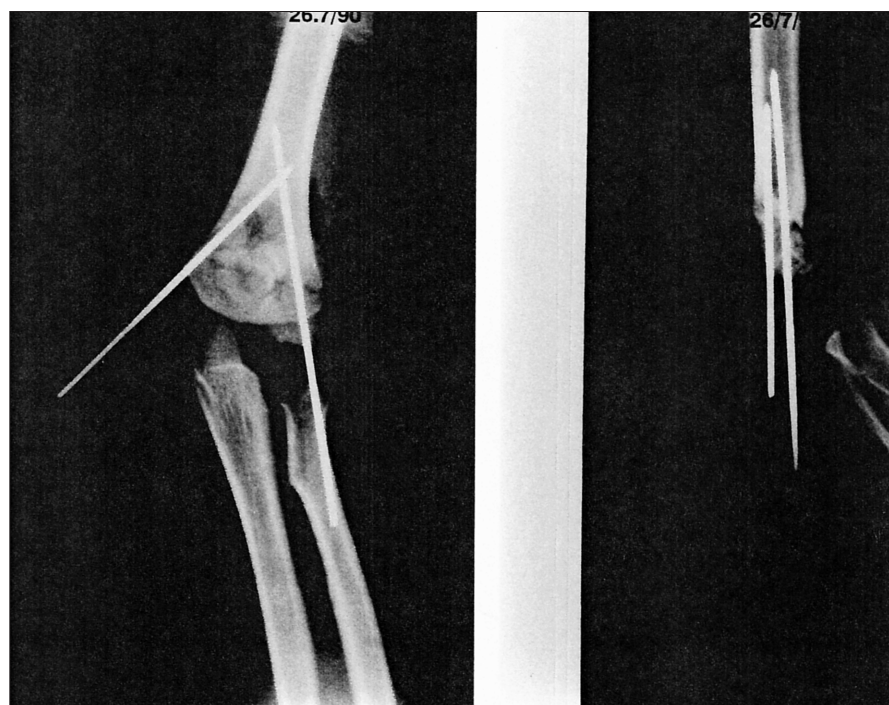

FIG. 1. Medial and lateral pin fixation: anteroposterior view (left) and lateral view (right).

Table II

Classification of Supracondylar Fractures According to Gartland<sup>15</sup> and Pirone, Graham and Krajbich<sup>16</sup>

Fracture type	Description
I	Undisplaced
II	Posterior angulation
IIIa	Posterior translocation
IIIb	Displaced with no cortical contact

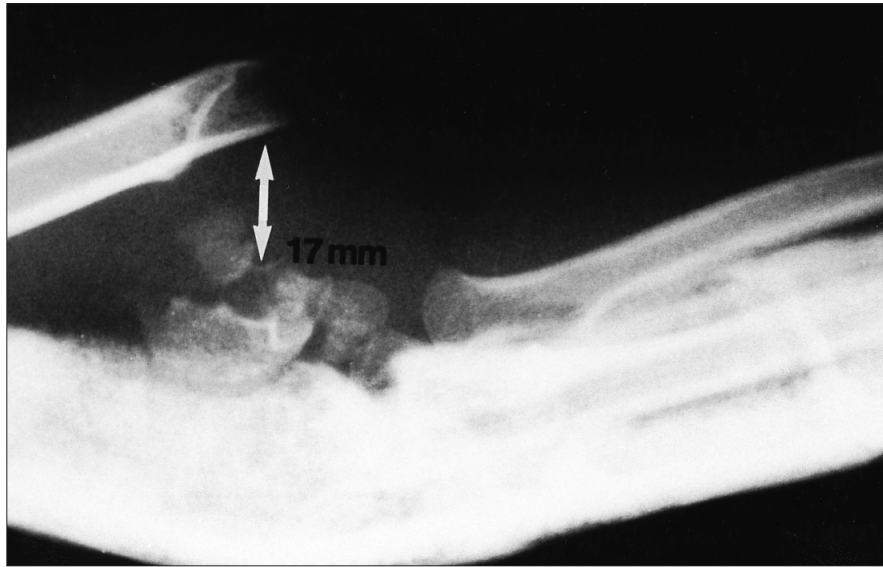
anterolateral. Analysis of the fracture characteristics revealed a jagged surface in 25 (61%) patients (Fig. 5, left), prominent spikes in 16 (39%) (Fig. 5, right) and comminution in 8 (20%) (Fig. 6).

The Baumann angle and the humero-capitellar angle were measured in each arm, intraoperatively and at follow-up. The average difference in the Baumann angle between the normal side and the healed fracture was

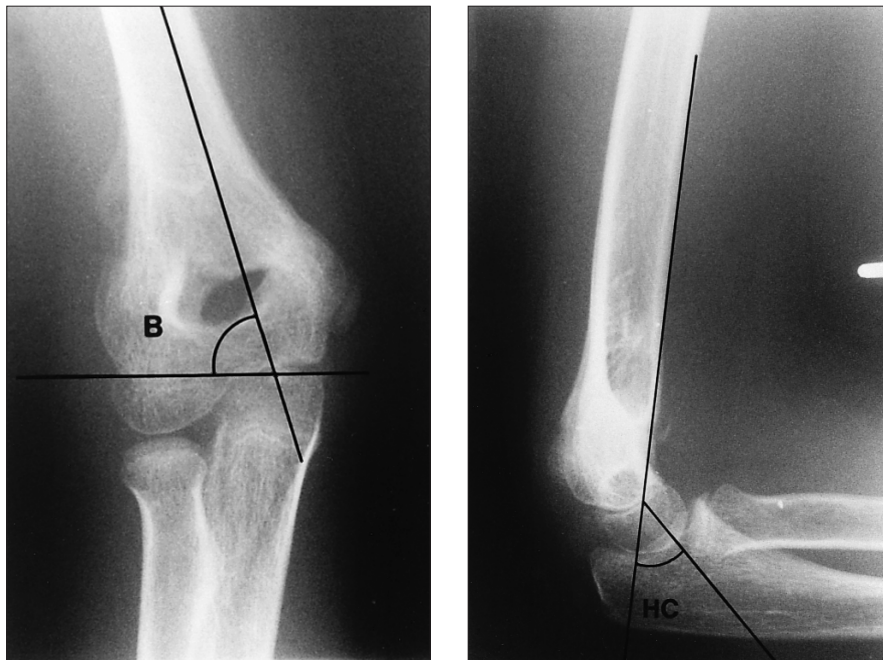
2° (ranging from 0° to 10°), based on 19 cases with comparable radiographs. The average difference between the intraoperative reduction and the final result at follow-up was also 2°, with the same range, based on 24 cases, indicating excellent maintenance of reduction. The average difference in humero-capitellar angle between the normal arm and the healed fracture was 5.3° (ranging from 0° to 40°), based on 17 cases. The average intraoperative to postoperative difference in humero-capitellar angle was 6.5° (ranging from 0° to 30°), based on 24 cases.

Using the criteria of Flynn, Matthews and Benoit<sup>17</sup> (Table V) to assess overall function, we found that 28 (82%) of 34 children had excellent or good results, 4 (12%) had fair results and 2 (6%) had poor results. At follow-up, the range of motion was satisfactory in 32 (94%) of the 34 children. Although 2 children (6%) had unsatisfactory motion according to the criteria of Flynn, Matthews and Benoit (more than 15° loss, 140° and 135° respectively), they experienced no functional limitations.

Worlock<sup>18</sup> showed a direct relationship between the Baumann angle and the carrying angle of the elbow. Also, the importance of careful, precise radiographic technique was stressed by Dodge<sup>1</sup> and Camp and associates.<sup>19</sup>



**FIG. 3.** A widely displaced type III fracture.



**FIG. 4.** Left: measurement of the Baumann angle, the angle (B) between a line drawn down the shaft of the humerus and a line drawn parallel to the capitellar physis. Right: measurement of the humero-capitellar angle, the angle (HC) between a line drawn down the anterior humeral shaft and a line that follows the coronoid orientation.

**Table III**

**Nerves Involved in Preoperative Neurologic Deficits Found in 15 of 41 Children**

Nerve involved	No. (and %) of children
Median sensory	11 (27)
Median motor	2 (5)
Anterior interosseous	2 (5)
Ulnar sensory	2 (5)
Radial sensory	4 (10)
Radial motor	5 (12)

Therefore, we used our measurements of the Baumann angle to represent the carrying angle, although this was not measured consistently at each follow-up visit. Using this method, we found

that the carrying angle was satisfactory in all 19 children who had a complete series of radiographs. Furthermore, none of our patients subsequently had cubitus varus deformity, Volkmann's

contracture, myositis ossificans or wound infection.

DISCUSSION

Percutaneous pinning after closed reduction has become the standard treatment for reducible supracondylar fractures. Numerous authors have compared this treatment to others. Prietto<sup>6</sup> reported a 5% incidence of cubitus varus after pin fixation, compared with a 33% incidence associated with Dunlop's traction. Pirone, Graham and Krajbich<sup>16</sup> reported excellent results in 78% of 96 patients treated with closed reduction and pin fixation. Open reduction and pinning have also been recommended by several authors for severe supracondylar fractures.<sup>7-9,11,20</sup> However, most pediatric orthopedic surgeons would reserve this approach for open fractures or for those associated with vascular injury.<sup>12-14,21</sup>

Although we agree that closed reduction should remain the first line of treatment, we believe that open reduction with internal or percutaneous pinning should be seriously considered when closed reduction is unattainable after 2 or 3 reasonable attempts. For type IIIb fractures, traction alone may not achieve bone-bone contact, (with the elbow flexed at about 45° to relax anterior soft structures). This is demonstrated on a shoot-through lateral x-ray film. Here, further manipulation may risk damage to nerve, vessel and other soft tissue, when the wide metaphysis is forced through a narrower buttonholed defect in the brachialis. If bone-bone contact is achieved without nerve or vessel compromise before or after reduction, then further manipulation is justified for better reduction. However if the radial pulse is still absent after reduction, and if the metaphyseal fragment is buttonholed through the brachialis and cannot be

Table IV

Intraoperative Findings in 41 Children

Finding	No. (and %) of children
No pulse*	2 (5)
Tented artery or nerve	9 (22)
Soft-tissue entrapment	31 (76)
Entrapment of	
brachialis muscle	15
brachialis muscle, radial nerve	2
brachialis muscle, periosteum	6
brachialis muscle, median nerve, brachial artery	2
periosteum	2
triceps	1
origin of flexor muscle	1
median nerve, brachial artery	1
brachial artery	1

\*Noted preoperatively

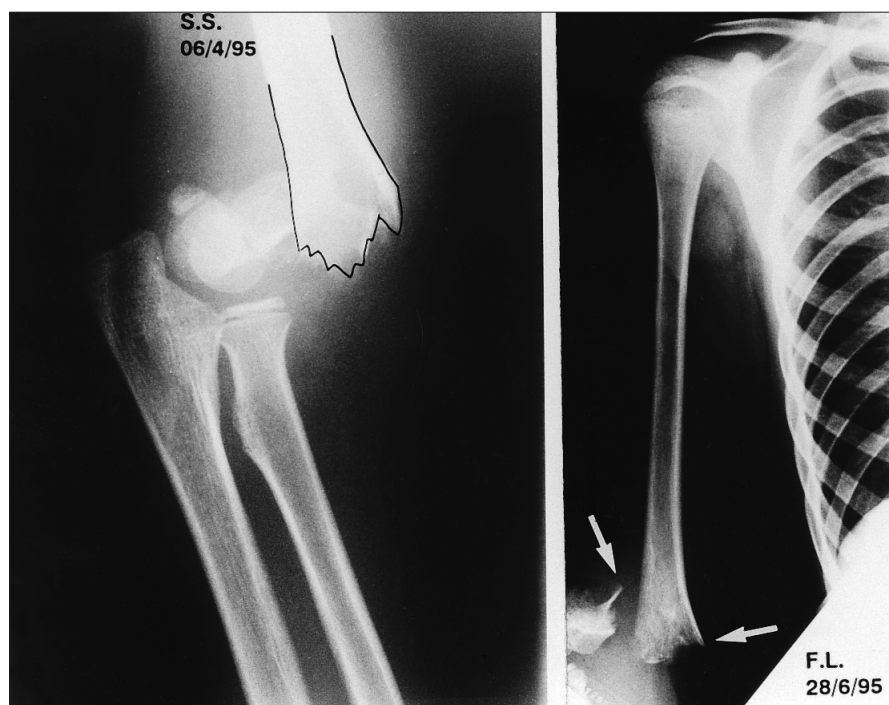


FIG. 5. Left: a jagged fracture line, which makes reduction difficult; right: spikes impeding reduction.

released by manipulation, open reduction should follow.

In a meta-analysis of 16 articles and 470 supracondylar fractures, Wilkins<sup>22</sup> reported a 1.5% incidence of infections, a 1.4% incidence of myositis ossificans and 0% incidence of lasting neurovascular deficit. Our results compare favourably with those of Wilkins. The children in this series had no infections and no myositis ossificans. Only 1 patient had a mild residual nerve deficit, and at follow-up this was improving.

Reports of cubitus varus have ranged from 0% to 33% with open re-

duction, with similar results after closed reduction.<sup>3,9,20,23</sup> No child in this review had cubitus varus based on measurements of the Baumann angle. Paradis and colleagues<sup>24</sup> stressed the importance of anatomic reduction of the critical medial column, whereas Minkowitz and Busch<sup>25</sup> described the impact of medial comminution on the development of cubitus varus. Close attention to these factors in the operating room and proper radiologic follow-up will ensure a low rate of cubitus varus.

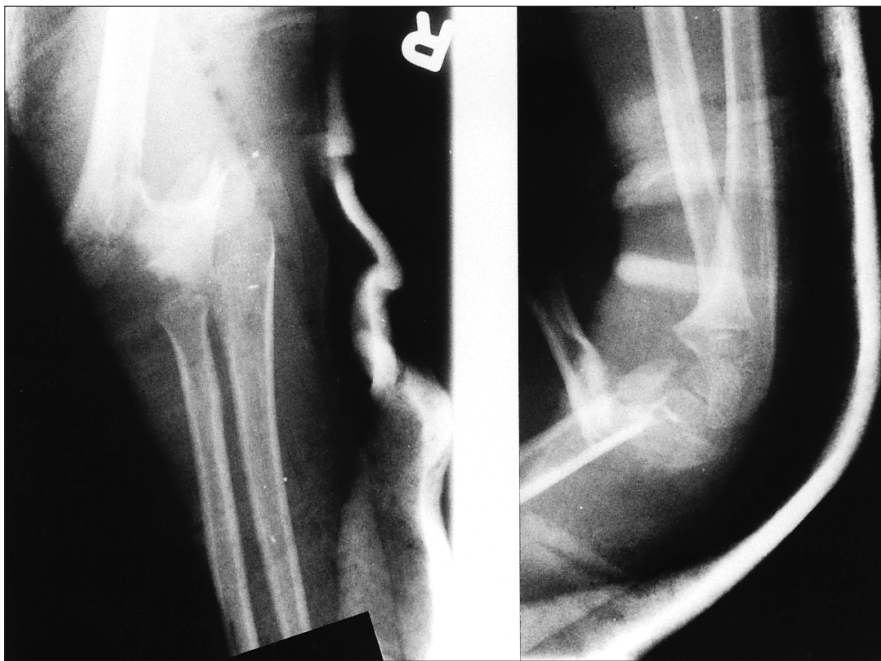
No child had a significant loss of motion; the 2 children with greater

than 15° difference in range of motion between arms could still move the affected arm through an arc of at least 100°. We believe this lack of clinical deficit was because the fractures were approached anteriorly over the metaphyseal fragment in most cases,<sup>26</sup> allowing decompression of the fracture site while preserving as much surrounding soft tissue as possible, thus minimizing future tissue fibrosis and contracture.

In view of the excellent results obtained in this series, we believe that open reduction of supracondylar fractures is safe and effective when indicated. It affords good cosmesis and function, and minimizes soft-tissue trauma and possible long-term complications from repeated attempts at closed reduction or from an imperfect reduction.

Even though the surgeon should usually attempt a gentle closed reduction, the presence of 1 or more of the following should suggest open reduction without fear of compromised elbow function: skin puckering from buttonholing of the metaphysis through the brachialis, loss of pulse with manipulation, a type III fracture with persistent wide displacement, a jagged fracture line and prominent metaphyseal or distal fragment spikes.

With an anterior approach over the proximal shaft fragment through tissues that have already been disrupted by the fracture, anatomic reduction can be achieved by reducing the fracture. Percutaneous medial and lateral pinning is then recommended. Postoperatively, immobilization of the arm at about 75° of elbow flexion in a posterior slab for 3 weeks is adequate for monitoring the radial pulse and to accommodate swelling. The pins can then be removed, and active elbow motion with a removable splint may begin. With the use of this regimen, excellent elbow function can be anti-



**FIG. 6.** A comminuted fracture that is extremely difficult to reduce anatomically by closed methods.

**Table V**

**Criteria of Flynn, Matthews and Benoit<sup>17</sup> for Assessing Healed Supracondylar Fractures**

Result	Rating	Loss of carrying angle and range of motion, °
Satisfactory	Excellent	0-5
	Good	6-10
	Fair	11-15
Unsatisfactory	Poor	> 15

cupated, and physiotherapy is rarely needed.

## References

1. Dodge ND. Displaced supracondylar fractures of the humerus in children. *J Bone Joint Surg [Am]* 1972;54:1408-18.
2. Palmer EE, Niemann KM, Vesely D, Armstrong JH. Supracondylar fractures of the humerus in children. *J Bone Joint Surg [Am]* 1978;60:653-6.
3. Worlock P, Colton C. Severely displaced supracondylar fractures of the humerus in children: a simple method of treatment. *J Pediatr Orthop* 1987; 7:49-53.
4. France J, Strong M. Deformity and function in supracondylar fractures of the humerus in children variously treated by closed reduction and splinting, traction, and percutaneous pinning. *J Pediatr Orthop* 1992;12:494-8.
5. Nacht JL, Ecker MD, Chung SMK, Lotke PA, Das M. Supracondylar fractures of the humerus in children treated by closed reduction and percutaneous pinning. *Clin Orthop* 1983; 177:203-9.
6. Prietto CA. Supracondylar fractures of the humerus: a comparative study of Dunlop's traction versus percutaneous pinning. *J Bone Joint Surg [Am]* 1979; 61:425-8.
7. Furrer M, Mark G, Ruedi T. Management of displaced supracondylar fractures of the humerus in children. *Injury* 1991;22:259-62.
8. Kekomaki M, Luoma R, Rikalainen H, Vilkki P. Operative reduction and fixation of a difficult supracondylar fracture of the humerus. *J Pediatr Orthop* 1984;4:13-5.
9. Weiland AJ, Meyer S, Tolo VT, Berg HL, Mueller J. Surgical treatment of displaced supracondylar fractures of the humerus in children. *J Bone Joint Surg [Am]* 1978;60:657-61.
10. Blount WP. *Fractures in children*. Baltimore: Williams & Wilkins; 1954.
11. Carcassonne M, Bergoin M, Hornung H. Results of operative treatment of severe supracondylar fractures of the elbow in children. *J Pediatr Surg* 1972; 7:676-9.
12. Elstrom JA, Pankovich AM, Kassab MT. Irreducible fractures of the humerus in children: a report of two cases. *J Bone Joint Surg [Am]* 1975;57: 680-1.
13. Millis MB, Singer IJ, Hall JE. Supracondylar fracture of the humerus in children. Further experience with a study of orthopaedic decision-making. *Clin Orthop* 1984;188:90-7.
14. Morrissy RT, Wilkins KE. Deformity following distal humeral fractures in childhood. *J Bone Joint Surg [Am]* 1984;66:537-62.
15. Gartland JJ. Management of supracondylar fractures of the humerus in children. *Surg Gynecol Obstet* 1959; 109:145-54.
16. Pirone M, Graham HK, Krajbich JJ. Management of displaced extension-type supracondylar fractures of the humerus in children. *J Bone Joint Surg [Am]* 1988;70:641-50.
17. Flynn JC, Matthews JG, Benoit RL. Blind pinning of displaced supracondylar fractures of the humerus in children: sixteen years experience with long-term follow-up. *J Bone Joint Surg [Am]* 1974;56:263-72.
18. Worlock P. Supracondylar fractures of the humerus: assessment of cubitus varus by the Baumann angle. *J Bone Joint Surg [Br]* 1986;68:755-7.
19. Camp J, Ishizue K, Gomez M, Gelberman R, Akeson W. Alteration of Baumann's angle by humeral position: implications for treatment of supracondylar humerus fractures. *J Pediatr Orthop* 1993;13:521-5.
20. Ramsey RH, Griz J. Immediate open reduction and internal fixation of severely displaced supracondylar fractures of the humerus in children. *Clin Orthop* 1973;90:130-2.
21. Mehserle WL, Meehan PL. Treatment of the displaced supracondylar fracture of the humerus (type III) with closed reduction and percutaneous pinning. *J Pediatr Orthop* 1991;11:705-11.
22. Wilkins KE. Fractures and dislocations of the elbow region. In: Rockwood CA Jr, Wilkins KE, King RE, editors. *Fractures in children*. 3rd ed. New York: JB Lippincott; 1991; p. 509-828.
23. Boyd DW, Aronson DD. Supracondylar fractures of the humerus: a prospective study of percutaneous pinning. *J Pediatr Orthop* 1992;12:789-94.
24. Paradis G, Lavallee P, Gagnon N, Lemire L. Supracondylar fractures of the humerus in children: technique and results of crossed percutaneous K-wire fixation. *Clin Orthop* 1993; 297:231-7.
25. Minkowitz B, Busch T. Supracondylar humerus fractures: current trends and controversies. *Orthop Clin North Am* 1994;25:581-94.
26. McIntyre W. Supracondylar fractures of the humerus. In: Letts M, editor. *Management of pediatric fractures*. New York: Churchill Livingstone; 1994. p. 167-98.