

Case Report

Étude de cas

SYNOVIAL CHONDROMATOSIS OF THE METACARPOPHALANGEAL JOINT: CASE REPORT AND REVIEW OF THE LITERATURE

Stephen C. Reed, BM BCh, MA, MSc, FRCSC; C. Stewart Wright, MD, FRCSC

Intra-articular synovial chondromatosis in the hand is rare but should be considered in the differential diagnosis of a swollen, stiff or painful joint. Other possible diagnoses include osteoarthritis, rheumatoid arthritis, gout, trauma and chronic infection, and unless enchondral ossification of loose bodies is seen the diagnosis of synovial chondromatosis may not be made preoperatively. A 69-year-old man with synovial chondromatosis of the metacarpophalangeal joint is reported. The joint was swollen and tender. He had not sustained trauma and there was no evidence of arthritis, involvement of other joints or infection. Complete synovectomy with removal of all loose bodies was successful and his symptoms resolved. Intra-articular synovial chondromatosis is a benign condition, but spontaneous resolution is the exception and surgical synovectomy remains the most effective treatment.

La chondromatose synoviale intra-articulaire de la main est rare, mais il faudrait l'envisager dans le diagnostic différentiel qui porte sur une articulation douloureuse, raide ou enflée. Les autres diagnostics possibles comprennent l'ostéoartrite, l'arthrite rhumatoïde, la goutte, un traumatisme et une infection chronique et, si l'on ne voit pas d'ossification enchondrale des arthrophytes, on ne peut diagnostiquer une chondromatose synoviale avant l'intervention. On décrit le cas d'un homme de 69 ans atteint de chondromatose synoviale de l'articulation métacarpophalangienne. L'articulation était enflée et sensible. Il n'avait pas subi de traumatisme et il n'y avait aucun signe d'arthrite, d'atteinte d'autres articulations ou d'infection. La synovectomie complète et l'ablation de tous les arthrophytes a réussi et les symptômes sont disparus. La chondromatose synoviale intra-articulaire est une infection bénigne, mais la disparition spontanée est l'exception et la synovectomie chirurgicale demeure le traitement le plus efficace.

Synovial chondromatosis is an uncommon condition of metaplastic focal formation of cartilage in the intimal layer of the synovial membrane. If the cartilage nodules undergo enchondral ossification, the condition is termed osteochondromatosis. Numerous opalescent nodules pepper a thickened synovium, occasionally breaking free to form loose bodies.

Clinically, the presentation is one of joint pain and swelling, stiffness, crepitus and mechanical symptoms such as locking. Originally described by Laennec in 1813,¹ the condition is

classically monoarticular and is found in the larger joints — hips, knees, shoulders and ankles.² Physical examination may reveal a decreased range of motion, swelling or a soft-tissue mass. Plain radiographs show periarticular soft-tissue swelling and calcification in up to 33% of cases. The disease is most often progressive, although spontaneous regression has been reported.³ Malignant change has been reported^{4,5} but is rare. Treatment is principally by synovectomy.

Synovial chondromatosis occurring in the hand is uncommon; most reported

cases involved extra-articular structures such as the tendon sheath.^{6,7} We present a case of truly intra-articular chondromatosis occurring in the metacarpophalangeal joint of the small finger.

CASE REPORT

A 69-year-old right-handed man gave a 1-year history of pain, swelling and stiffness in the metacarpophalangeal (MP) joint of the small finger of his right hand. He did not report any locking of the joint. There was no history of trauma. He was otherwise

From the The Orthopaedic and Arthritic Hospital, Toronto, Ont.

Accepted for publication Nov. 15, 1995

Correspondence to: Dr. C. Stewart Wright, The Orthopaedic and Arthritic Hospital, 43 Wellesley St. E, Toronto ON M4Y 1H1

© 1996 Canadian Medical Association (text and abstract/résumé)

healthy and no other joints were involved. Examination revealed a diffusely swollen MP joint, with moderate tenderness along the joint line and a range of motion from 15° to 60°. Plain radiographs revealed soft-tissue swelling with a radiopaque density dorsal and proximal to the joint (Fig. 1). No evidence of arthritis was noted. Aspiration of the joint by the referring doctor had been unsuccessful.

Under intravenous regional anesthesia, with a tourniquet, the extensor mechanism was identified through a transverse dorsal incision over the MP joint and divided longitudinally to expose the joint capsule. The dorsal capsule was expanded and extended proximally along the metacarpal. Division of the capsule revealed thickened inflammatory synovium, with numerous chondrous nodules both in the wall and lying free. Although continuous with the joint, these loose bodies were well contained within the dorsal pouch

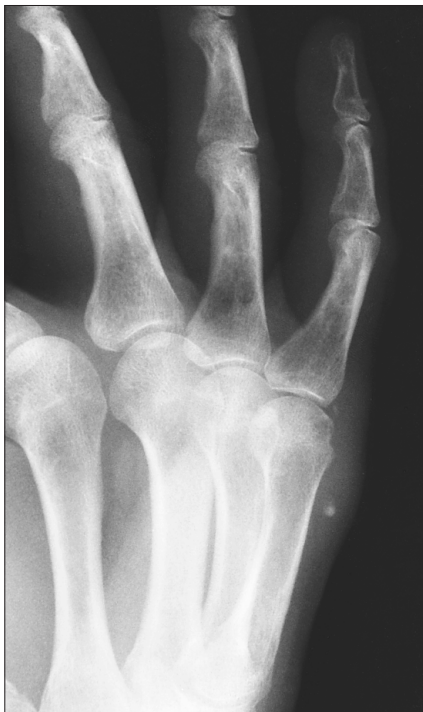

FIG. 1. Patient's right hand showing ossification adjacent to the involved fifth metacarpophalangeal joint.

of synovium and capsule and not actually between the joint surfaces. The articular surfaces were intact. A complete synovectomy was carried out and all loose bodies were removed (Fig. 2).

At follow-up 6 months postoperatively, the patient had complete resolution of his symptoms and a range of motion from 0° to 90°.

DISCUSSION

Synovial chondromatosis is uncommon in the hand. Of the reported cases, a number involve the tenosynovium and are therefore extra-articular.^{6,7} Intra-articular chondromatosis has been reported as causing painful locking in the wrist,⁸ swelling and stiffness in the interphalangeal joints of the thumb⁹ and long finger.^{10,11} Only one other case involving the MP joint has been reported.¹²

The literature supports a traumatic etiology for tenosynovial chondromatosis with well-documented injuries preceding the pathologic process in all cases. It is possible that this condition is so benign that it exists undetected until brought to the attention of the patient or physician by the injury.

However, the described cases indicate no evidence of pre-existing symptoms.

In contrast to the tenosynovial form, intra-articular chondromatosis shows no association with trauma. All cases, including ours, arose spontaneously with no specific or repetitive injury reported by the patients even on direct questioning.⁸⁻¹¹ The natural history is variable, with symptoms present from 3 months to 10 years. Pain, swelling and loss of motion are the principal complaints. Locking, a common symptom in other joints, is rarely a problem.⁸ This is likely due to the location of the loose bodies, which appear to become well contained within the expanded capsule dorsally and volarly and therefore do not become entrapped between the joint surfaces. The majority of cases have positive radiologic findings, including ossified loose bodies and periarticular erosions.^{8,10,11} Destruction of the joint space is rare and this is confirmed at surgery, where the articular surfaces remain well preserved. In only one case had the joint degenerated sufficiently to warrant fusion.¹⁰

Treatment in most cases of intra-articular chondromatosis is by arthro-

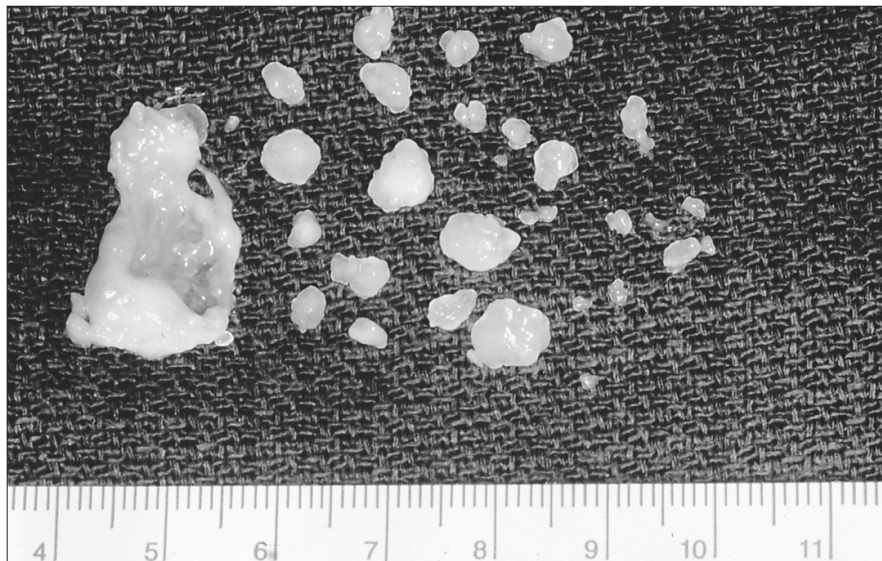


FIG. 2. Resected specimen showing synovium and loose bodies.

tomy, removal of loose bodies and synovectomy. This is uniformly successful with all patients reporting resolution of symptoms and improved range of motion at follow-up. The condition does not appear to recur,^{4,8,11} and in one case the periarticular erosions were noted to have filled in.¹¹

Synovial chondromatosis is one of the least common causes of joint swelling and loose bodies. Osteoarthritis, rheumatoid arthritis, gout, chronic infection (including tuberculosis) and trauma may all present in a similar fashion. Unless enchondral ossification of the loose bodies is noted on radiographs, the diagnosis may remain unclear until surgery. The gross pathological appearance in association with intact articular surfaces is diagnostic. Surgical treatment is straightforward and successful.

Intra-articular synovial chondromatosis in the hand is a rare but benign condition that should be considered in the differential diagnosis of patients presenting with a swollen, stiff or painful joint. Spontaneous resolution is the exception and surgical synovectomy remains the most effective treatment.

References

1. Halstead AE. Floating bodies in joints. *Ann Surg* 1895;22:327-42.
2. Jeffreys TE. Synovial chondromatosis. *J Bone Joint Surg [Br]* 1967;49:530-4.
3. Swan EF, Owens WF. Synovial chondrometaplasia: a case report with spontaneous regression and a review of the literature. *South Med J* 1972;65:1496-1500.
4. Constant E, Harebottle NH, Davis DG. Synovial chondromatosis of the hand. *J Plast Reconstr Surg* 1974;54:353-8.
5. Mullins F, Berard CW. Chondrosarcoma following synovial chondromatosis. *Cancer* 1965;18:1180-8.
6. Lynn MD, Lee J. Periarticular tenosynovial chondrometaplasia. *J Bone Joint Surg [Am]* 1972;54:650-2.
7. Murphy AF, Wilson TN. Tenosynovial osteochondroma in the hand. *J Bone Joint Surg [Am]* 1958;40:1236-40.
8. Ono H, Yajima H, Fukui A, Tamai S. Locking wrist with synovial chondromatosis: report of two cases. *J Hand Surg [Am]* 1994;19:797-9.
9. Lewis MM, Marshall JL, Mirra JM. Synovial chondromatosis of the thumb. *J Bone Joint Surg [Am]* 1974;56:180-3.
10. Kettelkamp DB, Dolan J. Synovial chondromatosis of an interphalangeal joint of the finger. *J Bone Joint Surg [Am]* 1966;48:329-32.
11. Takami H, Takahashi S, Ando M. Synovial chondromatosis of the proximal interphalangeal joint of a finger. *J Hand Surg [Am]* 1994;19:794-6.
12. Szepesi J. Synovial chondromatosis of a metacarpophalangeal joint: a case report. *Acta Orthop Scand* 1975;46:926-30.