

A simple manoeuvre to minimise bladder injury during laparoscopic incisional hernia repair

DL Sanders, JP Evans, I Finlay
Royal Cornwall Hospitals NHS Trust, UK

CORRESPONDENCE TO
David Sanders, E: dsanders@doctors.org.uk

BACKGROUND

Bladder injury during laparoscopic incisional hernia repair has a reported incidence of 0.5%.¹ Mesh placement during repair may be difficult when the fascial defect extends towards the pubis. The bladder may need to be separated from the peritoneum in order to place the mesh safely and achieve adequate mesh overlap.² We propose a simple intra-operative technique to help identify bladder position and better define the plane for dissection.

TECHNIQUE

A transurethral Foley catheter is inserted. Prior to pelvic dissection, the bladder is filled with 400ml of normal saline via the catheter. As the bladder fills, it projects upward out of the pelvis into the abdomen and defines the plane for dissection. The bladder should now be within the surgical field and easily identifiable.

DISCUSSION

The above technique provides a simple way to confirm bladder position laparoscopically. Once visualised within the surgical field, further dissection, mesh placement and safe mesh fixation avoiding the bladder can proceed. Furthermore, where iatrogenic bladder injury is suspected, the technique also provides direct visualisation of any leak through retrograde methylene blue dye instillation.³

References

1. Dalessandri KM, Bhojru S, Mulvihill SJ. Laparoscopic hernia repair and bladder injury. *JSLs* 2001; **5**: 175–177.
2. Frantzides C LL, Carlson M. Technical Factors Predisposing to Recurrence after Minimally Invasive Incisional Herniorrhaphy. In: Schumpelick V, Fitzgibbons RJ, eds. *Recurrent Hernia*. Heidelberg: Springer; 2007. pp170–178.
3. Carbonell AM, Kercher KW, Matthews BD *et al*. The laparoscopic repair of suprapubic ventral hernias. *Surg Endosc* 2005; **19**: 174–177.

A simple aid to fracture reduction in the digit

C Weddell¹, A McMurtrie², AK Hamad²
¹Shrewsbury and Telford Hospital NHS Trust, UK
²Robert Jones and Agnes Hunt Orthopaedic Hospital NHS Foundation Trust, UK

CORRESPONDENCE TO
Charlotte Weddell, E: lottietunstall@doctors.org.uk

BACKGROUND

We describe a simple method enabling traction to be applied to a digit and providing control of rotation, alignment and length while avoiding inadvertent radiation to the surgeon's or assistant's fingers. Furthermore, it provides excellent exposure to the digit, alleviating difficulties in fixation of complex fractures.

TECHNIQUE

A 1.1mm K-wire is inserted under fluoroscopic guidance transversely across the base of the distal phalanx of the injured digit. The wire is then bent on either side and the sharp ends trimmed. A Ramp-ley sponge holder is used to hold the wire (Figs 1 and 2). Traction is

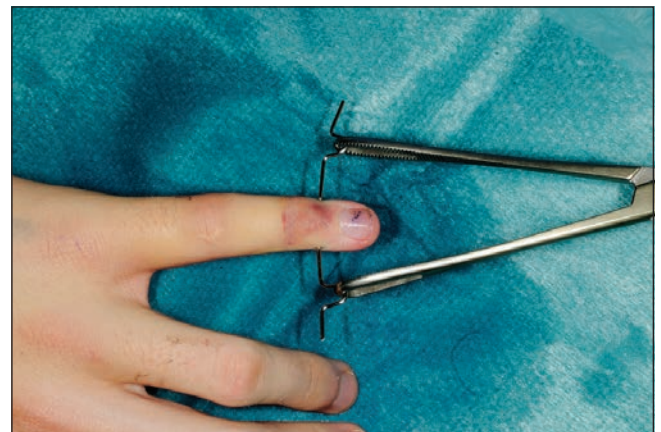

Figure 1 Anteroposterior photograph

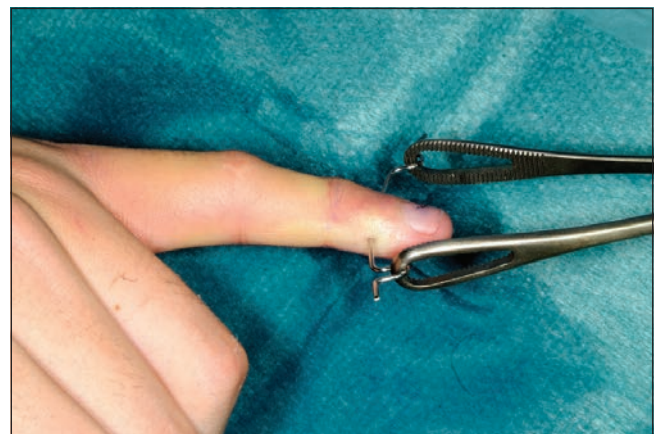


Figure 2 Lateral photograph

applied by holding on to the sponge holder to enable ligamentotaxis to reduce the fracture (Figs 3 and 4). Rotational deformity, angulation, length and radial/ulnar deviation can be corrected by applying varying forces. The standard method of fracture fixation can then be performed.

DISCUSSION

We have found this method extremely useful when fixing fractures of the digits where optimal access to the fracture site is required while continued traction is necessary to maintain reduction. This is particularly the case in fractures of the middle phalanx where alternative methods of applying traction may interfere with access to the fracture site. Although it is not an original principle, we believe that this technique has not been described previously in the literature. We strongly recommend this technique to those involved in the treatment of fractures of the hand.

A simple exercise to encourage precise suture placement

RL Storey, MR Gouda, AM Smith
Leeds Teaching Hospitals NHS Trust, UK

CORRESPONDENCE TO

Rowland Storey, E: rowland_storey@yahoo.co.uk

Surgical simulation is becoming increasingly important due to a reduction in operative exposure during surgical training. We describe a method to encourage precise suture placement using simple equipment that can be practised outside the skills laboratory.

Affix a Post-it® note to a table with its adhesive edge lying to your left. Using an 'inside to outside, outside to inside' technique, suture along the free edge of the Post-it® note (Fig 1). Now, pull out



Figure 3 Pre-reduction x-ray

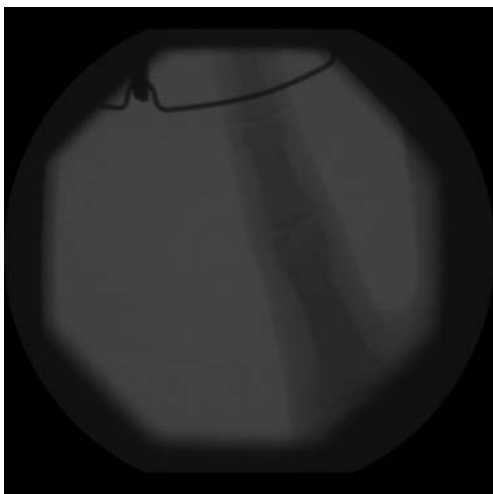


Figure 4 Post-reduction x-ray (with traction)




Figure 1 Initial suture placement

the stitch and resuture through the prior made perforations (Fig 2). This simple exercise encourages delicate handling to minimise tissue trauma and a good needle holder technique to facilitate the placement of precise stitches under direct vision.




Figure 2 Accurate continuous suture practice