

# Nuclear DNA content and p53 overexpression in stage I squamous cell carcinoma of the tongue compared with advanced tongue carcinomas

A Högmo, R Kuylenstierna, J Lindholm, A Nathansson, G Auer, E Munck-Wikland

## Abstract

**Aims**—To evaluate the predictive value of the nuclear DNA content (image cytometry) and p53 overexpression (immunohistochemistry using antibody CM-1) in uniformly treated stage I carcinomas of the mobile tongue. Also, to compare stage I carcinomas with advanced tongue carcinomas (stages II–IV).

**Methods**—Archival formalin fixed, paraffin wax embedded tumour specimens from 54 patients with stage I squamous cell carcinoma and 37 patients with advanced squamous cell carcinoma were analysed. Mean follow up time of the stage I carcinomas was 71 months (median, 62.5; range, 6–175).

**Results**—Twenty three patients (stage I) had recurring disease: 10 had local recurrence (in the tongue) and 13 had regional recurrence (cervical metastases). Locally recurring stage I carcinomas had a more pronounced DNA deviation than the other stage I carcinomas and this degree of deviation was comparable with the DNA content of advanced carcinomas. Stage I carcinomas that developed regional recurrences overexpressed p53 more frequently. In Cox multivariate regression analysis of time to recurrence, DNA deviation was a significant parameter in tumours that recurred locally ( $p = 0.032$ ). p53 overexpression was the only parameter close to significance for regional recurrence ( $p = 0.065$ ).

**Conclusions**—Nuclear DNA content and p53 immunostaining are of value for the prediction of recurrence of stage I squamous cell carcinomas of the mobile tongue. Stage I tongue carcinomas that are prone to local recurrence show the same DNA content as do advanced tongue carcinomas.

(J Clin Pathol: Mol Pathol 1998;51:268–272)

Keywords: squamous cell carcinoma; DNA; protein p53

surgery. However, among stage I tongue carcinomas there is a subgroup of tumours that is prone to local and/or regional recurrence. If this more aggressive behaviour could be predicted, this subgroup could be subjected to extended treatment, thus sparing patients with less aggressive carcinomas the morbidity caused by such treatment. The problem is even more urgent because recent epidemiological studies in Sweden show an increased incidence of tongue cancers among people less than 40 years of age, yet there has been no improvement in treatment results for many decades.<sup>1</sup>

Many attempts have been made to predict the outcome for tongue carcinomas through histopathological studies and molecular biology.<sup>2–6</sup> The degree of DNA deviation in a tumour cell population reflects its genetic instability but DNA analysis, by flow or image cytometry, has yielded varying results as a predictive tool when applied to head and neck carcinomas.<sup>7–9</sup>

Mutation of the p53 tumour suppressor gene usually results in a gene product consisting of a defective p53 protein with a prolonged half life, which enables detection through immunohistochemical methods. For head and neck cancers, p53 immunoreactivity has been shown to be a poor predictive value, in contrast to studies involving colonic or breast carcinomas. However, p53 studies on head and neck cancers have to a great extent been performed on material from tumours at different sites and at different stages, where biological parameters might have a different impact.<sup>7–10–13</sup> p53 is also receiving further attention as an approach for gene therapy.<sup>14</sup>

The aim of this study was to evaluate the importance of nuclear DNA content and p53 immunostaining in predicting the risk of recurrence of uniformly treated stage I carcinomas of the mobile tongue. A secondary aim was to compare these biological properties of small carcinomas to more advanced carcinomas (stages II–IV) of the mobile tongue.

## Methods

### PATIENTS

Fifty six consecutive patients were treated for squamous cell carcinoma of the mobile tongue at the department Oto-Rhino-Laryngology of Karolinska Hospital in Stockholm, Sweden, from January 1980 to November 1990. Nineteen of these patients presented with tumours classified as stage I (UICC; 1987). These 19 patients were added to 41 patients suffering from stage I tongue carcinomas collected during a multicentre study in Sweden from 1974

Department of  
Oto-Rhino-Laryngology,  
Head and Neck  
Surgery, Karolinska  
Hospital, S-171 76  
Stockholm, Sweden  
A Högmo  
R Kuylenstierna  
E Munck-Wikland

Department of Tumor  
Pathology, Karolinska  
Hospital  
J Lindholm  
G Auer

Department of  
Oto-Rhino-Laryngology,  
Head and Neck  
Surgery, Söder  
Hospital, S-118 83  
Stockholm, Sweden  
A Nathansson

Correspondence to:  
Dr Högmo.

Accepted for publication  
16 June 1998

Carcinoma of the mobile part of the tongue is a challenging disease: it has a poor prognosis when advanced and even tumours that are discovered at an early stage can have a fatal course.

In Sweden, stage I (UICC; 1987) cancers of the mobile tongue are treated with wedge excision only and, in general, more advanced tumours (stages II–IV) are treated with preoperative irradiation followed by more extensive

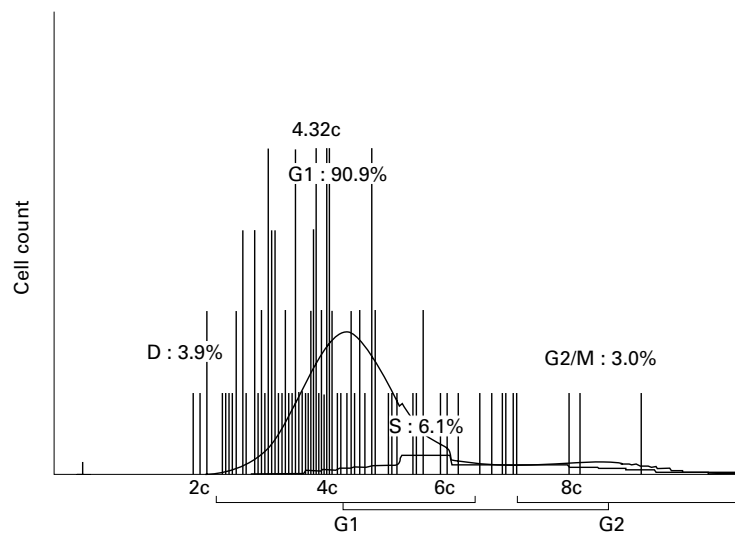


Figure 1 Example of DNA histogram for one specimen. Nuclear DNA content:  $> 5cER = 18.4\%$ .

to 1986 and comprised the stage I group of 60 patients. All patients' records were reviewed for clinical data. Six patients were then excluded: two patients who had received preoperative or postoperative irradiation and another four patients who had been treated with a dissection of the upper neck, in addition to local surgery. Four patients died from intercurrent diseases during the follow up time. All surgical excisions were performed including a margin of macroscopically tumour free tissue of at least 1 cm. All patients had tumour free margins of the surgical specimens. The mean follow up time was 71 months (median, 62.5; range, 6–175).

Thus, the group of stage I tongue carcinomas comprised 54 patients: 26 men (age range, 38–80 years; mean 63) and 28 women (age range, 36–88 years; mean, 64).

The group of advanced (stages II–IV) tongue carcinomas, consisted of the remaining 37 consecutive patients from the Karolinska Hospital: 25 men (age range, 29–84 years; mean 61) and 12 women (age range, 22–92 years; mean 67).

#### SPECIMENS

Three serial sections were cut (4  $\mu$ m thick) from the formalin fixed, paraffin wax embedded tumour specimens. The first section was stained with haematoxylin and eosin for histopathological analysis, the second was stained according to the Feulgen technique for image cytometry DNA analysis.<sup>15</sup>

The third section was deparaffinised in xylene and passed through a graded ethanol series. The sections underwent a 15 minute treatment with 0.05% protease (Sigma P5147; Labkemi/Sigma-Aldrich Sweden AB, Stockholm, Sweden). After blocking with 0.5% H<sub>2</sub>O<sub>2</sub> in water and 1% bovine serum albumin (BSA) in phosphate buffered saline (PBS), p53 rabbit polyclonal antibody CM-1 (Novocastra, Newcastle upon Tyne, UK) (1/700 dilution in 1% BSA) was added and the sections were incubated overnight at 4°C in a humidified chamber. After washing, the slides were incubated with biotinylated antirabbit IgG. A

third layer of ABC Vectastain kit elite (Vector Laboratories, California, USA) and diaminobenzidine (DAB) was added. Finally, a weak counterstain was used to visualise the nuclei.

#### DNA MEASUREMENT

For the quantitative DNA analysis, a densitometric device, the Ahrens image analysis system (Bargtheide, Hamburg, Germany) was used (Microscope NIKON, plan objective 40/0.95, TV based, video CCD camera).

The DNA content of 100 cell nuclei/specimen was registered. Lymphocytes were used as control cells to establish the normal diploid (2c) value.<sup>16</sup>

DNA content up to 4c is seen in premitotic normal cells, but DNA values exceeding 5c are found only rarely in normal epithelial cells. The percentage of cells with a nuclear DNA content of  $> 5c$  (%5c exceeding rate; %5cER) of each specimen was calculated (fig 1).

#### p53 IMMUNOSTAINING

The specimens were considered to be p53 positive (+) when a distinct brown staining, confined to the nuclei, could be seen in at least 1% of the cells.

For the p53 analysis, the MDA 231 breast cancer cell line was used as an external positive control. Non-tumour cells were used as an internal negative control.

#### STATISTICAL METHODS

The  $\chi^2$  test was used to determine the differences in distribution between groups. Differences between means were determined with the Student's *t* test, and all *p* values are two tailed. Four patients who died from intercurrent disease during the follow up were excluded from these tests (*n* = 50). For univariate analysis of categorical data (p53 and grade of differentiation) in relation to time to recurrence, the log rank test was applied, whereas Cox regression analysis was used for univariate evaluation of the importance of %5cER (continuous variable) (*n* = 54).

Cox multivariate regression analysis was applied to evaluate which of the factors had the greatest influence on recurrence and survival. The level of statistical significance was set at *p* = 0.05.

#### Results

Four out of 54 patients died from intercurrent disease during follow up (after 6, 15, 17, and 31 months). For each of the following analyses the number of included patients is stated.

#### RECURRENCE

Twenty three of the 54 patients with stage I tongue carcinoma had a recurrence during the follow up time. Ten patients had local recurrence in the tongue (10 of 54) and 13 patients had regional recurrence (cervical metastases; 13 of 54).

#### NUCLEAR DNA CONTENT

Table 1 and fig 2 give the result for nuclear DNA content. Stage I tumours that later recurred, locally or regionally, displayed a

Table 1 Analysis of nuclear DNA content (%5cER) and immunohistochemistry (IHC) for p53

	%5cER				IHC p53		
	n	Mean	SD	Range	+	-	Error
All stage I tumours	50	18	15	0-65	24	24	2
Local recurrence	10	29	19	2-65	4	6	
Regional recurrence	13	19	13	3-45	9	3	1
No recurrence	27	14	12	0-43	11	15	1
Advanced tumours	37	24	16	0-58	19	16	2

Stage I tongue carcinomas (n = 50) and the group of advanced (stages II-IV) carcinomas (n = 37).

higher %5cER than non-recurrent tumours ( $p = 0.021$ ;  $n = 50$ ; Student's  $t$  test). This difference was a result primarily of the locally recurring tumours ( $p = 0.012$ ;  $n = 50$ ; Student's  $t$  test).

Compared with stage I carcinomas, stage II-IV carcinomas tended to show a more pronounced DNA aberration expressed as %5cER ( $p = 0.079$ ; Student's  $t$  test).

However, stage I carcinomas with subsequent recurrence displayed DNA values comparable to the values of the stage II-IV carcinomas ( $p = 0.868$ ; Student's  $t$  test).

#### p53 IMMUNOHISTOCHEMISTRY

Twenty four of 54 (with two immunohistochemical technical errors) stage I carcinomas and 19 of 35 stage II-IV carcinomas (with two immunohistochemical technical errors) showed p53 positive staining (table 1). The stage I carcinomas that developed regional recurrence were more often p53 positive than stage I carcinomas without regional recurrence ( $p = 0.046$ ;  $n = 50$ ;  $\chi^2$  test).

#### NUCLEAR DNA CONTENT AND p53 IMMUNOSTAINING

There were no differences in DNA aberration between p53 positive and p53 negative lesions either for stage I or stage II-IV tumours (Student's  $t$  test) (table 1).

To evaluate whether nuclear DNA content or p53 immunostaining could have altered as a

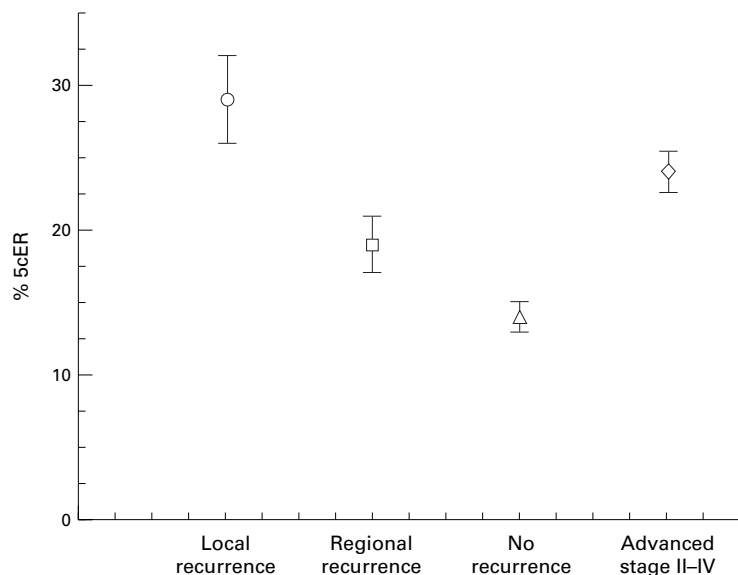


Figure 2 Means and standard error of means for stage I tongue carcinomas with (local recurrence,  $n = 10$ ; regional recurrence,  $n = 13$ ) or without recurring disease ( $n = 31$ ), and for advanced (stage II-IV) carcinomas ( $n = 37$ ).

Table 2 Stage and differentiation

Stage	n	Well	Moderate	Poor
I	54	28	22	4
II	13	4	6	3
III	13	2	9	2
IV	11	2	5	4

Table 3 Results of statistical analyses

Analysis	Factor	RH	CI	p value
A	%5cER	1.04	1.01-1.07	0.020
	%5cER	1.04	1.00-1.07	0.032
B	Differentiation	0.79	0.20-3.11	0.737
	p53	1.05	0.29-3.81	0.936
C	%5cER	1.01	0.97-1.04	0.703
	Differentiation	0.84	0.25-2.76	0.768
	p53	0.28	0.07-1.08	0.065

Analysis A, Cox regression analysis of %5cER  $v$  time to local recurrence. Analysis B, Cox multivariate regression analysis of %5cER, differentiation (well, 1; moderate/poor, 0), and p53 immunostaining (p53+, 1; p53-, 0)  $v$  time to local recurrence. Analysis C, Cox multivariate regression analysis of %5cER, differentiation, and p53 immunostaining (same coding)  $v$  time to regional recurrence.

RH, relative hazard; CI, 95% confidence interval.

result of the age of the specimens, the first 14 and the last 15 specimens were compared and no differences were found.

#### TUMOUR DIFFERENTIATION AND RECURRENCE

Table 2 gives detail of tumour stages and differentiation. All tumour specimens had been graded into well, moderately, or poorly differentiated.<sup>17</sup> More than half the stage I carcinomas were well differentiated, whereas less than a quarter of stage II-IV tumours were well differentiated ( $p = 0.007$ ;  $n = 54$ ;  $\chi^2$  test).

Among the stage II-IV tumours, the more advanced tumours dominated, and there were almost twice as many stage III-IV tumours as there were stage II tumours.

Among stage I carcinomas with local recurrence, six of 10 were well differentiated tumours, whereas carcinomas with regional recurrence were moderately or poorly differentiated (eight of 13). However, the differentiation of tumours with local or regional recurrence was not significantly different to that of non-recurrent carcinomas.

#### TIME TO RECURRENCE

Time to recurrence was defined as the time from diagnosis to when a recurring tumour was verified through a biopsy (months). Table 3 and fig 3 show times of recurrence.

The mean time to any kind of recurrence (local or regional) was 20 months (range, 3-56). For local recurrence the mean was 30 months (range, 11-56), and for regional recurrence the mean was 12 months (range, 3-40).

Statistical comparisons of the recurrence rate for tumours with different results of p53 immunostaining (+/-) and grade of differentiation (poor, moderate, well), respectively, were made using the Log Rank test ( $n = 54$ ).

There was a significant difference in the risk for regional recurrence depending on p53 immunostaining ( $p = 0.036$ ) (fig 3) but no significance for grade of differentiation ( $p = 0.359$ ).

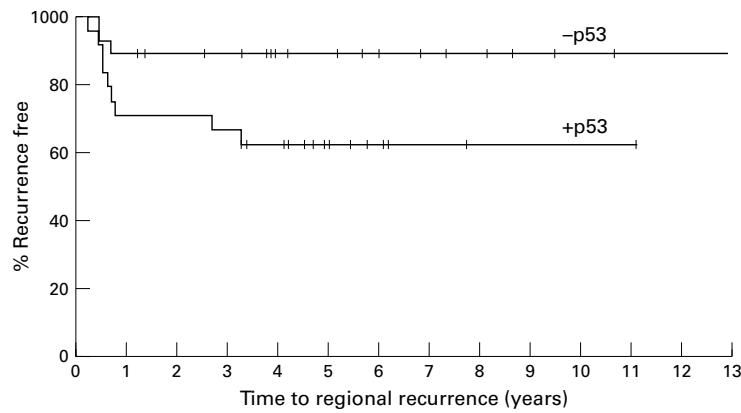


Figure 3 Percent patients free of regional recurrence against time to regional recurrence. Patients whose tumours were immunohistochemically positive (+p53) v patients whose tumours were immunohistochemically negative ( $p = 0.036$ ; Log Rank test).

p53 immunostaining or grade of differentiation were not significantly different for local or any (local or regional) recurrence.

For evaluation of %5cER and recurrence, Cox regression analysis was performed ( $n = 54$ ).

Results were significant for local recurrence ( $p = 0.020$ ) (table 3), and for local or regional recurrence ( $p = 0.053$ ), but were not significant for regional recurrence.

Finally, Cox multivariate regression analysis was used to weigh the impact of the parameters: %5cER, grade of differentiation, and p53 immunostaining on recurrence ( $n = 54$ ).

For local recurrence, %5cER was significant ( $p = 0.032$ ) (table 3).

For regional recurrence, only p53 immunostaining was close to significance ( $p = 0.065$ ) (table 3).

For local or regional recurrence, only %5cER showed a borderline significance ( $p = 0.066$ ).

#### SURVIVAL

Ten of 54 patients died from disease during the follow up time. Comparisons of survival according to the grade of differentiation and p53 immunostaining were performed, using the Log Rank test. None of the variables had any significant impact on survival. Cox regression analysis showed no significance between evaluation of %5cER and survival.

#### Discussion

Our study shows that image cytometry DNA analysis and p53 immunostaining in stage I tongue cancer can be useful in predicting the risk of recurrence. Tumours that recurred locally had a significantly higher degree of DNA deviation compared with tumours without local recurrence, and carcinomas that developed regional recurrence were more often p53 immunoreactive. Our study also shows that more aggressive tumours had a DNA content comparable to the more advanced (stages II–IV) carcinomas. Conventional histopathological grading of differentiation was not useful for evaluating the aggressiveness of stage I tongue carcinomas, but by adding “molecular” parameters, a more precise or “biological” classification of carcinomas might be possible.

When a limited tongue carcinoma recurs locally after surgery, the margins are always questioned. All specimens that were included showed free margins. However, the severe DNA deviation in the locally recurring tumours could indicate that the tumour, as well as the local recurrence, grew from a mucosa with precancerous features at a molecular level, undetectable by the microscope. These carcinomas could have developed as a result of “field cancerisation” rather than from insufficient margins.<sup>18</sup> Genetic alterations in histologically normal mucosa from patients harbouring oral carcinomas have been demonstrated previously.<sup>19</sup>

Our results showed that overexpression of the p53 protein correlated with the risk of development of a regional recurrence. The p53 gene is activated in response to DNA damage. The wild-type p53 protein interacts with the WAF1 gene, which regulates the cell cycle via its protein (p21) inhibiting the cyclin–cyclin dependant kinase systems. The tumour suppressor function of p53 works in the G1 phase of the cell cycle, allowing time for control of DNA structure and repair. p53 might also induce cell death by apoptosis. Thus, an immortalised cell clone that has lost p53 tumour suppressor function could possess growth advantages leading to (early) spread of tumour cells and, as a result, regional recurrence. Alterations of the p53 gene are considered to be an early event in the development of squamous cell carcinomas and could be a prerequisite for the survival of tumour cells with severe DNA aberrations. No correlation between the degree of DNA deviation and immunohistochemical p53 staining was found because p53 overexpression detected by immunohistochemistry does not always reflect mutations of the p53 gene.<sup>20, 21</sup> However, further studies of the genetic alterations in our specimens would be of great interest.

In earlier investigations, Gluckman *et al* found that p53 positive T1 carcinomas of the oral cavity had a more aggressive course and a worse prognosis than p53 negative tumours.<sup>22</sup> Leedy *et al*, however, found no correlation between the presence of p53 overexpression and neck nodal metastasis.<sup>23</sup>

Over the years, numerous studies have shown varying results on the prognostic value of DNA and p53 analysis for head and neck cancer. The differences might be because of variations in methodologies and the selection of patients. In many reports, tumours from different sites and of various sizes (T and N categories) were included.<sup>7, 8, 10–13</sup> The anatomical origin of a tumour plays a role in its development, its possibility to progress, and the risk of (occult) metastasis.<sup>24</sup> Thus, the diversity of sites in the relatively small series of head and neck cancers presented over the years has probably influenced the results of the studies on biological markers for these tumours.

Depending on tumour stage, biological parameters might play different roles because the more advanced tumours have a more pronounced heterogeneity among their cells, their genetic equipment, and their subsequent



characteristics. A carcinoma might develop by clonal expansion from one, genetically fragile cell. Because of this fragility, further mutations or genetic alterations take place, leading to the development of cell clones with features different from the initial clone.<sup>25</sup> Thus, biological characteristics measured in a single sample from a small tumour are more likely to be representative in terms of mirroring the aggressiveness of the tumour than a sample from an extended tumour, where other parts of the tumour containing other clones could have considerably different biological properties.<sup>26</sup>

None of the parameters studied affected survival. Ten of the 23 patients who developed a recurrence succumbed to the disease. Thus, even when the tumours showed their aggressiveness by recurring, many patients could still be cured. However, the numbers studied were too small for further conclusions concerning the influence of the parameters on survival, especially because there were large differences in the treatment of recurring tumours depending on the site of recurrence, the performance status of the patients, and the local treatment traditions of different hospitals.

Our study indicates that for patients harbouring a stage I tongue carcinoma with a high degree of DNA deviation, generous safe margins should be allowed when local surgical excision is performed to avoid local recurrence. Furthermore, at least in patients with tumours exhibiting p53 overexpression, adjuvant treatment of the neck should be considered.

This work was supported by grants from Cancerfonden (2992-B94-04xBC), Cancerföreningen i Stockholm and the Swedish Society of Medicine. We wish to thank Ms A-B Wikström for valuable technical assistance and Mr B Nilsson, Department of Cancer Epidemiology, Radiumhemmet, Karolinska Hospital, for help with statistical interpretations.

- 1 Biörklund A, Anderson H, Möller T, et al. Carcinoma of the tongue in young adults. *Clin Otolaryngol* 1995;20:186.
- 2 Nathansson A, Ågren K, Biörklund A, et al. Evaluation of some prognostic factors in small squamous cell carcinoma of the mobile tongue: a multicenter study in Sweden. *Head Neck* 1989;11:387-92.
- 3 Odell EW, Piyush J, Sherriff M, et al. The prognostic value of individual histologic grading parameters in small lingual squamous cell carcinomas. The importance of the pattern of invasion. *Cancer* 1994;74:789-94.
- 4 Gomez R, El-Naggar AK, Byers RM, et al. Squamous carcinoma of oral tongue: prognostic significance of flow-cytometric DNA content. *Mod Pathol* 1992;5:141-5.
- 5 Cooke LD, Cooke TG, Forster G, et al. Flow cytometric analysis of DNA content in squamous carcinoma of the tongue: the relationship to host and tumour factors and survival. *Clin Otolaryngol* 1994;19:131-4.
- 6 Saito T, Sato J, Satoh A, et al. Flow cytometric analysis of nuclear DNA content in tongue squamous cell carcinoma: relation to cervical lymph node metastasis. *Int J Oral Maxillofac Surg* 1994;23:28-31.
- 7 Högmo A, Munck-Wikland E, Kuylenstierna R, et al. Nuclear DNA content and p53 immunostaining in oral squamous cell carcinoma—an analysis of a consecutive 10-year material. *Int J Oncol* 1994;5:915-20.
- 8 Zätterström U, Wennerberg J, Ewers SB, et al. Prognostic factors in head and neck cancer: histologic grading, DNA ploidy and nodal status. *Head Neck* 1991;13:477-87.
- 9 Munck-Wikland E, Kuylenstierna R, Lind M, et al. The prognostic value of cytometric DNA analysis in early stage tongue cancer. *Oral Oncol Eur J Cancer* 1992;28B:135-8.
- 10 Field JK, Spandidos DA, Malliri A, et al. Elevated p53 expression correlates with a history of heavy smoking in squamous cell carcinoma of the head and neck. *Br J Cancer* 1991;64:573-7.
- 11 Watling D, Gown A, Coltrera M. Overexpression of p53 in head and neck cancer. *Head Neck* 1992;14:437-44.
- 12 Langdon J, Partridge M. Expression of the tumour suppressor gene p53 in oral cancer. *Br J Oral Maxillofac Surg* 1992;30:214-20.
- 13 Shin D, Lee JS, Lippman S, et al. p53 expression: predicting recurrence and secondary primary tumours in head and neck squamous cell carcinoma. *J Natl Cancer Inst* 1996;88:519-29.
- 14 Bischoff JR, Kirn DH, Williams A, et al. An adenovirus mutant that replicates selectively in p53-deficient human tumour cells. *Science* 1996;274:373-6.
- 15 Auer G, Askensten U, Ahrens O. Cytophotometry. *Hum Pathol* 1989;20:518-27.
- 16 Munck-Wikland E, Rubio CA, Auer G, et al. Control cells for image cytometric DNA analysis of esophageal tissue and the influence of preoperative treatment. *Anal Quant Cytol Histol* 1990;12:267-74.
- 17 Broders A. The microscopic grading of cancer. *Surg Clin North Am* 1941;21:947-62.
- 18 Slaughter DP, Southwick HW, Smejkal W. "Field cancerization" in oral stratified squamous epithelium. *Cancer* 1953;6:963-8.
- 19 Munck-Wikland E, Blegen H, Lewensohn-Fuchs I, et al. p53 overexpression in normal and dysplastic tissues adjacent to p53 negative squamous cell carcinomas of the head and neck. *Int J Oncol* 1997;11:97-104.
- 20 Xu L, Chen Y-T, Huvos A, et al. Overexpression of p53 protein in squamous cell carcinomas of the head and neck without apparent gene mutations. *Diagn Mol Pathol* 1994;3:83-92.
- 21 Nylander K, Nilsson P, Mehle C, et al. p53 mutations, protein expression and cell proliferation in squamous cell carcinomas of the head and neck. *Br J Cancer* 1995;71:826-30.
- 22 Gluckman JL, Stambrook PJ, Pavelic ZP. Prognostic significance of p53 protein accumulation in early stage T1 oral cavity cancer. *Oral Oncol Eur J Cancer* 1994;30B:281.
- 23 Leedy DA, Trune DR, Kronz JD, et al. Tumour angiogenesis, the p53 antigen, and cervical metastasis in squamous cell carcinoma of the tongue. *Otolaryngol Head Neck Surg* 1994;111:417-22.
- 24 Lindberg R. Distribution of cervical lymph node metastases from squamous cell carcinoma of the upper respiratory and digestive tracts. *Cancer* 1972;29:1446-9.
- 25 Nowell PC. The clonal evolution of tumour cell populations. *Science* 1976;194:23-8.
- 26 El-Naggar AK, Lopez-Varela V, Luna MA, et al. Intratumoural DNA content heterogeneity in laryngeal squamous cell carcinoma. *Arch Otolaryngol Head Neck Surg* 1992;118:169-73.