

# Surgical treatment in familial adenomatous polyposis

Vera N. Tudyka, Susan K. Clark

St. Mark's Hospital, Harrow, UK

## Abstract

Familial adenomatous polyposis (FAP) is a dominantly inherited condition caused by germline mutation of the *APC* gene resulting in formation of numerous large bowel adenomas in late childhood or adolescence. Unless these are removed, colorectal cancer inevitably develops. Prophylactic surgical treatment is required to prevent this. In surgical decision making, considerations should include genotype-phenotype correlation, perioperative morbidity and risk of impaired sexual and reproductive function in young patients after major pelvic surgery. Colectomy with ileorectal anastomosis remains an appropriate prophylactic procedure in many patients. However, in those with high-density polyposis or a genotype predictive of aggressive disease, restorative proctocolectomy is preferable. There is a range of other features, as FAP is essentially a systemic disease. These include duodenal and peri-ampullary adenomas and carcinoma, desmoid tumors, papillary-type thyroid carcinoma and pancreatic carcinoma among others. With improved management that reduces the risk of colorectal cancer, these extracolonic manifestations have become of increasing clinical significance. For all FAP patients, including those undergoing proctocolectomy, thorough surveillance is of vital importance as there remains a risk of developing neoplasia. Despite advances in surgical techniques, screening and surveillance, life expectancy in patients with FAP is still less than that of the general population.

**Keywords** familial adenomatous polyposis, colorectal cancer, ileorectal anastomosis, restorative proctocolectomy, ileoanal pouch

*Ann Gastroenterol* 2012; 25 (3): 201-206

## Introduction

Familial adenomatous polyposis (FAP) is a dominantly inherited condition resulting in formation of numerous large bowel adenomas in late childhood or adolescence. Unless these are removed, colorectal cancer inevitably develops [1,2]. FAP was originally clinically defined by the presence of 100 or more adenomas in the large bowel of an affected individual, or by any number of adenomas in someone at risk of inheriting the condition [3]. Subsequently, identification of a mutation in the *APC* gene in up to 85% of those with FAP has provided a clear genetic definition of the condition, as well as allowing a firm diagnosis and predictive genetic testing in families.

Study of families with a similar phenotype but no apparent *APC* mutation has resulted in identification of mutation in the *MYH* gene in some of these, leading to characterization of a distinct condition, MYH-associated polyposis (MAP), which is recessively inherited [4].

The Polyposis Registry, St. Mark's Hospital, Harrow, UK

Correspondence to: Miss Susan Clark, The Polyposis Registry, St Mark's Hospital, Harrow HA1 3UJ, UK, Tel: +44 20 8235 4270, Fax: +44 20 8235 4278, e-mail: s.clark8@nhs.net

Conflict of Interest: None

Received 27 March 2012; accepted 11 April 2012

## Diagnosis of FAP

Most patients with FAP are diagnosed through family screening, because one or other of their parents has the condition. In the majority, genetic testing is now available and is generally done around the age of 12 to 14 years. In those families where a causative mutation has not been identified, endoscopic surveillance should start at around this age [5]. Screening for FAP at a younger age is not recommended, for ethical reasons. As intervention is rarely required before the mid to late teens, it is not considered appropriate to test children long before this, when a delay would not affect their management and would allow them to be involved in counseling and decision making.

Generally, adenomas develop in late childhood and increase in size and number during adolescence. While high-grade dysplasia or carcinoma can occur at a very young age this is really the exception rather than the rule, and the average age of colorectal cancer development is around age 40-50 years [6]. However, any at risk child who develops symptoms of rectal bleeding, anemia or persistent diarrhea should be tested at presentation, whatever their age. Approximately 20% of cases of FAP are due to a new mutation (which can then be passed on to the next generation in the usual way) [7]. These individuals generally do not present until they are symptomatic with either advanced adenomatous polyposis or colorectal cancer. They therefore tend to be considerably older.

## Features of the disease

The cardinal feature of FAP is formation of hundreds to thousands of colorectal adenomas in late childhood and adolescence. In the vast majority these will develop into carcinoma by mid adulthood. There is a range of other features, as FAP is essentially a systemic disease. These include duodenal and peri-ampullary adenomas and carcinoma, benign cystic gland polyps of the stomach, congenital hypertrophy of the retinal pigment epithelium, desmoid tumors, osteomas, epidermoid cysts, supernumerary teeth, papillary-type thyroid carcinoma, pancreatic carcinoma, hepatoblastoma, medulloblastoma and, rarely, small bowel carcinoma.

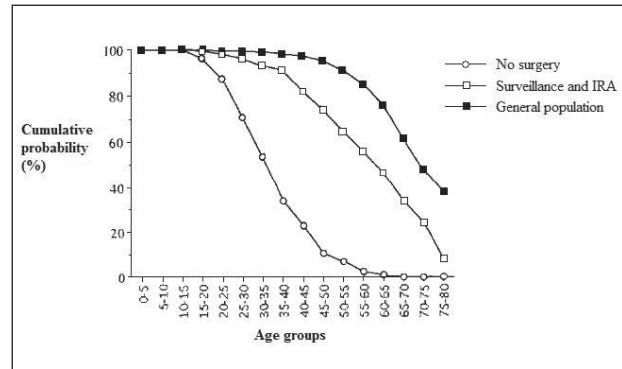
## Genotype-phenotype correlation

It has been established that there is a link between the site of mutation of the *APC* gene and some features of the phenotype of FAP. This is a so-called 'genotype-phenotype correlation'. Of particular relevance with regard to surgical management is the observation that mutations at the far 3' and 5' ends of the gene result in a milder colorectal phenotype whereas those between codons 1251 and 1309 result in a much heavier polyp burden and occurrence of colorectal cancer at a younger age [8,9]. Patients with mutation 3' of codon 1400 are at significantly increased risk of intra-abdominal desmoid, which is an important cause of morbidity and mortality in FAP [10].

The mainstay of management of this condition is surgical removal of the large bowel as, except in very rare cases of attenuated FAP, it is still not possible to manage the large number of adenomas endoscopically. This approach makes a dramatic difference to life expectancy (Fig. 1). This, however, still does not reach that of the general population, due mainly to the problems of duodenal and periampullary carcinoma, desmoid disease, perioperative mortality and rare cases of colorectal cancer. This emphasizes the importance of tailored screening, treatment and surveillance.

## Historical background to surgical decision making

The advent of safe anesthesia, antibiotics and large bowel anastomotic techniques ushered a new era of safe prophylactic surgery in the late 1940's. Prior to this, surgery was of such high risk that it was really only undertaken when carcinoma had developed and usually took the form of segmental colectomy [11]. From the late 1940's until the late 1970's the only surgical options available were total proctocolectomy (TPC) or colectomy with ileorectal anastomosis (IRA). In 1978 the restorative proctocolectomy (RPC) was described, and became extensively used in FAP prophylaxis [12].



**Figure 1** Comparing the effect of screening and surgery, with non-screened familial adenomatous polyposis and the general population. From: *Dis Colon Rectum* 1993 Nov;36(11):1059-62 by Nugent KP, Spigelman AD, Phillips RKS. (Figure 3. Comparing the effect of screening and surgery, with nonscreened familial adenomatous polyposis and the general population.) With kind permission from Springer Science+Business Media.

## Timing of surgery

Key considerations in the management of a patient with FAP are the timing and type of surgery to be performed. The rationale is to remove the colon or colon and rectum to substantially reduce the risk of colorectal cancer. Thus the aim is to undertake surgery before cancer develops.

Predictive genetic testing or screening large bowel endoscopy is first performed around the age of 12-14 in asymptomatic, at risk individuals. The aim is to avoid exposing children to the trauma of investigation or diagnosis of an inherited condition at a young age when such a diagnosis would not alter clinical management and yet to make a diagnosis early enough that they are not exposed to the risk of developing cancer. The vast majority are asymptomatic at this age and once the diagnosis has been confirmed annual colonoscopy is undertaken to assess and monitor polyp burden.

Historically, surgery was undertaken in the late teens or early twenties but has been done at a younger age more recently. The reason for this is probably a combination of increased maturity of adolescents, the increased safety of surgery and the availability of the laparoscopic approach [13]. Occasionally, children do become symptomatic if they have a severe phenotype. The presence of persistent symptoms, severe dysplasia or carpeting polyposis mandates surgery whatever the age. It is, however, unusual to have to perform surgery until the age of 14 or so [14].

In the vast majority the age at which surgery is done is dictated by a combination of social and educational factors, the aim being to impact as little as possible on the individual's personal development. Generally this involves performing surgery somewhere between the ages of 16 and 20 years, often during a long summer vacation to minimize interference with educational or work activities. In patients presenting older with symptoms or with cancer, surgery usually has to be undertaken without delay as soon as full staging investigations and any

appropriate neo-adjuvant therapy have been undertaken.

Some patients with MYH-associated polyposis (MAP) or attenuated forms of FAP may not require prophylactic surgery until much later in life and some may remain endoscopically manageable. They should undergo thorough colonoscopy annually with removal of polyps as required. Some may be manageable in this way indefinitely but many eventually develop a polyp burden that mandates surgery.

A number of chemotherapeutic agents have undergone trials including sulindac [15], celecoxib [16] and fish oil [17]. None of these however have shown a big enough effect to modify management. However, they can be helpful in some circumstances where surgery is either impossible because of desmoid disease or co-morbidity or where there is a clear need to try to delay surgery [10].

## Surgical options

The surgical options in FAP are listed in Table 1.

### Total proctocolectomy

This procedure results in total removal of all large bowel mucosa and thus is completely protective against colorectal cancer. However it inevitably involves a permanent end ileostomy which makes it unsuitable as a prophylactic procedure. It is still required in cases where the presentation with a low rectal cancer necessitates an abdominoperineal excision of the rectum, and in occasional circumstances in which ongoing surveillance is impossible.

### Colectomy with IRA

This was the first procedure employed in the prophylactic setting in FAP. The advantages are highlighted Table 2. The procedure is reasonably straightforward and can be readily performed laparoscopically [18,19]. It only rarely necessitates an ileostomy and does not expose the patient to the complications of pelvic dissection [20]. The major drawback is that adenomas and carcinomas can develop in the retained rectum and careful follow up on a six monthly to annual basis is required. It is clear that rectal cancer risk rises sharply around the age of 50 [21,22], however thorough the surveillance is. Some patients

**Table 1** Surgical options in FAP

Total proctocolectomy with permanent ileostomy (TPC)
Colectomy with ileorectal anastomosis (IRA)
Restorative proctocolectomy with formation of ileoanal pouch (RPC)

FAP, familial adenomatous polyposis; TPC, total proctocolectomy; RPC, restorative proctocolectomy

(usually in their 40's or 50's) go on to require further surgery in the form of completion proctectomy either with permanent ileostomy or formation of ileoanal pouch.

### RPC

This procedure was described in the late 1970s [12]. It has the advantage of removing virtually all of the large bowel at the expense of a pelvic dissection with risks to erectile and ejaculatory function in the male, and fertility in the female [20,23]. Any male undergoing proctectomy should be informed that there is a 1-2% risk of erectile or ejaculatory dysfunction. There is good evidence that in women, fertility is approximately halved [24], something which is not seen after IRA. Usually a temporary covering loop ileostomy is required and pouch failure resulting in a permanent ileostomy occurs in about 10% at 10 years [25].

There has been considerable debate about the technique employed with particular regard to whether the pouch anal anastomosis should be stapled or hand sewn following a mucosectomy [25]. A mucosectomy involves removing the mucosal lining of the anorectal transition zone immediately proximal to the dentate line, and of the short cuff of distal rectum between this and the level of rectal transection. There has been concern about a possible enhanced risk of formation of adenomas at the anorectal cuff following a stapled anastomosis [24]. However, it appears this risk is not abolished by mucosectomy. Indeed most of the published cases of cancer in this region have occurred in patients who had a mucosectomy, presumably as a result of buried islands of mucosa.

Mucosectomy is clearly not totally protective, and, together with handsewn anastomosis, is challenging to perform. Whichever anastomotic technique is employed, careful surveillance of the anorectal transition zone is required and transanal polypectomy may be needed to remove polyps arising in this area.

It has now been observed that adenomas and even carcinomas can arise in the body of the ileoanal pouch itself [26] and may necessitate removal of the pouch. Thus, ongoing surveillance is required, usually on an annual basis by flexible pouchoscopy.

### Secondary proctectomy

Some patients undergoing IRA eventually develop rectal polyposis that is not manageable endoscopically and require secondary proctectomy, either in the form of completion proctectomy and end ileostomy or RPC. There are very rare cases where this proves impossible because of the presence of desmoid tumor [27] but this is extremely unusual.

## Which operation?

Some centres advocate RPC for prophylaxis in all cases of FAP. The risk of developing cancer in the retained rectum are

**Table 2** Advantages and disadvantages of IRA versus RPC

	IRA	RPC
Operative and perioperative	Abdominal surgery only More straightforward to perform laparoscopically [18] Lower perioperative morbidity	Complex pelvic surgery Difficult to perform laparoscopically Higher perioperative morbidity [19]
Bowel function [20]	Ileostomy not required Defecatory frequency about 3 times per day Incontinence rare	Temporary ileostomy usually required Defecatory frequency about 5 times per day, once at night Impaired continence common Pouch failure can lead to permanent ileostomy (10%) [25]
Sexual and reproductive function [23,24]	No effect on female fertility No risk to erectile or ejaculatory function	Female fecundity reduced by 50% 1-2% risk of erectile or ejaculatory dysfunction
Follow-up and future risk	More intensive surveillance Rectal carcinoma risk rises with age [21] Secondary completion proctectomy sometimes required, ileoanal pouch possible	Less intensive surveillance Pouch body and anal transition zone adenomas common, and carcinomas reported [26] Further surgery complex

IRA, ileorectal anastomosis; RPC, restorative proctocolectomy

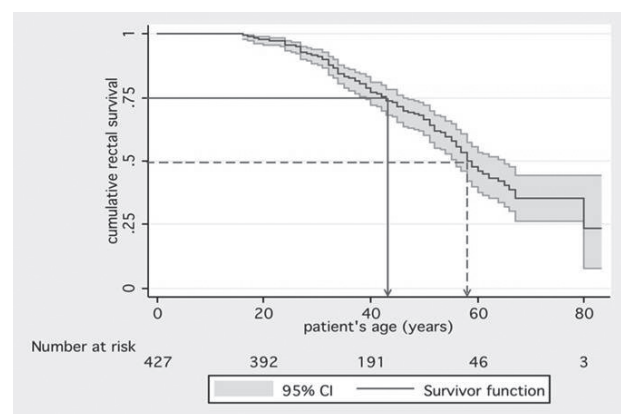
considered by some to be unacceptably high [28,29]. However these outcomes occurred in what is known as the 'pre-pouch era' when the only surgical options were TPC or IRA. In order to avoid permanent ileostomy, the vast majority of patients underwent IRA whatever their colonic or rectal polyp burden, and ongoing surveillance during this time could only be done using rigid sigmoidoscopy. Control of developing rectal polyps was limited to crude fulguration and there was resistance to secondary proctectomy as this would necessitate formation of a permanent end ileostomy [30].

Development of the RPC coincided with advances in flexible endoscopy and polypectomy techniques. In centres advocating more selective, individualized treatment, patients with a heavy colonic or rectal polyp burden undergo RPC while those with a milder phenotype undergo IRA and are then followed up with flexible endoscopy. This results in a better outcome [31]. Indeed, even in a study looking at 'all comers', including the pre and post-pouch eras, over 50% of patients undergoing IRA retained a healthy rectum at age 60 years (Fig. 2) [32].

### A selective approach

In those centers using a selective approach to surgery, colonic and rectal polyp burden together with mutation site have been used to select those with severe disease (more than 500-1000 colonic polyps, more than 20 rectal polyps, mutation

predicting severe disease) who should be advised to undergo RPC [31,32]. Patients who do not have these features of severe disease can be considered for IRA. The presence of colonic cancer does not increase the risk of future rectal neoplasia after IRA, provided the rectal polyp burden is low [32]. Evidence shows this approach decreases the risk of developing rectal carcinoma or the need of completion proctectomy after IRA in low risk patients considerably, compared with use of IRA in all patients [31,33].



**Figure 2** Kaplan-Meier plot showing survival of a healthy rectum (not requiring removal because of the absence of cancer or high adenoma burden) plotted against patient age following ileorectal anastomosis (data from St Mark's Hospital 1948-2007, previously unpublished)

The rationale behind the selective approach is that it avoids the risks to sexual and reproductive function, the need for a temporary ileostomy, and exposure to poorer bowel function in what are essentially healthy teenagers. The proportion requiring secondary proctectomy is minimized, while those who have to undergo secondary proctectomy will have completed their reproductive life and might accept the risks to sexual and bowel function more easily than healthy adolescents. There have been a number of studies comparing outcomes after IRA and RPC, with particular reference to bowel function and quality of life [20,34-37]. These studies have found little difference between IRA and RPC in terms of quality of life.

### Desmoids and surgery

The potential development of desmoid tumors can complicate the issues surrounding abdominal surgery. The vast majority of desmoids develop following prophylactic surgery, although some patients do present with pre-operative desmoid which may even make colectomy impossible.

Risk factors for desmoid tumor include family history of the disease and a mutation 3' of codon 1400 of the APC gene [38,39]. Surgical trauma is also thought to play a part in the initiation of desmoid disease [40]. There is some evidence that a delay in surgery may reduce the risk of desmoid formation [41] and also that laparoscopically assisted RPC may increase the risk [42]. Therefore in patients with a strong family history of desmoid or a 'desmoid prone mutation' there is an argument for delaying surgery and avoiding a laparoscopically-assisted RPC. Some argue that the possibility of future desmoid rendering secondary proctectomy impossible make initial RPC mandatory in those at high risk of this manifestation of FAP. This scenario is, however, extremely unusual, and those with desmoid associated with a far 3' mutation usually have an attenuated colonic phenotype, with scanty, late onset polyps.

### Family support

Adolescents coming to prophylactic surgery often require

**Table 3** High-risk features leading to RPC recommendation [32]

APC mutation codon 1251-1309
More than 500 colonic adenomas
More than 20 rectal adenomas
Rectal cancer
Rectal adenoma too large for endoscopic removal
Poor access to follow-up

RPC, restorative proctocolectomy

a great deal of emotional and psychological support. These are young people undergoing major surgery at a crucial time in their lives when they are well and usually asymptomatic. Those diagnosed later are faced not only with their own illness, but with the knowledge that they have a hereditary condition which may affect other family members, in particular their children. Many find this an enormous psychological burden and benefit greatly from help from dedicated genetic counsellors or polyposis nurses. Increasingly support groups are available through polyposis registries and online ([www.polyposisregistry.org.uk](http://www.polyposisregistry.org.uk)).

### Follow-up following surgery

It is important that once prophylactic surgery has taken place, patients are not lost to follow-up. They remain at risk of duodenal and peri-ampullary adenomatosis as they age and should undergo duodenal screening using esophagogastroduodenoscopy from age 25, with intervals dictated by Spigelman stage [5]. Those who have had IRA should undergo six monthly or annual flexible sigmoidoscopy with removal of polyps over 5 mm or so in size. Carpeting rectal polyposis or the presence of high grade dysplasia should trigger serious consideration of secondary proctectomy. Those who have undergone RPC should have annual pouchoscopy with careful examination of the anorectal cuff and also of the pouch body for adenomas which may need to be removed.

Finally, it is very important to ensure that as these patients have their own families, their at risk children are invited for screening as they reach an appropriate age.

### References

1. Bussey HJ. Historical developments in familial polyposis coli. *Semin Surg Oncol* 1987;3:67-70.
2. Cruz-Correa M, Giardiello FM. Familial adenomatous polyposis. *Gastrointest Endosc* 2003;58:885-894.
3. Phillips RKS, Clark SK. Polyposis syndromes. In: The ASCRS textbook of colon and rectal surgery. Springer-Verlag: New York; 2007, pp. 373-384.
4. Al-Tassan N, Chmiel NH, Maynard J, et al. Inherited variants of MYH associated with somatic G:CRT:A mutations in colorectal tumors. *Nat Genet* 2002;30:227-232.
5. Vasen HF, Möslein G, Alonso A, et al. Guidelines for the clinical management of familial adenomatous polyposis (FAP). *Gut* 2008;57:704-713.
6. Bisgaard ML, Fenger K, Bülow S, Niebuhr E, Mohr J. Familial adenomatous polyposis (FAP): frequency, penetrance, and mutation rate. *Hum Mutat* 1994;3:121-125.
7. Aretz S, Uhlhaas S, Caspari R, et al. Frequency and parental origin of de novo APC mutations in familial adenomatous polyposis. *Eur J Hum Genet* 2004;12:52-58.
8. Soravia C, Berk T, Madlensky L, et al. Genotype-phenotype correlations in attenuated adenomatous polyposis coli. *Am J Hum Genet* 1998;62:1290-1301.

9. Nieuwenhuis MH, Vasen HF. Correlations between mutation site in APC and phenotype of familial adenomatous polyposis (FAP): a review of the literature. *Crit Rev Oncol Hematol* 2007;**61**:153-161.
10. Sturt NJ, Clark SK. Current ideas in desmoid tumours. *Fam Cancer* 2006;**5**:275-285.
11. Bülow S, Berk T, Neale K. The history of familial adenomatous polyposis. *Fam Cancer* 2006;**5**:213-220.
12. Parks AG, Nicholls RJ. Proctocolectomy without ileostomy for ulcerative colitis. *BMJ* 1978;**2**:85-88.
13. Bhandari S, Mallappa S, Neale KF, Phillips RKS, Clark SK. Management of children with familial adenomatous polyposis in the present era: what are we doing differently? *Colorectal Dis* 2011;**13**(Suppl 5):48.
14. Will OC, Phillips RK, Hyer W, Clark SK. Symptomatic polyposis in a 4-year-old: the exception proves the rule. *J Paediatr Child Health* 2009;**45**:320-321.
15. Nugent KP, Farmer KC, Spigelman AD, et al. Randomized controlled trial of the effect of sulindac on duodenal and rectal polyposis and cell proliferation in patients with familial adenomatous polyposis. *Br J Surg* 1993;**80**:1618-1619.
16. Phillips RKS, Wallace MH, Lynch PM, et al. A randomised, double blind, placebo controlled study of celecoxib, a selective cyclooxygenase 2 inhibitor, on duodenal polyposis in familial adenomatous polyposis. *Gut* 2002;**50**:857-860.
17. West NJ, Clark SK, Phillips RK. Eicosapentaenoic acid reduces rectal polyp number and size in familial adenomatous polyposis. *Gut* 2010;**59**:918-925.
18. McNicol F, Kennedy R, Phillips R, Clark S. Laparoscopic total colectomy and ileorectal anastomosis (IRA), supported by an enhanced recovery programme in cases of familial adenomatous polyposis. *Colorectal Dis* 2012;**14**:458-462.
19. Björk J, Akerbrant H, Iselius L, et al. Outcome of primary and secondary ileal pouch-anal anastomosis and ileorectal anastomosis in patients with familial adenomatous polyposis. *Dis Colon Rectum* 2001;**44**:984-992.
20. Aziz O, Athanasiou T, Fazio VW, et al. Meta-analysis of observational studies of ileorectal versus ileal pouch-anal anastomosis for familial adenomatous polyposis. *Br J Surg* 2006;**93**:407-417.
21. Nugent KP, Phillips RK. Rectal cancer risk in older patients with familial adenomatous polyposis and an ileorectal anastomosis: a cause for concern. *Br J Surg* 1992;**79**:1204-1206.
22. Nugent KP, Spigelman AD, Phillips RKS. Life expectancy after colectomy and ileorectal anastomosis for familial adenomatous polyposis. *Dis Colon Rectum* 1993;**36**:1059-1062.
23. Cornish JA, Tan E, Teare J, et al. The effect of restorative proctocolectomy on sexual function, urinary function, fertility, pregnancy and delivery - a systematic review. *Dis Colon Rectum* 2007;**50**:1128-1138.
24. Olsen KO, Juul S, Bülow S, et al. Female fecundity before and after operation for familial adenomatous polyposis. *Br J Surg* 2003;**90**:227-231.
25. von Roon AC, Tekkis PP, Clark SK. The impact of technical factors on outcome of restorative proctocolectomy for familial adenomatous polyposis. *Dis Colon Rectum* 2007;**50**:952-961.
26. Church J. Ileoanal pouch neoplasia in familial adenomatous polyposis: an underestimated threat. *Dis Colon Rectum* 2005;**48**:1708-1713.
27. Penna C, Kartheuser A, Parc R, et al. Secondary proctectomy and ileal pouch-anal anastomosis after ileorectal anastomosis for familial adenomatous polyposis. *Br J Surg* 1993;**80**:1621-1623.
28. Nyam DC, Brilliant PT, Dozois RR, Kelly KA, Pemberton JH, Wolff BG. Ileal pouch-anal canal anastomosis for familial adenomatous polyposis: early and late results. *Ann Surg* 1997;**226**:514-521.
29. Kartheuser AH, Parc R, Penna CP, et al. Ileal pouch-anal anastomosis as the first choice operation in patients with familial adenomatous polyposis: a ten-year experience. *Surgery* 1996;**119**:615-623.
30. da Luz Moreira A, Church JM, Burke CA. The evolution of prophylactic colorectal surgery for familial adenomatous polyposis. *Dis Colon Rectum* 2009; **52**:1481-1486.
31. Church J, Burke C, McGannon E, Patean O, Clark B. Risk of rectal cancer in patients after colectomy and ileorectal anastomosis for familial adenomatous polyposis: a function of available surgical options. *Dis Colon Rectum* 2003;**46**: 1175-1181.
32. Sinha A, Tekkis PP, Rashid S, Phillips RK, Clark SK. Risk factors for secondary proctectomy in patients with familial adenomatous polyposis. *Br J Surg* 2010;**97**:1710-1715.
33. Bülow S, Bülow C, Vasen H, Järvinen H, Björk J, Christensen IJ. Colectomy and ileorectal anastomosis is still an option for selected patients with familial adenomatous polyposis. *Dis Colon Rectum* 2008;**51**:1318-1323.
34. van Duijvendijk P, Slors JF, Taat CW, Oosterveld P, Vasen HF. Functional outcome after colectomy and ileorectal anastomosis compared with proctocolectomy and ileal pouch-anal anastomosis in familial adenomatous polyposis. *Ann Surg* 1999;**230**:648-654.
35. Ko CY, Rusin LC, Schoetz DJ Jr, et al. Does better functional result equate with better quality of life? Implications for surgical treatment in familial adenomatous polyposis. *Dis Colon Rectum* 2000;**43**:829-835.
36. Günther K, Braunrieder G, Bittorf BR, Hohenberger W, Matzel KE. Patients with familial adenomatous polyposis experience better bowel function and quality of life after ileorectal anastomosis than after ileoanal pouch. *Colorectal Dis* 2003;**5**:38-44.
37. Hassan I, Chua HK, Wolff BG, et al. Quality of life after ileal pouch-anal anastomosis and ileorectal anastomosis in patients with familial adenomatous polyposis. *Dis Colon Rectum* 2005;**48**:2032-2037.
38. Caspari R, Olschwang S, Friedl W, et al. Familial adenomatous polyposis: desmoid tumours and lack of ophthalmic lesions (CHRPE) associated with APC mutations beyond codon 1444. *Hum Mol Genet* 1995;**4**:337-340.
39. Sturt NJH, Gallagher MC, Bassett P, et al. Evidence for genetic predisposition to desmoid tumours in familial adenomatous polyposis independent of the germline APC mutation. *Gut* 2004;**53**:1832-1836.
40. Clark SK, Phillips RKS. Desmoids in familial adenomatous polyposis. *Br J Surg* 1996;**83**:1494-1504.
41. Durno C, Monga N, Bapat B, et al. Does early colectomy increase desmoid risk in familial adenomatous polyposis? *Clin Gastroenterol Hepatol* 2007;**5**:1190-1194.
42. Vogel JD, Church JM, LaGuardia L. Minimally invasive pouch surgery predisposes to desmoid tumor formation in patients with familial adenomatous polyposis. *Dis Colon Rectum* 2005;**48**:662-663.