

# Curcumin attenuates neurotoxicity induced by fluoride: An *in vivo* evidence

Chhavi Sharma, Pooja Suhalka, Piyu Sukhwai, Neha Jaiswal, Maheep Bhatnagar

Department of Zoology, University College of Science, M.L. Sukhadia University, Udaipur, India

Submitted: 29-01-2013

Revised: 08-05-2013

Published: 07-02-2014

## ABSTRACT

**Background:** Curcumin (Cur), an active ingredient of turmeric is known to have multiple activities, including an antioxidant property and has been suggested to be useful in treatment of several neurological diseases. **Objective:** To investigate the neuroprotective effects of Cur to mitigate the effect of the Fluoride (F) induced neurotoxicity in mice brain using the histological and the biochemical parameters. **Materials and Methods:** Exposure of mice (30 days old male) to F (120 ppm) daily for 30 days. **Result and Discussion:** Treatment with the F causes an increase in lipid peroxidation (LPO) and also increase in the neurodegenerative cells in the hippocampal sub-regions. Interestingly, co-treatment with Cur (30 mg/kg BW) with F (120 ppm) for 30 days results in significant decreases in LPO with a concomitant decrease in neurodegeneration as compared with those treated with F alone. **Conclusion:** Our study reveals that Cur is useful in ameliorating degenerative effects of F in mice brain.

**Key words:** Curcumin, neurodegeneration, neuroprotection, lipid peroxidation, oxidative stress, fluoride, histology.

## INTRODUCTION

Fluoride (F) is probably the first inorganic ion which drew attention of the scientific world for its toxic effects and now the F toxicity through drinking water is well-recognized as a global problem. Health effect reports on F exposure also include various cancers, adverse reproductive activities, cardiovascular, and neurological diseases.<sup>[1,2]</sup> Major cause of F induced neurological diseases is excitotoxicity causing degeneration of neuron cell bodies in selective brain areas.<sup>[3-5]</sup> The process of neurodegeneration begins at the cellular level in which two main processes, oxidative stress, and excitotoxicity act relentlessly to inflict the majority of cell damage and death. Oxidative Stress can cause cellular damage and subsequent cell death mainly by apoptosis in neurodegeneration because the reactive oxygen species (ROS) oxidize vital cellular components such as lipids, proteins, and deoxyribonucleic acid;<sup>[6-8]</sup> therefore, the imbalance between intracellular ROS and antioxidant defense mechanisms results in oxidative stress that is harmful for neurons. F had obvious influence on phospholipid and fatty acid composition in brain cells of

rats where lipid peroxidation (LPO) due to oxidative stress causes a decrease in total brain phospholipid content.<sup>[9]</sup> Thus, it is not surprising that oxidative stress is a common discussion point for neurodegenerative changes observed in fluorosis patients. Damage to neurons can reflect both an increase in oxidative processes and a decrease in antioxidant defenses. One proposed strategy for the treatment of neurodegenerative disorders that has gained considerable attention is the use of natural antioxidant agents since one common advantage of all these compounds is their human safety.<sup>[7]</sup> Curcumin (Cur) is an ancient Indian herb, which is extracted from the curry powder and has powerful antioxidant and anti-inflammatory properties.<sup>[10]</sup> It reacts with the free radical and can protect cell from singlet oxygen, hydroxyl radical, and superoxide radical damage. The increase in level of glutathione by Cur indicates its antioxidant property possibly by increasing the endogenous defense of the brain to combat oxidative stress.<sup>[11]</sup> Cur's neuroprotective role has recently been demonstrated during neuronal developmental<sup>[12]</sup> and adult hippocampal neurogenesis in fluoride intoxicated mice<sup>[13]</sup> and a biological activity that may enhance neuronal plasticity and repair.<sup>[13]</sup> Here, we investigated the possible protective effects of Cur, a herbal polyphenolic compound, with respect to F induced oxidative stress in hippocampal regions of mice brain.

### Address for correspondence:

Dr. Maheep Bhatnagar, Department of Zoology, University College of Science, M. L. Sukhadia University, Udaipur - 313 001, India.  
E-mail: mbhatnagar@yahoo.com

### Access this article online

#### Website:

www.phcog.com

#### DOI:

10.4103/0973-1296.126663

#### Quick Response Code:



## MATERIALS AND METHODS

### Drug and chemicals

Cur used in this study was purchased from Prolab marketing Ltd. All other chemicals used were purchased from the standard commercial suppliers and were of analytical grade.

### Animals

Adult (one and half months), male, *Swiss Albino mice* weighing 30 g  $\pm$  5 g (BW) were used. Animals were divided into control and three experimental groups (I to III:  $n = 7$ ). All experiments and protocols were approved by Institutional Animal Ethical Committee (IAEC Reg. No. 973/ac/06/CPCSEA). Animals were maintained in the laboratory as per international norms.

### Control group

Group I: Control animals were given mice chow and F-free water ad-libitum for 30 days.

### Experimental groups

Mice were randomly divided into three experimental groups and the dosages were selected on the basis of pilot studies conducted in our laboratory.

The treatments were given for 30 days to all the groups and the dosage are as follows:

Experimental group	Doses	Mode of treatment
II	Fluoride (120 ppm)	Fluoride was given in distilled drinking water ad libitum
III	Fluoride+Cur (120 ppm+ 30 mg/kg BW)	Oral dose of Cur dissolved in olive oil along with fluoride in drinking water
IV	Cur (30 mg/kg BW)	Oral dose of Cur dissolved in olive oil

### Malondialdehyde (MDA) biochemical estimation

MDA content in brain tissue was measured by using the protocol of Buege and Aust,<sup>[14]</sup> 1978. After 30 days, all the mice were weighed and sacrificed by cervical dislocation. The brain, was dissected out and placed on chilled glass plate, dried, and weighed. Brains were cut into two sagittal pieces with the help of surgical blade, and the hippocampus was dissected out under a stereomicroscope. The tissue was minced, and then homogenized in chilled 100 mM pH-7.2 phosphate buffer saline using a Teflon mechanical homogenizer. Samples were then diluted tenfold and the homogenate was spun at 10,000 rpm for 15 min and the supernatant was used for enzymatic assay. To 0.8 ml of supernatant, 1.2 ml of TCA-TBA-HCl (Trichloroacetic acid (TCA): 15% w/v, thiobarbituric acid (TBA) 0.375%, hydrochloric acid (HCl) 0.25 N) reagent was added and kept

in boiling water bath for 10 min. After cooling 2.0 ml of freshly prepared 1 N NaOH was added. The absorbance of pink color obtained was measured at 535 nm against blank, which contained distilled water.

### Calculation

Molar extinction of MDA at 535 nm is  $1.56 \times 10^5$ /M/cm

$$V \times OD_{535}/0.156 = 4 \times OD_{535}/0.156 = 25.6 \times OD_{535} \text{ n moles/ml of homogenate}$$

### Statistical analysis

The data were expressed as Mean  $\pm$  SEM and comparisons of all groups were carried out using the ANOVA (one-way analysis) followed by turkey's post testpost-test. Data were analyzed by the prism software program (Graph pad software Inc.).

### Cresyl violet studies

Mice were anesthetized with ether vapors and perfused transcardially using a perfusion unit. The brains were dissected and overnight post fixation was carried out in 10% formaldehyde. Post fixed brains were washed in 0.01 M Phosphate buffer (pH-7.4), three changes of 30 min each. The brain was then dehydrated in graded series of alcohol i.e., 30%, 50%, 70%, 90% and absolute alcohol. This was followed by clearing in xylene. The brain was then impregnated with 2 changes of 50% paraffin in xylene in an oven set at 59.5°C, followed by two changes in melted paraffin at 59.5°C. The blocks were prepared with the help of Leuckhart's pieces and tissues were oriented to cut coronal sections. Coronal sections were cut serially at 10  $\mu$  thickness with rotary microtome. Sections were deparaffinized in xylene (two changes of 10 min each). The sections were hydrated to water through down a series of alcohol i.e., 100%, 90%, 70%, 50%, and 30%, 5 min in each grade. The sections were stained in Cresyl violet working solution for 2 min quickly washed in DW and air dried for 45 min in a dust free chamber. The sections were dehydrated in n-butanol, cleared in xylene and mounted in Distrenetricresyl phosphate xylene (DPX). The brain of control and all the experimental mice were studied with the help of stereotaxic atlas of mice brain and neuronal counting were carried out.<sup>[15]</sup>

## RESULT

### MDA estimation

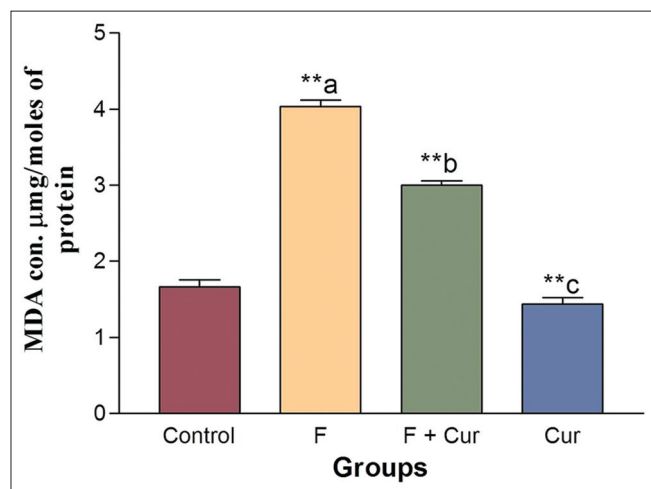
The mean value of MDA content in brain homogenate showed significance (\*\*a,  $P < 0.001$ ) increase in the MDA activity [Figure 1] in group II, and that of group III a significant decrease (\*\*b,  $P < 0.001$ ) was found, when compared to the control. Group IV (\*\*c,  $P < 0.001$ ) shows the MDA concentration near to group I.

### Cresyl violet staining and cell counting

Sections of (Cornu Ammonis area 1)CA1, (Cornu Ammonis area 2) CA3, and (Dentate gyrus) DG region of group I showed optimal sized, pyramidal shaped neuronal cells with a continuous cell membrane [Figure 3]. The cells were closely grouped together to form a band. Group II show extensive degeneration, which appeared to have bursted and lost their shapes, the number of viable cells have been decreased significantly ( $P < 0.05$ ) [Figure 2] whereas, significant ( $P < 0.05$ ) increase in the viable cell number was found in group III animals. The morphological structure and number of cells of group IV were found comparable to group I.

## DISCUSSION

A number of studies and animal experiments indicate that the involvement of free radicals, LPO, and altered antioxidant defense systems are thought to play a key role in the toxic effects of F.<sup>[3]</sup> In our study, we found that MDA content in brain tissue was increased, this could be associated with peroxidation of membrane phospholipids and thus accumulation of MDA. F may cross the blood brain barrier, accumulate in mice hippocampal neuron cell bodies and initiates cascade of reactions which increases the oxidative stress that causes an increase in MDA content of brain tissue, which is an end product of LPO.<sup>[16]</sup> On the other hand, a distinctive decrease in MDA level was observed after Cur treatment, compared to group treated with F.<sup>[17]</sup> This can be correlated with the fact that this phytochemical is capable of quenching oxygen free radicals such as superoxide anions and hydroxyl radicals, which are important for the initiation of LPO.<sup>[18]</sup>

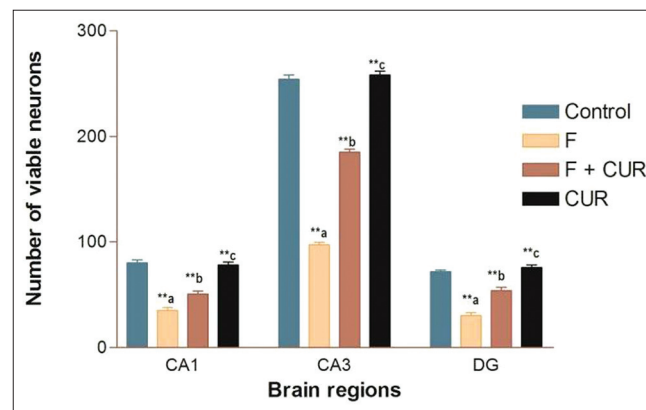


**Figure 1:** Effect of Fluoride (F) and Curcumin (Cur) on Malondialdehyde content of mice Brain. Data represented as mean  $\pm$  SD,  $P < 0.001^{**}$ , no sign = non-significant. On comparing control to Group F (\*\*a) and F + Cur (\*\*b); F to Group F + Cur (\*\*b) and Cur (\*\*c)

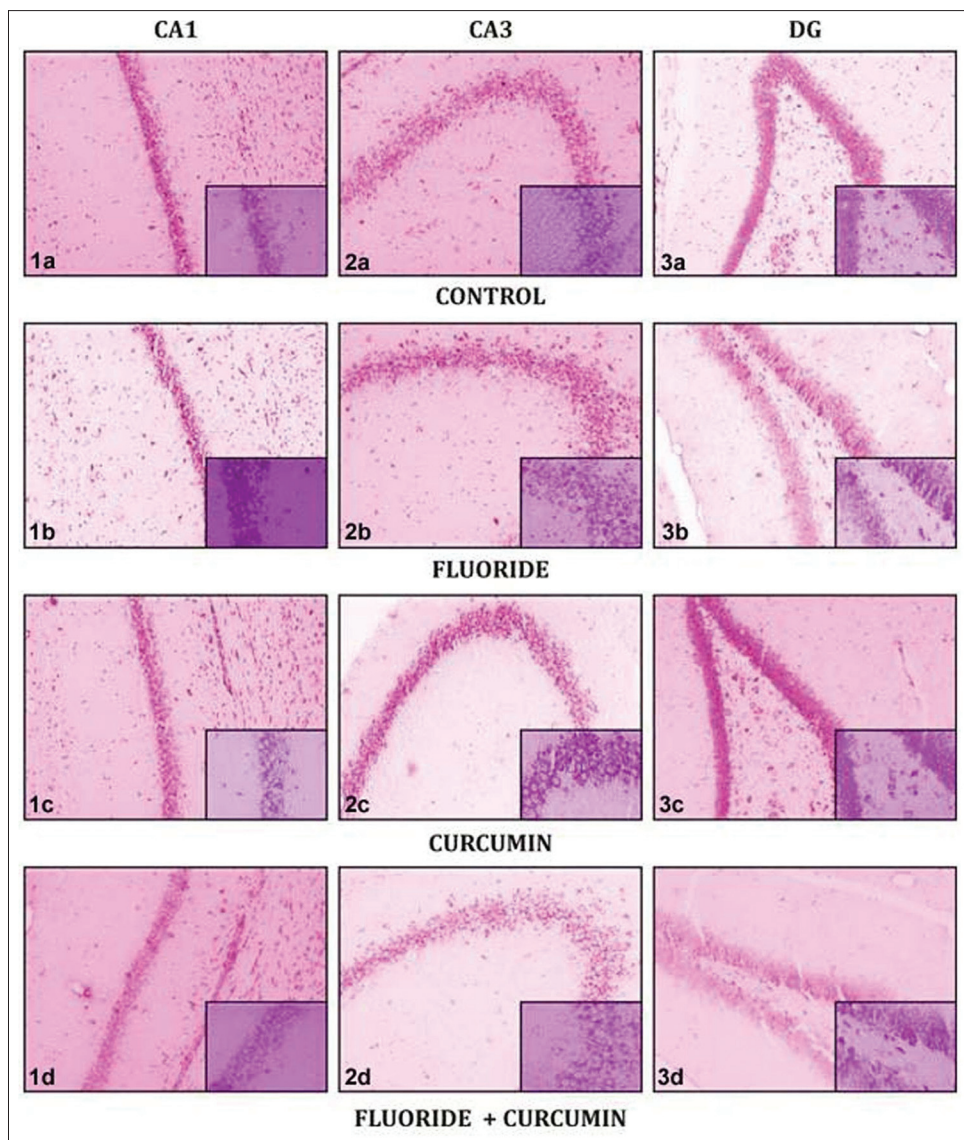
At cytological level, neurodegenerative changes have been reported from our laboratory.<sup>[19]</sup> Although earlier studies on F intoxication and mental disability were observed in fluorosis patients, but these studies were not fully supported with experimental evidences. Recent studies from our laboratory<sup>[20,21]</sup> reported first time that F causes severe neurodegenerative changes in brain particularly in the hippocampus and cerebral cortex. Treatment with F (120 ppm) for 1 month cause significant degeneration in cells of the hippocampus of mice brain.<sup>[22]</sup> These neurodegenerative changes are observed as dark cells, pyknotic cell, 5% cells showed reduced size and few cells showed small or shrunken nucleus in CA1, CA3, and DG region of the hippocampus [Figure 3] and in these regions, various degenerative changes were observed. Even the number of neuronal cells counted in a specific region was less in F group animals as compared to control group [Figure 2]. In group III decrease in neurodegenerative effects were observed. it is evident by presence of fewer dark cells, cells with distorted shape etc., A significant increase in viable neuronal cell count was found when the results were compared with the group II.<sup>[23]</sup> Cresyl violet staining of Cur group clearly showed control pattern of cellular morphology and distribution. Thus Cur protects the neuronal cell bodies in hippocampal area, offering neuroprotection.<sup>[24]</sup> Furthermore, we have first time reported that co-treatment of Cur (30 mg/kg B.W.) along with F (120 ppm) for 30 days, can lower the risk of degeneration caused due to F.

## CONCLUSION

Our study thus demonstrate that daily single dose of 120 ppm F result in highly significant increases in the LPO as well as neurodegenerative changes in neuron cell bodies of selected hippocampal regions. Supplementation with curcumin significantly reduce the toxic effect of F to near normal level



**Figure 2:** Effect of Fluoride (F) and Curcumin (Cur) on Neuronal viability. Data represented as Mean  $\pm$  SE ( $P < 0.05$ )<sup>\*\*</sup>, No sign = No significance. On comparing control to F Group (\*\*a) and F + Cur (\*\*b); F Group to F + Cur (\*\*b) and Cur (\*\*c)



**Figure 3:** Photomicrographs demonstrating (Cornu Ammonis) CA1, CA3 and Dentate gyrus region of Hippocampus showing Cresyl violet staining in Control, 120 ppm fluoride (F), Curcumin (Cur) and F + Cur treated group

by augmenting the antioxidant defense through its scavenging property and provide an evidence of having therapeutic role against oxidative stress mediated neurodegeneration.

## ACKNOWLEDGMENT

The authors are thankful to the University Grants Commission, New Delhi for providing a research grant under the UGC-SAP program. Financial assistance was provided to Prof. Maheep Bhatnagar (Coordinator-SAP) under research thrust area–Neurobiology, Gene, and Genomics.

## REFERENCES

- Bhatnagar M, Rao P, Bhatnagar C, Bhatnagar R. Trace element concentration in various tissues following fluoride administration to female mice. *Indian J Exp Biol* 2003;41:652-4.
- Dhar V, Bhatnagar M. Physiology and toxicity of fluoride. *Indian J Dent Res* 2009; 20:350-5.
- Blaylock RL. Exitotoxicity: A possible central mechanism in fluoride neurotoxicity. *Fluoride* 2004;37:301-14.
- Zhang M, Wang A, Xia T, He P. Effects of fluoride on DNA damage, S-phase cell-cycle arrest and the expression of NF-kappaB in primary cultured rat hippocampal neurons. *Toxicol Lett* 2008;179:1-5.
- Narayanaswamy M, Piler MB. Effect of maternal exposure of fluoride on biometals and oxidative stress parameters in developing CNS of rat. *Biol Trace Elem Res* 2010;133:71-82.
- Bradford F, Gupta S. A review of antioxidant and Alzheimer's disease. *Ann Clin Psychiatry* 2005;37:269-86.
- Aliev G, Obrenovich ME, Reddy VP, Shenk JC, Moreira PI, Nunomura A, *et al.* Antioxidant therapy in Alzheimer's disease: Theory and practice. *Mini Rev Med Chem* 2008;8:1395-406.
- Hsiung GY, Feldman HH. Pharmacological treatment in

- moderate-to-severe Alzheimer's disease. *Expert Opin Pharmacother* 2008;9:2575-82.
9. Shen X, Zhang Z, Xu X. Influence of combined iodine and fluoride on phospholipid and fatty acid composition in brain cells of rats. *Wei Sheng Yan Jiu* 2004;33:158-61.
  10. Calabrese V, Butterfield DA, Stella AM. Nutritional antioxidants and the heme oxygenase pathway of stress tolerance: Novel targets for neuroprotection in Alzheimer's disease. *Ital J Biochem* 2003;52:177-81.
  11. Ghoneim AI, Abdel-Naim AB, Khalifa AE, El-Denshary ES. Protective effects of curcumin against ischaemia/reperfusion insult in rat forebrain. *Pharmacol Res* 2002;46:273-9.
  12. Basha PM, Madhusudhan N. Pre and post natal exposure of fluoride induced oxidative macromolecular alterations in developing central nervous system of rat and amelioration by antioxidants. *Neurochem Res* 2010;35:1017-28.
  13. Kim SJ, Son TG, Park HR, Park M, Kim MS, Kim HS, *et al.* Curcumin stimulates proliferation of embryonic neural progenitor cells and neurogenesis in the adult hippocampus. *J Biol Chem* 2008;283:14497-505.
  14. Buege JA, Aust SD. Microsomal lipid peroxidation. *Methods Enzymol* 1978;52:302-10.
  15. Franklin KBJ, Paxinos G. The mouse brain in stereotaxic coordinates. 3<sup>rd</sup> ed.: Academic press;2008.
  16. Shivarajashankara YM, Shivashankara AR, Gopalakrishna Bhat P, Hanumanth Roa S. Effect fluoride intoxication on lipid peroxidation and antioxidant systems in rats. *Fluoride* 2001;34:108-13.
  17. Nabavi SF, Eslami Sh, Moghaddam AH, Nabavi SM. Protective effect of curcumin against fluoride induced oxidative stress in rat brain. *Neurophysiology* 2011;43:332-6.
  18. Butterfield D, Castegna A, Pocernich C, Drake J, Scapagnini G, Calabrese V. Nutritional approaches to combat oxidative stress in Alzheimer's disease. *J Nutr Biochem* 2002;13:444.
  19. Bhatnagar M, Rao P, Sushma J, Bhatnagar R. Neurotoxicity of fluoride: Neurodegeneration in hippocampus of female mice. *Indian J Exp Biol* 2002;40:546-54.
  20. Bhatnagar M, Rao P, Saxena A, Bhatnagar R, Meena P, Barbar S. Biochemical changes in brain and other tissues of young adult female mice from fluoride in their drinking water. *Fluoride* 2006;39:280-4.
  21. Bhatnagar M, Sukhwal P, Suhalka P, Jain A, Joshi C, Sharma D. Effects of fluoride in drinking water on NADPH-diaphorase neurons in the forebrain of mice: A possible mechanism of fluoride neurotoxicity. *Fluoride* 2011;44:195-9.
  22. Chirumari K, Reddy PK. Dose-dependent effects of fluoride on neurochemical milieu in the hippocampus and neocortex of rat brain. *Fluoride* 2007;40:101-10.
  23. Madhusudhan N, Basha PM, Rai P, Ahmed F, Prasad GR. Effect of maternal fluoride exposure on developing CNS of rats: Protective role of Aloe vera, Curcuma longa and Ocimum sanctum. *Indian J Exp Biol* 2010;48:830-6.
  24. Sabetkasaei M, Ataie A, Haghparasat A, Moghaddam HA, Ataee R, Moghaddam NS. Curcumin exerts neuroprotective effects against homocystein intracerebroventricular injection induced cognitive impairment and oxidative stress in rat brain. *J Med Food* 2010;13:821-6.

**Cite this article as:** Sharma C, Suhalka P, Sukhwal P, Jaiswal N, Bhatnagar M. Curcumin attenuates neurotoxicity induced by fluoride: An *in vivo* evidence. *Phcog Mag* 2014;10:61-5.

**Source of Support:** Nil, **Conflict of Interest:** None declared.