

# Effectiveness of Mini Implants in Three-Dimensional Control During Retraction - A Clinical Study

DEEPAK VICTOR<sup>1</sup>, RAMCHANDRA PRABHAKAR<sup>2</sup>, M.K. KARTHIKEYAN<sup>3</sup>, R. SARAVANAN<sup>4</sup>, P. VANATHI<sup>5</sup>, N. RAJ VIKRAM<sup>6</sup>, P. ADARSH REDDY<sup>7</sup>, M. SUDEEPTHI<sup>8</sup>

## ABSTRACT

**Introduction:** Three-dimensional control throughout the orthodontic treatment is essential for uncompromised results. Mini screws introduced for orthodontic anchorage has given the clinician an option of absolute three dimensional control. The purpose of this study was to compare and measure the vertical control and torque control of incisors and molar during enmass retraction with titanium microimplants and conventional molar anchorage.

**Material and Methods:** Twenty patients were selected with extraction of all first premolars and bonded with 0.022" slot MBT system. After aligning and leveling, all subjects were placed with 0.019" X 0.025" posted SS wire with standardized torquing curve. The 20 subjects were randomly divided into 2 groups consisting of 10 each (Group A & Group B). Group A subjects, implants were placed and Group B formed the

control group. Retraction was carried out using NiTi closed coil springs. The assessment of the vertical and torque control of incisors and tipping and vertical control of molars was done by radiographic method using lateral cephalogram taken before and after retraction.

**Results:** The torque control of incisors, P11 value in group A and B indicated no significant difference. The molar tip, P12 value in group A indicated that there was distal tipping of molars while the P12 in group B indicated mesial tipping. On vertical plane P21, P22 and P23 values in Group A indicated that there was intrusion of incisors and molars while value in Group B indicated extrusion of incisors and molars.

**Conclusion:** Three dimensional control is better in the implant group compared to the non implant group. Therefore the implant group definitely has cited advantages over conventional method.

**Keywords:** Mini Screw Implant, Vertical control, Torque control, Three-dimensional control

## INTRODUCTION

Predictable three-dimensional control of the teeth during the orthodontic treatment is essential to avoid any adverse effects on the dentition and the adjoining tissues due to the applied orthodontic force. Though the control of the teeth is required from day one of the therapy, it is most critical during retraction. Extra oral forces have probably been the only comfort factor to provide satisfactory control, but it has huge dependency on patient's compliance, which can set back the whole concept of control over the treatment. Other issues being able, to achieve true intrusion and torque control of the anteriors and majorly, the tipping of the molars.

Mini-implants and micro-implants have changed the face of orthodontics today. They have increased the scope of orthodontics and encroached into the surgical zone, that is, what was considered impossible in orthodontics, is quite a possibility now, with the usage of implants. Implants have gained popularity in all the treatment phases, as in retraction, intrusion of anteriors and posteriors and a key role in adult orthodontics. Miniscrews are convenient, save time, and produce good treatment results with no need for patient-cooperation. These implants have always offered sufficient anchorage stability while allowing easy removal without fracturing after treatment [1,2].

The aim of this study is to determine and compare, the Torque of incisors, Tip of molars and Vertical control during the orthodontic treatment, using MBT appliance system (Richard McLaughlin, John Bennett and Hugo Trevisi, in the early 1990s launched MBT Appliance System) with and without mini screw implants.

## MATERIALS AND METHODS

The patient sample was selected from the subjects seeking treatment at the Department of Orthodontics, Meenakshi Ammal

Dental College and Hospital, Meenakshi University, Tamil Nadu, India. Twenty patients requiring all 1<sup>st</sup> premolar extraction for correction of proclination between 14-25 years, both male and females were selected for the study. Patients were specifically instructed to maintain a good oral health till cessation of therapy. Comprehensive medical and dental history of all the patients was taken to rule out any systemic illness. Only those subjects with an average mandibular plane angle were included for the study. It was mandatory that all patients, after initial aligning, had a minimum of 4 mm of space left for retraction.

After the extraction of all first premolars, molars were banded and the remaining teeth were bonded with 0.022" slot MBT appliance system (3M Unitek Gemini Metal Brackets) and 0.016" NiTi (OrthoForm III) wires were placed. The 20 subjects were randomly divided into 2 Groups consisting of 10 each: Group A & Group B. Group A subjects comprised of those where implants were placed and Group B formed the control Group. The implant used in this study was a mini screw (Absoanchor - SH 1312-08) having a diameter of 1.3 mm and a length of 8 mm. Periapical X-rays were taken with guide bar 8 (jig) to standardize the exact position and to determine whether adequate space was available for implant placement [Table/Fig-1]. To obtain 8 mm biting depth without injuring the adjacent structures, the screw insertion was angulated at 40° and 8 mm gingival to the archwire [3]. The occlusogingival position of microscrew implants determines the force direction so that the retraction of the anterior teeth can be controlled.

The microscrew implant was placed 8 mm gingival to the archwire (reference jig, [Table/Fig-1]) for retracting the six anterior teeth. The center of resistance of the six anterior teeth was estimated to be halfway between the center of resistance of the four incisors and canines [4]. By using an upward and backward force passing near

the center of resistance, the maxillary anterior teeth would show bodily intrusion and retraction.

For subjects under Group A, [Table/Fig-2a] the implants were positioned at maximum thickness of infrazygomatic crest 1, between the roots of second premolar and first molar in the upper arch, as soon as, they were upgraded to 0.019 x 0.025 posted SS wire. Retraction was planned after 4 weeks of implant placement and done using NiTi closed coil spring (3M Unitek Medium, 9 mm), stretched between the implant and the post of the 0.019 x 0.025 SS wire in Group A.

For retraction in Group B, [Table/Fig-2b] NiTi closed coil spring was stretched between the molar hook and the post of the 0.019 x 0.025 SS wire. The methods controlling the mode of anterior teeth retraction were the vertical position of the anterior hooks on 0.019 X 0.025 posted SS wire and the amount of torquing curve (reverse curve) given on the archwire. To standardize the amount of torquing curve given on the archwire a plaster template [Table/Fig-1] having a standard design for 0.019 X 0.025 posted SS wire was used. The torquing curve incorporated into the archwire produces an intrusive force and generates a labial crown torque on anterior teeth which helps to enhance the vertical and torque control of the anterior teeth [5].

Dontrix gauge was used to check 150 gms of force which was applied using NiTi closed coil spring for all the patients. All patients were recalled at regular intervals of 4 weeks. At each visit the springs were checked such that a force around 150 gms was maintained, while the arch wire was checked for any damage to prevent any interference with sliding. At the end of space closure, post treatment records were taken which included cephalogram. [Table/Fig-3a,3b].

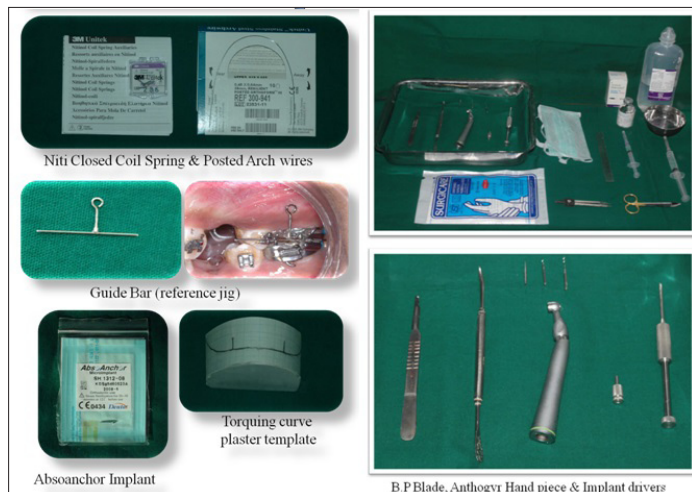The assessment of the torque control and vertical control during retraction was done by radiographic assessment method. Lateral cephalograms were superimposed according to the method of Pancherz [6]. Lateral cephalometric radiographs were taken before (T<sub>1</sub>) and after retraction (T<sub>2</sub>) [Table/Fig-4]. All lateral cephalograms were traced by two different investigators twice and the mean of all the values were taken into consideration. Landmarks and reference planes used for this study are illustrated in [Table/Fig-5].

For the assessment of torque control and vertical control during retraction five variables [6] were taken into consideration. Cephalometric readings of these five variables were taken and tabulated. The variables and their description with illustrations are mentioned in [Table/Fig-6].

Records of each patient were tabulated and the values for all patients were recorded as appended below in [Table/Fig-7].

**RESULTS**

At the end of retraction, the results obtained were recorded, tabulated and statistically analyzed as follows [Table/Fig-8a,b,c].



[Table/Fig-1]: Armamentarium used

Means and standard deviation were estimated from the samples for each Group. Comparison of mean values between Group A and B were estimated. In the present study, p<0.05 was considered as the level of significance. The mean, S.D and value of significance for Group A and B were analyzed under the following headings; P<sub>1</sub> and P<sub>2</sub>.

Student's independent t-test was used to calculate the p-value.

$$\text{Standard Deviation, SD} = \sqrt{\frac{\sum (xi - x)^2}{n-1}}$$

$$\text{Student's paired t-test: } t = \frac{\frac{\bar{d}}{SE(\bar{d})}}{\text{Where } SE(\bar{d}) = \frac{S}{\sqrt{n}}}$$

$$S = \sqrt{\frac{\sum (di - \bar{d})^2}{n-1}}$$

$$\bar{d} = \frac{\sum di}{n}$$

d<sub>i</sub> is the difference of observations of the two Groups. Equation follows a t-distribution with n-1 degrees of freedom. In the present study, the level of significance was considered as p < 0.05.

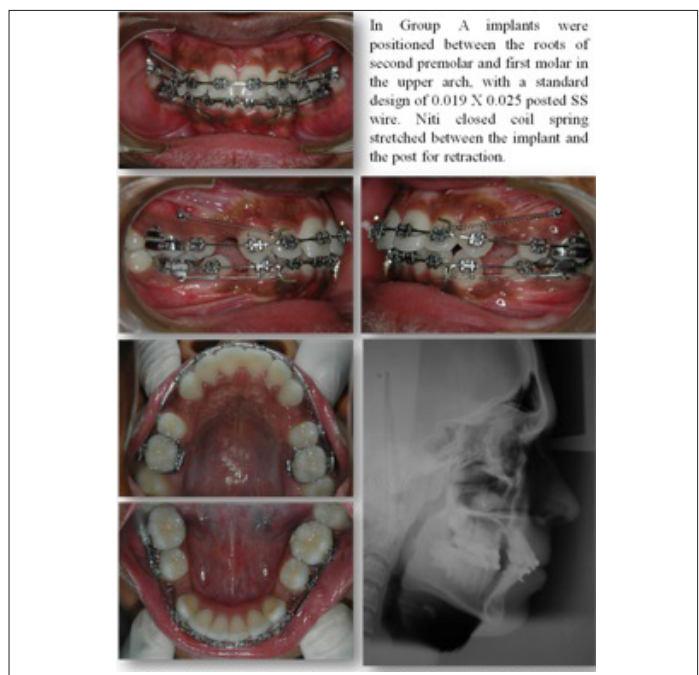
Inference of [Table/Fig-8(a)]:

The mean value for P<sub>1</sub>, pre- (torque control of incisors) for Group A was 123.9 ± 6.0 while the mean value for P<sub>1</sub>, post- for Group A was 118.1 ± 6.1 indicating a mean difference of 5.8 ± 1.3. The mean value for P<sub>1</sub>, pre- for Group B was 125.4 ± 3.0 while the mean value for P<sub>1</sub>, post- for Group B was 119.6 ± 3.2 indicating a mean difference of 5.8 ± 1.3 [Table/Fig-9].

The comparative difference between the mean values (P<sub>1</sub>, change) in Group A & B was 5.8 ± 1.3 & 5.8 ± 1.3 respectively which indicated no significant difference. The p-value, P<sub>1</sub>, change of 1.0 substantiates that there was no significant difference.

Inference of [Table/Fig-8(b)]:

The mean value for P<sub>2</sub>, pre (tip of Molars) for Group A was 85.8 ± 4.2 while the mean value for P<sub>2</sub>, post for Group A was 84.9 ± 4.8 indicating a mean difference of -0.88 ± 1.13. The mean value for P<sub>2</sub>, pre- for Group B was 84.4 ± 3.0 while the mean value for P<sub>2</sub>, post- for Group B was 87.8 ± 2.4 indicating a mean difference of 3.38 ± 0.92 [Table/Fig-10].



[Table/Fig-2a]: Group A- Pre-treatment

The comparative difference between the mean values ( $P1_2$  change) in Group A & B was  $-0.88 \pm 1.13$  &  $3.38 \pm 0.92$  respectively, which indicated a significant difference of  $<0.0001$ . The  $P1_2$  change value in Group A of  $-0.88 \pm 1.13$  indicated that there was a mild distal tipping of molars, while in Group B, a mesial tipping of  $3.38 \pm 0.92$  was noted. The p-value,  $P1_2$  change of  $<0.0001$  substantiates the significant difference.

Inference of [Table/Fig-8(c)]:

The mean value for  $P2_1$  pre- (vertical distance between palatal plane and incisal tip) for Group A was  $30.5 \pm 2.3$  while the mean value for  $P2_1$  post- for Group A was  $28.9 \pm 3.1$  indicating a mean difference of  $1.6 \pm 0.9$ . The mean value for  $P2_1$  pre- for Group B was  $29.7 \pm 1.3$  while the mean value for  $P2_1$  post- for Group B was  $30.9 \pm 1.2$  indicating a mean difference of  $-1.2 \pm 1.1$ .

The comparative difference between the mean values ( $P2_1$  change) in Group A & B was  $1.6 \pm 0.9$  &  $-1.2 \pm 1.1$  respectively, which

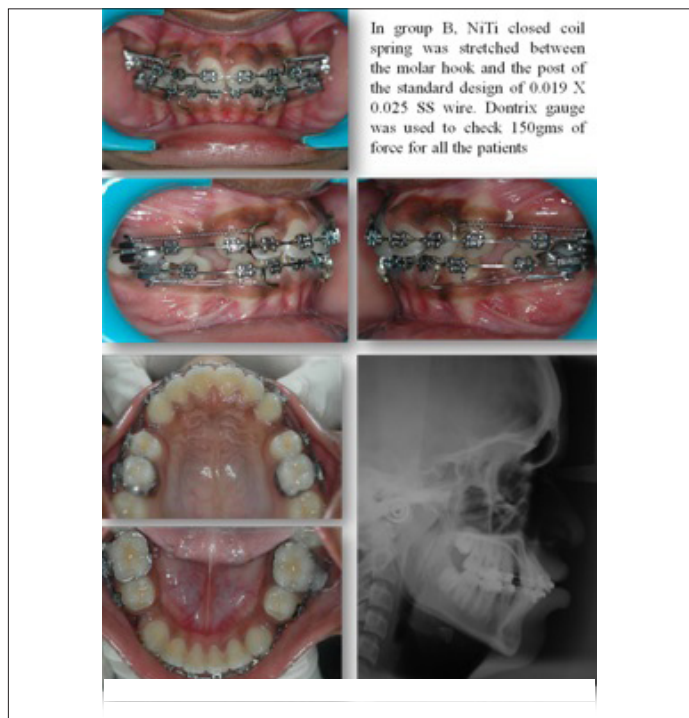indicated a significant difference of  $<0.0001$ . The  $P2_1$  change value in Group A of  $1.6 \pm 0.9$  indicated that there was intrusion of incisors while the Group B  $-1.2 \pm 1.1$  indicated an extrusion of incisors. The p-value,  $P4_1$  change of  $<0.0001$  substantiates the significant difference.

The mean value for  $P2_2$  pre- (vertical distance between palatal plane and apical region of incisor) for Group A was  $7.6 \pm 1.9$  while the mean value for  $P2_2$  post- for Group A was  $6.6 \pm 2.3$  indicating a mean difference of  $1.1 \pm 0.5$ . The mean value for  $P2_2$  pre- for Group B was  $5.6 \pm 0.9$  while the mean value for  $P2_2$  post- for Group B was  $6.9 \pm 0.9$  indicating a mean difference of  $-1.4 \pm 1.2$ .

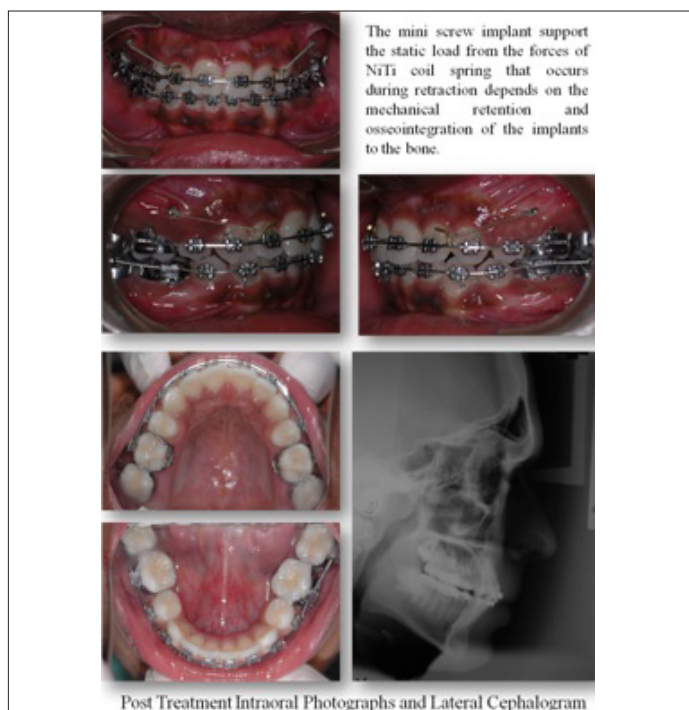
The comparative difference between the mean values ( $P2_2$  change) in Group A & B was  $1.1 \pm 0.5$  &  $-1.4 \pm 1.2$  respectively, which indicated a significant difference of  $<0.0001$ . The  $P2_2$  change value in Group A of  $1.1 \pm 0.5$  indicated that there was intrusion of incisors while the Group B  $-3.38 \pm 0.92$  indicated extrusion of incisors. The p-value,  $P2_2$  change of  $<0.0001$  substantiates the significant difference.

The mean value for  $P2_3$  pre- (vertical distance between palatal plane and mesiobuccal cusp) for Group A was  $25.7 \pm 2.6$  while the mean value for  $P2_3$  post- for Group A was  $25.4 \pm 2.3$  indicating a mean difference of  $0.3 \pm 0.5$ . The mean value for  $P2_3$  pre- for Group B was  $24.8 \pm 1.0$  while the mean value for  $P2_3$  post- for Group B was  $25.5 \pm 1.7$  indicating a mean difference of  $-0.8 \pm 0.9$ .

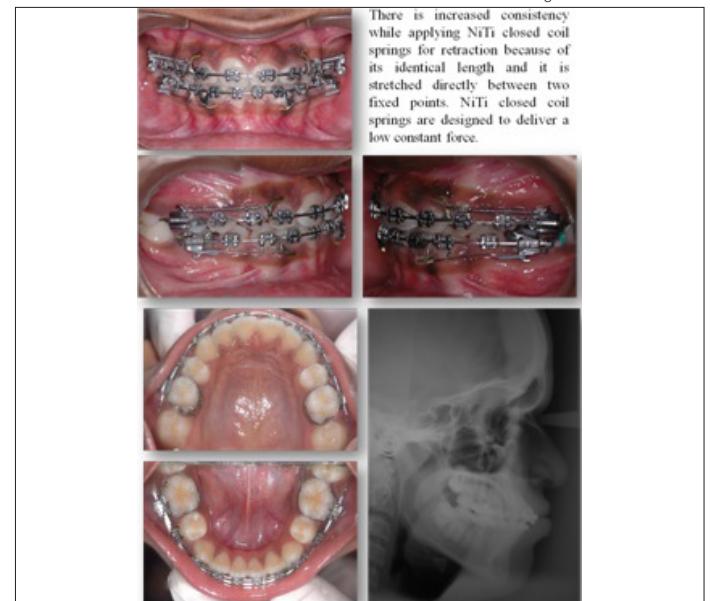The comparative difference between the mean values ( $P2_3$  change) in Group A & B was  $0.3 \pm 0.5$  &  $-0.8 \pm 0.9$  respectively which indicated a significant difference of 0.01. The  $P2_3$  change value



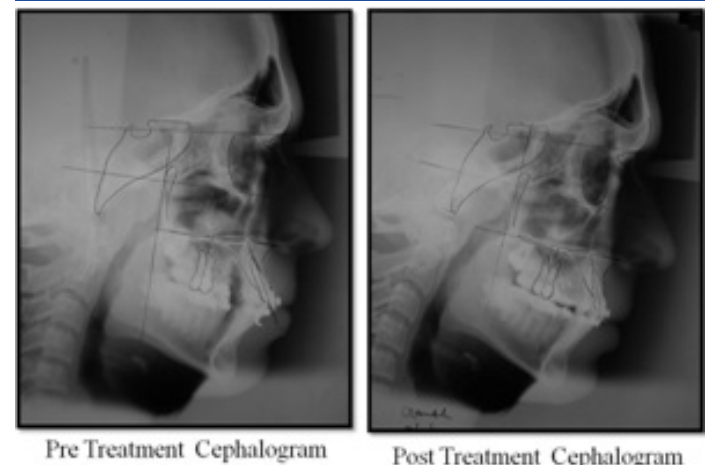
[Table/Fig-2b]: Group B- Pre-treatment



[Table/Fig-3a]: Group A- Post-treatment



[Table/Fig-3b]: Group B- Post-treatment



[Table/Fig-4]: Radiograph assessment

in Group A of  $0.3 \pm 0.5$  indicated that there was only a very mild intrusion of molar, while the Group B  $-0.8 \pm 0.9$  indicated a mild extrusion of molars. The p-value,  $P_{2_3}$  change of 0.01 substantiates the significant difference [Table/Fig-11].

### DISCUSSION

The comparative difference between the mean values for  $P1_1$  change (torque of incisors) for Group A and B was  $5.8 \pm 1.3$  indicating no significant difference, which is contrary to the other studies, which have reported such a change [7,8]. This may be due to the fact that in the earlier studies, loss of torque was significant in the non-implant Group, whilst, it was insignificant in this study. The overall torque control was better due to a full size wire retraction, expression of residual tip and torque before commencement of retraction and proper four-week activation protocol. The mean loss of torque for incisors in this study was found to be 5.80, hence, there was no comparative difference in the mean values obtained for Group A and B in this study.

Landmarks and reference planes	
Nasion	(N)
Sella	(S)
Orbitale	(Or)
Porion	(Po)
Anterior nasal spine	(ANS)
Posterior nasal spine	(PNS)
Pterygoid point	(Pt point)
Upper incisor edge	(U1E)
Upper incisor root apex	(U1A)
Center of Max. 1st molar crown on occlusal surface	(U6C)
Most mesial point of mesial surface of Max. 1st molar crown	(U6M)
Mesiobuccal root apex of Max. 1st molar	(U6A)
Vertical reference plane through Pt point (tangent to palatal plane)	(PTV)

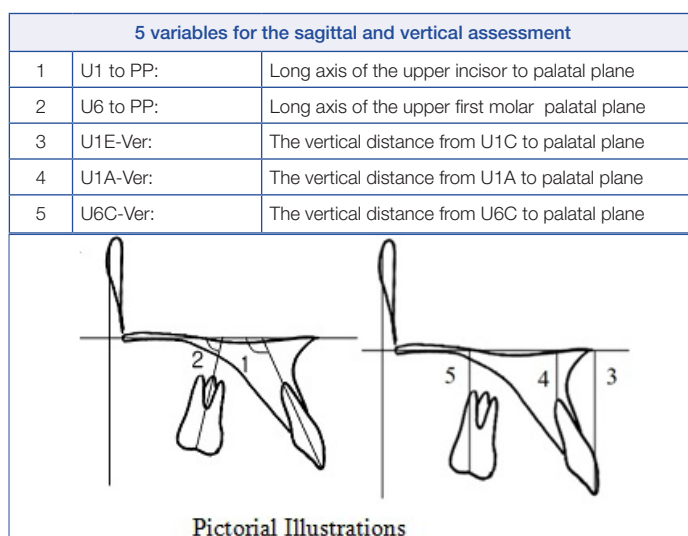
[Table/Fig-5]: Landmarks and reference planes

Subjects	U1-PP		U6-PP		U1E-Ver		U1A-Ver		U6C-Ver	
	Pre-Rx	Post-Rx	Pre-Rx	Post-Rx	Pre-Rx	Post-Rx	Pre-Rx	Post-Rx	Pre-Rx	Post-Rx
<b>Group A</b>										
1	126	111	86	86	31	30	10	9	26	26
2	122	110	81	81	29	27	6	4.5	22	22
3	130	114	92	92	27	29	6.7	6	25	25
4	125	129	89	92	29	27	6.5	5	27.5	26.5
5	130	119	85	81	27	29	4.7	5.5	24.5	24
6	118	110	82	85	34	33	8	7	29.5	28.5
7	114	108	85	84	34	34	11	11	28	28
8	123	111	82	82	29	27	7	5.5	23	23
9	126	111	86	86	31	30	10	9	26	26
10	122	110	81	81	29	27	6	4.5	22	22
<b>Group B</b>										
1	123	117	79	87	31	28	7.8	5	25	23
2	127	110	79	85	28	30	5.5	5.8	24	26
3	125	123	87	90	32.5	30	7.5	7.3	25	27
4	120	128	86	89	32	28.5	5	5	26	24.5
5	118	109	87	88	30	30	6	6	22	22
6	129	129	89	90	38	27	6	7	23	23
7	120	115	84	88	29	29	6	6	25	25
8	122	116	78	86	31	30	7	5	25	24
9	123	117	79	87	31	28	7.8	5	25	23
10	127	110	79	85	28	30	5.5	5.8	24	26

[Table/Fig-7]: Recorded values for all patients

The comparative difference between the mean values  $P1_2$  change (tip of molars) in Group A was  $-0.88 \pm 1.13$  indicated that there was only a mild distal tipping of molars. This is due to the fact that the reactive component of force is directed occlusal to the centre of resistance of the tooth even after space closure and not apically. The comparative difference between the mean values  $P1_2$  in Group B was  $3.38 \pm 0.92$  indicated a mild mesial tipping of molar which could be explained by the fact that the molar tooth is the anchor component and the reactionary forces acting on it would bring about a mesial movement of molars.

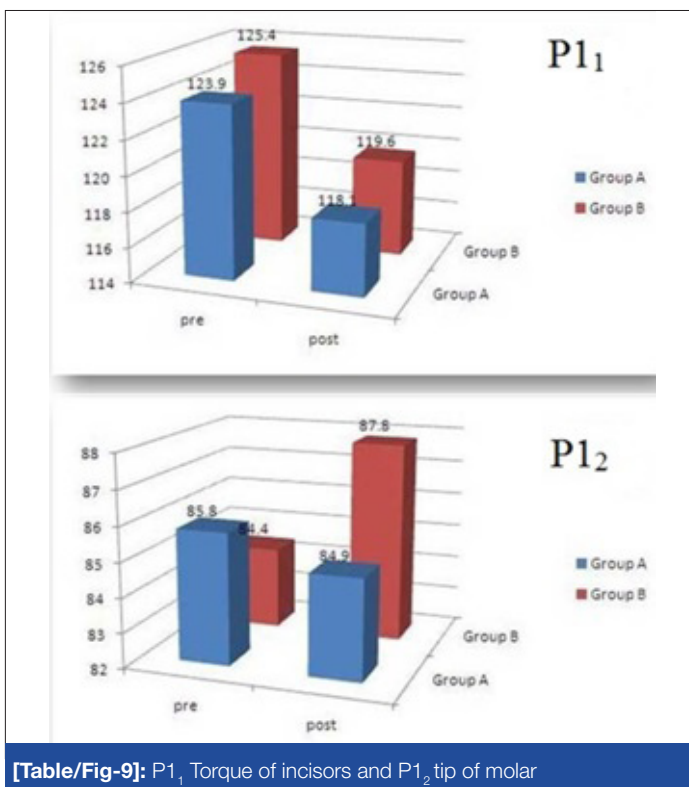
The comparative difference between the mean values of  $P2_1$  and  $P2_2$  change (vertical distance between palatal plane and incisor) in Group A was  $1.6 \pm 0.9$  and  $1.1 \pm 0.5$ . The  $P2_1$  and  $P2_2$  change value in Group A indicated that there was only a mild intrusion of incisors because the point of force application is more apical to the centre of resistance than with conventional mechanics [5,9]. On the contrary,  $P2_1$  and  $P2_2$  change value in Group B which was  $-1.2$



[Table/Fig-6]: 5 variables for the sagittal and vertical assessment with Pictorial Illustrations

Torque of incisors (a)				
Variable	Group A	Group B	p-value*	Significance
	Mean ± S.D	Mean ± S.D		
P1 <sub>1</sub> -pre	123.9 ± 6.0	125.4 ± 3.0	0.54	N.S
P1 <sub>1</sub> -post	118.1 ± 6.1	119.6 ± 3.2	0.55	N.S
P1 <sub>1</sub> - Change	5.8 ± 1.3	5.8 ± 1.3	1.00	N.S
Tip of Molars (b)				
Variable	Group A	Group B	p-value	Significance
	Mean ± S.D	Mean ± S.D		
P1 <sub>2</sub> -pre	85.8 ± 4.2	84.4 ± 3.0	0.47	N.S
P1 <sub>2</sub> -post	84.9 ± 4.8	87.8 ± 2.4	0.15	N.S
P1 <sub>2</sub> - Change	0.88 ± 1.13	-3.38 ± 0.92	<0.0001	*
Vertical Control (c)				
Variable	Group A	Group B	p-value	Significance
	Mean ± S.D	Mean ± S.D		
P2 <sub>1</sub> -Pre	30.5 ± 2.3	29.7 ± 1.3	0.40	N.S
P2 <sub>1</sub> -Post	28.9 ± 3.1	30.9 ± 1.2	0.12	N.S
P2 <sub>1</sub> -Change	1.6 ± 0.9	-1.2 ± 1.1	<0.0001	*
P2 <sub>2</sub> -Pre	7.6 ± 1.9	5.6 ± 0.9	0.02	*
P2 <sub>2</sub> -Post	6.6 ± 2.3	6.9 ± 0.9	0.68	N.S
P2 <sub>2</sub> -Change	1.1 ± 0.5	-1.4 ± 1.2	<0.0001	*
P2 <sub>3</sub> -Pre	25.7 ± 2.6	24.8 ± 1.0	0.37	N.S
P2 <sub>3</sub> -Post	25.4 ± 2.3	25.5 ± 1.7	0.90	N.S
P2 <sub>3</sub> -Change	0.3 ± 0.5	-0.8 ± 0.9	0.01	*

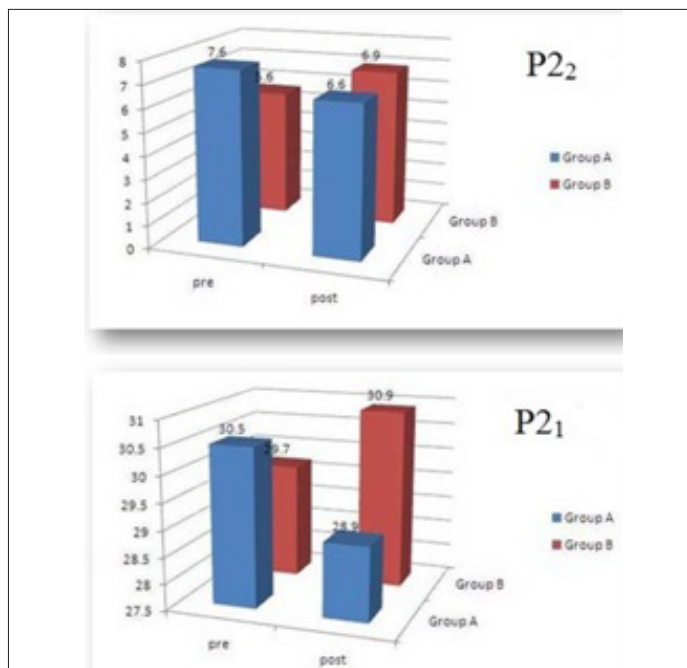
[Table/Fig-8a,b,c]: Statistically analyzed values tabulated



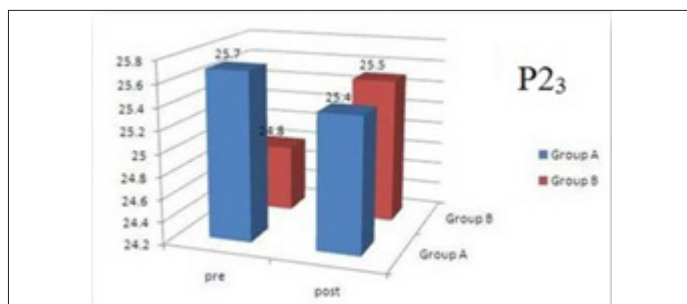
[Table/Fig-9]: P1<sub>1</sub> Torque of incisors and P1<sub>2</sub> tip of molar

± 1.1 and -1.4 ± 1.2 indicated a mild extrusion of incisors because the point of force application was more coronal. The p-value, P2<sub>1</sub> change of <0.0001 substantiates the significant difference.

The comparative difference between the mean values P2<sub>3</sub> change (vertical distance between palatal plane and molar) in Group A was 0.3 ± 0.5 which is clinically negligible. The mean values for P2<sub>3</sub> change in Group B was -0.8 ± 0.9 indicated a mild extrusion of molars. This could be explained by the fact that the molar tooth



[Table/Fig-10]: P2<sub>2</sub> Incisor verticla control - apical and P2<sub>1</sub> Incisor verticla control - coronal



[Table/Fig-11]: Molar vertical control

is the anchor component and the reactionary forces acting on it would bring about an extrusion of the molars [10]. The p-value, P2<sub>1</sub> change of 0.01 substantiates the significant difference.

### CONCLUSION

The implant provides an excellent three-dimensional control of the anterior and posterior segment during retraction when compared to the conventional mode of anchorage. The following advantages are cited,

1. The torque control between the Groups is comparable.
2. The tip control of molar is better in the implant Group.
3. True intrusion is possible with the implant Group.
4. Vertical control of the molar is better in the implant Group.

### REFERENCES

- [1] Akihiko Shinohara, Mitsuru Motoyoshi, Yasuki Uchida, Noriyoshi Shimizu. Root proximity and inclination of orthodontic mini implants after placement: Cone-beam computed tomography evaluation. *American Journal of Orthodontics and Dentofacial Orthopedics*. 2013; 144(1): 50-56.
- [2] Manuel Nienkemper, Benedict Wilmes, Alexander Pauls, Dieter Drescher. Mini-implant stability at the initial healing period A clinical pilot study. *Angle Orthod*. 2013; 83: 4.
- [3] Carano A, Velo S, Leone P, Siciliani G. Clinical application of the miniscrew anchorage system. *J Clin Orthod*. 2005; 39: 1: 9-24.
- [4] Park HS, Kwon TG. Sliding mechanics with microscrew implant anchorage. *Angle Orthod*. 2004; 74: 703-10.
- [5] Park HS, Kwon OW, JH Sung. Microscrew implants anchorage sliding mechanics. *World J Orthod*. 2005; 6: 265-74.
- [6] Pancherz H. A cephalometric analysis of skeletal and dental changes contributing to Class II correction in activator treatment. *Am J Orthod*. 1984;85:125-34
- [7] Park HS, Jeong SH, Kwon OW. Factors affecting the clinical success of screw implants used as orthodontic anchorage. *Am J Orthod Dentofacial Orthop*. 2006; 130: 18-25.

- [8] Miyawaki S, Koyama I, Inoue M, Mishima K, Sugawara T, Yamamoto TT. Factors associated with the stability of titanium screws placed in the posterior region for orthodontic anchorage. *Am J Orthod Dentofacial Orthop.* 2003; 124: 373-78.
- [9] Park HS, Kwon TG. Sliding mechanics with microscrew implant anchorage. *Angle Orthod.* 2004; 74: 703-10.
- [10] Wook Heo; Dong-Seok Nahm; Seung-Hak Baek. En Masse Retraction and Two-Step Retraction of Maxillary Anterior Teeth in Adult Class I Women. *Angle Orthodontist.* 2007, 77, 6: 975-78.

**PARTICULARS OF CONTRIBUTORS:**

1. Senior Lecturer, Meenakshmi Ammal Dental College & Hospital, Chennai, India.
2. Dean, Professor and Hod, Department of Orthodontics, Thai Moogambigi Dental College & Hospital, Mogappair, Chennai-600107, India.
3. Professor, Department of Orthodontics, Thai Moogambigi Dental College & Hospital, Mogappair, Chennai-600107, India.
4. Professor, Department of Orthodontics, Thai Moogambigi Dental College & Hospital, Mogappair, Chennai-600107, India.
5. Professor, Department of Orthodontics, Thai Moogambigi Dental College & Hospital, Mogappair, Chennai-600107, India.
6. Reader, Department of Orthodontics, Thai Moogambigi Dental College & Hospital, Mogappair, Chennai-600107, India.
7. PG Student, Department of Orthodontics, Thai Moogambigi Dental College & Hospital, Mogappair, Chennai-600107, India.
8. PG Student, Department of Orthodontics, Thai Moogambigi Dental College & Hospital, Mogappair, Chennai-600107, India.

**NAME, ADDRESS, E-MAIL ID OF THE CORRESPONDING AUTHOR:**

Dr. Ramchandra Prabhakar,  
Dean, Professor and Hod, Department of Orthodontics, TMDCH, Chennai, India.  
Phone: 9840400867, 9444468399, E-mail: dr.ramachandra.prabhakar@gmail.com

Date of Submission: **Oct 02, 2013**  
Date of Peer Review: **Oct 29, 2013**  
Date of Acceptance: **Nov 02, 2013**  
Date of Online Ahead of Print: **Nov 22, 2013**  
Date of Publishing: **Feb 03, 2014**

**FINANCIAL OR OTHER COMPETING INTERESTS:** None.