

## Intraperitoneal rupture of the bladder after urinary catheterization

Sophie Jambet,<sup>1</sup> Olivier Facy,<sup>1</sup>  
Pierre Landreau,<sup>1</sup> Céline Duperron,<sup>2</sup>  
Benjamin Kretz<sup>3</sup>

<sup>1</sup>Department of Digestive Surgical Oncology; <sup>2</sup>Department of Urology; <sup>3</sup>Department of Vascular Surgery, University hospital, Dijon, France

### Abstract

Intraperitoneal rupture of the bladder is a rare cause of peritonitis. Intraperitoneal rupture of the bladder was diagnosed during an emergency laparotomy for suspected mesenteric ischemia. The patient had undergone iterative urinary catheterization after a vascular bypass. The perforation was excised and sutured and the patient was catheterized for urinary rest for 15 days. Urinary catheterization is a possible cause of intraperitoneal rupture of the bladder.

### Case Report

A 74-year-old man was admitted for acute stage IV lower limb ischemia. A right femoropopliteal bypass with transmetatarsal amputation was performed. After the operation, he presented with acute urinary retention requiring urinary catheterization, but pulled out the urinary catheter twice because of agitation due to alcoholic stop. For each procedure, a silicon Foley catheter sizing 18 French was placed by the nurses without reported difficulty. On post-operative day 5 (the day following the third urinary catheterization), he presented with acute abdominal pain. On physical examination, there was abdominal guarding with hypotension. His temperature was normal, urine output in the Foley was 200 mL and the blood parameters showed an acute inflammatory response (17000 leukocytes/mm<sup>3</sup>, C-reactive protein: 17.5 mg/L), with normal creatinine and elevated urea (10 g/L, 2N). Emergency laparotomy was performed for suspected acute mesenteric ischemia. The laparotomy revealed a peritoneal perforation of the urinary bladder, with concomitant urinary peritonitis. The intestine was healthy. The bladder had been perforated by the urinary catheter and there was neither diverticulosis nor tumor (Figure 1). The perforation was excised and the bladder closed with one layer resorbable sutures. The urinary culture was normal. The urinary catheter was left in place for 15 days,

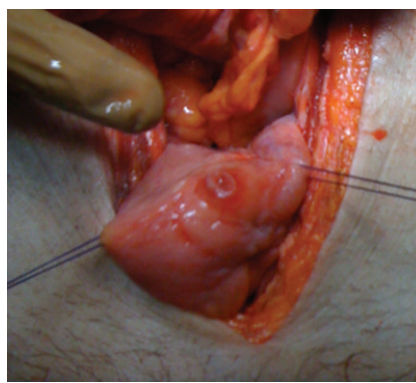
and the patient resumed normal urination after its removal. The pathological examination confirmed the absence of tumor and the patient is well after 6 months of follow-up.

### Discussion

Intraperitoneal perforation of the urinary bladder may occur in particular situations such as trauma, iatrogenicity (cystoscopy, prostatectomy), cancer, radiotherapy, infections or inflammatory lesions (cystitis, schistosomiasis, tuberculosis) and diverticulosis.<sup>1</sup> A few cases of idiopathic rupture that could have been related to the consumption of toxic substances (alcohol, drugs) have been reported. Few cases of rupture after urinary catheterization without other predisposing factors have been described in the literature.<sup>2</sup>

The diagnosis is challenging because the symptoms are not specific (pain, hematuria, oliguria), as well as blood parameters (inflammatory syndrome, renal insufficiency), leading to misdiagnosis and inappropriate or late treatment. The medical history of this patient with several successive urinary catheters may suggest this diagnosis (even if no traumatic difficulty was reported during the catheterization). Retrograde urethro-cystography or an abdominal computed tomography scan with bladder opacification can establish the diagnosis and localize the site of rupture.<sup>2,3</sup>

The main factor for the therapeutic management is peritoneal rupture. Retroperitoneal rupture of the bladder is commonly treated with bladder catheterization for 10 days. The classical treatment for intraperitoneal rupture of the bladder is surgical repair and urinary rest (with a Foley catheter left in place for one week at least).<sup>1-3</sup> Laparoscopy is possible in this setting and this approach would have been chosen if the perforation was diagnosed in our case.<sup>4</sup> In selective cases (particularly in the absence of peritoneal signs), conservative management may be effective with a urinary derivation for 15 days.<sup>2,3,5,6</sup>



**Figure 1.** Intra-peritoneal rupture of the top of the bladder due to the contact with the urinary catheter.

Correspondence: Olivier Facy, Service de chirurgie digestive et cancérologique, CHU, 14 rue Gaffarel, 21079 Dijon cedex, France. Tel. +33.380.293.747 - Fax: +33.380.293.591 E-mail: olivier.facy@chu-dijon.fr

**Key words:** bladder rupture, urinary catheterization.

Received for publication: 27 September 2011.  
Revision received: 21 October 2011.  
Accepted for publication: 24 October 2011.

This work is licensed under a Creative Commons Attribution NonCommercial 3.0 License (CC BY-NC 3.0).

©Copyright S. Jambet et al., 2011  
Licensee PAGEPress, Italy  
*Clinics and Practice* 2011; 1:e109  
doi:10.4081/cp.2011.e109

Idiopathic intra-peritoneal rupture of the bladder is difficult to diagnose due to the non-specific clinical picture. Despite it is widely performed, this procedure have potential risk of morbidity. Urinary opacification is the examination of choice when it is suspected. Conservative management may be sufficient in selective cases. Surgical treatment consists of bladder repair and a search for conditions that increase the risk of rupture (tumor, diverticulosis, infection).

### References

1. Kato A, Yoshida K, Tsuru N, et al. Spontaneous rupture of the urinary bladder presenting as oligurie acute renale failure. *Intern Med* 2006;45:815-8.
2. Farraye MJ, Seaberg D. Indwelling foley catheter causing extraperitoneal bladder perforation. *Am J Emerg Med* 2000;18:497-500.
3. Wirth GJ, Peter R, Poletti PA, Iselin CE. Advances in the management of blunt traumatic bladder rupture: experience with 36 cases. *BJU Int* 2010;106:1344-9.
4. Kim FJ, Chammas MF Jr, Gewehr EV, et al. Laparoscopic management of intraperitoneal bladder rupture secondary to blunt abdominal trauma using intracorporeal single layer suturing technique. *J Trauma* 2008;65:234-6.
5. Basiri A, Radfar MH. Conservative management of early bladder rupture after postoperative radiotherapy for prostate cancer. *Urol J* 2008;5:269-71.
6. Pansadoro A, Franco G, Laurenti C, Pansadoro V. Conservative treatment of intraperitoneal bladder perforation during transurethral resection of bladder tumor. *Urology* 2002;60:682-4.