

Colonic polyposis

Adrianna D'Mello^a, Ramesh B. Deshpande^b, Devendra Desai^c, Sudeep R. Shah^a

PD Hinduja Hospital, Mumbai, India

A 30-year-old female, with no significant family history, came with complaints of intermittent, colicky abdominal pain and abdominal distension of 5 months duration, with significant weight loss. CT abdomen showed multiple polypoidal lesions in the colon. Colonoscopy revealed multiple polyps carpeting the entire colon (Fig. 1A); biopsy of which revealed adenomatous polyps. The patient underwent total proctocolectomy with J-pouch ileo-anal anastomosis and ileostomy. Gross examination is depicted in Fig. 1B. Microscopic picture is demonstrated in Fig. 2. Patient is currently doing well on a one-month follow up.

Familial adenomatous polyposis (FAP) is an autosomal dominant, inheritable condition, characterized by over a hundred adenomatous polyps in the large intestine. It is linked to mutations of the *adenomatous polyposis coli* (APC) gene located on chromosome 5q21. Adenomatous polyps are present in nearly 100% by 40 years of age [1]. The lifetime risk of colorectal malignancy in untreated patients with FAP is near 100% with a median age of 39 years [2].

Surgical options include total abdominal colectomy with ileorectostomy, proctocolectomy with ileal pouch anal reconstruction, and total proctocolectomy with Brooke ileostomy [1-3].

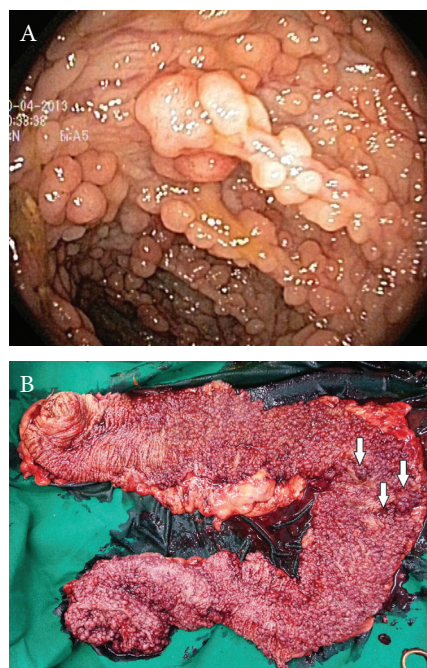
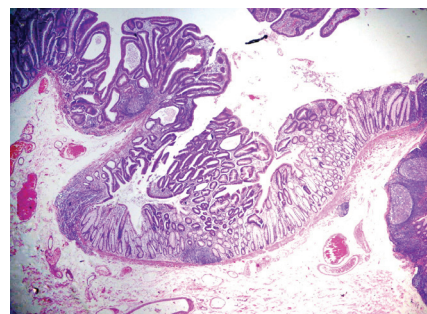


Figure 1 (A) Colonoscopic picture showing multiple polyps (B) Gross examination of the total proctocolectomy specimen, showing numerous polyps, varying in size from 0.1 to 1.8 cm, with areas suspicious for malignancy as indicated by the arrows

Figure 2 Microscopic picture, x10, stained with eosin and hematoxylin, showing an adenomatous polyp with evidence of well-differentiated adenocarcinoma with infiltration beyond the muscularis mucosae but restricted to the submucosa



Divisions of GI *Surgery (Adrianna D'Mello, Sudeep R. Shah);
^bPathology (Ramesh B. Deshpande); ^cMedical GI (Devendra Desai),
 PD Hinduja Hospital, Mumbai, India

Conflict of Interest: None

Correspondence to: Dr. Sudeep Shah, Divisions of GI Surgery and Pathology, PD Hinduja Hospital, Mumbai 400 016, India, Tel.: +91 9820 087642, e-mail: shahsudeep@hotmail.com

Received 14 June 2013; accepted 21 June 2013

References

1. Beech D, Pontius A, Muni N, Long WP. Familial adenomatous polyposis: a case report and review of the literature. *J Natl Med Assoc* 2001;**93**:208-213.
2. Ellis CN. Colonic adenomatous polyposis syndromes: clinical management. *Clin Colon Rectal Surg* 2008;**21**:256-262.
3. Al-Sukhni W, Aronson M, Gallinger. Hereditary colorectal cancer syndromes: familial adenomatous polyposis and Lynch syndrome. *Surg Clin N Am* 2008;**88**:819-844.