

**Sir,
Real-time visualisation of anaesthetic fluid localisation following incisionless sub-Tenon block**

The sub-Tenon block (STB) is the most widely used anaesthetic technique for cataract surgery.¹ This technique traditionally involves making an incision in the conjunctiva with blunt-tipped sprung Westcott scissors and blunt dissecting the sub-Tenon layer away from the sclera.²

We have previously developed a new minimally invasive technique of STB, which uses a blunt 'pencil point' cannula to allow access to the sub-Tenon space without prior conjunctival incision³ (Supplementary video 1). We investigated the spread and distribution of

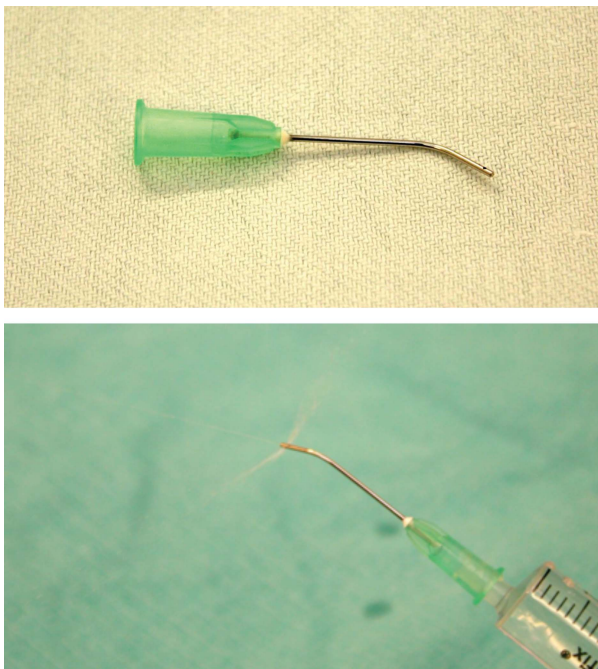


Figure 1 Eagle Tri-port sub-Tenon cannula used to perform minimally invasive sub-Tenon anaesthesia without prior conjunctival incision.

local anaesthetic via the incisionless STB, and compared it with standard techniques, using B-scan ultrasonography.

Case report

Patients having routine cataract extraction at the West of England Eye Unit were selected, and informed consent obtained. Dynamic B-scan ultrasonography was performed on the eye during administration of the STB by either the incisionless technique utilising the 'pencil point' sub-Tenon cannula (21G × 25 mm angled Tri-Port sub-Tenon Anaesthetic Cannula; Eagle Laboratories, Cucamonga, CA, USA; Figure 1), or by standard methods.

B-scan ultrasonography was chosen as a simple and non-invasive method for visualising the distribution of anaesthetic fluid in the posterior sub-Tenon space during an STB.⁴ We found that the anaesthetic fluid was easily visualised on ultrasonography as a dark outline tracking behind the globe in the retrobulbar space (Supplementary video 2).

Comment

The STB has gained popularity with both ophthalmic surgeons and anaesthetists as providing adequate anaesthesia and akinesia for intraocular procedures, while avoiding the risk of complications from sharp needles associated with other regional orbital block techniques.⁵ As the technique has further evolved and novel cannulae are introduced, it is important to objectively assess the safety and efficacy of these innovations.

We found that both standard and incisionless techniques of STB achieved similar ocular anaesthesia, and real-time visualisation of anaesthetic fluid localisation by B-scan ultrasonography demonstrated no significant differences in the spread and distribution of anaesthetic fluid between standard and incisionless techniques (Figure 2).

The incisionless STB has the advantage of reduced conjunctival trauma compared with traditional techniques, and reducing anterior refluxing of local anaesthetic improves the onset, quality, and reproducibility of the block.³ We feel that the incisionless STB is therefore recommended in view

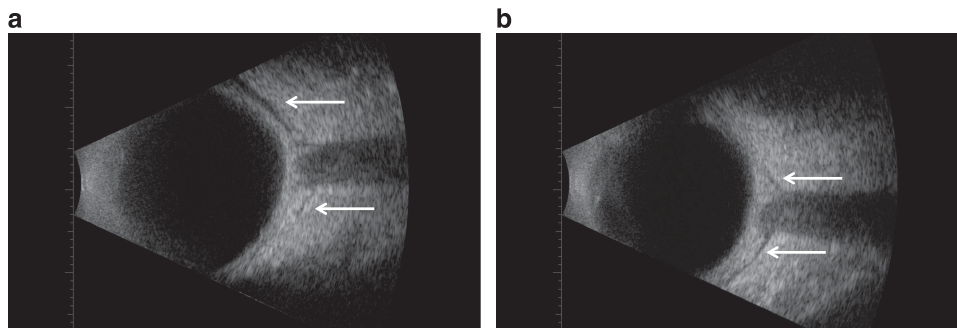


Figure 2 B-scan ultrasound images with arrows showing expanded posterior sub-Tenon space and 'T-sign' following (a) standard sub-Tenon technique and (b) incisionless sub-Tenon technique.

of its advantages over the traditional sub-Tenon anaesthetic techniques.

Conflict of interest

The authors declare no conflict of interest.

References

- 1 El-Hindy N, Johnston RL, Jaycock P, Eke T, Braga AJ, Tole DM *et al.* The Cataract National Dataset Electronic Multi-centre Audit of 55,567 operations: anaesthetic techniques and complications. *Eye (Lond)* 2009; **23**: 50–55.
- 2 Kumar CM, Dodds C. Sub-Tenon's anesthesia. *Ophthalmol Clin North Am* 2006; **19**: 209–219.
- 3 Allman KG, Theron AD, Byles DB. A new technique of incisionless minimally invasive sub-Tenon's anaesthesia. *Anaesthesia* 2008; **63**: 782–783.
- 4 Kumar CM, McNeela BJ. Ultrasonic localization of anaesthetic fluid using sub-Tenon's cannulae of three different lengths. *Eye (Lond)* 2003; **17**: 1003–1007.
- 5 Jeganathan VSE, Jeganathan VP. Sub-Tenon's anaesthesia: a well tolerated and effective procedure for ophthalmic surgery. *Curr Opin Ophthalmol* 2009; **20**: 205–209.

S Lin¹, RH Ling¹ and KG Allman²

¹West of England Eye Unit, Royal Devon & Exeter NHS Foundation Trust, Exeter, UK

²Department of Anaesthesia, Royal Devon & Exeter NHS Foundation Trust, Exeter, UK
E-mail: slin@nhs.net

This work was previously presented at the 44th RANZCO Annual Scientific Congress, November 2012, Melbourne, Australia.

Eye (2014) **28**, 497–498; doi:10.1038/eye.2014.14; published online 7 February 2014

Supplementary Information accompanies this paper on Eye website (<http://www.nature.com/eye>)

Sir, Dante and asthenopia: a modern visual problem described during the Middle Ages

One of the oldest descriptions of asthenopia (or eyestrain) may be evidenced in the 'Convivio' ('The Banquet'), a less-known work by the Italian poet Dante Alighieri (1265–1321). It should come as no surprise to find some descriptions of medical problems in Dante's encyclopedic literary works.^{1,2} Indeed, the poet had to be enrolled in the guild of physicians and apothecaries ('*ars medicorum et spetiariorum*') to take part in the public and political life of Florence; so, although he never practiced medicine, Dante studied the basic principles of science and medicine.³ His knowledge on

classical optics and human eye functions may be evidenced by accurate descriptions of optical phenomena (eg reflection and refraction) and visual problems (eg presbyopia) in some passages of his masterpiece, the 'Divine Comedy'.³ In the 'Convivio', a prose work written between 1304 and 1307, Dante provided with us an accurate description of a sudden visual disorder that he suffered from when he was 27 years old: 'for greatly taxing my sight in eagerness of reading, I so weakened the *visual spirits* that all the stars appeared to me to be shadowed by a kind of halo' (Conv. 3, 9).⁴ This description may be referred to asthenopia, a visual disorder that reveals itself through eyestrain, fatigue, pain in or around the eyes, and blurred vision.⁵ Aside from the association with jobs requiring intensive utilization of visual display terminals, its etiology and patho-physiology remain unknown. However, sometimes it appears to be due to specific visual problems such as uncorrected refraction errors or binocular vision problems.⁵ For this reason, some authors postulated that Dante may have suffered from uncorrected hyperopia or astigmatism.³ Interestingly, the Italian poet also reported how his own visual disorder was solved, stating that 'by long repose in dark and cool places, and cooling the body of eye in clear water, I knit together again the disintegrated power, so as to return to my former good condition of sight' (Conv. 3, 9).⁴ All of which is echoed today, and medieval treatment of this condition doesn't seem to be so dissimilar from modern suggestions of ophthalmologists, orthoptists, and visual therapists.

Conflict of interest

The authors declare no conflict of interest.

References

- 1 Widmer DA. Black bile and psychomotor retardation: shades of melancholia in Dante's *Inferno*. *J Hist Neurosci* 2004; **13**: 91–101.
- 2 Lucchini RG, Riva MA, Sironi VA, Porro A. Torvis oculis: occupational roots of behavioral neurotoxicology in the last two centuries and beyond. *Neurotoxicology* 2012; **33**: 652–659.
- 3 Mattioli M. *Dante e la medicina*. Edizioni Scientifiche Italiane: Napoli, 1965, pp 164–165.
- 4 Alighieri D. *The Convivio of Dante Alighieri*. Translated by Philip H Wicksteed, J.M. Dent and Sons: London, 1931.
- 5 Bhandari DJ, Choudhary S, Doshi VG. A community-based study of asthenopia in computer operators. *Indian J Ophthalmol* 2008; **56**: 51–55.

MA Riva, C Arpa and M Gioco

Department of Health Science, University of Milano Bicocca, Monza, Italy
E-mail: michele.riva@unimib.it

Eye (2014) **28**, 498; doi:10.1038/eye.2013.313; published online 10 January 2014
