

CASE REPORT

Open Access

# Discovery of imatinib-responsive *FIP1L1-PDGFR*A mutation during refractory acute myeloid leukemia transformation of chronic myelomonocytic leukemia

Shilpan Shah<sup>1</sup>, Sanam Loghavi<sup>2</sup>, Guillermo Garcia-Manero<sup>1</sup> and Joseph D Khoury<sup>2\*</sup>

## Abstract

The *FIP1L1-PDGFR*A rearrangement results in constitutive activation of the tyrosine kinase PDGFR. Neoplasms harboring this rearrangement are responsive to imatinib mesylate at doses much lower than those recommended for the treatment of chronic myelogenous leukemia. Only a single report has described the identification of *FIP1L1-PDGFR*A in chronic myelomonocytic leukemia (CMML). Herein, we present a case report of a patient in whom the *FIP1L1-PDGFR*A was discovered as he evolved from CMML to acute myeloid leukemia (AML). The presence of a dominant neoplastic clone with *FIP1L1-PDGFR*A rearrangement was suspected on the basis of sudden onset of peripheral and bone marrow eosinophilia and confirmed by fluorescence in situ hybridization and molecular diagnostic tests. Whereas the patient was initially refractory to chemotherapy before the rearrangement was detected, subsequent therapy with imatinib led to complete remission.

**Keywords:** *FIP1L1-PDGFR*A, Chronic myelomonocytic leukemia, Imatinib mesylate

## Background

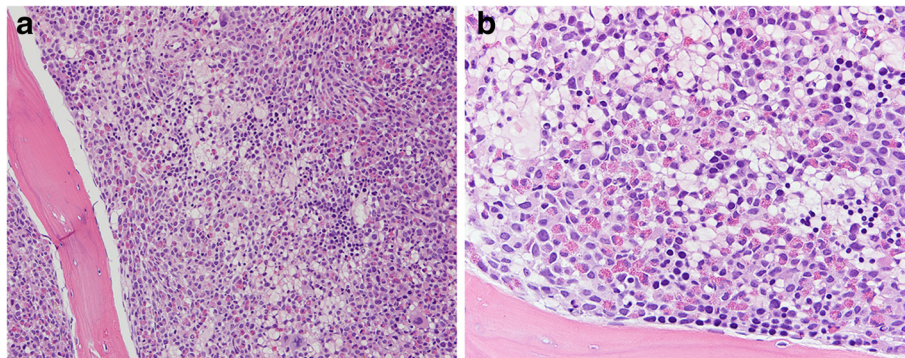
Hypereosinophilia is a feature of a variety of uncommon hematologic disorders like hyper eosinophilic syndrome (HES), systemic mastocytosis (SM) and chronic eosinophilic leukemia (CEL). Approximately 4% of patients with HES or SM have interstitial deletion of chromosome 4q12 leading to juxtaposition of *FIP1L1* and *PDGFR*A [1]. The fusion product is exquisitely sensitive to therapy with imatinib mesylate, and hence its identification has important therapeutic ramifications particularly in hematologic disorders presenting with hypereosinophilia [2-5]. We herein present the case of a patient in whom *FIP1L1-PDGFR*A was discovered at the time of evolution from chronic myelomonocytic leukemia (CMML) to refractory acute myeloid leukemia and how therapy with imatinib resulted in durable complete remission.

## Case presentation

A 64-year-old Caucasian man presented to our institution with a 6-month history of progressive leukocytosis. Per the patient's outside medical records, a bone marrow biopsy at initial presentation had shown a 100% cellular marrow with marked myeloid hyperplasia. Conventional cytogenetics demonstrated a diploid male karyotype. Fluorescence in situ hybridization studies (FISH) were negative for myelodysplasia-associated abnormalities. Molecular studies were negative for *BCR-ABL* rearrangement, and *JAK2*<sup>V617F</sup> and *MPL*<sup>W515L</sup> mutations. Based on these features, he was diagnosed with myelodysplastic/myeloproliferative neoplasm, unclassifiable, and was started on hydroxyurea, 1.5 grams daily. At presentation to our institution, his white blood cell (WBC) count was  $44.6 \times 10^9/L$  with 76% neutrophils, 6% metamyelocytes, 10% monocytes, 6% lymphocytes, 1% eosinophils and 1% blasts, with absolute monocytosis ( $4.46 \times 10^9/L$ ) and eosinophilia ( $0.45 \times 10^9/L$ ). He was anemic (hemoglobin 9.0 g/dL) and mildly thrombocytopenic (platelet count  $119 \times 10^9/L$ ). He did not have splenomegaly on physical examination. Bone marrow evaluation performed at presentation to our institution

\* Correspondence: jkhoury@mdanderson.org

<sup>2</sup>Department of Hematopathology, The University of Texas MD Anderson Cancer Center, 1515 Holcombe Boulevard, MS-72, 77030 Houston, TX, USA  
Full list of author information is available at the end of the article



**Figure 1** Bone marrow core biopsy at the time of initial *FIP1L1-PDGFRα* rearrangement discovery. The bone marrow is hypercellular (100%), with prominent eosinophilia and myeloid hyperplasia, mild increase in immature cells, and features of myelofibrosis manifesting primarily as cellular streaming. (a: 10x objective; b: 20x objective; hematoxylin and eosin stain).

revealed a 100% cellular bone marrow with myeloid hyperplasia. Megakaryocytes were decreased in number and included rare dysplastic forms. Wright-Giemsa stained smears prepared from the bone marrow aspirate were remarkable for increased myeloid cells and trilineage dysplasia; a 500-cell differential count showed mildly increased monocytes (6%) and myeloid blasts (7%). The constellation of findings was diagnostic of chronic myelomonocytic leukemia (CMML-1). Conventional cytogenetics showed trisomy 8 in two of twenty analyzed metaphases; this was confirmed by fluorescence in situ hybridization (FISH) using an alpha-satellite (D8Z2) CEP8 probe (positive in 4% of the cells studied). Reverse transcriptase polymerase chain reaction (RT-PCR) performed on the bone marrow aspirate was negative for *BCR-ABL* fusion. Targeted next-generation sequencing mutation analysis was negative for 53 “hotspot” mutations analyzed as described previously [6].

The patient was enrolled on the SGI-110 clinical trial, a phase 1–2 dose escalation, multicenter study of SGI-110, a DNA hypomethylating agent, in subjects with intermediate or high-risk myelodysplastic syndromes (MDS) or AML. He received two courses of SGI-110, after which he experienced rapidly progressive leukocytosis with a peak WBC count of  $126 \times 10^9/L$  and new onset of peripheral

eosinophilia (11%). Bone marrow evaluation performed at this time demonstrated nearly 100% cellularity with myeloid hyperplasia; in contrast to the previous biopsy, prominent eosinophilia and moderate myelofibrosis were noted in this sample (Figure 1a-b). Wright-Giemsa stained smears showed increased granulocytes with left-shifted maturation and prominent eosinophilia (16%) in a background of trilineage dysplasia. There was no significant increase in bone marrow monocytes (5%). Myeloid blasts comprised 12% of total nucleated cells. The unexpected and abrupt presence of prominent eosinophilia in the peripheral blood and bone marrow at this point in time prompted us to evaluate for *PDGFRα* rearrangement. FISH analysis performed using a LSI-4q12 tricolor rearrangement probe that hybridizes to the chromosome 4q12 region containing the *FIP1L1*, *CHIC2* and *PDGFRα* genes revealed deletion of the *CHIC2* gene in 86.5% of the cells analyzed indicating the presence of the *FIP1L1-PDGFRα* rearrangement. The *FIP1L1-PDGFRα* fusion transcript was further confirmed by RT-PCR. Low-level trisomy 8 was also detected by FISH in this sample. Based on these findings a diagnosis of myelodysplastic/myeloproliferative neoplasm with eosinophilia and *PDGFRα* rearrangement was rendered. A follow-up bone marrow biopsy after one month showed acute myeloid leukemia with

**Table 1** Sequence of clinical events

Event sequence	WBC ( $\times 10^9$ )	Eosinophils in PB (% AEC)	Eosinophils in BM (%)	Blasts in BM (%)	Diagnosis	Intervention	Disease status
Initial presentation	44.6	1, 0.45	1	7	CMML-1	SGI-110	Refractory
After 2 months	65.1	9, 5.8	5	4	CMML-1	SGI-110	Progression
After 1 month	126	11, 13.8	16	12	Myelodysplastic/myeloproliferative neoplasm with eosinophilia, and <i>PDGFRα</i> rearrangement	Fludarabine + Cytarabine	Progression
After 1 month	6.4	1, 0.06	1	26	AML with <i>PDGFRα</i> rearrangement	Imatinib (with Idarubicin + Cytarabine)	Remission

WBC: white blood cells, PB: peripheral blood, AEC: absolute eosinophil count, BM: bone marrow, CMML: chronic myelomonocytic leukemia, AML: acute myeloid leukemia.

**Table 2 PDGFRA rearrangement in unusual adult myeloid neoplasms**

Author/journal	Disease	Treatment	Outcome
Tang et al., Acta Haematol. 2012;128:83–87	Myeloproliferative neoplasm with eosinophilia	Imatinib – started at 400 mg daily and maintained at 100 mg daily	Complete hematologic and molecular remission at 12 months
Papanikolaou et al., Ann Hematol. 2012 May;91(5):785-7	Chronic eosinophilic leukemia with lytic bone lesions	Imatinib 200 mg daily; on progression, nilotinib 400 mg BID	Progressed to erythroblastoid blast crisis after 2 years on TKI
Sorour et al., Br J Haematol. 2009 Jul;146(2):225-7	Acute myeloid leukemia with eosinophilia	Imatinib with FLAG-Ida followed by matched unrelated allograft	Relapsed with Imatinib resistance; started on Dasatinib but died 15 months later
Lierman et al., Leukemia. 2009 May;23(5):845-51	Chronic eosinophilic leukemia blast crisis with Imatinib resistance	Sorafenib 400 mg BID	Hematologic response without molecular response for 3 months
Zota et al., J Clin Oncol. 2008 Apr 20;26(12):2040-1	Chronic myelomonocytic leukemia	Imatinib 400 mg BID	Resolution of eosinophilia without other hematologic response; progressed to extramedullary disease
Florian et al., Leuk Res. 2006 Sep;30(9):1201-5	Systemic mastocytosis with chronic eosinophilic leukemia	Incomplete response to hydroxyurea, corticosteroids and interferon-alpha; started on imatinib 100 mg in 2002	Long-term response to low-dose Imatinib (50-100 mg) after inadequate responses to previous therapies
Von Bubnoff et al., Leukemia. 2005 Feb;19(2):286-7	Chronic myeloproliferative disorder with eosinophilia	Imatinib 100-400 mg daily	Hematologic and symptomatic response for 6 months; progression to myeloid blasts crisis and malignant pleural effusion
Saflet et al., Genes Chromosomes Cancer 2004 May;40(1):44-50	Atypical chronic myeloid leukemia with t(4;22) leading to formation of BCR-PDGFRA fusion gene	Imatinib 100 mg daily	Complete hematologic response at 7-month follow up

26% blasts. In addition to persistent low-level trisomy 8, conventional cytogenetics and FISH demonstrated a new clone with *TP53* gene deletion. FISH was positive for deletion of the *CHIC2* gene, *TP53* deletion and trisomy 8 in 90%, 10% and 9% of the analyzed cells, respectively.

The patient was then started on imatinib mesylate 400 mg daily along with a short course of idarubicin and subcutaneous cytarabine for cytoreduction. He achieved complete hematologic and morphologic remission and went on to receive a matched unrelated allogeneic stem cell transplant (SCT). To date, the patient remains in complete hematologic, morphologic and molecular remission with successful engraftment as demonstrated by chimerism studies. The sequence of events is provided in Table 1.

## Discussion

The PDGFRA and PDGFRB proteins are members of the class III receptor kinase family that also includes c-KIT, and FLT3 [7]. *PDGFRA* is located on chromosome 4q12 [8]. A small interstitial deletion of 4q12 leads to juxtaposition of *FIP1L1* and *PDGFRA* resulting in a gain of function fusion protein with signal independent kinase activity and therefore increased cell proliferation and survival [9]. This interstitial deletion is generally cryptic and not detectable using standard cytogenetic banding techniques.

*FIP1L1-PDGFR*A rearrangements are often associated with chronic eosinophilic leukemia and hypereosinophilic syndromes [9,10] as well as systemic mastocytosis [11]. Pardnani *et al.* reported a prevalence of approximately 4% for *FIP1L1-PDGFR*A fusion gene in a large series of patients with suspected or established HES or systemic mastocytosis [1]. We recently described a case of chronic neutrophilic leukemia associated with *FIP1L1-PDGFR*A rearrangement [4]. The basis for the apparent lineage predilection of *FIP1L1-PDGFR*A for eosinophils is not well understood. The hypothesis is that it is present in all myeloid lineages, but that eosinophils are particularly sensitive to the *FIP1L1-PDGFR*A proliferative signal [12]. In contrast to rearrangements involving *PDGFRB*, the *FIP1L1-PDGFR*A rearrangement is exceedingly rare in the setting of chronic myelomonocytic leukemia [13-16]. To our knowledge, only one other case has been reported in the literature by Zota *et al.* [17] In contrast to our patient, the patient reported by Zota *et al.* did not evolve in to acute myeloid leukemia, albeit the acquisition of *FIP1L1-PDGFR*A fusion was considered a feature of disease evolution. Initiation of imatinib resolved eosinophilia but did not effectively improve other counts, and the patient subsequently progressed to CMML-2 and developed extramedullary disease in abdominal lymph nodes; she succumbed in 10 months. A case series from Germany described five patients with *FIP1L1-PDGFR*A who presented with AML and eosinophilia, but no history of antecedent myeloid

malignancy was reported for any of the patients [18]. A summary of case reports describing *PDGFRA* rearrangements arising in patients with myeloid neoplasms commonly not associated with such rearrangements is provided in Table 2. All patients received imatinib therapy and achieved at least a hematologic response. One patient got sorafenib and another got dasatinib after acquiring resistance to imatinib. Two of eight patients maintained molecular response, while two maintained hematologic response at last reported follow up. Notably, clonal acquisition of *FIP1L1-PDGFR*A has not been reported in the setting of acute myeloid leukemia evolving from CMML.

Our case highlights the importance of assessing for *PDGFRA* rearrangement in myeloid neoplasms with *de novo* or subsequently acquired eosinophilia. The identification of the *FIP1L1-PDGFR*A fusion gene is significant since imatinib has excellent efficacy at low doses (100-400 mg daily) in *FIP1L1-PDGFR*A-positive neoplasms [2,5]. Of note, due to the 250-fold lower IC<sub>50</sub> as compared to *BCR-ABL*, reports suggest that even once weekly doses of imatinib are adequate in the setting of *FIP1L1-PDGFR*A [3]. However, these responses are eventually lost due to emergence of an imatinib-resistant T614I mutation in the ATP-binding site of *PDGFRA* [9]. In our patient, the ability to induce a complete remission using imatinib at a time when the patient was unresponsive to chemotherapy induction permitted subsequent allogeneic SCT and an ensuing durable remission as of last follow up.

## Conclusion

We describe a case report of a patient who transformed from CMML to AML which was refractory to standard chemotherapy. Emergence of peripheral and bone marrow hypereosinophilia during this transformation led to suspicion of presence of *FIP1L1-PDGFR*A rearrangement, which was confirmed by FISH and RT-PCR. Treatment with imatinib led to a complete remission and permitted allogeneic SCT therapy.

## Endnote

The identification of new onset of eosinophilia in acute myeloid leukemia arising in a patient with chronic myelomonocytic leukemia might indicate acquisition of imatinib-responsive *FIP1L1-PDGFR*A rearrangement.

## Consent

Granted under protocol approved by the Institutional Review Board of The University of Texas M.D. Anderson Cancer Center.

## Abbreviations

CMML: Chronic myelomonocytic leukemia; AML: Acute myeloid leukemia; HES: Hypereosinophilic syndrome; SM: Systemic mastocytosis; CEL: Chronic eosinophilic leukemia; FISH: Fluorescence in situ hybridization studies; PCR: Polymerase chain reaction; MDS: Myelodysplastic syndromes.

#### Competing interests

The authors declare no competing interest pertaining related to this study.

#### Authors' contributions

SS, GGM and JDK: conception of manuscript, chart review, and manuscript preparation; SL: chart review and manuscript preparation. All authors have read and approved the final manuscript.

#### Author details

<sup>1</sup>Department of Leukemia, The University of Texas MD Anderson Cancer Center, 1515 Holcombe Boulevard, MS-72, 77030 Houston, TX, USA.

<sup>2</sup>Department of Hematopathology, The University of Texas MD Anderson Cancer Center, 1515 Holcombe Boulevard, MS-72, 77030 Houston, TX, USA.

Received: 24 February 2014 Accepted: 16 March 2014

Published: 27 March 2014

#### References

- Pardanani A, Ketterling RP, Li CY, Patnaik MM, Wolanskyj AP, Elliott MA, Camoriano JK, Butterfield JH, Dewald GW, Tefferi A: **FIP1L1-PDGFRα in eosinophilic disorders: prevalence in routine clinical practice, long-term experience with imatinib therapy, and a critical review of the literature.** *Leuk Res* 2006, **30**(8):965–70.
- Helbig G, Stella-Holowiecka B, Grosicki S, Bober G, Krawczyk M, Wojnar J, Reiter A, Hochhaus A, Holowiecki J: **The results of imatinib therapy for patients with primary eosinophilic disorders.** *Eur J Haematol* 2006, **76**(6):535–6.
- Helbig G, Stella-Holowiecka B, Majewski M, Calbecka M, Gajkowska J, Klimkiewicz R, Moskwa A, Grzegorzczak J, Lewandowska M, Holowiecki J: **A single weekly dose of imatinib is sufficient to induce and maintain remission of chronic eosinophilic leukaemia in FIP1L1-PDGFRα-expressing patients.** *Br J Haematol* 2008, **141**(2):200–4.
- Jain N, Khoury JD, Pemmaraju N, Kollipara P, Kantarjian H, Verstovsek S: **Imatinib therapy in a patient with suspected chronic neutrophilic leukemia and FIP1L1-PDGFRα rearrangement.** *Blood* 2013, **122**(19):3387–8.
- Metzgeroth G, Walz C, Erben P, Popp H, Schmitt-Graeff A, Haferlach C, Fabarius A, Schnittger S, Grimwade D, Cross NC, Hehlmann R, Hochhaus A, Reiter A: **Safety and efficacy of imatinib in chronic eosinophilic leukaemia and hypereosinophilic syndrome: a phase-II study.** *Br J Haematol* 2008, **143**(5):707–15.
- Alayed K, Patel KP, Konoplev S, Singh RR, Routbort MJ, Reddy N, Pemmaraju N, Zhang L, Shaikh AA, Aladily TN, Jain N, Luthra R, Medeiros LJ, Khoury JD: **TET2 mutations, myelodysplastic features, and a distinct immunoprofile characterize blastic plasmacytoid dendritic cell neoplasm in the bone marrow.** *Am J Hematol* 2013, **88**(12):1055–61.
- Reilly JT: **Class III receptor tyrosine kinases: role in leukaemogenesis.** *Br J Haematol* 2002, **116**(4):744–57.
- Gronwald RG, Adler DA, Kelly JD, Distechi CM, Bowen-Pope DF: **The human PDGF receptor alpha-subunit gene maps to chromosome 4 in close proximity to c-kit.** *Hum Genet* 1990, **85**(3):383–5.
- Cools J, DeAngelo DJ, Gotlib J, Stover EH, Legare RD, Cortes J, Clark J, Galinsky I, Griffin JD, Cross NC, Tefferi A, Malone J, Alam R, Schrier SL, Schmid J, Rose M, Vandenbergh P, Verhoef G, Boogaerts M, Wlodarska I, Kantarjian H, Marynen P, Coutre SE, Stone R, Gilliland DG: **A tyrosine kinase created by fusion of the PDGFRA and FIP1L1 genes as a therapeutic target of imatinib in idiopathic hypereosinophilic syndrome.** *N Engl J Med* 2003, **348**(13):1201–14.
- Pardanani A, Brockman SR, Paternoster SF, Flynn HC, Ketterling RP, Lasho TL, Ho CL, Li CY, Dewald GW, Tefferi A: **FIP1L1-PDGFRα fusion: prevalence and clinicopathologic correlates in 89 consecutive patients with moderate to severe eosinophilia.** *Blood* 2004, **104**(10):3038–45.
- Pardanani A, Pardanani A, Ketterling RP, Brockman SR, Flynn HC, Paternoster SF, Shearer BM, Reeder TL, Li CY, Cross NC, Cools J, Gilliland DG, Dewald GW, Tefferi A: **CHIC2 deletion, a surrogate for FIP1L1-PDGFRα fusion, occurs in systemic mastocytosis associated with eosinophilia and predicts response to imatinib mesylate therapy.** *Blood* 2003, **102**(9):3093–6.
- Gotlib J: **Molecular classification and pathogenesis of eosinophilic disorders: 2005 update.** *Acta Haematol* 2005, **114**(1):7–25.
- Apperley JF, Gardembas M, Melo JV, Russell-Jones R, Bain BJ, Baxter EJ, Chase A, Chessells JM, Colombat M, Dearden CE, Dimitrijevic S, Mahon FX, Marin D, Nikolova Z, Olavarria E, Silbermann S, Schultheis B, Cross NC, Goldman JM: **Response to imatinib mesylate in patients with chronic myeloproliferative**

diseases with rearrangements of the platelet-derived growth factor receptor beta. *N Engl J Med* 2002, **347**(7):481–7.

- David M, Cross NC, Burgstaller S, Chase A, Curtis C, Dang R, Gardembas M, Goldman JM, Grand F, Hughes G, Huguet F, Lavender L, McArthur GA, Mahon FX, Massimini G, Melo J, Rousselot P, Russell-Jones RJ, Seymour JF, Smith G, Stark A, Waghorn K, Nikolova Z, Apperley JF: **Durable responses to imatinib in patients with PDGFRβ fusion gene-positive and BCR-ABL-negative chronic myeloproliferative disorders.** *Blood* 2007, **109**(1):61–4.
- Drechsler M, Hildebrandt B, Kündgen A, Germing U, Royer-Pokora B: **Fusion of H4/D10S170 to PDGFRβ in a patient with chronic myelomonocytic leukemia and long-term responsiveness to imatinib.** *Ann Hematol* 2007, **86**(5):353–4.
- La Starza R, Rosati R, Roti G, Gorello P, Bardi A, Crescenzi B, Pierini V, Calabrese O, Baens M, Folens C, Cools J, Marynen P, Martelli MF, Mecucci C, Cuneo A: **A new NDE1/PDGFRβ fusion transcript underlying chronic myelomonocytic leukaemia in Noonan Syndrome.** *Leukemia* 2007, **21**(4):830–3.
- Zota V, Miron PM, Woda BA, Raza A, Wang SA: **Eosinophilia with FIP1L1-PDGFRα fusion in a patient with chronic myelomonocytic leukemia.** *J Clin Oncol* 2008, **26**(12):2040–1.
- Metzgeroth G, Walz C, Score J, Siebert R, Schnittger S, Haferlach C, Popp H, Haferlach T, Erben P, Mix J, Müller MC, Beneke H, Müller L, Del Valle F, Aulitzky WE, Wittkowsky G, Schmitz N, Schulte C, Müller-Hermelink K, Hodges E, Whittaker SJ, Diecker F, Döhner H, Schulz P, Hehlmann R, Hochhaus A, Cross NC: **Recurrent finding of the FIP1L1-PDGFRα fusion gene in eosinophilia-associated acute myeloid leukemia and lymphoblastic T-cell lymphoma.** *Leukemia* 2007, **21**(6):1183–8.

doi:10.1186/1756-8722-7-26

**Cite this article as:** Shah et al.: Discovery of imatinib-responsive FIP1L1-PDGFRα mutation during refractory acute myeloid leukemia transformation of chronic myelomonocytic leukemia. *Journal of Hematology & Oncology* 2014 **7**:26.

**Submit your next manuscript to BioMed Central and take full advantage of:**

- Convenient online submission
- Thorough peer review
- No space constraints or color figure charges
- Immediate publication on acceptance
- Inclusion in PubMed, CAS, Scopus and Google Scholar
- Research which is freely available for redistribution

Submit your manuscript at  
www.biomedcentral.com/submit

