

Inhibitory effects by ayurvedic plants on prostate enlargement induced in rats

Rahul K. Dumbre, Manisha B. Kamble¹, Vijay R. Patil

Department of Pharmacognosy, TVES's Loksevak Madhukarrao Chaudhari College of Pharmacy, Faizpur, Maharashtra,
¹Department of Pharmacognosy, Rajgad Dyanpeeth's College of Pharmacy, Bhor, Pune, Maharashtra, India

Submitted: 29-06-2013

Revised: 16-08-2013

Published: 18-03-2014

ABSTRACT

Background: Ayurveda recommends several plants and plant preparation for conditions of urogenital disorders as per its principles. Objectives: Ayurvedic plants Tamala (*Cinnamomum tamala*); Daruhadal (*Berberis aristata*); Ativisha (*Aconitum heterophyllum*) were studied for mechanisms of prostatic hyperplasia induced in rats. **Materials and Methods:** Prostatic enlargement was induced in castrated rats by testosterone injection s.c. for 21 days and simultaneously plants were dosed orally daily. On day 22 rats were sacrificed and prostate was removed; weight and volume of prostate was measured; histopathology performed. Inflammation was induced by injecting carrageenan in rat hind paw and inhibition was studied by measuring rat paw oedema at different time points. **Results:** Tamala showed significant effect where it reduced prostatic enlargement and improved hyperplastic changes, while Daruhadal and Ativisha did not show any significant effect. All of them showed mild to moderate anti-inflammatory activity. **Conclusion:** Study concludes that Tamala may benefit in prostate disorder by virtue of inhibition of androgen mechanisms in prostate and modulating inflammatory mediators in prostate. Daruhadal and Ativisha did not show any effect in this model of prostate enlargement while the anti-inflammatory effect may propose one of the useful properties when included in various formulations.

Key words: Ativisha (*Aconitum heterophyllum*), daruhadal (*Berberis aristata*), prostatic hyperplasia, tamala (*Cinnamomum tamala*)

INTRODUCTION

Benign Prostatic Hyperplasia (BPH) and associated Lower Urinary Tract Symptoms (LUTS) and Prostatitis are one of the major urogenital disorders affecting elderly mens.^[1-3]

Ayurveda, traditional system of medicine recommends many plants and plant preparations for management of urogenital disorders as per the principles of its pathology. Present study is done to understand the effects of plants and plant preparations mentioned in Ayurveda viz. Tamala (*Cinnamomum tamala*), Daruhadal (*Berberis aristata*), Ativisha (*Aconitum heterophyllum*) in experimental enlargement of prostate and inflammation in rats, conditions usually found in BPH patients.

Address for correspondence:

Mr. Rahul K. Dumbre, Flat no 408, Prathamesh, Jai Ganesh Vishwa, Gokulnagar, Katraj Kondhwa Road, Pune - 411 048, Maharashtra, India. E-mail: rahuldumbre@hotmail.com

MATERIALS AND METHODS

Plants

Tamala consisting of dried mature leaves of *Cinnamomum tamala* (Buch. Ham.) Nees and Eberm. (Fam. Lauraceae) and Daruhadal consisting of dried stem of *Berberis aristata* DC. (Fam. Berberidaceae) were used for studies. Ativisha consisting of dried, tuberous roots of *Aconitum heterophyllum* Wall. ex. Royle (Fam. Ranunculaceae) were selected for study.

Plants were obtained from local market, authenticated and quality evaluated as per Ayurvedic Pharmacopeia of India. Plant material was powdered and passed through mesh of size 85 and used for studies.^[4]

Chemicals

Chemicals were obtained as follows: Testosterone Propionate (German Remedies, India-Testoviron);

Access this article online

Website:

www.phcogres.com

DOI: 10.4103/0974-8490.129031

Quick Response Code:



Finasteride (Dr. Reddy, India-Finax); Carrageenan and Indomethacin from Sigma Aldrich.

Animals

Male rats of Sprague-Dawley strain weighing between 240-300 g were used for the experiments. All the animals were obtained from Animal House of National Toxicology Centre, Pune. Animals were fed *ad libitum* with standard pellet (Chakan Oil Mills, Pune, India) diet and had free access to water. All the protocols of animal experiments were approved by the Institutional Animal Ethics Committee. Animals were maintained at a temperature of $25 \pm 1^\circ\text{C}$ and relative humidity of 45 to 55% under 12 h light: 12-h dark cycle. They were housed individually in the polypropylene cages after surgery.

Effect in experimentally induced prostatic hyperplasia in rats

The rats were castrated by removing their testes and 6 days after castration animals were divided into following groups of negative control, test groups of Tamala, Daruhalad and Ativish and positive control with 6 animals in each group. Six normal non-castrated rats were taken as normal control. Test groups, were divided in dose range of 270 and 540 mg/kg for Tamala; 500 and 1000 mg/kg for Daruhalad; 180 and 360 mg/kg for Ativish and dosage were given orally. Positive control Finasteride was given at dose of 5 mg/kg orally. Negative control received water orally. One hour after oral dosing the negative control, test groups and positive control group received testosterone propionate 0.5 mg/0.1 mL by s.c. route. Dosing was done for 3 weeks. 24 hours after last dosing animals were sacrificed and prostate removed. Prostate weight and volume was measured. The volume was measured (by the formula: $1/2(a \times b^2)$, where a and b refer to longer and shorter dimension, respectively). Prostate was fixed in 10% formalin. The formalin fixed tissues were embedded in paraffin and thin sections were taken and stained by H and E staining process.^[5,6]

Anti-inflammatory activity

The rats were divided into normal vehicle control,

test groups, and positive control with 6 rats in each group. Acute inflammation was produced in all rats by subplantar administration of 0.1 mL of 1% carrageenan in normal saline in the right hind paw of rats. Test groups were divided in dose range of 270 and 540 mg/kg for Tamala; 500 and 1000 mg/kg for Daruhalad; 180 and 360 mg/kg for Ativish. Positive control received Indomethacin 10 mg/kg orally. Vehicle control received only water orally. The paw volume was measured at 0, 1, 2, 3 and 4 h after carrageenan administration by plethysmometer (Ugo Basile). Dosing was done 1 h before carrageenan administration. The amount of inflammation was compared with the 0 h reading of the same rat and percentage anti-inflammatory activity calculated by comparing difference in percentage inflammation with vehicle control group.^[6]

Statistical analysis

The data was expressed as mean \pm SEM. The results were analyzed statistically using ANOVA and student's *t* test. The minimum level significance was considered as $P < 0.05$.

RESULT

Negative control shows that testosterone at dose of 0.5 mg/0.1 mL significantly increased prostate weight and volume of castrated animals compared to normal control animals indicating enlargement [Table 1 and Figure 1]. Tamala powder after 21 days treatment at dose of (270 and 540 mg/kg) significantly reduced the volume and weight of prostate when compared to negative control. The effect was more pronounced than positive control Finasteride (5 mg/kg). Ativish powder at dose (180 and 360 mg/kg) and Daruhalad at dose (500 and 1000 mg/kg) did not show any significant effect on volume and weight of prostate after 21 days treatment [Table 1 and Figure 1].

Histopathological observations show that normal control rat show regular acini, cuboidal epithelial cells with

Table 1: The effect of plants on testosterone- induced growth of volume and weight index of prostate gland of castrated rat

Group	Dose (mg/kg)	B.W. (g)	Volume of prostate (cm ³)	Wet weight index of prostate (mg/100 g B.W.)
Normal control	-	264.67 \pm 38.39	0.42 \pm 0.11	159.86 \pm 12.54
Negative control	Water	261.83 \pm 35.90	0.60 \pm 0.12	248.34 \pm 7.76
Finasteride	5	280.83 \pm 22.76	0.51 \pm 0.06*	191.90 \pm 9.11**
Tamala	270	279.17 \pm 20.08	0.52 \pm 0.02	188.22 \pm 6.91**
	540	273.67 \pm 18.08	0.42 \pm 0.02*	158.91 \pm 10.00**
Daruhalad	500	273.17 \pm 26.95	0.55 \pm 0.02	243.07 \pm 13.59
	1000	261.67 \pm 23.91	0.55 \pm 0.05	215.54 \pm 22.48
Ativish	180	274.33 \pm 29.03	0.65 \pm 0.03	245.35 \pm 19.62
	360	280.00 \pm 27.32	0.55 \pm 0.03	233.61 \pm 15.21

n=6, mean \pm S.E.M. * $P < 0.05$, ** $P < 0.01$ vs. Group II. B.W. represents body weight

Table 2: Results of histopathology of prostate glands

Label	Gland crowding	Epithelial hyperplasia	Stromal hyperplasia	Stromal inflammation
Normal control	---	---	---	---
Testosterone treated control	++	++	++	+++
Finasteride+testosterone	+	+	+	---
Tamala+testosterone	---	---	---	---
Daruhalad+testosterone	++	+++	+	---
Ativish+testosterone	++	+++	+	---

+=Mild hyperplasia; ++=Moderate hyperplasia; +++=Severe hyperplasia; ---=Absent hyperplasia

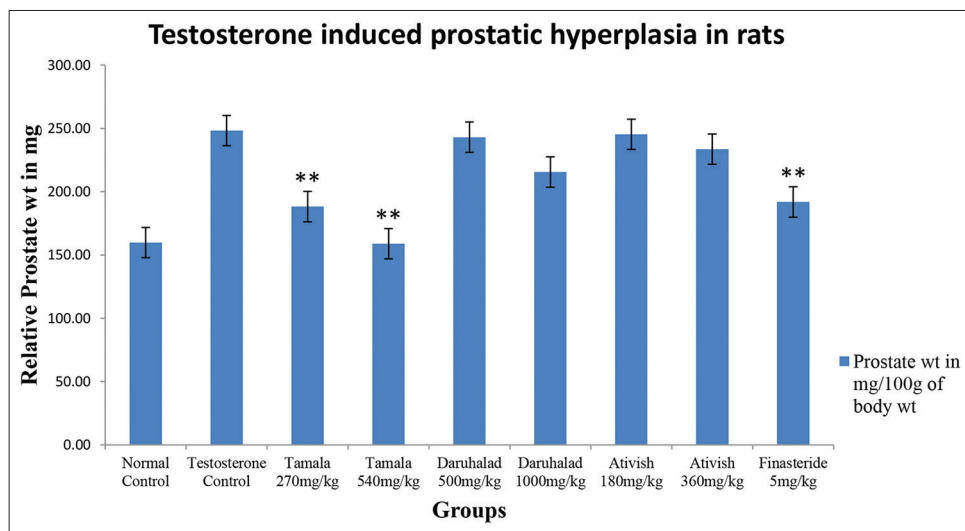


Figure 1: Relative prostate weight of rats

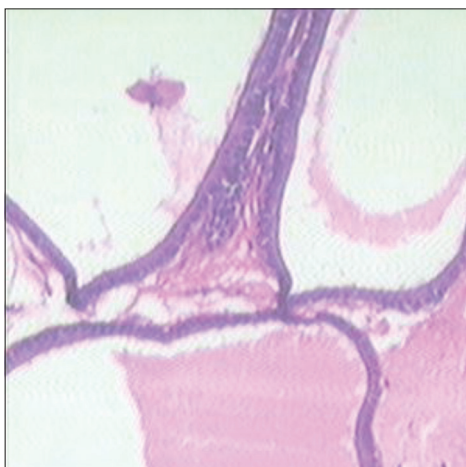


Figure 2: Normal control

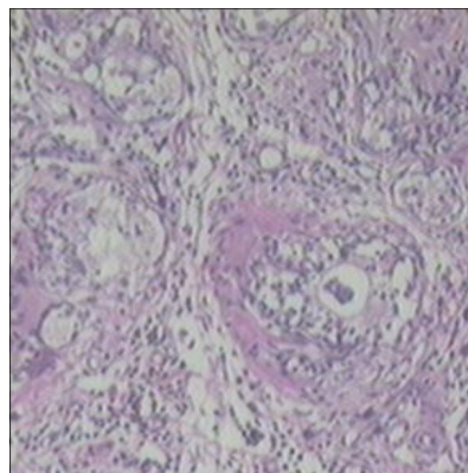


Figure 3: Testosterone treated control

round nuclei at basal position; intact basal membrane of epithelial lining and slightly irregular interstitial stroma region [Table 2 and Figure 2]. Testosterone-treated rat show irregular acini growth with irregular stroma. Epithelial lining shows hyperplasia with low cuboidal to tall cells and basal membrane was slightly discontinuous. There was high chronic edematous interstitial and intraluminal infiltration and WBC exudates. Lesions of prostatitis and fibrosis were observed [Table 2 and Figure 3].

Finasteride-treated group show regular acini, cuboidal to tall epithelial cells with some hyperplasia, intact basal membrane with slight irregular stroma [Table 2 and Figure 4]. Tamala-treated group show regular acini, cuboidal epithelial cells with round nuclei at basal position, intact basal membrane and slightly irregular interstitial stroma [Table 2 and Figure 5]. Daruhalad-treated group show irregular acini growth with irregular stroma. Epithelial lining shows hyperplasia with cuboidal to tall cells and

intact basal membrane [Table 2, Figure 6]. Ativish showed irregular acini growth with slight irregular stroma and mild focal epithelial hyperplasia, cuboidal to tall epithelial cells with round nuclei at basal position and intact basal membrane [Table 2, Figure 7].

Ativish at dose of 360 mg/kg, Daruhalad at 1000 mg/kg and Tamala at 540 mg/kg reduced carrageenan-induced paw edema by 23.04%, 33.65% and 29.21%, respectively, indicating mild to moderate anti-inflammatory activity [Table 3].

DISCUSSION

Benign prostatic hyperplasia is a complex disease where various mechanisms are leading to enlargement of tissue and retention of urine. Age-related hormonal imbalance of testosterone/estrogen and activity of testosterone and dihydrotestosterone after binding to cellular androgen

receptors set complex secondary reactions that signal the cell to produce growth factors resulting in hyperplastic growth of prostate. High amounts of 5-alpha reductase enzyme activity that convert testosterone to dihydrotestosterone (active form of androgen in prostate) in prostate as well as abundance of estrogen receptor are responsible for BPH prostates.^[7-14]

Table 3: Anti-inflammatory activity of Ativish

Group	Dose mg/kg orally	Mean of % inflammation and increase in paw volume			
		1 h	2 h	3 h	4 h
Control	-	45.6±3.7	67.5±3.8	87.4±4.0	88.7±4.3
Ativish	180	43.5±0.9	64.4±1.8	75.1±2.0*	72.1±1.8*
Ativish	360	37.9±3.8	53.7±3.3*	67.3±5.0*	65.4±4.8*
Daruhalad	500	30.0±3.5*	54.7±5.2	68.7±3.3*	67.3±3.3*
Daruhalad	1000	32.2±3.4*	46.5±4.5*	58.0±6.6*	55.7±6.5*
Tamala	270	34.5±3.1*	53.6±2.0*	70.3±1.9*	68.7±2.8*
Tamala	540	31.5±4.6*	49.1±4.9*	61.9±4.8*	59.4±4.9**
Indomethacin	10	17.9±3.1**	37.8±3.4**	39.6±5.0**	32.3±4.3**

n=6, Values are expressed as mean of % inflammation±S.E.M, **P*<0.05, ***P*<0.001 when compared with control group

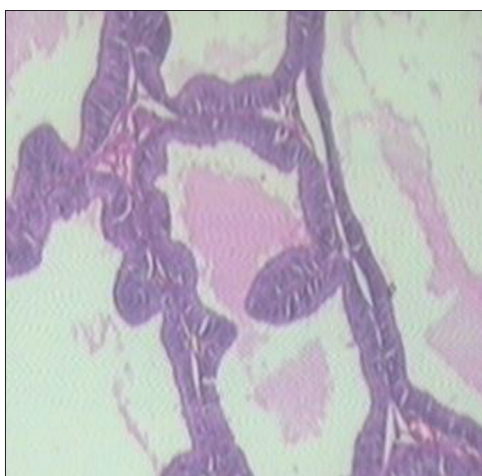


Figure 4: Standard Finasteride

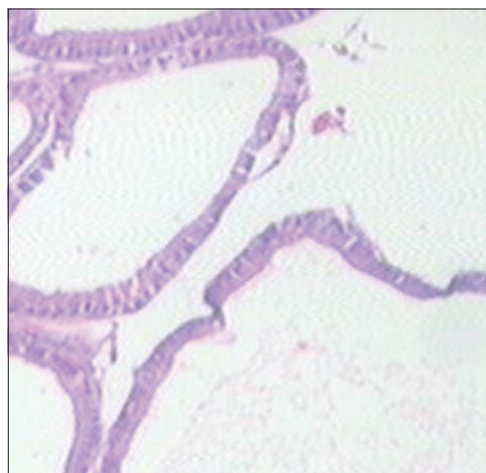


Figure 5: Tamala

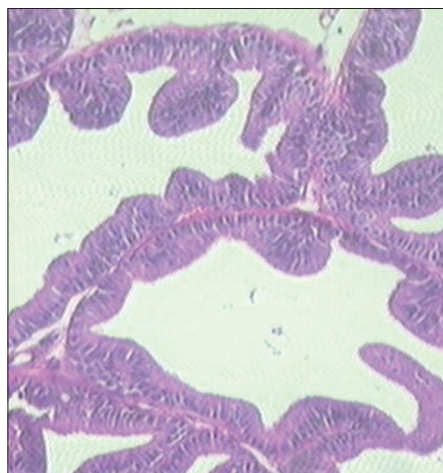


Figure 6: Daruhalad

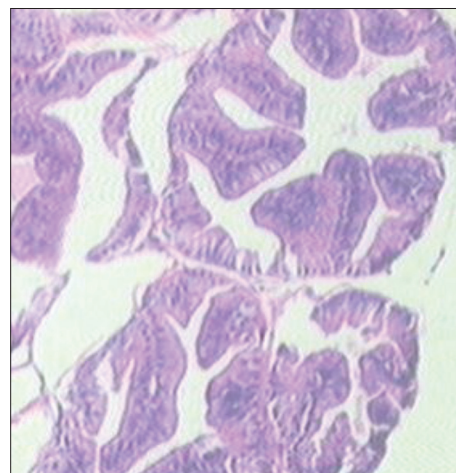


Figure 7: Ativish

Exogenous testosterone accelerate the growth of an immature prostate, castration prior to puberty prevents prostatic development and testosterone administration to castrated adult male rat causes the gland to grow to normal size.^[15] Castration of adult male rats causes extensive atrophy of prostate with induction of apoptosis, majorly of the ventral prostate epithelial cells.^[16] Further administration of testosterone exogenously to castrated rats caused suppression of apoptosis and prevents epithelial cell atrophy. Finasteride, an inhibitor of 5 α -reductase enzyme, reduced the testosterone-induced prostatic hyperplasia in rats. Tamala at doses of 270 mg and 540 mg/kg showed good dose response in reducing prostate size and improving hyperplastic changes induced by testosterone. Daruhalahad and Ativish did not show any significant effect in reducing prostate enlargement and hyperplasia induced by testosterone. The results are indicative of anti-androgenic activity and inhibition of proliferative processes in prostate.

Prostatic inflammation represents an important factor in influencing prostatic growth and progression of symptoms. Inflammatory mediators secreted by prostatic stromal cells is mediating low level, cumulative increase in proliferation of both epithelial and stromal cells that characterizes age-related development of BPH. Activation of CD4+ lymphocytes, prostate-specific antigen (PSA) and initiation of pro-inflammatory processes by presence of growth factors and cytokines, autoimmune mechanisms in prostate, oxidative stress by Nitric Oxide (NO) and other oxygen species, presence of COX (Cyclooxygenase) activity leads to activation of hyperproliferative pathways in prostate. COX-2 inhibition is reported to increase apoptotic activity in prostatic cell in human BPH tissue.^[17-22]

The use of carrageenan as an irritant agent to induce rat paw inflammation introduced by Winter *et. al.*^[23] and is one of the most popular methods for drug testing and evaluation of anti-inflammatory therapies.^[23,24] Carrageenan is believed to result from the action of locally released several mediators sequentially like histamine, serotonin and bradykinin in the initial phase (0-1 h), and an increase in the production of prostaglandins through the activation of cyclooxygenase-2 and release of nitric oxide in the later phase (1-6 h).^[25] Mild anti-inflammatory activity shown by powder of Tamala, Daruhalahad and Ativish in carrageenan-induced paw edema in rat is indicative of inhibition of Cox and Prostaglandin mechanisms, which are one of the factors in the growth of prostate.

CONCLUSION

The study concludes that Tamala may benefit in prostate disorder by virtue of inhibition of androgen mechanisms in

prostate as well as modulation of inflammatory mediators in prostate. Although Daruhalahad and Ativish are important Ayurvedic drugs included in many formulations or used individually in many related disorders, they are found to be ineffective in this model while their mild anti-inflammatory property may benefit when used as component of formulation.

ACKNOWLEDGEMENT

We authors are thankful to Dr. Kishori Apte and Mr. Yogesh Talekar, APT Research Foundation, Pune for Technical guidance for pharmacological work. Dr. Avinash Pradhan, MD Pathology for carrying out histopathological study

REFERENCES

1. Navre KR, Panshikar LV, Soman KV, editors. Nighunturatnakar. Delhi: Published by Chaukhamba Sanskrit Prasthan; 2011; Part 2, p. 516-86, 631-37.
2. Tripathi B, editor. Charaka Samhita. Volume2, Varanasi: Published by Chaukhamba Surbharati Prakashan; 2011. p. 541-86.
3. Ghanekar BG, editor. Sushrut Samhita, Nidasthanam, Chapter 1-11. Pune: Meharchand Laxmandas; 1998. p. 1-71.
4. Published by Department of Ayush; Ministry of Health and family welfare, Govt of India. The Ayurvedic Pharmacopeia of India. 1st Ed, Part I. New Delhi: 2007; Vol I p. 27-8 153-4, Vol II.p. 34-6.
5. Guo QL, Ding QL, and Wu QZ. Effect of baicalein on experimental prostatic hyperplasia in rats and mice. Biol Pharm Bull 2004;27:333-7.
6. Chapter H. Analgesic, anti-inflammatory and anti-pyretic activity, In: Vogel HG, editor. Drug Discovery and Evaluation Pharmacological Assays. 2nd ed. New York: Springer-Verlag Berlin Heidelberg; 2002. p. 759-60.
7. Marengo SR, Chung LW. An orthotopic model for the study of growth factors in the ventral prostate of the rat: Effects of epidermal growth factor and basic fibroblast growth factor. J Androl 1994;15:277-86.
8. Levine AC, Ren M, Huber GK, Kirschenbaum A. The effects of androgen, estrogen, and growth factors on the proliferation of cultured fibroblast derived from human fetal and adult prostates. Endocrinology 1992;130:2413-9.
9. Russell PJ, Bennett S, Stricker P. Growth factor involvement in progression of prostate cancer. ClinChem1998;44:705-23.
10. Story MT, Hopp KA, Meier DA, Begun FP, Lawson RK. Influence of transforming growth factor beta 1 and other growth factors on basic fibroblast growth factor level and proliferation of cultured human prostate-derived fibroblasts. Prostate 1993;22:183-97.
11. Culig Z, Hobisch A, Cronauer MV. Regulation of prostatic growth and function by peptide growth factor. Prostate 1996;28:392-405.
12. Rosner W, Hryb DJ, Khan MS, Nakhla AM, Romas NA. Sex hormone-binding globulin: Anatomy and physiology of a new regulatory system. J Steroid Biochem Mol Biol 1991;40:813-20.
13. Nakhla AM, Romas NA, and Rosner W. Estradiol activates the prostate androgen receptor and prostate-specific antigen secretion through the intermediacy of sex hormone-binding globulin. J Biol Chem 1997;272:6838-41.
14. Farnsworth WE. Roles of estrogen and SHBG in prostate physiology. Prostate 1996;28:17-23.

15. Griffiths K. Molecular control of prostate growth. In: Kirby R, McConnell JD, Fitzpatrick JM, Roehrborn CG, Boyle P, editors. Textbook of Benign prostatic hyperplasia. London: Oxford; 1996. p. 23-55.
16. Colombel M, Buttyan R. Hormonal control of apoptosis: The rat ventral prostate gland as a model system. *Methods Cell Biol* 1995;46:369-85.
17. Hamid AR, Umbas R, Mochtar CA. Recent role of inflammation in prostate diseases: Chemoprevention development opportunity. *Acta Med Indones* 2011;43:59-65.
18. Chughtai B, Lee R, Te A, Kaplan S. Role of inflammation in benign Prostatic hyperplasia. *RevUrol* 2011;13:147-50.
19. Fibbi B, Penna G, Morelli A, Adorini L, Maggi M. Chronic inflammation in the pathogenesis of benign prostatic hyperplasia. *Int J Androl* 2010;33:475-88.
20. Sciarra A, Mariotti G, Salciccia S, Autran Gomez A, Monti S, Toscano V, *et al.* Prostate growth and inflammation. *J Steroid Biochem Mol Biol* 2008;108:54-60.
21. Kramer G, Marberger M. Could inflammation be a key component in the progression of benign prostatic Hyperplasia? *Curr Opin Urol* 2006;16:25-9.
22. Kramer G, Mitteregger D, Marberger M. Is Benign Prostatic Hyperplasia (BPH) an immune inflammatory disease? *Eur urol* 2007;51:1202-16.
23. Winter CA, Risley EA, Nuss GW. Carrageenan-induced edemas in hind paw of rat as an assay for anti-inflammatory drugs. *Proc Soc Exp Biol Med* 1962;3:544-7.
24. Colville-Nash PR, Gilroy DW. COX-2 and the cyclopentenone prostaglandins - A new chapter in the book of inflammation? *Prostaglandins Other Lipid Mediat* 2000;62:33-43.
25. Raghavendra V, Kulkarni SK. AT1 receptor antagonism enhances angiotensin-II facilitated carrageenan-induced paw oedema. *Clin Pharmacol* 2000;22:633-8.

Cite this article as: Dumbre RK, Kamble MB, Patil VR. Inhibitory effects by ayurvedic plants on prostate enlargement induced in rats. *Phcog Res* 2014;6:127-32.

Source of Support: Nil, **Conflict of Interest:** None declared.