

## Review

# Rare adipose disorders (RADs) masquerading as obesity

Karen L HERBST

Department of Medicine, University of California, San Diego and Veteran's Affairs San Diego Healthcare System, USA

Rare adipose disorders (RADs) including multiple symmetric lipomatosis (MSL), lipedema and Dercum's disease (DD) may be misdiagnosed as obesity. Lifestyle changes, such as reduced caloric intake and increased physical activity are standard care for obesity. Although lifestyle changes and bariatric surgery work effectively for the obesity component of RADs, these treatments do not routinely reduce the abnormal subcutaneous adipose tissue (SAT) of RADs. RAD SAT likely results from the growth of a brown stem cell population with secondary lymphatic dysfunction in MSL, or by primary vascular and lymphatic dysfunction in lipedema and DD. People with RADs do not lose SAT from caloric limitation and increased energy expenditure alone. In order to improve recognition of RADs apart from obesity, the diagnostic criteria, histology and pathophysiology of RADs are presented and contrasted to familial partial lipodystrophies, acquired partial lipodystrophies and obesity with which they may be confused. Treatment recommendations focus on evidence-based data and include lymphatic decongestive therapy, medications and supplements that support loss of RAD SAT. Associated RAD conditions including depression, anxiety and pain will improve as healthcare providers learn to identify and adopt alternative treatment regimens for the abnormal SAT component of RADs. Effective dietary and exercise regimens are needed in RAD populations to improve quality of life and construct advanced treatment regimens for future generations.

**Keywords:** adiposis dolorosa; Dercum's disease; lipedema; multiple symmetric lipomatosis; familial multiple lipomatosis; familial partial lipodystrophy; lymph; lymphatics

Acta Pharmacologica Sinica (2012) 33: 155–172; doi: 10.1038/aps.2011.153

## Introduction

Lifestyle-induced obesity in children and adults has reached epidemic proportions worldwide. In the United States (US), a third of adults aged 20 years and over are overweight, a third are obese, and over five percent are extremely obese<sup>[1]</sup>. The National Health and Nutrition Examination Survey and Pediatric Nutrition Surveillance System reported a tripling of the prevalence of obesity among US school-age children and adolescents over the past three decades<sup>[2]</sup>. Numerous published studies validate the weight loss efficacy of lifestyle changes that include decreased amounts and types of food, and improved exercise regimens. Medications used for the treatment of obesity are severely limited<sup>[3,4]</sup>. Bariatric surgery has been exceptional in its ability to induce weight loss and resolve the co-morbidities of obesity, though complications rates can be high<sup>[5]</sup>, many people are still obese by body mass index (BMI) after Roux-en-Y gastric bypass (RYGB)<sup>[6]</sup>, and weight regain occurs<sup>[7,8]</sup>.

This review aims to demonstrate lymphatic dysfunction as a component of rare adipose disorders (RADs) that increases the

amount and alters the location of subcutaneous adipose tissue (SAT) while resisting fat loss after lifestyle changes or bariatric surgery. Lipodystrophies are also discussed as they may be confused with rare adipose disorders (RADs).

## Non-lifestyle causes of obesity

### Lipodystrophies

Lipodystrophies or fat redistribution syndromes involve a primary lack or loss of SAT; however, increased SAT in other areas can be confused with lifestyle-induced obesity. Human immunodeficiency virus (HIV)-associated lipodystrophy, is well-known, but familial partial lipodystrophies are rare and therefore less well known, and can go undiagnosed for years or are never recognized. Acquired partial lipodystrophy, also rare, with a progressive and symmetrical lipoatrophy of SAT starting from the face and spreading to the upper part of the body, sparing the legs, can be confused with the RAD, lipedema, due to a disproportion between upper and lower body SAT (see below).

### Acquired lipodystrophies

#### Human immunodeficiency virus (HIV)-associated lipodystrophy

HIV-and highly active antiretroviral treatment (HAART)-associated lipodystrophy includes loss of SAT from the face,

\* To whom correspondence should be addressed.

E-mail karen.herbst@va.gov

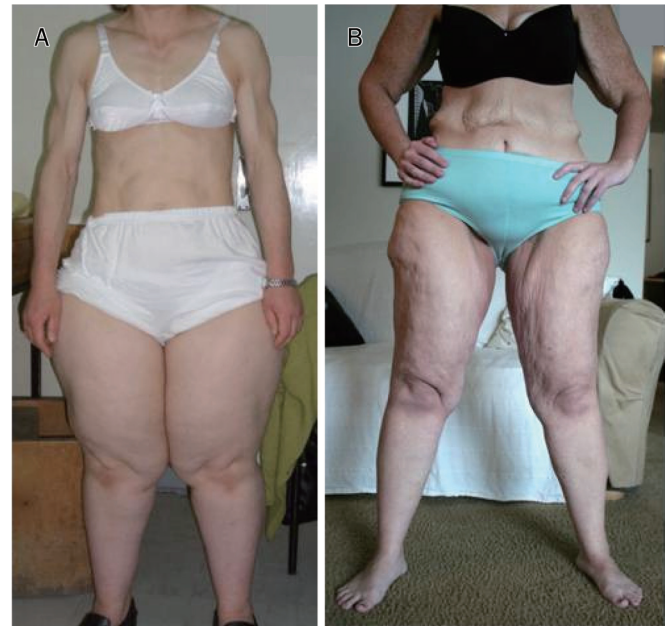Received 2011-08-31 Accepted 2011-10-12

buttocks, arms, and legs. In men with lipodystrophy, SAT can be increased on the abdomen and chest (gynecomastia), and a dorsocervical fat pad or “buffalo hump” is common<sup>[9, 10]</sup>. The SAT in the dorsocervical fat pad is thought to be identical to the SAT in multiple symmetric lipomatosis (MSL), one of the RADs (see below). Upper body fat, including parotid hypertrophy, circumferential enlargement of the neck and a dorsocervical fat pad are associated with insulin resistance in HIV+ men<sup>[11-13]</sup> as is intermuscular fat and SAT on the legs in HIV+ women<sup>[14]</sup>. Large breasts are part of HIV lipodystrophy in Black women and other non-Caucasian ethnicities<sup>[15]</sup>. Women with HIV may also develop increased SAT on the upper part of the arm out of context with the usual lipoatrophy in this area in HIV+ men suggesting an estrogen and/or progesterone component to location of the SAT. This upper arm SAT looks visually similar to the SAT in women with the RAD, MSL (see below and Figure 1). In addition to excision of excess SAT as treatment for lipodystrophy<sup>[16]</sup>, tesamorelin, a synthetic analogue of human growth hormone-releasing hormone, is FDA-approved for the reduction of excess visceral adipose tissue in HIV-infected patients with lipodystrophy. Visceral adipose tissue was reduced up to 18% during active use of tesamorelin<sup>[17]</sup>. The glucagon-like peptide-1 agonist, exenatide, also improved the HIV- and treatment-induced obesity through weight loss in a single case<sup>[18]</sup>.

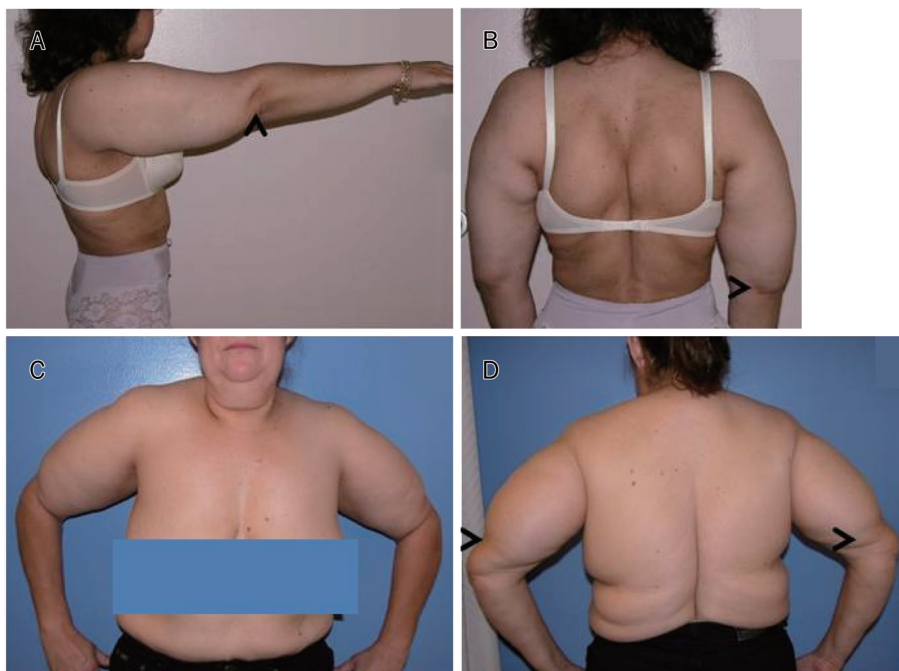
#### Acquired partial lipodystrophy (APL; BARRAQUER-SIMONS syndrome)

Acquired partial lipodystrophy is characterized by a regional loss of SAT primarily in children and adolescents starting at the face and extending to the waist, sparing the legs; in fact SAT may be increased on the legs<sup>[19]</sup>. Because of the higher amount of SAT in the legs compared to the upper body, APL

could be confused with the RAD, lipedema (Figure 2). In lipedema, there is increased fat on the legs but the fat of the upper body is normal or increased (see below). APL is thought to be autoimmune occurring after a febrile (viral) illness<sup>[20]</sup> with



**Figure 2.** Acquired partial lipodystrophy and lipedema. A, a 37 year old woman with acquired partial lipodystrophy. C3 level <math>< 16.1\text{ mg/dL}</math> (normal range: 90-180) and C4 level 23.11 mg/dL (normal range: 10-40). Note the loss of SAT from the upper body to the waist but obesity of the hips and legs (photo by Dr Alper GURLEK). B, a woman with lipedema stage II and a previous history of obesity with a 100 kg weight loss; note redundant skin on arms and abdomen from weight loss of non-RAD fat; note also lipedema in legs.



**Figure 1.** Multiple symmetric lipomatosis with or without HIV infection. A and B, non-HIV-related MSL Type II; note increased upper arm size and increased fat on back. Not shown is increased fat in the labia majora. C and D, increased arm and back fat, respectively in HIV- and HAART-induced MSL Type II. Arrows point to end of MSL fat on the upper arm. Normal labia majora (not shown).

low levels of complement factor 3 (C3) and the presence of a circulating autoantibody called complement 3-nephritic factor. Treatment with the thiazolidinedione, rosiglitazone, improved levels of C3 and increased SAT in a participant with APL<sup>[21]</sup>.

### Familial partial lipodystrophies (FPLD)

FPLD Type 1: FPLD1, also known as Köbberling lipodystrophy, is a lesser known partial lipodystrophy primarily found in women causing a lipodystrophy of the arms, legs, and sometimes breasts, with an increase in fat on the abdomen and remainder of the trunk<sup>[22]</sup>. The prevalence of FPLD1 and any genetic mutation remains unknown. There are no blood or urine biomarkers for FPLD1. FPLD1 may go unrecognized if the practitioner does not recognize the lipodystrophy; finding a ledge where SAT ends on the buttocks can help in the diagnosis. Diabetes and hypertriglyceridemia are highly prevalent in FPLD1 while acanthosis nigricans is minimal. Treatment is restricted to usual care of obesity-associated co-morbidities, although, RYGBP should be considered as it improved weight and co-morbidities in a case of FPLD1<sup>[23]</sup>.

FPLD Type 2: The best studied FPLD is Type 2 (FPLD2), also known as Dunnigan lipodystrophy. In FPLD2, SAT is lost around the time of puberty from the legs, arms, buttocks, abdomen and chest; areas of remaining SAT deposits are on the back, face and chin, giving a Cushingoid appearance; fat is increased in the labia majora in women<sup>[24]</sup>; this finding also occurs in women with MSL (Figure 1). Mutations in the lamin A and C gene, LMNA, cause FPLD2<sup>[25]</sup>. People with FPLD2 have all the co-morbidities associated with obesity. Leptin levels can be very low in lipodystrophies and leptin treatment has shown benefit but remains investigational<sup>[26]</sup>. RYGB has also shown benefit in reducing the co-morbidities associated with FPLD2<sup>[27]</sup>.

FPLD Type 3: Mutations in the peroxisome proliferator-activated receptor gamma (PPARG) gene can cause partial lipodystrophy with abdominal obesity<sup>[28]</sup> known as FPLD3<sup>[29]</sup>; people with FPLD3 may look very similar to FPLD2. Treatment with thiazolidinediones may be useful in people with PPARG gene mutations<sup>[30]</sup> and other cases of FPLD without identified gene mutations<sup>[31]</sup>.

Additional lipodystrophies and single cases of additional types of FPLD have been well reviewed<sup>[19]</sup>.

### RADs

#### Multiple Symmetric Lipomatosis (Madelung's disease/syndrome; Launois Bensaude syndrome)

Multiple symmetric lipomatosis (MSL) is a rare syndrome (Table 1) originally described in 1846<sup>[32]</sup>, characterized by the painless, symmetrical accumulation of abnormal tumor-like SAT. The first systematic treatise was by the German surgeon Dr Otto Madelung who collected 30 cases and reported an additional 3 cases in 1888 under the name "Fetthals" or fat neck<sup>[33]</sup>, but the French Physicians Drs Pierre-Emile LAUNOIS and Raoul BENSAUDE gave prominence to and caused recognition of MSL by publishing a detailed account of 65 cases in 1898<sup>[34]</sup>. There are many synonyms for MSL including

**Table 1.** Identifying codes or numbers for SAT Disorders.

Code or number	SAT disorder		
	MSL	DD	Lipedema
OMIM	151800	103200	614103
Listed by NORD	Yes	Yes	No
NLM MESH ID	D008069	D000274	NA*
ICD-9/10	272.8/E88.8	NA/E88.2	NA
Alternative ICD-9/10	NA	338.4/G89.4	457.1/189.0
		Chronic pain syndrome	Lymphedema, not elsewhere classified
Orphanet number	2398	36397	77243

ICD=International Classification of Diseases; MESH=medical subject headings; NLM=national Library of Medicine; NORD=National Organization of Rare Disease; OMIM=Online Mendelian Inheritance in Man®; \*Application for a MESH code submitted

benign symmetric lipomatosis but this disorder is anything but benign, arguing against its use. Over 300 adult cases are reported in the literature with an age range of 20–71 years. The early literature on MSL was dominated by research on alcoholic men with a reported incidence of 1/25 000 in the Italian population<sup>[35]</sup>. Non-alcoholics and women are also affected<sup>[36–38]</sup>; two cases have been reported in children<sup>[39, 40]</sup>.

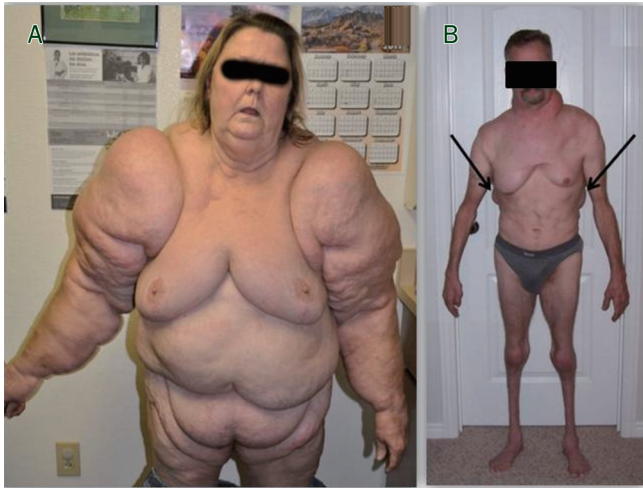
### Diagnosis

Identification of MSL is by history and clinical exam. There are no blood or urine biomarkers for MSL and the gene(s) remains unknown in a majority of cases. Individuals with MSL have increased SAT, either as discrete non-encapsulated lipomas or as a confluent increase in SAT in a symmetrical distribution on the neck, the back, the chest, the upper arms, or on the thighs; MSL usually spares the distal limbs<sup>[41]</sup> but not in many women with MSL where the altered fat may be global<sup>[42]</sup> (Figure 3). Because the appearance and location of SAT in MSL can vary, MSL has been divided into three types:

#### Clinical types of MSL<sup>[37, 43]</sup>

Type I, head and/or neck with extension down the back, or only on the back: In rare cases, MSL SAT can invade the lingual muscles of the tongue<sup>[44, 45]</sup>, or the vocal cords and compress the recurrent laryngeal nerve causing hoarseness<sup>[46]</sup>, or increase periorbital fat<sup>[47]</sup>. Tracheal or esophageal compression and the superior vena cava syndrome can be found in 15%–20% of patients<sup>[48]</sup>. The presence of a dorsocervical fat pad (buffalo hump) can be found both in MSL<sup>[41, 49, 50]</sup> and HIV-associated lipodystrophy<sup>[9, 10, 51, 52]</sup>; it has been proposed that the fat in these two disorders arises from brown adipose tissue located in that area<sup>[53]</sup>.

Type II body: Includes the shoulder girdle, the upper arms, the thorax, the back, the abdomen and upper buttocks. In one case, fat grew around the testicles in the scrotum and was contiguous with MSL tissue in the perineum and the root of the penis<sup>[54]</sup>. Also rare is growth of the MSL fat on the hands<sup>[55]</sup>.



**Figure 3.** Whole body MSL and MSL-associated lipodystrophy. While MSL is noted to spare the forearms (see text), the entire body can be clearly affected. A, 60 year old woman with a history of alcohol dependence with global MSL SAT; note prevalent SAT on the forearms (photo by Dr Andy COREN). This type of MSL may be easily confused with global obesity or lipedema stage III. B, 50 year old man with MSL Types I and II with associated muscle and normal fat atrophy (also note the increased back MSL SAT; arrows); this type of MSL may be confused with partial lipodystrophy.

Many individuals have a combination of Types II and III. While the MSL fat grows, normal fat and muscle can undergo wasting which can be confused with a partial lipodystrophy (Figure 3).

Type III, thigh (female type): Rarest type. MSL type III is clinically similar to and may be instead, the RAD, lipedema (see below). Women tend to have Type II and III MSL with widespread altered SAT<sup>[41]</sup>.

#### MSL inheritance

MSL is thought to be inherited through mitochondrial mutations in a few familial cases including multiple deletions of mitochondrial DNA, and the myoclonus epilepsy and ragged-red fibers (MERRF) tRNA(Lys) A>G(8344) mutation<sup>[56, 57]</sup>. Klopstock *et al* found mitochondrial mutations in only 2 of 12 patients studied<sup>[50]</sup>. Chalk *et al* found no mitochondrial pathology or mutations in four siblings with MSL with a pattern favoring autosomal recessive<sup>[58]</sup>. The phenotype of MSL may require a combined effect of alcohol (or other insult) and a currently unknown genetic mutation.

#### Histology of MSL fat

Individual fat cells have been described as smaller than normal<sup>[38, 49, 59]</sup> or normal sized<sup>[38]</sup>. MSL SAT is thought to be derived from brown adipose tissue (BAT) or as white adipose tissue (WAT) that transdifferentiates into BAT<sup>[49, 60, 61]</sup>. Ultrastructurally, brown adipocytes have numerous large mitochondria packed with cristae. Under light microscopy, brown adipocytes have cytoplasmic lipids arranged as numer-

ous small droplets (multilocularity), while white adipocytes have cytoplasmic lipids arranged in a unique vacuole (unilocularity). In BAT, the metabolic reactions of mitochondria are uncoupled from ATP synthesis by uncoupling protein (UCP)-1 so that energy produced is released as heat<sup>[62]</sup>. Infants and even adolescents have a substantial amount of BAT, especially between the shoulder blades. BAT persists throughout adulthood in the perirenal, omental, mesenteric, pericardial, intercostal, axillary, cervical, and interscapular fat, embedded within WAT<sup>[63, 64]</sup> with an approximated ratio of 1 brown adipocyte for every 200 white adipocytes<sup>[65, 66]</sup>.

By light microscopy, adipocytes in MSL SAT are monovacuolar<sup>[67, 68]</sup> or multivacuolar<sup>[69]</sup>. By electron microscopy of long-term primary cultures from the stromal vascular fraction (SVF), containing stem and immune cells, cells were polymorphic with thin microfilaments suggestive of elevated metabolic activity<sup>[69]</sup>, were multivacuolar, and had large mitochondria packed with cristae suggesting a more BAT phenotype in MSL<sup>[60, 68]</sup>.

#### Physiology of MSL SAT

MSL SAT may arise from a stem cell population either destined to form BAT, or WAT that transdifferentiates to BAT; in either case, UCP-1 levels help track BAT features. SAT cells from subjects with MSL express UCP-1 suggesting its origin as BAT<sup>[61, 70]</sup>, but this is not substantiated in all cases<sup>[71]</sup>. Adrenergic receptors (AR) that respond to sympathetic input, such as the three subtypes of  $\beta$ -AR,  $\beta_1$ -,  $\beta_2$ - and  $\beta_3$ -, promote lipolysis and energy expenditure. Cells isolated from the MSL SVF did not increase UCP-1 in response to noradrenaline even though MSL cells express all three  $\beta$ -AR<sup>[61]</sup>. Resting energy expenditure (REE) may be expected to be higher in MSL with BAT; indeed REE when normalized to fat free mass was mildly higher in MSL subjects than normal, suggestive of energy uncoupling and heat generation<sup>[72]</sup>, however, REE in other subjects with MSL was within normal limits<sup>[38]</sup>. In MSL cell culture, catecholamines did not increase lipolysis, expression of inducible nitric oxide synthase (iNOS) or PPAR $\gamma$  coactivator-1 $\alpha$  (PGC-1 $\alpha$ ), a coregulator of nuclear receptors that control metabolic pathways in BAT<sup>[61, 73-75]</sup>. Two other groups found a normally reactive adenylate cyclase system and a normal number of  $\alpha$ - and  $\beta$ -adrenergic receptors in MSL SAT<sup>[76, 77]</sup>. Cytokine and adipokine levels in MSL are also mixed<sup>[37, 61]</sup>. While the multilocularity of MSL SAT is suggestive of BAT, more data in a larger number of subjects of well characterized participants are needed to substantiate the cell type of origin and functionality of pathways.

The increase in MSL fat is extensive and deforming, compressing tissue structures and vessels. Early, MSL SAT is watery but later becomes fibrotic and scars easily<sup>[78]</sup>. Similarly in obesity, excess fat physically impedes lymph collection and flow, protein-rich lymphatic fluid collects in SAT, resulting in lymphedema and tissue hypoxia<sup>[79]</sup>. SAT also grows in the presence of lymphedema<sup>[80]</sup>. Further accumulation of fluid in the setting of decreased oxygen tension leads to fibrosis<sup>[81]</sup>. Interestingly, ischemia activates the growth of adipose-

derived progenitor cells<sup>[82]</sup>. Congestion of lymph nodes by other means, such as lymphoma in the neck, induces fat growth similar to MSL<sup>[83]</sup>. Increased volumes of SAT in MSL, like obesity, may therefore be sufficient to externally compress vasculature and lymphatics inducing further growth of SAT as seen in other localized fat collections<sup>[84]</sup>. Impedance of lymph flow into lymph collectors is a local effect and does not affect flow in larger lymph trunks, therefore the role of lymphoscintigraphy in MSL is questionable<sup>[85]</sup>.

#### **Conditions associated with MSL**

Alcohol-induced liver disease is common in MSL. Hyperlipidemia, hyperuricemia, hypothyroidism, and diabetes mellitus have been reported but are not consistent amongst those affected<sup>[86, 87]</sup>. People with MSL I or II should be tested for sleep apnea<sup>[87]</sup>. Cancerous transformation of the SAT is uncommon; development of myxoid liposarcoma was reported in one case<sup>[88]</sup>. Slowly progressive axonal sensory and autonomic peripheral neuropathies have been reported to occur after the development of MSL fat and impairment of autonomic function has been suggested as a cause of sudden death<sup>[86, 89]</sup>. The neuropathology is a distal axonal demyelination different from that associated with alcohol intake<sup>[58, 86, 90]</sup>; this impairment seems to be prevalently parasympathetic<sup>[48, 91]</sup>. In a ten year follow-up, ~10% of 31 patients died from sudden death due to autonomic neuropathy<sup>[36]</sup>. Surgical placement of a cardiac pacemaker may be needed.

#### **MSL treatment recommendations**

##### Primary recommendations

1) Alcohol abstinence: Abstinence from alcohol may arrest further progression of the MSL SAT but does not cause regression of the SAT deformities<sup>[92]</sup>.

2) Lymphatic decongestive therapy (LDT): Includes manual lymphatic drainage (MLD), wrapping of the limbs, compression garments, exercise such as pool therapy and other non-impact exercise (so as to avoid lactic acid accumulation in tissue due to poor lymph flow), dietary recommendations, and skin care. Manual lymphatic drainage works well to reduce MSL SAT before fibrosis<sup>[93]</sup>.

3) Surgery: Surgical resection and liposuction provide the only means of dramatically decreasing the MSL SAT<sup>[94-97]</sup>. In a majority of cases of MSL Type II and III, resection or liposuction of the lipomatosis is considered cosmetic and insurance companies are reluctant to cover this procedure<sup>[98]</sup>. Unfortunately, the fat usually penetrates and surrounds deeper structures such as muscle and bone, making total excision of the abnormal tissue difficult<sup>[92]</sup>; the lipomatosis can, therefore, recur after liposuction or excision<sup>[87, 99, 100]</sup>; in three of eleven patients in one series<sup>[101]</sup>.

##### Additional considerations for MSL treatment

4)  $\beta_2$ -Adrenergic Agonist: After demonstrating an intact lipolytic response of the MSL fat to catecholamines, an oral  $\beta_2$ -AR specific drug, salbutamol, 15 mg per day in divided doses, reversed the rapid accumulation of the MSL fat and increased

REE in a man with MSL, but was effective only during active use<sup>[102]</sup>.

5) Fibric acid: A man with MSL Type II with a past history of hypertriglyceridemia was treated with fenofibrate 200mg daily. The circumference of his abdomen decreased 119 cm (46.9 in) to 108 cm (42.7 in) within a year. Fibric acids are PPAR $\alpha$  agonists. Activation of the PPAR $\alpha$  receptor may suppress expression of proteins involved in the architecture of BAT, thereby maintaining BAT in a quiescent state<sup>[103]</sup>.

6) Growth hormone: Growth hormone (GH) treatment has been suggested in the community of individuals with MSL as a treatment option (personal communication) but GH levels were normal in one subject with MSL during a glucose tolerance test<sup>[49]</sup> and in three other subjects<sup>[104]</sup> suggesting a normal GH axis. Testing for GH deficiency should be undertaken and replacement considered only for those deficient in this hormone.

7) Lifestyle: Lifestyle improvements provide no resolution of the MSL SAT<sup>[105]</sup>.

8) Local SAT injections: Corticosteroid injections have been suggested as treatment for lipomatosis such as MSL SAT<sup>[106]</sup> but there are a number of cases demonstrating the development of lipomatosis after steroid use<sup>[107, 108]</sup>. Local injection with thyroxine<sup>[107]</sup>, enoxaparin<sup>[109]</sup>, deoxycholate<sup>[110]</sup>, and phosphatidylcholine<sup>[78]</sup> have also been proposed for treatment of lipomas but the latter require multiple injections and use of thyroxine injections in the presence of autonomic dysfunction would be dangerous. In addition, the extent of the SAT in MSL does not allow for single site injections, limiting these treatments to lipomas.

#### ***Lipedema (lipoedema; lipalgia; adiposis dolorosa; lipomatosis dolorosa of the legs; lipohypertrophy dolorosa; painful column leg)***

Lipedema is generally unknown to medical providers, is easily confused as obesity, does not have a MESH term in the National Library of Medicine, and does not have an International Classification of Diseases (ICD) code; it does have an Online Mendelian Inheritance in Man code, and is recognized by Orphanet (a European website providing information about orphan drugs and rare diseases (Table 1). Drs Allen and Hines Jr from the Mayo clinic labeled this condition as lipedema in 1940<sup>[111]</sup>. Outside the US, lipedema is known as "lipoedema", meaning edema of the fat. This disorder is likely very common but underdiagnosed.

#### **Diagnosis**

The diagnosis of lipedema is made clinically by history, visual inspection and physical exam as extensive deposition of SAT between the iliac crest and the malleoli and approximately 30% of the time, on the arm<sup>[42]</sup>. When the fat is palpated, it will be tender and feel like round peas in a plastic bag or a "beanie baby"<sup>[111, 112]</sup>. Larger nodules, lumps, lipomas or angioliipomas may also be found in the SAT. There are no blood or urine biomarkers for lipedema and the gene(s) is unknown. The skin and SAT is thicker in lipedema compared

to healthy controls and muscle mass is not edematous as it is in lymphedema<sup>[113]</sup>. The skin is also less elastic and striae are common in lipedema.

In 1951, Wold, Hines and Allen analyzed 119 cases and provided the diagnostic criteria for lipedema<sup>[114]</sup>:

1) Almost exclusive occurrence in women developing by the third decade of life. Prevalence within the population remains grossly under diagnosed<sup>[115]</sup>. According to an epidemiologic study by Földi E and Földi M<sup>[116]</sup>, lipedema affects 11% of the female population. At least seven cases have been reported in men with testosterone or GH deficiency, or liver disease<sup>[114, 115, 117]</sup>.

2) Bilateral and symmetrical nature with minimal involvement of the feet, resulting in an “inverse shouldering” or “bracelet” effect at the ankle

3) Minimal pitting edema (non-pitting edema is present)

4) Pain, tenderness, and easy bruising

5) Persistent enlargement despite elevation of the extremities or weight loss

6) Increased vascular fragility; easy bruising

Often women note that the lipedema appears or is exacerbated at the time of puberty, pregnancy<sup>[118]</sup> or menopause suggesting an estrogen component; that few men have this condition except those with hypogonadism or hyperestrogenemia supports this hypothesis.

#### There are five types of lipedema<sup>[119]</sup>

Type I: Pelvis, buttocks and hips (saddle bag phenomenon)

Type II: Buttocks to knees, with formation of folds of fat around the inner side of the knee

Type III: Buttocks to ankles

Type IV: Arms

Type V: Lower leg

There may be a mixture of lipedema types in one person, for example Type II and IV. Only the arms may be affected in 3% of lipedema cases (Type IV)<sup>[42]</sup>. The importance of knowing the different lipedema types is to improve recognition, and identification of differences *ie*, all people with lipedema do not

look alike; treatment is similar amongst the types. In addition to types of lipedema, the lipedema progresses through stages; the progression varies greatly amongst those affected and there is no data suggesting everyone need progress through all stages.

#### There are three stages of lipedema (Figure 4)<sup>[112, 120]</sup>

Stage 1: Normal skin surface with enlarged hypodermis

Stage 2: Uneven skin with indentations in the fat<sup>[121]</sup>; larger mounds of tissue grow as unencapsulated masses, lipomas and angioliipomas

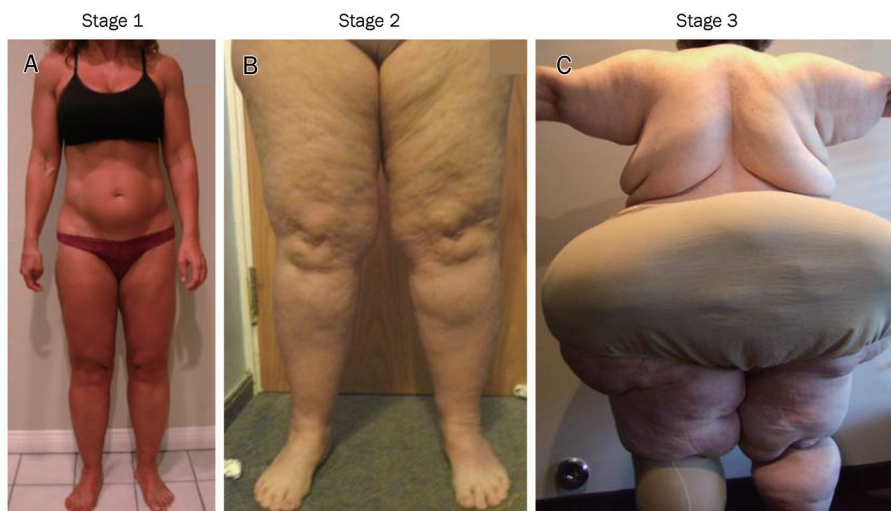
Stage 3: Large extrusions of tissue causing deformations especially on the thighs and around the knees

Stage 4: Lipedema with lymphedema (lipolymphedema)

Progression to lipolymphedema can develop during stage II-III. The description and representative pictures of Type III MSL<sup>[41]</sup> are that of lipedema stage II<sup>[38]</sup>; no study has formerly differentiated these two SAT disorders. Synonyms for lipedema also include adiposis dolorosa, which is another name for the RAD, Dercum’s disease (see below). However, according to Cornely, the trunk, hands and feet are not involved in lipedema “Thus, lipedema differs clearly from Dercum’s disease”<sup>[122]</sup>. As lipedema progresses to lipolymphedema, the hands, feet, trunk and head develop excess SAT making this statement incorrect. Because lymphatic dysfunction is a part of Dercum’s disease and many early cases of Dercum’s disease are visually and descriptively lipedema (see below), the two SAT disorders are at a minimum, in the same spectrum. Lipedema may also be confused with APL, however, in APL there is a lack of SAT on the face and upper body while in lipedema, SAT is normal or increased in these areas (Figure 1).

#### Inheritance of lipedema

Inheritance has been noted up to 60% of people with lipedema<sup>[118, 123, 124]</sup> but is likely higher due to under diagnosis. In six families over three generations with lipedema, the inheritance pattern was autosomal dominant with incomplete



**Figure 4.** The three stages of lipedema. A, Stage I with little alteration of the skin surface. B, In stage 2, the surface of the skin takes on the appearance of a mattress with lipomas in the fat. C, In stage III lipedema, there are much larger fat extrusions.

penetrance<sup>[115]</sup>.

### **Histology of lipedema SAT**

The gross description of the fat in lipedema is similar to that of MSL with “free fluid fat” in biopsy specimens<sup>[125]</sup>. Histological exam is not unlike that found for cellulite with dilation of subdermal blood capillaries, perivascular cells, fibrosis of arterioles, fibrosis and dilation of venules, and hypertrophy and hyperplasia of adipocytes<sup>[126, 127]</sup>. Histochemical studies show adipocytes death and stem cell regeneration<sup>[128]</sup>. There are also increased numbers of blood vessels especially capillaries and prominent venules<sup>[116]</sup>. Large clusters of macrophages are found around multiple fat cells (not isolated crown-like structures<sup>[129]</sup>), surrounding blood vessels and forming oil cysts in lipedema SAT<sup>[116, 130]</sup>; macrophages may also be a prominent component of cellulite<sup>[131]</sup>. The histology of lipedema SAT can also appear as normal<sup>[125]</sup>.

### **Physiology of lipedema SAT**

The elasticity of the skin and fascia is decreased in lipedema<sup>[132]</sup> which in Stage III may progress to abnormally clumped elastic fibers or pseudoxanthoma<sup>[133]</sup>. The skin loses its role as an abutment for the skeletal muscle venous pump and the increased compliance of the SAT results in an increase in capillary compliance<sup>[116, 124]</sup>. The permeable capillaries release excess protein-rich fluid into the interstitium along with blood<sup>[42, 116, 134, 135]</sup>. The veno-arteriolar reflex in lipedema is also absent so that under orthostatic conditions (standing), there is limited vasoconstriction and increased net filtration driving edema<sup>[116]</sup>. Early on, lymphatic transport increases to accommodate the increased fluid flux from the capillaries<sup>[136, 137]</sup>. During this time, visualization of lymphatic vessels on a gross level by lymphoscintigraphy is normal<sup>[138, 139]</sup>. As lipedema progresses, microaneurysms appear in the lymphatics in the skin<sup>[139, 140]</sup> which eventually leak<sup>[125, 136]</sup>. It is during this time that hypertrophy and hyperplasia of fat cells accelerates<sup>[138]</sup> further altering the microlymphatic architecture and increasing venous congestion. The resultant edema increases hydrostatic pressure in the tissue and pain<sup>[123, 141]</sup>.

As an example of what happens in SAT when lymph leaks, mutation of prospero homeobox protein 1, encoded by the PROX1 gene, causes leakage from lymphatics and resultant obesity in heterozygote mice<sup>[142]</sup>. Lymph placed on adipocytes in culture also induces robust growth; in essence, “lymph makes you fat”<sup>[143]</sup>. Although PROX1 mutations are not known to be associated with lipedema, it is clear that fat grows in response to lymph<sup>[80]</sup>. Eventually, the microlymphatics may become obliterated in lipedema<sup>[144]</sup> leading to backflow and an overall dynamic insufficiency of the lymphatic system<sup>[42]</sup>. The increased tissue pressure and lymphatic vessel leakage lead to the development of lipolymphedema<sup>[136, 145, 146]</sup>. While lipolymphedema does not usually develop with cellulite in women, the pathophysiology of cellulite development is similar to that in lipedema, and LDT (see treatments below) improves the cosmetic appearance of cellulite<sup>[147, 148]</sup>. Lipedema may therefore be an extreme form of cellulite.

### **Conditions associated with lipedema**

Depression and anxiety are very common in people with lipedema for many reasons including the lengthy time to diagnosis, repeated counseling on diet and exercise by the healthcare community when neither is particularly effective and because of the massive and sometimes rapid body metamorphosis over a lifetime. In one clinic, women with lipedema were found to be more depressed than patients with paralysis<sup>[112]</sup>. Painful SAT is a chronic problem in lipedema<sup>[111, 114]</sup>. The excess tissue fluid weakens nearby structures leading to the development of joint pains; with progression of lipedema, arthritis develops<sup>[149]</sup>. Capillary fragility, ecchymosis, hematomas and venous varicosities are common<sup>[150]</sup>. The Kaposi-Stemmer sign is negative in lipedema (the skin cannot be pinched as a fold by the fingers) until the development of lipolymphedema. Idiopathic edema (IE) is similar to lipedema by description and has been identified in women with lipedema<sup>[116, 134]</sup>. Other changes in skin include dryness, fungal infections, cellulitis, and slow wound healing. Free fatty acids may be different in both blood and the lipedema SAT<sup>[125]</sup>.

### **Lipedema treatments recommendations**

#### Primary recommendations

1) Lymphatic Decongestive therapy (LDT) is the standard of care for lipedema. Includes manual lymphatic drainage (MLD), wrapping of the limbs, compression garments, movement therapy, dietary recommendations, and skin care. LDT has been shown to improve skin elasticity, restore the veno-arteriolar reflex, increase pre-lymph drainage and lymph transport in lymphatic vessels<sup>[116, 151]</sup>, and reduce capillary fragility in lipedema<sup>[152]</sup>. Intermittent pneumatic compression may not improve limb size over MLD alone<sup>[153]</sup> but may be effective alone when MLD is not available<sup>[154]</sup>. Compression is most effective when tissue edema is present<sup>[155]</sup> as in its absence, it has little effect<sup>[156]</sup>. That compression was effective in lipedema was noted by Hines in a woman with lipedema whose fat and edema were absent under the area covered by her “high-topped shoes”<sup>[157]</sup>.

2) Exercise: Aqua lymphatic therapy (pool hydrotherapy) significantly reduces limb volume in lymphedema<sup>[158]</sup>. In addition to improving strength and bone mineral density, whole body vibration (WBV) improves peripheral circulation<sup>[159, 160]</sup> and increases lymph flow, raising the threshold level for edema formation in the legs<sup>[161]</sup>. During WBV, the user simply stands (or stretches/exercises) on a platform for 10-15 min. making this a very accessible exercise modality.

3) Pain Control: Must be individually optimized; liposuction improves pain (see below).

4) Psychological support: Many women with lipedema are left on their own to find their diagnosis, convince their healthcare providers about lipedema and then seek treatment, all complicated by depression, anxiety and eating disorders; counseling and support during treatment are necessary when any of these are present<sup>[116]</sup>. Counseling reduces anxiety by 50% in people with secondary lymphedema<sup>[162]</sup>.

5) Surgery: Liposuction works effectively for lipedema to

reduce SAT and pain<sup>[122, 163, 164]</sup>. In patients who have lipolymphedema, it may be prudent to undergo lymphoscintigraphy to confirm the absence of large lymph vessel damage before pursuing liposuction<sup>[116]</sup>. Bariatric surgery is ineffective in uncomplicated lipedema (without obesity or lymphedema)<sup>[165, 166]</sup> but effective in lipedema and lymphedema associated with obesity as long as LDT is performed before and after bariatric surgery<sup>[167]</sup>.

#### Additional considerations for lipedema treatment

6) Beta-adrenergic agonist: Modeling treatment after capillary leak syndrome, terbutaline sulfate, 5 mg five times daily, and theophylline, 200 mg twice daily, were given to a woman with lipedema (called lymphedema in the paper) and after 10 months a weight loss of 20 kg was noted. Cessation or lowering the medication allowed weight regain<sup>[168]</sup>.

7) Corticosteroids: Corticosteroids produce a fast reduction in swelling and pain but increase the risk of infection, capillary fragility and SAT growth. A series of corticosteroid joint injections is usually well-tolerated without exacerbation of lipedema.

8) Diuretics: Diuretics can quickly deplete lymphedema fluid but concentrate protein in edematous tissue promoting fibrosclerosis<sup>[169]</sup>. Use of diuretics in lipedema before lymphedema may result in the development of pseudo Barrter's syndrome characterized by hypokalemic-hypochloremic alkalosis, hyperactivity of the renin-angiotensin-aldosterone system and elevation of atrial natriuretic peptide<sup>[116, 170]</sup>.

9) Flavonoids: Daflon is a flavonoid that has been used to treat lymphedema<sup>[171-173]</sup>; it may be expensive and is unlikely available by prescription. Other flavonoids such as those for venous disease<sup>[174]</sup> have not been formerly tested in lipedema participants. The International Society of Lymphology does not endorse the use of flavonoids as a substitute for LDT.

10) Lifestyle: Obesity can occur along with lipedema especially in Stage III when the lipedema limits movement, but can also occur when movement is limited by pain in earlier stages; lifestyle improvements should always be considered but are not the cause of lipedema<sup>[175]</sup>. Lipedema SAT is unaffected by caloric restriction alone<sup>[175]</sup>.

11) Selenium: Sodium selenite (selenium) has proven effective for reduction of secondary lymphedema<sup>[169, 176-181]</sup>. The US National Research Council has defined the individual maximum safe dietary intake for selenium as 600 µg daily and the no adverse effect level as 800 µg daily.

12) Shock wave therapy: One report suggests that shock wave therapy functions similarly to LDT in reducing oxidative stress of the tissues and in smoothing the dermis and hypodermis<sup>[182]</sup> which may be useful as part of a treatment plan and when lymphatics are still functioning.

#### ***Dercum's disease (adiposis dolorosa; Morbus Dercums)***

Dercum's disease (DD) was recognized in 1892 as a clinical entity called "adiposis dolorosa", meaning painful fatty deposits, when Dr Francis X DERCUM from the University of Pennsylvania published on three cases<sup>[183]</sup>. This senti-

nel publication was preceded by a report of a single case in 1888<sup>[184]</sup> and followed by the published autopsy of that case<sup>[185]</sup>. Numerous case studies, case series and descriptions of DD have been published with such a wide variety of locations for the fatty deposits, including misdiagnoses of obvious cases of lipedema, familial multiple lipomatosis and MSL<sup>[186]</sup> that, unless one is an expert in SAT disorders, it would be difficult to diagnose this often misunderstood syndrome. DD is currently considered to be a rare disorder (Table 1).

#### ***Diagnosis***

Diagnosis of DD is made by history and physical exam. Dercum's disease occurs primarily in women with a ratio of females to males of 5-7:1<sup>[186-188]</sup>; the average age of development in one series was 35 years<sup>[188]</sup> but it has been reported to develop in children<sup>[188-191]</sup> and in adults up to age 80 years<sup>[186]</sup>. One in a 1,000 are affected in Sweden<sup>[187]</sup>. Many cases of peri- or post-menopausal women with DD have been reported suggesting a hormonal component to the development of DD<sup>[192]</sup>. In addition to painful SAT, there are many other signs and symptoms associated with DD so a lengthy review of systems is helpful (Table 2).

#### ***There are three types of DD***<sup>[187, 193]</sup>:

Type I, juxta-articular (around the joint): Painful folds or nodular fat on the inside of the knees and/or on the hips; in rare cases only evident in the upper-arm fat (similar to Type IV lipedema).

Type II, diffuse, generalized type: Widespread pain from fatty tissue found anywhere from head to the soles of the feet.

Type III, nodular type: Intense pain in and around multiple "lipomas", sometimes in the absence of obesity.

Interestingly, the painful lumps of fat first noticed around joints in DD Type 1 occur in locations of lymph nodes, for example around the knee (popliteal nodes), the elbow (cubital nodes), hips and thighs (inguinal nodes), upper arm (axillary nodes) and supraclavicular. As Dr Kling reported in 112 cases of Type I DD, "Juxta-articular adiposis dolorosa is regarded as the initial and intermediate stage of generalized adiposis dolorosa"<sup>[194]</sup>. Dercum's disease Type I is therefore, the first stage of DD, and Type II a stage with more widespread dysfunction. Type I DD around the knees is visually consistent with Type IV and Type II lipedema Stages 2-3.

Type III DD is likely a variant of familial multiple lipomatosis (FML) in which men present mainly with lipomas and/or angioliipomas predominating on the lower and upper arms, the lower trunk and thighs and women present with lipomas, angioliipomas and obesity<sup>[188, 195]</sup>. Angioliipomas can be found in up to 30% of people with DD<sup>[188, 196]</sup>. The lipomas are generally not painful in FML except if they are growing or traumatized frequently, however, they are painful in DD Type 3. In a DD family, family members may have lipomas without pain<sup>[195]</sup>. Even if a person with FML has non-painful lipomas, at some point in time a lipoma can become painful, followed by generalized pain in all lipomas. Pack and Ariel<sup>[197]</sup> described this as lipoma dolorosa, distinct from DD. It is



unclear why the authors make this distinction as others ascribe the same pathological process to both FML and DD Type III, with pain in the latter due to "local conditions"<sup>[198]</sup>. The "local conditions" may be increased tissue tension from fluid accumulation. In two cases of DD Type III, pain was relieved after local hemorrhage<sup>[186]</sup>. The underlying pathophysiology of DD needs to be elucidated to further differentiate or group the three types of DD.

DD inheritance: Thought to be autosomal dominant<sup>[188, 195, 199, 200]</sup>. In two families, females were more affected than males suggesting a sex-specific influence on the expression of the DD phenotype<sup>[195]</sup>.

### Histology of DD

Some of the unilocular adipocytes are extremely large in DD SAT compared to weight matched controls<sup>[187]</sup>. Dr Dercum and others found an infiltration of nerves (neuritis)<sup>[185, 201]</sup> but this has not been substantiated. Increased connective tissue around nerves, blood vessels and as thickened septae has been noted<sup>[185, 202, 203]</sup>. Perivascular cells<sup>[203]</sup>, giant cells<sup>[204]</sup>, and granulomas suggestive of a foreign body reaction are apparent in some areas<sup>[205]</sup>. The histology of DD SAT can also appear normal<sup>[194, 206-209]</sup>.

### Physiology of DD

The physiology of DD is unknown and many etiologies have been advanced. These include thyroid dysfunction<sup>[185]</sup>, pituitary dysfunction, polyglandular disease, infection, neuritis, alcohol, trauma, a defect in the synthesis of long chain fatty acids<sup>[205]</sup>, lower resting energy expenditure<sup>[202]</sup>, and altered responses to norepinephrine and insulin.<sup>210</sup> Ballet may have been closest to the actual etiology when he stated that it is a "chronic intoxication of endogenous origin"<sup>[211]</sup>. The evidence currently points to an underlying vascular and lymphatic dysfunction in DD Types I/ II similar to lipedema (Birgher Fagher, personal communication) for the following reasons:

1) Vascular dysfunction as hematemesis<sup>[212, 213]</sup>, epistaxis<sup>[213, 214]</sup>, hemochezia<sup>[212]</sup>, heavy menses<sup>[215, 216]</sup>, varicose veins<sup>[194]</sup>, and altered vasoconstrictor responses<sup>[217]</sup> is common in both lipedema and DD. Perivascular infiltration of immune cells have been found in DD tissue<sup>[218]</sup> suggesting damage to or repair of blood vessels, and brain vasculitis in DD has been reported<sup>[219]</sup>.

2) LDT has been reported to be beneficial in DD<sup>220</sup> as in lipedema.

3) Multiple lipomas can develop in lipedema as in DD<sup>[221]</sup>.

4) Fibrosis secondary to lymphedema<sup>[222]</sup> is common in lipedema<sup>[112]</sup> and DD<sup>[202]</sup>.

5) In the presence of lymphatic and vascular dysfunction in lipedema, the fat is painful<sup>[112]</sup>, similar to DD.

6) In the German literature, lipedema is known as adiposis dolorosa, another name for DD<sup>[118]</sup>.

7) Original descriptions of DD match descriptions of lipedema. For example, Spiller described a woman with painful fat as follows: "The obesity was marked over the thighs, calves, abdomen, nates (buttocks), and back. It was also very

great in the arms, less marked in the forearms, and absent in the feet and hands"<sup>[223]</sup>. Dr Collins noted that "The fatty accumulations have not been noticed in the hands, face or feet, and frequently the contrast between the feet which preserve their normal outline and contour and the legs, when the latter are involved, is most striking"<sup>[214]</sup>. These cases are similar to lipedema in terms of the pattern of painful fat (less likely early on in the hands, feet, face, and forearms) and the latter case describes well the distinct "bracelet" of fat seen at the base of the leg above the foot that is classic in lipedema<sup>[112]</sup>. The published photographs of the columnar legs with the cuff of fat above the foot, or the mass of tender fat inferomedial to the knee, and the enlarged upper arms in DD are consistent with lipedema<sup>[112, 183, 184, 224, 225]</sup>.

8) The nodular "beans in a bag" feel of the fat in lipedema is the same as in DD Types 1 and 2<sup>[188, 226]</sup>.

9) Dr Dercum described DD as a disorder of the "haemolymph system"<sup>[227]</sup> though the importance of these structures in humans is unclear. Hemolymph nodes are structures resembling a lymph node, but which can have blood in the sinuses; erythrocytes enter the hemolymph nodes through afferent lymphatics<sup>[228]</sup>. There are few reports on the function of hemolymph glands in humans.

10) Dr Mills reported "In one case studied carefully with Dr Dercum, there was a general disease of the lymphatic system"<sup>[229]</sup>.

The data suggest that the vascular and lymph system are dysfunctional in both lipedema and DD, that pre-lymph remains in the tissue longer, inducing fat growth and the characteristic beans in a bag feel to the fat. In both lipedema and DD there is a hereditary component<sup>[195, 199]</sup>. Also in both cases, estrogen and/or progesterone likely play a role resulting in the predominance of women with lipedema and/or DD; lipedema is known to occur with the onset puberty and pregnancy, and DD with menopause, both times of changing hormone levels. In DD, a more widespread insult to the vascular and lymphatic system may occur compared to lipedema. Many of the early reported cases of DD had syphilis<sup>[213, 216, 230]</sup>, well known to affect the lymph nodes, consumed alcohol<sup>[214, 231]</sup> which acutely increases mesenteric lymphatic pumping but decreases lymphatic myogenic tone<sup>[232]</sup>, or had antecedent trauma which may have affected lymphatic function<sup>[207, 213, 233]</sup>. Many patients with DD Type I or II noticed their first painful area of fat after a viral flu, severe pneumonia or trauma<sup>[188, 213, 234]</sup>. Data are needed on lymphatic function in DD to confirm these hypotheses.

### Conditions associated with DD

In addition to the two cardinal symptoms of fatty deposits and pain proposed by Dercum<sup>[184]</sup>, Vitaut added the third cardinal symptom of DD, asthenia (abnormal physical weakness or lack of energy)<sup>[193]</sup>. Accessory symptoms in DD are found in the psychiatric, motor, sensory and sympathetic nervous systems<sup>[186]</sup> as well as the pulmonary, endocrine, gastrointestinal and rheumatological systems<sup>[187, 188, 235]</sup> (Table 2).

Thyroid dysfunction has been suggested as one etiology of

**Table 2.** Cardinal and accessory signs and symptoms of Dercum's disease with checkbox.

Cardial Signs/Symptoms	Details	√
Fat deposits	Nodules (lipomas) in fat ranging in size from rice grains to a fist or larger	
Pain in fat deposits for at least 3 months	Pain exacerbated by stress, strenuous exercise, trauma, changes in weather, or other; pain can be spontaneous or on palpation; may wax and wane or move around	
Fatigue (asthenia)	Exacerbated by activities of daily living or exercise	
≥2 accessory symptoms		
Cognitive change(s)	Memory difficulties; difficulty forming thoughts; "brain fog"	
Weight gain	Difficult to lose fatty deposits with lifestyle changes	
Vascular involvement	Visible vascularity near lipomas; telangiectasias; multiple cherry angiomas, multiple petechiae; easy bruising; flushing; hematuria of unknown etiology; heavy or prolonged menstrual bleeding; epistaxis	
SAT edema	Non-pitting	
Gastrointestinal complaints	Gastroesophageal reflux disease, irritable bowel syndrome, bloating, abdominal pain, early satiety	
Joint pain and/or stiffness	Increased in areas of fat deposits	
Muscle pain/stiffness	Especially on awakening or the day after physical activity	
Shortness of breath	In the presence of normal oxygen saturation or as part of the need for oxygen supplementation	
Tachycardia	Varies from palpitations to supraventricular tachycardia requiring beta-blockade	

DD. While a few cases of DD benefited from thyroid treatment<sup>[216, 236]</sup> many cases of DD failed to improve<sup>[192, 215, 230, 237, 238]</sup> and DD generally continues to progress during adequate thyroid replacement<sup>[188]</sup>. Others have suggested multiple endocrine dysfunction as a cause for DD<sup>[201]</sup> (reviewed<sup>[186]</sup>) but ACTH and pituitary extract did not improve signs and symptoms associated with DD<sup>[192, 239]</sup> and hormone testing was normal in other cases<sup>[210, 240]</sup>. If hypercholesterolemia is present, severe and generalized vascular disease may be found<sup>[241]</sup>.

### DD treatment recommendations

#### Primary recommendations

1) Exercise: Similar to lipedema. Supporting the use of WBV as exercise in DD, WBV slowed the acquisition of fat in female rats<sup>[242]</sup> and improved pain and fatigue in women with fibromyalgia<sup>[243]</sup>.

2) LDT: LDT<sup>[220]</sup> and "massage"<sup>[225]</sup> are known to be beneficial for DD Types I and II; recommendations are similar to lipedema (see above).

3) Pain control: Must be individually optimized; only published or important anecdotal reports are included here:

(a) Chemotherapy: A patient with DD had improved pain and growth of DD SAT slowed on methotrexate combined with infliximab<sup>[244]</sup>. One case had resolution of her lipomas and pain with paclitaxel and carboplatin (unpublished); once the paclitaxel was discontinued because of neuropathy, the pain and lumps returned.

(b) Cyclic Variations in Adaptive Conditioning (CVACTM): A novel therapy that reduces tissue fluid by variable patterning of different atmospheric pressures around a person sitting in an altitude simulator. Peri-corporal pressure patterns vary from sea level to four sequential altitude levels: 3200 m (10.5K ft), 4419 m (14.5K ft), 5638 m (18.5K ft), and 6858 m (22.5K ft). This 'body conditioning' reduced fluid and pain in 10 DD participants<sup>[245]</sup> and improved VO<sub>2</sub>max in healthy men<sup>[246]</sup>.

(c) Lidocaine: Intravenous (IV) lidocaine has been used with some success to treat the intractable pain associated with DD<sup>[217, 247–253]</sup>. Many individuals with DD obtain good local pain relief using lidocaine patches, cream, gel or EMLA<sup>[248, 254]</sup>.

(d) Mexilitene: Mexilitene (an antiarrhythmic drug) has been used for the effective treatment of pain in DD<sup>[196]</sup>.

(e) Pregabalin: LDT combined with pregabalin (an anti-convulsant drug used for neuropathic pain) has been used to treat the pain associated with DD<sup>[220]</sup>.

4) Psychological support: See lipedema (above).

5) Surgery: Liposuction is one of the accepted methods of treatment for DD<sup>[196, 255–257]</sup> resulting in decreased pain<sup>[258, 259]</sup>. When asked specifically about liposuction in a series of 110 patients, 83 respondents (75.5%) reported having had liposuction; of these, 50.6% reported that the painful fat depots grew back<sup>[188]</sup>. Surgical resection and liposuction should be preceded by LDT and compression to support all vasculature and decrease the risk of seroma and hematoma formation. DD may be one reason why RYGBP without LDT failed to result in weight loss in a published case<sup>[260]</sup>.

#### Additional recommendations

6) Aminoacetic acid (glycine) and prostigmine: In three women with DD, a diet consisting of 70 grams protein, 70 grams of fat and 100 grams carbohydrate or 1500 calories/day (specifics unavailable), 10 grams glycine and 45 mg prostigmine daily improved weight loss and energy<sup>[261]</sup>. If glycine binding in the central nervous system is antagonized, feeding in rats increased<sup>[262]</sup>; glycine may therefore be an appetite suppressant while prostigmine improves asthenia.

7) Corticosteroids (oral): Cortisone treatment has been shown to help with pain but with none of the other features of DD<sup>[263]</sup>; cortisone treatment can also induce DD<sup>[264]</sup>. A series of corticosteroid joint injections is usually well-tolerated without exacerbation of symptoms and signs in DD.

8) Hormonal testing: Testing for thyroid function and assessing a complete panel of pituitary hormones at least once after diagnosis of DD and when symptoms change is prudent so as not to miss accompanying hormonal dysfunction, which should be treated with usual methods. Adipose tissue is a very hormonally responsive tissue<sup>[265]</sup>, so estrogen, progesterone and testosterone levels should be monitored regularly on any replacement regimen so as to regulate high and low levels and avoid wide fluctuations.

9) Lifestyle: While obesity is prominent in DD, the DD SAT is resistant to loss with lifestyle changes<sup>[261, 266]</sup> while normal SAT as part of obesity can be lost<sup>[261]</sup>.

10) Oxygen therapy: Many people with DD feel short of breath<sup>[188]</sup>. This can progress on to the need for continuous oxygen therapy. It is unclear why the shortness of breath occurs but it is likely a combination of increased interstitial fluid moving cells away from their oxygen source and a weakened diaphragm. Pulmonary function testing should be performed on everyone with DD that has shortness of breath even if it serves simply as a baseline for future changes or symptoms. Similar to MSL, if a patient has increased thickened fat around the chest or neuropathy, DD patients with shortness of breath and/or edema should be evaluated for thoracic outlet syndrome, sleep apnea and/or autonomic dysfunction.

Co-morbidities associated with obesity in DD are treated as usual.

## Conclusions

Obesity is very common and in the limited time allotted to patient care, it may be easy to misdiagnose a patient with a lipodystrophy or a RAD disorder as having simple obesity, and prescribe lifestyle changes only. The widespread increase in abnormal SAT in MSL, DD or lipedema Type II or III can easily masquerade as global obesity (Table 3). The loss of normal

fat and muscle in MSL or the disproportion of fat in lipedema can also be confused with lipodystrophy; lipedema Type I is usually overlooked. Lifestyle changes and bariatric surgery work effectively for the obesity component of FPLD and RADs but not for the abnormal SAT tissue in RADs. The RAD SAT likely results from the growth of a brown stem cell population that secondarily compresses lymphatics and vessels (in MSL) or a primarily vascular and lymphatic dysfunction with secondary growth of SAT (in lipedema and DD), neither of which respond well to caloric limitation. Academic testing of various dietary regimens, mechanical treatments, surgery, medications, and supplements is needed for RADs. Understanding the genomics of the RADs is also important to help differentiate lipedema, MSL and DD especially in women where the three disorders can look so much alike, and to assess for RADs in obesity. Improved recognition of RADs may also prove that lipedema and DD are not RADs at all but common disorders and that understanding the underlying pathophysiology of RADs may improve our understanding of refractory obesity. Lymphatic drainage methods used for RADs should be considered in resistant obesity cases or before bariatric surgery, low to very low calorie diets or other methods that induce rapid weight loss requiring optimal lymphatic function.

## Acknowledgements

This study received research support from the UCSD NIDDK Diabetes and Endocrinology Research Center Grant P30 DK063491 and the UCSD General Clinical Research Center by Public Health Grant 5M01RR000827. This paper is dedicated to people with RADs and to Birgher Fagher, MD, who died in April of 2011.

## Conflicts of interest

This study was approved by the University of California, San

**Table 3.** Comparison of RAD characteristics.

Characteristic	MSL	RADs	
		DD	Lipedema
Abnormal SAT location	Upper*	Global	Legs±Arms
Diet-resistant SAT	Yes	Yes	Yes
Lipomas	Common in males	Common	Large nodular fat masses
Time of SAT change	Adult	Child to adult	Puberty; by third decade
Painful SAT	Not usually	Yes	Yes
Sex predominance	Male	Female	Female
Lymphatic dysfunction	Secondary	Primary	Primary
Look-alike conditions	Obesity; HIV lipodystrophy	Obesity; FML	Obesity; APL
Associated conditions	Neuropathy	Autoimmune; diabetes	Lymphedema
Population frequency	Rare	Likely common	Likely common
Inheritance pattern	Autosomal dominant or recessive	Autosomal dominant; sex-specific influence	Autosomal dominant; incomplete penetrance
Known gene	tRNALys mutations uncommon	None	None
Known biomarkers	No	No	No
Alcohol association	Yes	No	No

\* Can be global especially in women; APL=acquired partial lipodystrophy; FML=familial multiple lipomatosis; RAD=rare adipose disorder; SAT=subcutaneous adipose tissue

Diego Human Research Protection Program and the Research and Development Committee at the Veterans Affairs San Diego Healthcare System. All subjects described herein completed an informed consent process prior to enrollment.

## References

- Ogden CL, Carroll MD. Prevalence of overweight, obesity, and extreme obesity among adults: united states, trends 1960–1962 through 2007–2008. <http://www.cdc.gov/nchs/fastats/overwt.htm>.
- Orsi CM, Hale DE, Lynch JL. Pediatric obesity epidemiology. *Curr Opin Endocrinol Diabetes Obes* 2011; 18: 14–22.
- James WP, Caterson ID, Coutinho W, Finer N, Van Gaal LF, Maggioni AP, *et al*. Effect of sibutramine on cardiovascular outcomes in overweight and obese subjects. *N Engl J Med* 2010; 363: 905–17.
- Sam AH, Salem V, Ghatei MA. Rimonabant: From RIO to Ban. *J Obes* 2011; 2011: 432607.
- Bobowicz M, Lehmann A, Orłowski M, Lech P, Michalik M. Preliminary outcomes 1 year after laparoscopic sleeve gastrectomy based on bariatric analysis and reporting outcome system (BAROS). *Obes Surg* 2011; 15.
- Butner KL, Nickols-Richardson SM, Clark SF, Ramp WK, Herbert WG. A review of weight loss following Roux-en-Y gastric bypass vs restrictive bariatric surgery: impact on adiponectin and insulin. *Obes Surg* 2010; 20: 559–68.
- Ray JB, Ray S. Safety, efficacy, and durability of laparoscopic adjustable gastric banding in a single surgeon U.S. community practice. *Surg Obes Relat Dis* 2011; 7: 140–4.
- D'Hondt M, Vanneste S, Pottel H, Devriendt D, Van Rooy F, Vansteenkiste F. Laparoscopic sleeve gastrectomy as a single-stage procedure for the treatment of morbid obesity and the resulting quality of life, resolution of comorbidities, food tolerance, and 6-year weight loss. *Surg Endosc* 2011; 25: 2498–504.
- Engelson ES. HIV lipodystrophy diagnosis and management. Body composition and metabolic alterations: diagnosis and management. *AIDS Read* 2003; 13: S10–14.
- Lo JC, Mulligan K, Tai VW, Algren H, Schambelan M. “Buffalo hump” in men with HIV-1 infection. *Lancet* 1998; 351: 867–70.
- Grunfeld C, Rimland D, Gibert CL, Powderly WG, Sidney S, Shlipak MG, *et al*. Association of upper trunk and visceral adipose tissue volume with insulin resistance in control and HIV-infected subjects in the FRAM study. *J Acquir Immune Defic Syndr* 2007; 46: 283–90.
- Mallon PW, Wand H, Law M, Miller J, Cooper DA, Carr A. Buffalo hump seen in HIV-associated lipodystrophy is associated with hyperinsulinemia but not dyslipidemia. *J Acquir Immune Defic Syndr* 2005; 38: 156–62.
- Tierney EP, Hanke CW. “Bullfrog neck,” a unique morphologic trait in HIV lipodystrophy: case series and review of the literature. *Arch Dermatol* 2007; 146: 1279–82.
- Albu JB, Kenya S, He Q, Wainwright M, Berk ES, Heshka S, *et al*. Independent associations of insulin resistance with high whole-body intermuscular and low leg subcutaneous adipose tissue distribution in obese HIV-infected women. *Am J Clin Nutr* 2007; 86: 100–6.
- Andany N, Raboud JM, Walmsley S, Diong C, Rourke SB, Rueda S, *et al*. Ethnicity and gender differences in lipodystrophy of HIV-positive individuals taking antiretroviral therapy in Ontario, Canada. *HIV Clin Trials* 2011; 12: 89–103.
- Abrams H, Herbst KL. Novel liposuction techniques for the treatment of HIV-associated dorsocervical fat pad and parotid hypertrophy. In: Serdev N, ed. *Advanced techniques in liposuction and fat transfer*. Vol In press. Rijeka, Croatia: InTech; 2011.
- Falutz J, Potvin D, Mamputu JC, Assaad H, Zoltowska M, Michaud SE, *et al*. Effects of tesamorelin, a growth hormone-releasing factor, in HIV-infected patients with abdominal fat accumulation: a randomized placebo-controlled trial with a safety extension. *J Acquir Immune Defic Syndr* 2011; 53: 311–22.
- Oriot P, Hermans MP, Selvais P, Buysschaert M, de la Tribonniere X. Exenatide improves weight loss insulin sensitivity and beta-cell function following administration to a type 2 diabetic HIV patient on antiretroviral therapy. *Ann Endocrinol* 2010; 72: 244–6.
- Garg A. Lipodystrophies: genetic and acquired body fat disorders. *J Clin Endocrinol Metab* 2011; 96: 3313–25.
- Kurugol Z, Ulger Z, Berk O, Tugral O. Acquired partial lipodystrophy associated with varicella. *Turk J Pediatr* 2009; 51: 617–20.
- Walker UA, Kirschfink M, Peter HH. Improvement of acquired partial lipodystrophy with rosiglitazone despite ongoing complement activation. *Rheumatology* 2003; 42: 393–4.
- Herbst KL, Tannock LR, Deeb SS, Purnell JQ, Brunzell JD, Chait A. Kobberling type of familial partial lipodystrophy: an underrecognized syndrome. *Diabetes Care* 2003; 26: 1819–24.
- Utzschneider KM, Trence DL. Effectiveness of gastric bypass surgery in a patient with familial partial lipodystrophy. *Diabetes Care* 2006; 29: 1380–2.
- Donadille B, Lascols O, Capeau J, Vigouroux C. Etiological investigations in apparent type 2 diabetes: when to search for lamin A/C mutations? *Diabetes Metab* 2005; 31: 527–32.
- Decaudain A, Vantyghem MC, Guerci B, Hécart AC, Auclair M, Reznik Y, *et al*. New metabolic phenotypes in laminopathies: LMNA mutations in patients with severe metabolic syndrome. *J Clin Endocrinol Metab* 2007; 92: 4835–44.
- Chong AY, Lupsa BC, Cochran EK, Gorden P. Efficacy of leptin therapy in the different forms of human lipodystrophy. *Diabetologia* 2009; 53: 27–35.
- McGrath NM, Krishna G. Gastric bypass for insulin resistance due to lipodystrophy. *Obes Surg* 2006; 16: 1542–4.
- Ludtke A, Buettner J, Wu W, Muchir A, Schroeter A, Zinn-Justin S, *et al*. Peroxisome proliferator-activated receptor-gamma C190S mutation causes partial lipodystrophy. *J Clin Endocrinol Metab* 2007; 92: 2248–55.
- Jeninga EH, van Beekum O, van Dijk AD, Hamers N, Hendriks-Stegeman BI, Bonvin AM, *et al*. Impaired peroxisome proliferator-activated receptor gamma function through mutation of a conserved salt bridge (R425C) in familial partial lipodystrophy. *Mol Endocrinol* 2007; 21: 1049–65.
- Ludtke A, Buettner J, Schmidt HH, Worman HJ. New PPARG mutation leads to lipodystrophy and loss of protein function that is partially restored by a synthetic ligand. *J Med Genet* 2007; 44: e88.
- Iwanishi M, Ebihara K, Kusakabe T, Chen W, Ito J, Masuzaki H, *et al*. Clinical characteristics and efficacy of pioglitazone in a Japanese diabetic patient with an unusual type of familial partial lipodystrophy. *Metabolism* 2009; 58: 1681–7.
- Brodie B. *Lectures illustrative of various subjects in pathology and surgery*. London, Longman; 1846.
- Madelung O. *Über den Fetthals*. *Langenbecks Archiv Klin Chirurg* 1888; 37: 106.
- Lanois P, F FB. *L'adipomatose symétrique*. *Bull Soc med Hop Paris* 1898; 1: 289.
- Enzi G, Biondetti PR, Fiore D, Mazzoleni F. Computed tomography of deep fat masses in multiple symmetrical lipomatosis. *Radiology* 1982; 144: 121–4.
- Enzi G, Busetto L, Ceschin E, Coin A, Digo M, Pigozzo S. Multiple symmetric lipomatosis: clinical aspects and outcome in a long-term

- longitudinal study. *Int J Obes Relat Metab Disord* 2002; 26: 253–61.
- 37 Harsch IA, Michaeli P, Hahn EG, Ficker JH, Konturek PC. Launois-Bensaude syndrome in a female with type 2 diabetes. *Med Sci Monit* 2003; 9: CS5–8.
- 38 Nielsen S, Levine J, Clay R, Jensen MD. Adipose tissue metabolism in benign symmetric lipomatosis. *J Clin Endocrinol Metab* 2001; 86: 2717–20.
- 39 Kratz C, Lenard HG, Ruzicka T, Gartner J. Multiple symmetric lipomatosis: an unusual cause of childhood obesity and mental retardation. *Eur J Paediatr Neurol* 2000; 4: 63–7.
- 40 Nounla J, Rolle U, Grafe G, Kraling K. Benign symmetric lipomatosis with myelomeningocele in an adolescent: an uncommon association-case report. *J Pediatr Surg* 2001; 36: E13.
- 41 Busetto L, Strater D, Enzi G, Coin A, Sergi G, Inelmen EM, et al. Differential clinical expression of multiple symmetric lipomatosis in men and women. *Int J Obes Relat Metab Disord* 2003; 27: 1419–22.
- 42 Herpertz U. Das lipödem. *Lymphologie* 1995; 19: 1–11.
- 43 Donhauser G, Vieluf D, Ruzicka T, Braun-Falco O. Benign symmetric Launois-Bensaude type III lipomatosis and Bureau-Barriere syndrome. *Hautarzt* 1991; 42: 311–4.
- 44 Ettl T, Gaumann A, Ehrenberg R, Reichert TE, Driemel O. Encapsulated lipomas of the tongue in benign symmetric lipomatosis. *J Dtsch Dermatol Ges* 2009; 7: 441–4.
- 45 Lopez-Ceres A, Aguilar-Lizarralde Y, Villalobos Sanchez A, Prieto Sanchez E, Valiente Alvarez A. Benign symmetric lipomatosis of the tongue in Madelung's disease. *J Craniomaxillofac Surg* 2006; 34: 489–93.
- 46 Birnholz JC, Macmillan AS Jr. Advanced laryngeal compression due to diffuse, symmetric lipomatosis (Madelung's disease). *Br J Radiol* 1973; 46: 245–9.
- 47 Laure B, Sury F, Tayeb T, Corre P, Goga D. Launois-Bensaude syndrome involving the orbits. *J Craniomaxillofac Surg* 2011; 39: 21–3.
- 48 Enzi G. Multiple symmetric lipomatosis: an updated clinical report. *Medicine (Baltimore)* 1984; 63: 56–64.
- 49 Kodish ME, Alsever RN, Block MB. Benign symmetric lipomatosis: functional sympathetic denervation of adipose tissue and possible hypertrophy of brown fat. *Metabolism* 1974; 23: 937–45.
- 50 Klopstock T, Naumann M, Seibel P, Shalke B, Reiners K, Reichmann H. Mitochondrial DNA mutations in multiple symmetric lipomatosis. *Mol Cell Biochem* 1997; 174: 271–5.
- 51 Carr A, Miller J, Law M, Cooper DA. A syndrome of lipoatrophy, lactic acidemia and liver dysfunction associated with HIV nucleoside analogue therapy: contribution to protease inhibitor-related lipodystrophy syndrome. *AIDS* 2000; 14: F25–32.
- 52 Heath KV, Hogg RS, Chan KJ, Harris M, Montessori V, O'Shaughnessy MV, et al. Lipodystrophy-associated morphological, cholesterol and triglyceride abnormalities in a population-based HIV/AIDS treatment database. *AIDS* 2001; 15: 231–9.
- 53 Urso R, Gentile M. Are 'buffalo hump' syndrome, Madelung's disease and multiple symmetrical lipomatosis variants of the same dysmetabolism? *Aids* 2001; 15: 290–1.
- 54 Poggi G, Moro G, Teragni C, Delmonte A, Saini G, Bernardo G. Scrotal involvement in Madelung disease: clinical, ultrasound and MR findings. *Abdom Imaging* 2006; 31: 503–5.
- 55 Yamamoto K, Ichimiya M, Hamamoto Y, Muto M. Benign symmetrical lipomatosis of the hands. *J Dermatol* 2000; 27: 748–9.
- 56 Klopstock T, Naumann M, Schalke B, Bischof F, Seibel P, Kottlors M, et al. Multiple symmetric lipomatosis: abnormalities in complex IV and multiple deletions in mitochondrial DNA. *Neurology* 1994; 44: 862–6.
- 57 Berkovic SF, Andermann F, Shoubridge EA, Carpenter S, Robitaille Y, Andermann E, et al. Mitochondrial dysfunction in multiple symmetrical lipomatosis. *Ann Neurol* 1991; 29: 566–9.
- 58 Chalk CH, Mills KR, Jacobs JM, Donaghy M. Familial multiple symmetric lipomatosis with peripheral neuropathy. *Neurology* 1990; 40: 1246–50.
- 59 Enzi G, Favaretto L, Martini S, Fellin R, Baritussio A, Baggio G, et al. Metabolic abnormalities in multiple symmetric lipomatosis: elevated lipoprotein lipase activity in adipose tissue with hyperalphalipoproteinemia. *J Lipid Res* 1983; 24: 566–74.
- 60 Zancanaro C, Sbarbati A, Morrioni M, Carraro R, Cigolini M, Enzi G, et al. Multiple symmetric lipomatosis. Ultrastructural investigation of the tissue and preadipocytes in primary culture. *Lab Invest* 1990; 63: 253–8.
- 61 Nisoli E, Regianini L, Briscini L, et al. Multiple symmetric lipomatosis may be the consequence of defective noradrenergic modulation of proliferation and differentiation of brown fat cells. *J Pathol* 2002; 198: 378–87.
- 62 Rial E, Nicholls DG. The mitochondrial uncoupling protein from guinea-pig brown adipose tissue. Synchronous increase in structural and functional parameters during cold-adaptation. *Biochem J* 1984; 222: 685–93.
- 63 Hany T, Gharehpapagh E, Kamel E, Buck A, Himms-Hagen J, von Schulthess G. Brown adipose tissue: a factor to consider in symmetrical tracer uptake in the neck and upper chest region. *Eur J Nuclear Med Mol Imaging* 2002; 29: 1393–8.
- 64 Seemayer TA, Knaack J, Wang NS, Ahmed MN. On the ultrastructure of hibernoma. *Cancer* 1975; 36: 1785–93.
- 65 Krief S, Lonnqvist F, Raimbault S, Baude B, Van Spronsen A, Arner P, et al. Tissue distribution of beta 3-adrenergic receptor mRNA in man. *J Clin Invest* 1993; 91: 344–9.
- 66 Oberkofler H, Dallinger G, Liu YM, Hell E, Krempler F, Patsch W. Uncoupling protein gene: quantification of expression levels in adipose tissues of obese and non-obese humans. *J Lipid Res* 1997; 38: 2125–33.
- 67 Morelli F, De Benedetto A, Toto P, Tulli A, Feliciani C. Alcoholism as a trigger of multiple symmetric lipomatosis? *J Eur Acad Dermatol Venereol* 2003; 17: 367–9.
- 68 Dwells AR, Plans AB, Sarasura JG. Cervical Lipomatosis. *Manual de Cirugía Plástica*. Vol 39: Sociedad de Espanola de Cirugía; 2000.
- 69 Cinti S, Enzi G, Cigolini M, Bosello O. Ultrastructural features of cultured mature adipocyte precursors from adipose tissue in multiple symmetric lipomatosis. *Ultrastruct Pathol* 1983; 5: 145–52.
- 70 Vila MR, Gamez J, Solano A, Playán A, Schwartz S, Santorelli FM, et al. Uncoupling protein-1 mRNA expression in lipomas from patients bearing pathogenic mitochondrial DNA mutations. *Biochem Biophys Res Commun* 2000; 278: 800–2.
- 71 Kazumi T, Ricquier D, Maeda T, Masuda T, Hozumi T, Ishida Y, et al. Failure to detect brown adipose tissue uncoupling protein mRNA in benign symmetric lipomatosis (Madelung's disease). *Endocr J* 1994; 41: 315–8.
- 72 Coin A, Sergi G, Enzi G, Busetto L, Pigozzo S, Lupoli L, et al. Total and regional body composition and energy expenditure in multiple symmetric lipomatosis. *Clin Nutr* 2005; 24: 367–74.
- 73 Dorigo P, Prosdociami M, Carpenedo F, Caparrotta L, Tessari F, Enzi G. Multiple symmetric lipomatosis. A defect in adrenergic stimulated lipolysis II. *Pharmacol Res Commun* 1980; 12: 625–38.
- 74 Enzi G, Inelmen EM, Baritussio A, Dorigo P, Prosdociami M, Mazzoleni F. Multiple symmetric lipomatosis: a defect in adrenergic-stimulated lipolysis. *J Clin Invest* 1977; 60: 1221–9.
- 75 Desai KS, Zinman B, Steiner G. Multiple symmetric lipomatosis

- (Launois-Bensaude syndrome) - adipose tissue insensitivity to cyclic AMP. *J Clin Endocrinol Metab* 1979; 49: 307–9.
- 76 Kather H, Schroder F. Adrenergic regulation of fat-cell lipolysis in multiple symmetric lipomatosis. *Eur J Clin Invest* 1982; 12: 471–4.
- 77 Pecquery R, Malagrida L, Giudicelli Y. Adipocyte adenylate cyclase and alpha- and beta-adrenergic receptors in one case of multiple symmetric lipomatosis. *Biomedicine* 1980; 33: 64–6.
- 78 Bechara FG, Sand M, Sand D, Rotterdam S, Stücker M, Altmeyer P, et al. Lipolysis of lipomas in patients with familial multiple lipomatosis: an ultrasonography-controlled trial. *J Cutan Med Surg* 2006; 10: 155–9.
- 79 Mogilevskii IL, Osmolovskaia NN, Deputovich SA. Microcirculatory disorders of the arm in post-mastectomy edema. *Sov Med* 1989; 15–20.
- 80 Brorson H, Ohlin K, Olsson G, Svensson B, Svensson H. Controlled compression and liposuction treatment for lower extremity lymphedema. *Lymphology* 2008; 41: 52–63.
- 81 Garcia Hidalgo L. Dermatological complications of obesity. *Am J Clin Dermatol* 2002; 3: 497–506.
- 82 Suga H, Eto H, Aoi N, Kato H, Araki J, Doi K, et al. Adipose tissue remodeling under ischemia: death of adipocytes and activation of stem/progenitor cells. *Plast Reconstr Surg* 2010; 126: 1911–23.
- 83 Becker ST, Wiltfang J, Klapper W, Repp R, Sinis N, Warnke PH. Massive swelling of the cervical region: an uncommon manifestation of B cell chronic lymphocytic leukemia. *Oral Maxillofac Surg* 2008; 12: 205–8.
- 84 Dwyer TM, Mizelle HL, Cockrell K, Buhner P. Renal sinus lipomatosis and body composition in hypertensive, obese rabbits. *Int J Obes Relat Metab Disord* 1995; 19: 869–74.
- 85 Vasileiou AM, Bull R, Kitou D, Alexiadou K, Garvie NJ, Coppack SW. Oedema in obesity; role of structural lymphatic abnormalities. *Int J Obes (London)* 2011; 35: 1247–50.
- 86 Pollock M, Nicholson GI, Nukada H, Cameron S, Frankish P. Neuropathy in multiple symmetric lipomatosis. Madelung's disease. *Brain* 1988; 111: 1157–71.
- 87 Chen XM, Li WY, Ni DF, Wei BJ, Xu CX, Gao ZQ, et al. Diagnosis and treatment of Madelung's disease. *Zhonghua Er Bi Yan Hou Tou Jing Wai Ke Za Zhi* 2006; 41: 524–7.
- 88 Tizian C, Berger A, Vykoupil KF. Malignant degeneration in Madelung's disease (benign lipomatosis of the neck): case report. *Br J Plast Surg* 1983; 36: 187–9.
- 89 Taylor LM, Beahrs OH, Fontana RS. Benign symmetric lipomatosis. *Proc Staff Meet Mayo Clin* 1961; 36: 96–100.
- 90 Uglesic V, Knezevic P, Milic M, Jokic D, Kosutic D. Madelung syndrome (benign lipomatosis): clinical course and treatment. *Scand J Plast Reconstr Surg Hand Surg* 2004; 38: 240–3.
- 91 Fedele D, Bellavere F, Bosello G, Cardone C, Girardello L, Ferri M, et al. Impairment of cardiovascular autonomic reflexes in multiple symmetric lipomatosis. *J Auton Nerv Syst* 1984; 11: 181–8.
- 92 Lee HW, Kim TH, Cho JW, Ryu BY, Kim HK, Choi CS. Multiple symmetric lipomatosis: Korean experience. *Dermatol Surg* 2003; 29: 235–40.
- 93 Foldi M, Foldi E. Benign symmetric lipomatosis. In: Foldi M, Foldi E, Strossenreither R, S K, eds. *Földi's textbook of lymphology Germany*: Elsevier, Urban & Fischer Verlag; 2007; p 430–31.
- 94 Guilemany JM, Romero E, Blanch JL. An aesthetic deformity: Madelung's disease. *Acta Otolaryngol* 2005; 125: 328–30.
- 95 Gonzalez-Garcia R, Rodriguez-Campo FJ, Sastre-Perez J, Munoz-Guerra MF. Benign symmetric lipomatosis (Madelung's disease): case reports and current management. *Aesthetic Plast Surg* 2004; 28: 108–12; discussion 113.
- 96 Verhelle NA, Nizet JL, Van den Hof B, Guelinckx P, Heymans O. Liposuction in benign symmetric lipomatosis: sense or senseless? *Aesthetic Plast Surg* 2003; 27: 319–21.
- 97 Martinez-Escribano JA, Gonzalez R, Quecedo E, Febrer I. Efficacy of lipectomy and liposuction in the treatment of multiple symmetric lipomatosis. *Int J Dermatol* 1999; 38: 551–4.
- 98 Faga A, Valdatta LA, Thione A, Buoro M. Ultrasound assisted liposuction for the palliative treatment of Madelung's disease: a case report. *Aesthetic Plast Surg* 2001; 25: 181–3.
- 99 Horl C, Biemer E. Benign symmetrical lipomatosis. Lipectomy and liposuction in the treatment of Madelung disease. *Handchir Mikrochir Plast Chir* 1992; 24: 93–6.
- 100 Smith PD, Stadelmann WK, Wassermann RJ, Kearney RE. Benign symmetric lipomatosis (Madelung's disease). *Ann Plast Surg* 1998; 41: 671–3.
- 101 Constantinidis J, Steinhart H, Zenk J, Bohlender J, Iro H. Surgical therapy of Madelung's disease in the head and neck area. *HNO* 2003; 51: 216–20.
- 102 Leung NW, Gaer J, Beggs D, Kark AE, Holloway B, Peters TJ. Multiple symmetric lipomatosis (Launois-Bensaude syndrome): effect of oral salbutamol. *Clin Endocrinol (Oxf)* 1987; 27: 601–6.
- 103 Zeitler H, Ulrich-Merzenich G, Richter DF, Vetter H, Walger P. Multiple benign symmetric lipomatosis — a differential diagnosis of obesity. Is there a rationale for fibrate treatment? *Obes Surg* 2008; 18: 1354–6.
- 104 Mirouze J, Orsetti A, Vidal F. Application of 2 radioimmunological methods for the determination of growth hormone. Application to various dysmorphic syndromes. *Ann Endocrinol (Paris)* 1970; 31: 237–46.
- 105 Harsch IA, Wiedmann R, Bergmann T, Hahn EG, Wiest GH. Unspecified gain of weight? *Internist (Berl)* 2005; 46: 1265–9.
- 106 Botwin KP, Sakalkale DP. Epidural steroid injections in the treatment of symptomatic lumbar spinal stenosis associated with epidural lipomatosis. *Am J Phys Med Rehabil* 2004; 83: 926–30.
- 107 McCullen GM, Spurling GR, Webster JS. Epidural lipomatosis complicating lumbar steroid injections. *J Spinal Disord* 1999; 12: 526–9.
- 108 Taille C, Fartoukh M, Houel R, Kobeiter H, Remy P, Lemaire F. Spontaneous hemomediastinum complicating steroid-induced mediastinal lipomatosis. *Chest* 2001; 120: 311–3.
- 109 Fischer M, Wohrlab J, Taube KM, Marsch WC. Intralesional injection of enoxaparin in benign symmetrical lipomatosis: an alternative to surgery? *Br J Dermatol* 2001; 144: 629–30.
- 110 Rotunda AM, Ablon G, Kolodney MS. Lipomas treated with subcutaneous deoxycholate injections. *J Am Acad Dermatol* 2005; 53: 973–8.
- 111 Allen EV, Hines EAJ. Lipedema of the legs: A syndrome characterised by fat legs and orthostatic edema. *Proc Staff Meet Mayo Clin* 1940; 15: 184–7.
- 112 Fife CE, Maus EA, Carter MJ. Lipedema: a frequently misdiagnosed and misunderstood fatty deposition syndrome. *Adv Skin Wound Care* 2010; 23: 81–92; 93–84.
- 113 Dimakakos PB, Stefanopoulos T, Antoniadis P, Antoniou A, Gouliamos A, Rizos D. MRI and ultrasonographic findings in the investigation of lymphedema and lipedema. *Int Surg* 1997; 82: 411–6.
- 114 Wold LE, Hines EA Jr, Allen EV. Lipedema of the legs; a syndrome characterized by fat legs and edema. *Ann Intern Med* 1951; 34: 1243–50.
- 115 Child AH, Gordon KD, Sharpe P, Brice G, Ostergaard P, Jeffery S, et al. Lipedema: an inherited condition. *Am J Med Genet A* 2010; 152A: 970–6.

- 116 Foldi E, Foldi M. Lipedema. In: Foldi M, Foldi E, eds. *Foldi's Textbook of Lymphology*. Munich (Germany): Elsevier GmbH; 2006. p417–27.
- 117 Chen SG, Hsu SD, Chen TM, Wang HJ. Painful fat syndrome in a male patient. *Br J Plast Surg* 2004; 57: 282–6.
- 118 Schmeller W, Meier-Vollrath I. Lipödem-aktuelles zu einem weitgehend unbekannter Krankheitsbild. *Aktuelle Dermatologie* 2007; 33: 1–10.
- 119 Meier-Vollrath I, Schneider W, Schmeller W. Das Lipodem: neue Möglichkeiten der Therapie. *Schweiz Med Forum* 2007; 7: 150–5.
- 120 Meier-Vollrath I, Schmeller W. Lipoedema – current status, new perspectives. *J Dtsch Dermatol Ges* 2004; 2: 181–6.
- 121 Pascucci A, Lynch PJ. Lipedema with multiple lipomas. *Dermatol Online J* 16(9): 4.
- 122 Cornely ME. Lipedema and Lymphatic Edema. In: Shiffman MA, Di Giuseppe A, eds. *Liposuction*. Berlin Heidelberg: Springer; 2006: 10–4.
- 123 Greer KE. Lipedema of the legs. *Cutis* 1974; 14: 98.
- 124 Földi E, Földi M. Das Lipödem. In: Földi M, Földi E, Kubik S, eds. *Lehrbuch der Lymphologie für Mediziner, Masseur und Physiotherapeuten*. Munich: Elsevier, Urban & Fischer; 2005; p 443–53.
- 125 Stallworth JM, Hennigar GR, Jonsson HT Jr, Rodriguez O. The chronically swollen painful extremity. A detailed study for possible etiological factors. *JAMA* 1974; 228: 1656–9.
- 126 Curri SB, Merlen JF. Microvascular disorders of adipose tissue. *J Mal Vasc* 1986; 11: 303–9.
- 127 Merlen JF, Curri SB, Sarteel AM. Cellulitis, a conjunctive microvascular disease. *Phlebologie* 1979; 32: 279–82.
- 128 Suga H, Araki J, Aoi N, Kato H, Higashino T, Yoshimura K. Adipose tissue remodeling in lipedema: adipocyte death and concurrent regeneration. *J Cutan Pathol* 2009; 3: 3.
- 129 Cinti S, Mitchell G, Barbatelli G, Murano I, Ceresi E, Faloia E, et al. Adipocyte death defines macrophage localization and function in adipose tissue of obese mice and humans. *J Lipid Res* 2005; 46: 2347–55.
- 130 Kaiserling E. Morphological changes in lymphedema and tumors. In: Foldi M, Foldi E, eds. *Foldi's Textbook of Lymphology*. Munich (Germany): Elsevier, GmbH; 2006: 322–90.
- 131 Kligman AM. Cellulite: facts and fiction. *J Geriatric Dermatol* 1997; 5: 136–9.
- 132 Jagtman BA, Kuiper JP, Brakkee AJ. Measurements of skin elasticity in patients with lipedema of the Moncorps "rusticanus" type. *Phlebologie* 1984; 37: 315–9.
- 133 Taylor NE, Foster WC, Wick MR, Patterson JW. Tumefactive lipedema with pseudoxanthoma elasticum-like microscopic changes. *J Cutan Pathol* 2004; 31: 205–9.
- 134 Szolnoky G. Chapter 17: Differential Diagnosis - Lipedema. In: Lee BB, Bergan J, Rockson SG, eds. *Lymphedema: A Concise Compendium of Theory and Practice*. London: Springer-Verlag; 2011. p125–35.
- 135 Wienert V, Leeman S. Lipedema. *Hautarzt* 1991; 42: 484–6.
- 136 Partsch H, Stoberl C, Urbanek A, Wenzel-Hora Bl. Clinical use of indirect lymphography in different forms of leg edema. *Lymphology* 1988; 21: 152–60.
- 137 Tiedjen KU, Schultz-Ehrenburg U. Isotopenlymphographische Befunde beim Lipödem. In: Holzmann H, Altmeyer P, Hör G, eds. *Dermatologie und Nuklearmedizin*. Berlin: Springer-Verlag; 1985. p432–438.
- 138 van Geest AJ, Esten SCAM, Cambier J-PRA, et al. Lymphatic disturbances in lipedema. *Phlebologie* 2003; 32: 138–42.
- 139 Amann-Vesti BR, Franzeck UK, Bollinger A. Microlymphatic aneurysms in patients with lipedema. *Lymphology* 2001; 34: 170–175.
- 140 Bollinger A, Amann-Vesti BR. Fluorescence microlymphography: diagnostic potential in lymphedema and basis for the measurement of lymphatic pressure and flow velocity. *Lymphology* 2007; 40: 52–62.
- 141 Harwood CA, Bull RH, Evans J, Mortimer PS. Lymphatic and venous function in lipoedema. *Br J Dermatol* 1996; 134: 1–6.
- 142 Harvey NL, Srinivasan RS, Dillard ME, Johnson NC, Witte MH, Boyd K, et al. Lymphatic vascular defects promoted by Prox1 haploinsufficiency cause adult-onset obesity. *Nat Genet* 2005; 37: 1072–81.
- 143 Schneider M, Conway EM, Carmeliet P. Lymph makes you fat. *Nat Genet* 2005; 37: 1023–4.
- 144 Bollinger A. Microlymphatics of human skin. *Int J Microcirc Clin Exp* 1993; 12: 1–15.
- 145 Brautigam P, Foldi E, Schaiper I, Krause T, Vanscheidt W, Moser E. Analysis of lymphatic drainage in various forms of leg edema using two compartment lymphoscintigraphy. *Lymphology* 1998; 31: 43–55.
- 146 Bilancini S, Lucchi M, Tucci S, Eleuteri P. Functional lymphatic alterations in patients suffering from lipedema. *Angiology* 1995; 46: 333–9.
- 147 de Godoy JM, de Godoy Mde F. Treatment of cellulite based on the hypothesis of a novel physiopathology. *Clin Cosmet Investig Dermatol* 4: 55–9.
- 148 Bayraktar Tunay V, Akbayrak T, Bakar Y, Kayihan H, Ergun N. Effects of mechanical massage, manual lymphatic drainage and connective tissue manipulation techniques on fat mass in women with cellulite. *J Eur Acad Dermatol Venereol* 2009; 24: 138–42.
- 149 Wenczl E, Daroczy J. Lipedema, a barely known disease: diagnosis, associated diseases and therapy. *Orv Hetil* 2008; 149: 2121–7.
- 150 Tsukanov Iu T, Tsukanov A. Syndrome of lower limb volume enlargement in varicosity: causes and medical approaches. *Angiol Sosud Khir* 2007; 13: 85–91.
- 151 Tan IC, Maus EA, Rasmussen JC, Marshall MV, Adams KE, Fife CE, et al. Assessment of lymphatic contractile function after manual lymphatic drainage using near-infrared fluorescence imaging. *Arch Phys Med Rehabil* 1992; 73: 756–764 e751.
- 152 Szolnoky G, Nagy N, Kovacs RK, Dósa-Rácz E, Szabó A, Bársony K, et al. Complex decongestive physiotherapy decreases capillary fragility in lipedema. *Lymphology* 2008; 41: 161–6.
- 153 Szolnoky G, Borsos B, Barsony K, Balogh M, Kemeny L. Complete decongestive physiotherapy with and without pneumatic compression for treatment of lipedema: a pilot study. *Lymphology* 2008; 41: 40–4.
- 154 Adams KE, Rasmussen JC, Darne C, Tan IC, Aldrich MB, Marshall MV, et al. Direct evidence of lymphatic function improvement after advanced pneumatic compression device treatment of lymphedema. *Biomed Opt Express* 2010; 1: 114–25.
- 155 Beninson J, Edelglass JW. Lipedema – the non-lymphatic masquerader. *Angiology* 1984; 35: 506–10.
- 156 Bauke J. Kritische Gegenüberstellung der verschiedenen Behandlungsmethoden der Adipositas. *Med Welt* 1983; 34: 201–3.
- 157 Hines EA Jr. Lipedema and physiologic edema. *Proc Staff Meet Mayo Clin* 1952; 27: 7–9.
- 158 Tidhar D, Katz-Leurer M. Aqua lymphatic therapy in women who suffer from breast cancer treatment-related lymphedema: a randomized controlled study. *Support Care Cancer* 2009; 18: 383–92.
- 159 Lohman EB 3rd, Petrofsky JS, Maloney-Hinds C, Betts-Schwab H,

- Thorpe D. The effect of whole body vibration on lower extremity skin blood flow in normal subjects. *Med Sci Monit* 2007; 13: CR71–76.
- 160 Kersch-Schindl K, Grampp S, Henk C, Resch H, Preisinger E, Fialka-Moser V, *et al.* Whole-body vibration exercise leads to alterations in muscle blood volume. *Clin Physiol* 2001; 21: 377–82.
- 161 Stewart JM, Karman C, Montgomery LD, McLeod KJ. Plantar vibration improves leg fluid flow in perimenopausal women. *Am J Physiol Regul Integr Comp Physiol* 2005; 288: R623–629.
- 162 Gulias S, Nieto S. Psychological assistance and its importance in the medical treatment of lymphedema. *J Soc Phlebot Lymphol* 2007; 2: 179–87.
- 163 Schmeller W, Meier-Vollrath I. Tumescence liposuction: a new and successful therapy for lipedema. *J Cutan Med Surg* 2006; 10: 7–10.
- 164 Warren AG, Janz BA, Borud LJ, Slavin SA. Evaluation and management of the fat leg syndrome. *Plast Reconstr Surg* 2007; 119: 9e–15e.
- 165 Ray C. Caring for the Bariatric Patient with lymphedema and obesity. *Bariatrics Today* 2004: 48–50.
- 166 Foldi E, Foldi M. Lipedema. In: Foldi M, Foldi E, Kubik S, eds. *Foldi's Textbook of Lymphology*. Munich (Germany): Elsevier GmbH; 2006. p 417–427.
- 167 Williams A. Amy's Butterfly Journey: Living My Life with Lymphedema and Obesity. *Obesity Help* 2004: 43–4.
- 168 Moore JC, Ballas ZK. A novel therapy for lymphedema. *Arch Intern Med* 2009; 169: 201–2.
- 169 Bruns F, Micke O, Bremer M. Current status of selenium and other treatments for secondary lymphedema. *J Supportive Oncol* 2003; 1: 121–30.
- 170 Sasaki H, Okumura M, Kawasaki T, Kangawa K, Matsuo H. Indomethacin and atrial natriuretic peptide in Pseudo-Bartter's syndrome. *N Engl J Med* 1987; 316: 167.
- 171 Pecking AP, Fevrier B, Wargon C, Pillion G. Efficacy of Daflon 500 mg in the treatment of lymphedema (secondary to conventional therapy of breast cancer). *Angiology* 1997; 48: 93–8.
- 172 Pecking AP. Evaluation by lymphoscintigraphy of the effect of a micronized flavonoid fraction (Daflon 500 mg) in the treatment of upper limb lymphedema. *Int Angiol* 1995; 14: 39–43.
- 173 Casley-Smith JR, Casley-Smith JR. The effects of diosmin (a benzopyrone) upon some high-protein oedemas: lung contusion, and burn and lymphoedema of rat legs. *Agents Actions* 1985; 17: 14–20.
- 174 Suter A, Bommer S, Rechner J. Treatment of patients with venous insufficiency with fresh plant horse chestnut seed extract: a review of 5 clinical studies. *Adv Ther* 2006; 23: 179–90.
- 175 Cornely ME. Lipedema and Lymphatic Edema. In: Shiffman MA, Di Giuseppe A, eds. *Liposuction Principles and Practice*. Berlin Heidelberg: Springer; 2006.
- 176 Conley SM, Bruhn RL, Morgan PV, Stamer WD. Selenium's effects on MMP-2 and TIMP-1 secretion by human trabecular meshwork cells. *Invest Ophthalmol Vis Sci* 2004; 45: 473–9.
- 177 Obenheimer H, Jankowiak P, Berlemann K, Hermann V, Diethelm A. Clinical and biological effects of selenium in edema. Paper presented at: Proceedings of the International Symposium: Lymphedema — New Perspectives in Research and Treatment. 1976; Zaragoza, Spain.
- 178 Schrauzer GN. Selenium in the therapy of chronic lymphedema—mechanistic perspectives and practical applications. *Z Lymphol* 1997; 21: 16–9.
- 179 Micke O, Bruns F, Schäfer U, Kisters K, Hesselmann S, Willich N. Selenium in the treatment of acute and chronic lymphedema. *Trace Elements and Electrolytes* 2000; 17: 206–9.
- 180 Horvathova M, Jahnova E, Gazdik F. Effect of selenium supplementation in asthmatic subjects on the expression of endothelial cell adhesion molecules in culture. *Biol Trace Elem Res* 1999; 69: 15–26.
- 181 Kiremidjian-Schumacher L, Roy M, Glickman R, Schneider K, Rothstein S, Cooper J, *et al.* Selenium and immunocompetence in patients with head and neck cancer. *Biol Trace Elem Res* 2000; 73: 97–111.
- 182 Siems W, Grune T, Voss P, Brenke R. Anti-fibrosclerotic effects of shock wave therapy in lipedema and cellulite. *Biofactors* 2005; 24: 275–82.
- 183 Dercum FX. Three cases of a hitherto unclassified affection resembling in its grosser aspects obesity, but associated with special nervous symptoms - adiposis dolorosa. *Am J Med Sci* 1892; civ: 521.
- 184 Dercum FX. A subcutaneous connective-tissue dystrophy of the arms and back, associated with symptoms resembling myxoedema. *Univ Med Magazine Philadelphia* 1888: 140–50.
- 185 Dercum FX. Autopsy in a case of adiposis dolorosa, with microscopical examination. *J Nerv Ment Dis* 1900;XXVII(8):419–29.
- 186 Lyon IP. Adiposis and lipomatosis: Considered in reference to their constitutional relations and symptomatology. *Arch Int Med* 1910; VI: 28–120.
- 187 Brorson H, Fagher B. Dercum's disease. Fatty tissue rheumatism caused by immune defense reaction? *Lakartidningen* 1996; 93: 1430; 1433–6.
- 188 Herbst KL, Asare-Bediako S. Adiposis Dolorosa is More than Painful Fat. *The Endocrinologist* 2007; 17: 326–44.
- 189 Walsler WC. Adiposis dolorosa in an infant. *Boston Med Surg J* 1910; CLXII: 906–7.
- 190 Bruning H, Walter FK. Zur frage der Adipositas dolorosa (Dercumshe Krankheit) in Kindersalter. *Ztschr f Kinderh* 1919; 24: 183.
- 191 Loening K, Fuss S. Schilddrüsenveränderungen bei Adipositas dolorosa. *Verhandl d Cong f inn Med* 1906: 222.
- 192 Steiger WA, Litvin H, Lasche EM, Durant TM. Adiposis dolorosa (Dercum's disease). *N Engl J Med* 1952; 247: 393–6.
- 193 Vitaut L. Maladie de Dercum (adiposis dolorosa). *Loire med St Etienne* 1901; 20: 254.
- 194 Kling DH. Juxta-articular adiposis dolorosa, its significance and relation to Dercum's disease and osteo-arthritis. *J Arch Surg* 1937; 34: 599–630.
- 195 Lynch HT, Harlan WL. Hereditary factors in adiposis dolorosa (Dercum's disease). *Am J Hum Genet* 1963; 15: 184–90.
- 196 Steiner J, Schiltz K, Heidenreich F, Weissenborn K. Lipomatosis dolorosa — a frequently overlooked disease picture. *Nervenarzt* 2002; 73: 183–7.
- 197 Pack GT, Ariel IM. *Tumors of the soft somatic tissues: a clinical treatise*. New York: Hoeber-Harper; 1958.
- 198 Thimm P. Adipositas dolorosa und schmerzende symmetrische Lipome. *Montsh f prakt Dermatol* 1903; xxxvi: 282.
- 199 Campen R, Mankin H, Louis DN, Hirano M, Maccollin M. Familial occurrence of adiposis dolorosa. *J Am Acad Dermatol* 2001; 44: 132–6.
- 200 Cantu JM, Ruiz-Barquin E, Jimenez M, Castillo L, Macotela-Ruiz E. Autosomal dominant inheritance in adiposis dolorosa (Dercum's disease). *Humangenetik* 1973; 18: 89–91.
- 201 Winkelmann NW, Eckel JL. Adiposis dolorosa (Dercum's disease) a clinicopathologic study. *J Am Med Assoc* 1925; 85: 1935–9.
- 202 Herbst KL, Coviello AD, Chang A, Boyle DL. Lipomatosis-associated inflammation and excess collagen may contribute to lower relative resting energy expenditure in women with adiposis dolorosa. *Int J Obes (Lond)* 2009; 33: 1031–8.



- 203 Kirpilä J, Ripatti N. Adipositas dolorosa juxtaarticularis (Dercum's disease) och dess behandling [in Swedish]. *Nord Med* 1958; 59: 358-60.
- 204 Hovesen E. Adipositis dolorosa (Dercum's syndrome). *Nord Med* 1953; 50: 971.
- 205 Blomstrand R, Juhlin L, Nordenstam H, Ohlsson R, Werner B, Engstrom J. Adipositis dolorosa associated with defects of lipid metabolism. *Acta Derm Venereol* 1971; 51: 243-50.
- 206 Page IH. Chemiche Untersuchungen bei der Dercumschen Krankheit. *Virchow Arch Path Anat* 1930; 279: 262.
- 207 Mella BA. Adipositis dolorosa. *Univ Michigan Med Center J* 1967; 33: 79-81.
- 208 Held JL, Andrew JA, Kohn SR. Surgical amelioration of Dercum's disease: a report and review. *J Dermatol Surg Oncol* 1989; 15: 1294-6.
- 209 Campen RB, Sang CN, Duncan LM. Case records of the Massachusetts General Hospital. Case 25-2006. A 41-year-old woman with painful subcutaneous nodules. *N Engl J Med* 2006; 355: 714-22.
- 210 Pimenta WP, Paula FJ, Dick-de-Paula I, Piccinato CE, Monteiro CM, Brandão-Neto J, et al. Hormonal and metabolic study of a case of adipositis dolorosa (Dercum's disease). *Braz J Med Biol Res* 1992; 25: 889-93.
- 211 Ballet G. L'adipose, douloureuse (maladie de Dercum). *Presse méd Par* 1903; i: 285-8.
- 212 Price GE. Adipositis dolorosa: a clinical and pathological study, with the report of two cases with necropsy. *Am J Med Sci* 1909; 137: 705-14.
- 213 Eshner AA. A case of adipositis dolorosa. *J Am Med Assoc* 1898; XXXI: 1156-60.
- 214 Collins J. Adipositis dolorosa. In: Dercum FX, ed. *Textbook of Nervous Diseases*. Lea Brothers & Co; 1895. p 898-200.
- 215 Alger EM. Clinical memoranda: A case of adipositis dolorosa. *Med News (1882-1905)* 1901; 78: 91-2.
- 216 Frankenheimer JB. Adipositis dolorosa. *J Am Med Assoc* 1908; L: 1012-3.
- 217 Skagen K, Petersen P, Kastrup J, Norgaard T. The regulation of subcutaneous blood flow in patient with Dercum's disease. *Acta Derm Venereol* 1986; 66: 337-9.
- 218 Falta W. Endocrine diseases. In: Meyers MK, ed. 2 ed. Philadelphia: Blakiston's Son & Co; 1916: 575.
- 219 Moi L, Canu C, Pirari P, Mura MN, Piludu G, Del Giacco GS. Dercum's disease: a case report. *Ann Ital Med Int* 2005; 20: 187-91.
- 220 Lange U, Oelzner P, Uhlemann C. Dercum's disease (Lipomatosis dolorosa): successful therapy with pregabalin and manual lymphatic drainage and a current overview. *Rheumatol Int* 2008; 29: 17-22.
- 221 Pascucci A, Lynch PJ. Lipedema with multiple lipomas. *Dermatol Online J* 2010; 16: 4.
- 222 Rockson SG. The unique biology of lymphatic edema. *Lymphat Res Biol* 2009; 7: 97-100.
- 223 Spiller WG. Clinical Memoranda: Report of three cases of adipositis dolorosa. *Med News* 1898: 268-70.
- 224 Eisman J, Swezey RL. Juxta-articular adipositis dolorosa: what is it? Report of 2 cases. *Ann Rheum Dis* 1979; 38: 479-82.
- 225 White WH. A case of adipositis dolorosa. *Br Med J* 1899; 2: 1533-4.
- 226 Burr CW. A case of adipositis dolorosa with necropsy. *J Nervous Mental Disease* 1900; XXVII: 519-25.
- 227 Dercum FX, McCarthy DJ. Autopsy in a case of adipositis dolorosa. *Am J Med Sci* 1902; (124): 994.
- 228 Abu-Hijleh MF, Scothorne RJ. Studies on haemolymph nodes. IV. Comparison of the route of entry of carbon particles into parathyroid nodes after intravenous and intraperitoneal injection. *J Anat* 1996; 188: 565-73.
- 229 Mills CK. A case of adeno lipomatosis: With some remarks on the differential diagnosis of the affection from adipositis dolorosa and other diseases. *J Nervous Mental Disease* 1918; 36: 106-8.
- 230 Stolkind E. Cases of adipositis dolorosa (Dercum's disease). *Proc Royal Soc Med* 1923; 16 (Clinical Section): 45-7.
- 231 Hammond JA. An instance of adipositis dolorosa in two sisters. *Br Med J* 1904; 2: 121.
- 232 Souza-Smith FM, Kurtz KM, Molina PE, Breslin JW. Adaptation of mesenteric collecting lymphatic pump function following acute alcohol intoxication. *Microcirculation* 2010; 17: 514-24.
- 233 Dercum FX. Note on a case of adipositis dolorosa in which there was present also spasticity and contracture involving the extremities. *J Nervous Mental Disease* 1918; 36: 159-62.
- 234 Price GE, Bird JT. Adipositis dolorosa: A report of a case with increased sugar tolerance and epileptiform convulsions. *J Am Med Association* 1925; 84: 247-8.
- 235 Wortham NC, Tomlinson IP. Dercum's disease. *Skinmed* 2005; 4: 157-162; quiz 163-4.
- 236 Bergeron PN. A case of adipositis dolorosa with involvement of the large nerve trunks. *J Nerv Mental Disease* 1918; 36: 159.
- 237 Kirpila J, Ripatti N. Adipositis dolorosa juxta-articularis: Dercum's disease & its therapy. *Nordisk medicin* March 1958; 59: 358-60.
- 238 Taylor EW, Luce DS. A case of adipositis dolorosa. *Boston Medical and Surgical Journal*; CLIV: 187-90.
- 239 Myers B. Case of adipositis dolorosa. *Proceedings of the Royal Society of Med* 1923; 16 (Clinical Section): 12-3.
- 240 Palmer ED. Dercum's disease: adipositis dolorosa. *Am Fam Physician* 1981; 24: 155-7.
- 241 Szypula I, Kotulska A, Szopa M, Pieczyrak R, Kucharz EJ. Adipositis dolorosa with hypercholesterolemia and premature severe generalized atherosclerosis. *Wiad Lek* 2009; 62: 64-65.
- 242 Maddalozzo GF, Iwaniec UT, Turner RT, Rosen CJ, Widrick JJ. Whole-body vibration slows the acquisition of fat in mature female rats. *Int J Obes (Lond)* 2008; 32: 1348-54.
- 243 Alentorn-Geli E, Padilla J, Moras G, Lazaro Haro C, Fernandez-Sola J. Six weeks of whole-body vibration exercise improves pain and fatigue in women with fibromyalgia. *J Altern Complement Med* 2008; 14: 975-81.
- 244 Singal A, Janiga J, Bossenbroek N, Lim H. Dercum's disease (adipositis dolorosa): a report of improvement with infliximab and methotrexate. *J Eur Acad Dermatol Venereol* 2007; 21: 717.
- 245 Herbst KL, Rutledge T. Pilot study: rapidly cycling hypobaric pressure improves pain after 5 days in adipositis dolorosa. *J Pain Res* 2010; 3: 147-53.
- 246 Hetzler RK, Sargent RW, Kimura IK, et al. The effect of a cyclic variable altitude conditioning program on arterial oxygen saturation acclimation. Paper presented at: 53rd Annual Meeting, American College of Sports Med, 2006; Denver, CO.
- 247 Juhlin L. Long-standing pain relief of adipositis dolorosa (Dercum's disease) after intravenous infusion of lidocaine. *J Am Acad Dermatol* 1986; 15: 383-5.
- 248 Desai MJ, Siriki R, Wang D. Treatment of pain in Dercum's disease with Lidoderm (lidocaine 5% patch): a case report. *Pain Med* 2008; 9: 1224-6.
- 249 Petersen P, Kastrup J. Dercum's disease (adipositis dolorosa). Treatment of the severe pain with intravenous lidocaine. *Pain* 1987; 28: 77-80.
- 250 Devillers AC, Oranje AP. Treatment of pain in adipositis dolorosa (Dercum's disease) with intravenous lidocaine: a case report with a

- 10-year follow-up. *Clin Exp Dermatol* 1999; 24: 240–1.
- 251 Atkinson RL. Intravenous lidocaine for the treatment of intractable pain of adiposis dolorosa. *Int J Obes* 1982; 6: 351–7.
- 252 Taniguchi A, Okuda H, Mishima Y, Nagata I, Oseko F, Hara M, *et al.* A case of adiposis dolorosa: lipid metabolism and hormone secretion. *Int J Obes* 1986; 10: 277–81.
- 253 Iwane T, Maruyama M, Matsuki M, Ito Y, Shimoji K. Management of intractable pain in adiposis dolorosa with intravenous administration of lidocaine. *Anesth Analg* 1976; 55: 257–9.
- 254 Reggiani M, Errani A, Staffa M, Schianchi S. Is EMLA effective in Dercum's disease? *Acta Derm Venereol* 1996; 76: 170–1.
- 255 Berntorp E, Berntorp K, Brorson H, Frick K. Liposuction in Dercum's disease: impact on haemostatic factors associated with cardiovascular disease and insulin sensitivity. *J Intern Med* 1998; 243: 197–201.
- 256 DeFranzo AJ, Hall JH Jr, Herring SM. Adiposis dolorosa (Dercum's disease): liposuction as an effective form of treatment. *Plast Reconstr Surg* 1990; 85: 289–92.
- 257 Brorson H, Aberg M, Fagher B. Liposuction in adiposis dolorosa (morbus Dercum) – an effective therapy. *Ugeskr Laeger* 1992; 154: 1914–5.
- 258 Wollina U, Goldman A, Heinig B. Microcannular tumescent liposuction in advanced lipedema and Dercum's disease. *G Ital Dermatol Venereol* 2010; 145: 151–9.
- 259 Hansson E, Svensson H, Brorson H. Liposuction may reduce pain in Dercum's disease (adiposis dolorosa). *Pain Med* 2011; 12: 942–52.
- 260 Tsang C, Aggarwal R, Bonanomi G. Dercum's disease as a cause of weight loss failure after gastric bypass surgery. *Surg Obes Relat Dis* 2011; 7: 243–5.
- 261 Wohl MG, Pastor N. Adipositas dolorosa (Dercum's disease). *JAMA* 1938; 110: 1261–4.
- 262 Sorrels TL, Bostock E. Induction of feeding by 7-chlorokynurenic acid, a strychnine-insensitive glycine binding site antagonist. *Brain Res* 1992; 572: 265–8.
- 263 Spota BB, Brage D. Cortisona Y Enfermedad de Dercum. *Dia med B Air* 1952; 24: 1930.
- 264 Greenbaum SS, Varga J. Corticosteroid-induced juxta-articular adiposis dolorosa. *Arch Dermatol* 1991; 127: 231–3.
- 265 Rebuffe-Scrive M, Lonnroth P, Marin P, Wesslau C, Bjorntorp P, Smith U. Regional adipose tissue metabolism in men and postmenopausal women. *Int J Obes* 1987; 11: 347–55.
- 266 de Médicis Sajous CE. The Internal secretions and the principles of medicine. Vol 1. 9th ed. Philadelphia: FA Davis Co; 1920.