

# Diabetes-Induced Impairment in Visual Function in Mice: Contributions of p38 MAPK, RAGE, Leukocytes, and Aldose Reductase

Chieh Allen Lee,<sup>1</sup> Guangyuan Li,<sup>1,2</sup> Mansi D. Patel,<sup>3</sup> J. Mark Petrash,<sup>4</sup> Beth Ann Benetz,<sup>5</sup> Alex Veenstra,<sup>1</sup> Jaume Amengual,<sup>1</sup> Johannes von Lintig,<sup>1</sup> Christopher J. Burant,<sup>1,6</sup> Johnny Tang,<sup>1,5,6</sup> and Timothy S. Kern<sup>1,6</sup>

<sup>1</sup>Case Western Reserve University, Cleveland, Ohio, United States

<sup>2</sup>The Second Hospital of Jilin University, Changchun, Jilin, China

<sup>3</sup>St. Louis School of Medicine, St. Louis, Missouri, United States

<sup>4</sup>University of Colorado Denver Health Sciences Center, Aurora, Colorado, United States

<sup>5</sup>University Hospitals Eye Institute, Case Western Reserve University, Cleveland, Ohio, United States

<sup>6</sup>Stokes Veterans Administration Medical Center, Cleveland, Ohio, United States

Correspondence: Timothy S. Kern, Department of Medicine, 441 Wood Building, Case Western Reserve University, 10900 Euclid Avenue, Cleveland, OH 44106; tsk@case.edu.

CAL and GL contributed equally to the work presented here and should therefore be regarded as equivalent authors.

Submitted: January 14, 2013

Accepted: July 27, 2013

Citation: Lee CA, Li G, Patel MD, et al. Diabetes-induced impairment in visual function in mice: contributions of p38 MAPK, RAGE, leukocytes, and aldose reductase. *Invest Ophthalmol Vis Sci.* 2014;55:2904–2910. DOI: 10.1167/iovs.13-11659

**PURPOSE.** Visual function is impaired in diabetes, but molecular causes of this dysfunction are not clear. We assessed effects of diabetes on visual psychophysics in mice, and tested the effect of therapeutic approaches reported previously to inhibit vascular lesions of the retinopathy.

**METHODS.** We used the optokinetic test to assess contrast sensitivity and spatial frequency threshold in diabetic C57Bl/6J mice and age-matched nondiabetic controls between 2 and 10 months of diabetes. Contributions of p38 MAP kinase (MAPK), receptor for advanced glycation end products (RAGE), leukocytes, and aldose reductase (AR) to the defect in contrast sensitivity were investigated. Cataract, a potential contributor to reductions in vision, was scored.

**RESULTS.** Diabetes of 2 months' duration impaired contrast sensitivity and spatial frequency threshold in mice. The defect in contrast sensitivity persisted for at least 10 months, and cataract did not account for this impairment. Diabetic mice deficient in AR were protected significantly from development of the diabetes-induced defects in contrast sensitivity and spatial frequency threshold. In contrast, pharmacologic inhibition of p38 MAPK or RAGE, or deletion of inducible nitrous oxide synthase (iNOS) from bone marrow-derived cells did not protect the visual function in diabetes.

**CONCLUSIONS.** Diabetes reduces spatial frequency threshold and contrast sensitivity in mice, and the mechanism leading to development of these defects involves AR. The mechanism by which AR contributes to the diabetes-induced defect in visual function can be probed by identifying which molecular abnormalities are corrected by AR deletion, but not other therapies that do not correct the defect in visual function.

Keywords: spatial frequency threshold, contrast sensitivity, diabetic retinopathy

Diabetic retinopathy (DR) generally has been regarded as a disease of the retinal vasculature, and sequelae of the abnormal vasculature (including retinal edema, hemorrhage, fibrovascular membranes, and neovascularization) are recognized causes of visual impairment or blindness in diabetes. Diabetes-induced defects in function of retinal neurons or even death of those cells also are known, and these changes can develop early in diabetes. Electrophysiologic abnormalities of the retina in diabetes include changes in electroretinogram (ERG), visual evoked potential (VEP), and macular latency.<sup>1–6</sup>

Visual function, however, is much more complex than electrical measurements, and represents the complex summation of signaling of many cell types in retina and brain. Visual function can be evaluated by a variety of tests, including visual acuity, visual field, color perception, stereoacuity, glare recovery, dark adaptation, fixation, and contrast sensitivity. Diabetes also impairs visual

psychophysics, as evidenced not only by reductions in visual acuity,<sup>7–9</sup> but also reductions in contrast sensitivity<sup>10</sup> and color vision.<sup>7–9,11</sup> Contrast sensitivity is important in daily living as the ability allows for edge discrimination.<sup>12</sup> Loss of such ability is highly correlated with significant reductions in the quality of vision, and has been associated with increased patient morbidity.<sup>13,14</sup> Little is known about the molecular causes of these functional defects. Animal studies of diabetic retinopathy have not focused on vision in the past, due to a lack of techniques to measure such parameters in animals.

Considerable effort has been expended in recent years to understand the molecular pathogenesis of diabetic retinopathy. Most of this effort to date has focused on the vascular lesions of the retinopathy, and oxidative stress, inflammatory proteins, and growth factors have been implicated in this vasculopathy.<sup>15</sup> The molecular pathogenesis of the alterations of the neural retina

caused by diabetes, however, are much less clear. Some studies have identified diabetes-induced alterations that contribute to degeneration of retinal ganglion cells,<sup>16–21</sup> but to our knowledge no prior studies have focused on the pathogenesis of diabetes-induced defects of visual function. It is not known if the molecular alterations underlying these functional defects originate in retinal cells (such as photoreceptors) or higher in the brain.

In our study, we have used a visual psychophysics test (virtual optokinetic system) to assess contrast sensitivity and spatial frequency threshold (an estimate of visual acuity) in diabetic mice. Our studies demonstrated a persistent diabetes-induced reduction in these parameters. The potential contributions of p38 MAP kinase (MAPK), receptor for advanced glycation end products (RAGE), bone marrow-derived cells, and aldose reductase (AR) in development of the diabetes-induced defect in contrast sensitivity were investigated.

## METHODS

### Animals

Wild-type mice (WT; C57BL/6J) were purchased from Jackson Laboratories (Bar Harbor, ME). All mice were housed in ventilated microisolator cages, and all experiments followed the guidelines set forth by the Association for Research in Vision and Ophthalmology (ARVO) Animal Statement for the Use of Animals in Ophthalmic and Vision Research.

Experimental therapies or genetic modifications tested were a p38 MAPK inhibitor (PHA666859), a RAGE inhibitor, and animals deficient in AR (AR<sup>-/-</sup>). PHA666859 was obtained from Pfizer, Inc. (New York, NY), and was administered in the diet at a dose of 25 mg/kg body weight (BW), as per a prior study where we demonstrated that this dose inhibited biomarkers of p38 MAPK activity in vivo and capillary degeneration in diabetic rodents.<sup>22</sup> A murine RAGE-Fc fusion protein from Galactica Pharmaceuticals, Inc. (Villanova, PA) was injected intraperitoneally three times per week at 100 µg per mouse. Likewise, we recently reported that this dose of drug in these same animals significantly inhibited diabetes-induced degeneration of retinal capillaries in diabetic rodents.<sup>23</sup> Both of these drugs had the intended pharmacologic effects in vivo, as demonstrated by assessment of products and proteomic analyses.<sup>22,24</sup> AR<sup>-/-</sup> mice were generated by Ho et al.,<sup>25</sup> and provided to us. The effect of AR deletion on development of the histopathology of diabetic retinopathy in these mice currently is being reported elsewhere. Diabetic mice made chimeric (deficient in inducible nitric oxide synthase [iNOS] in bone marrow-derived cells only) were generated as reported previously by us,<sup>26,27</sup> and were killed at 4 months' duration of diabetes.

### Diabetes

Insulin-deficient diabetes was induced in 2-month-old, fasted, male mice by intraperitoneal injections of streptozotocin (55 mg/kg BW) on 5 consecutive days. Insulin was given as needed to maintain BW and allow a slow increase in BW while allowing hyperglycemia, polyuria, and hyperphagia (0–0.2 U every 2–3 days). Hyperglycemia was quantified every 2 to 3 months by measuring total glycated hemoglobin levels (Variant II total GHb Program; BioRad, Hercules, CA, USA) and by measuring blood glucose concentrations (glucose dehydrogenase-based strips).

### Spatial Frequency Threshold and Contrast Sensitivity

The virtual optokinetic system (VOS OKT) has been described at length by Prusky et al.<sup>28</sup> The VOS apparatus consists of four computer monitors positioned around a square testing arena

with an unrestrained rodent placed in the middle. A sine wave grating is projected on the monitors in 3D coordinate space, and revolves around the animal. The experimenter (who was masked as to the group that the animals were in) judged whether the animal made tracking movements with its head to follow the moving grating lines. By varying the contrast and spacing of moving “bars,” the spatial frequency threshold and contrast sensitivity of the animals were determined. Animals initially were placed in the device without recording the response to allow animal training. Each measurement was repeated several times to evaluate the reproducibility of responses. Animals were not anesthetized.

Spatial frequency threshold and contrast sensitivity were measured in WT diabetic animals (and age-matched nondiabetic controls) between 2 and 10 months of diabetes. The maximum spatial frequency capable of driving head tracking was determined as spatial frequency threshold. Contrast sensitivity was measured at 6 various spatial frequencies (for all experiments except the iNOS chimeras; see below) to detect functional defects in spatially sensitive retinal cells or in higher visual pathways, and was determined as the inverse of Michelson contrast, without correction for luminance of the monitors. Because diabetes-induced defects in contrast sensitivity have been reported to develop earlier than defects in visual acuity and because acuity is one point on a contrast sensitivity curve (the point of 100% contrast),<sup>29</sup> we did not measure spatial frequency threshold in our studies of p38 MAPK, RAGE, or AR. Spatial frequency threshold or visual acuity has been derived by extrapolation from contrast sensitivity curves in many studies, so we estimated spatial frequency threshold in our studies of AR<sup>-/-</sup> mice by linear regression using contrast thresholds for the 3 highest spatial frequencies (0.103, 0.192, and 0.275 c/d). The point where the fitted line intercepted a contrast threshold of 0.01 (100% contrast) was taken as visual acuity. The derived value for a given mouse was not included if the line generated from the 3 points did not yield an  $R^2$  value  $>0.85$ . For iNOS chimeric mice, we measured spatial frequency threshold and a single point of the contrast sensitivity curve (0.064 c/d). Cataract photos were taken 6 and 10 months of diabetes. The grader was masked with regard to the experimental group of the animals (nondiabetic animals could be differentiated from diabetic animals based on body weight, but since some diabetics were treated with a therapy and others were untreated, the investigator was masked with respect to experimental group in the diabetics).

### Cataract Grading

Cataracts were assessed using a 4-step scale that gave a composite score for nuclear, cortical, and/or posterior subcapsular abnormalities. The scale was a simplification of the Lens Opacities Classification System III (LOCS III) classification<sup>30</sup>: 0, absent; 1+, mild (LOCS III categories 1, 2); 2+, moderate (categories 3, 4); 3+, severe (categories 5, 6). Pupils were dilated, and close-up photographs of lenses of anesthetized animals were taken using side illumination. Lenses were assigned one of the grades described above based on the photographs. The grader was masked with regard to the experimental group of the animals.

### Statistical Analyses

Contrast sensitivity was analyzed by the repeated measures ANOVA (within and between, and between subjects). Visual acuity and clinical data were analyzed by the ANOVA followed by Fisher's post hoc test. Differences were considered statistically significant at  $P < 0.05$ .

TABLE 1. Metabolic Control in Diabetic Mice (Mean ± SD)

Group	Final BW, g	Ave. GHb, %
Experiment 1		
N WT	49 ± 6	3.0 ± 0.0
D WT	28 ± 2*	10.4 ± 0.9*
D + PHA666859	28 ± 1*	10.3 ± 0.6*
D + mRAGE-Fc	27 ± 3*	10.6 ± 0.7*
Experiment 2		
N WT	50 ± 4	2.9 ± 0.1
D WT	28 ± 2*	10.1 ± 0.8*
N AR <sup>-/-</sup>	59 ± 3	3.0 ± 0.1
D AR <sup>-/-</sup>	28 ± 2*	10.2 ± 0.8*
Experiment 3, chimeras		
N WT→WT	35 ± 3	3.3 ± 0.2
D WT→WT	27 ± 2*	10.4 ± 0.7*
N iNOS <sup>-/-</sup> →WT	39 ± 5	3.3 ± 0.2
D iNOS <sup>-/-</sup> →WT	29 ± 2*	10.6 ± 0.5*

\* Different from N control at  $P < 0.05$ .

RESULTS

Diabetic mice from all experimental groups had levels of glycosylated hemoglobin (GHb) and blood glucose that were significantly greater ( $P < 0.05$ ) than levels found in appropriate age-matched nondiabetic controls. Average GHb for the nondiabetic control (N WT), diabetic control (D WT), diabetic plus PHA666859 (D + PHA666859), diabetic plus murine RAGE-Fc fusion protein (D + mRAGE-Fc), diabetic and nondiabetic iNOS chimeras (iNOS<sup>-/-</sup> → WT), and diabetic AR<sup>-/-</sup> groups over the entire duration of study are listed in Table 1. None of the animals was losing body weight (although diabetics were not gaining at the normal rate), and all of the animals appeared clinically healthy.

Diabetes-dependent reductions in contrast sensitivity and spatial frequency threshold were detected at 2 months of diabetes (Fig. 1), and the defects persisted for at least 10 months. The diabetes-induced defect seemed most noticeable in spatial frequencies in the mid to high range.

Impairment of light from reaching the retina might contribute to apparent reductions in contrast sensitivity and visual acuity. Therefore, we measured severity of cataract in these animals. In our animals, cataract severity in mice diabetic for 6 or 10 months was not different from that in age-matched nondiabetic controls mice (data for 10 months of diabetes are shown in Table 2). Thus,

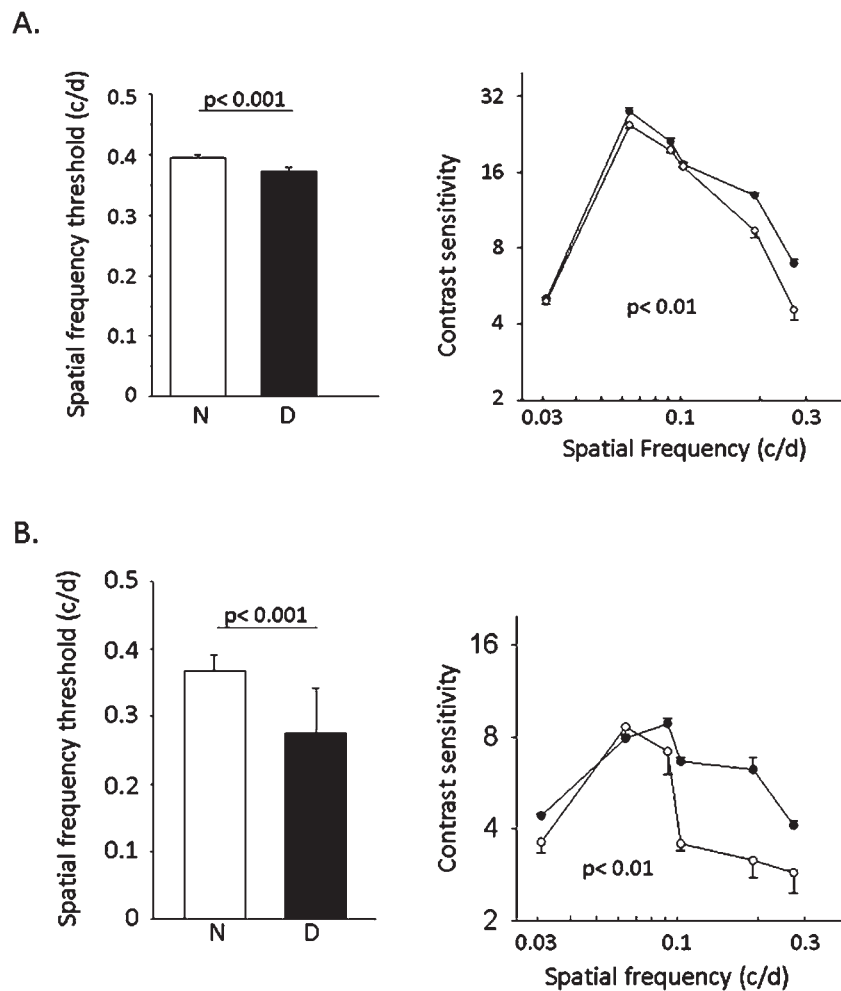


FIGURE 1. Diabetes-induced defects in spatial frequency threshold and contrast sensitivity. Both defects develop quickly (2 months) in diabetic C57Bl/6 mice (A), and are preserved for at least 10 months of diabetes (B). Solid circles: nondiabetic WT controls. Hollow circles: diabetic WT controls.  $n \geq 5$  in each group. Mean ± SEM.

**TABLE 2.** Cataract Severity in Nondiabetic and Diabetic Mice

	Duration, mo	<i>n</i>	Cataract Grade
N WT	10	12	1.6 ± 0.2
D WT	10	12	1.5 ± 0.1
N AR <sup>-/-</sup>	10	5	1.0 ± 0.3
D AR <sup>-/-</sup>	10	5	1.9 ± 0.2

Mean ± SD. None of the diabetic groups is significantly ( $P < 0.05$ ) different from the appropriate N WT group.

cataract severity did not explain the observed diabetes-induced reduction in contrast sensitivity and visual acuity.

We previously have found that pharmacologic inhibition of p38 MAPK or RAGE signaling inhibited the early vascular lesions of diabetic retinopathy, notably capillary degeneration.<sup>22,23</sup> The present studies demonstrated that despite these beneficial actions on vascular structure, these therapies did not significantly inhibit the diabetes-induced loss of contrast sensitivity at 8 months of diabetes (Fig. 2). Likewise, we previously have reported that leukocytes have a critical role in development of the vascular lesions of early diabetic retinopathy, and that the vascular degeneration of early diabetic retinopathy is inhibited significantly in animals lacking iNOS or other proinflammatory enzymes only from bone marrow-derived cells.<sup>26,27</sup> Despite the previously reported beneficial effect of deleting these enzymes from marrow-derived cells on vascular structure, these chimeras likewise did not inhibit significantly the diabetes-induced loss of contrast sensitivity or spatial frequency threshold at 4 months of diabetes (Table 3). In contrast, diabetic mice deficient in AR were protected from the defect in contrast sensitivity (Fig. 3). Consistent with a beneficial effect of AR deletion on visual function in diabetes, the extrapolated value for spatial frequency threshold was significantly less (26%) in WT diabetics than in WT nondiabetic controls ( $0.322 \pm 0.015$  vs.  $0.438 \pm 0.017$ , respectively;  $P < 0.05$ ), whereas diabetic AR<sup>-/-</sup> mice were not significantly different (13%) from their appropriate nondiabetic control ( $0.374 \pm 0.073$  vs.  $0.331 \pm 0.045$ , respectively).

## DISCUSSION

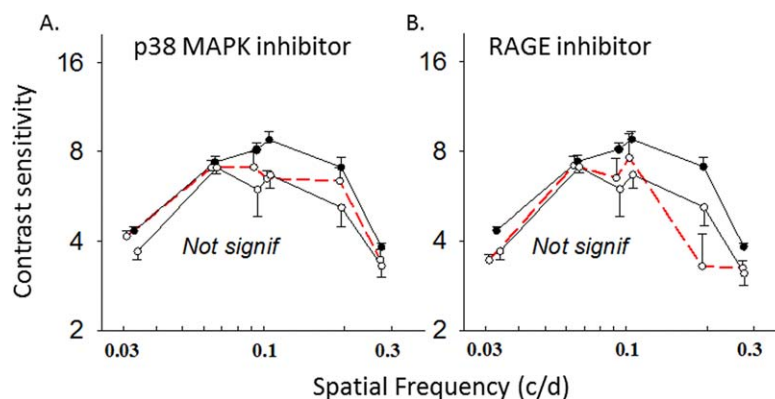
Contrast sensitivity and visual acuity are important components of vision, measuring for example the ability to discriminate objects that do not stand out from their background, and spatial resolving capacity of the visual system.

Contrast sensitivity is encoded as early as the second order retinal neurons,<sup>14</sup> and is measured at multiple spatial frequencies to detect functional defects in spatially sensitive retinal cells or in higher visual pathways.

Contrast sensitivity and other defects in vision have been studied widely in patients with diabetic retinopathy.<sup>31-34</sup> Reduction in contrast sensitivity in diabetic patients commonly precedes reductions in visual acuity,<sup>35</sup> and significant losses of the contrast sensitivity (particularly in spatial frequencies in the mid to high range) have been observed in patients with Type 1 diabetes who had no evidence of retinopathy when compared to nondiabetic controls.<sup>31,36-39</sup> Trick et al. found that 38% of diabetic subjects without retinopathy had abnormalities in contrast sensitivity, and this figure rose to 60% in those with nonproliferative (background) retinopathy.<sup>36</sup> Contrast sensitivity was abnormal more frequently than color discrimination (measured by the Farnsworth Munsell 100-Hue Test), and contrast sensitivity correlated more closely with the grade of retinopathy than either color vision or macular recovery.<sup>40</sup> Although these neurosensory defects can occur in the absence of retinopathy, they have been found to be predictive of proliferative retinopathy that ultimately leads to significant visual impairment.<sup>2,38</sup>

The present results demonstrate that diabetes causes significant losses of contrast sensitivity and spatial frequency threshold also in mice. A previous study<sup>41</sup> as well as those presented recently in abstract form (Barber AJ, et al. *IOVS* 2010;51:ARVO E-Abstract 109; Barber AJ, et al. *IOVS* 2011;52:ARVO E-Abstract 5970; and Aung MH, et al. *IOVS* 2011;52:ARVO E-Abstract 5960) likewise have detected this defect after short durations of diabetes, but we show also that the defect persists for almost a year. Like the case in diabetic patients, the defects affected particularly spatial frequencies in the mid to high range. Our threshold measurements of sensitivity in intermediate frequencies at 8 to 10 months of diabetes were approximately half of those obtained by us and others<sup>28</sup> in young diabetics, perhaps as a result of aging or more conservative grading of head tracking by us in the older diabetics. Contrast sensitivity diminished slightly in our nondiabetic animals at the longest duration (as it does in patients<sup>42</sup>), raising a possibility that aging might contribute to the defect in long-term diabetes. Nevertheless, the influence of diabetes apparently outweighed that of age, because the visual function defect was significantly worse in the diabetic animals than that in the age-matched nondiabetics at the longest durations of study.

Changes in contrast sensitivity and visual acuity may be caused by indirect mechanisms (cataract, retinal edema) or



**FIGURE 2.** Pharmacologic inhibition of p38 MAPK (A) or RAGE (B) from the onset of diabetes did not significantly inhibit (repeated measures test) the diabetes-induced defect in contrast sensitivity measured at 8 months of diabetes. *Solid circles, solid line:* nondiabetic WT controls. *Hollow circles, solid line:* diabetic WT controls. *Hollow circles, red dashed line:* diabetic animals given drug. Contrast sensitivity was determined at the same spatial frequencies in all groups, but group means are offset slightly to allow easier visualization of data.  $n \geq 5$  in each group. Mean ± SEM.

**TABLE 3.** Spatial Frequency Threshold and Single Point Contrast Sensitivity in Controls and Mice Deficient in iNOS in Bone Marrow-Derived Cells Only (4 Months of Diabetes)

	<i>n</i>	Spatial Frequency Threshold	Contrast Sensitivity at 0.064 c/d
N WT	12	0.399 ± 0.007*	24.6 ± 0.6*
D WT	12	0.363 ± 0.003	20.8 ± 0.4
N iNOS <sup>-/-</sup> → WT	5	0.392 ± 0.008†	25.2 ± 2.7†
D iNOS <sup>-/-</sup> → WT	5	0.356 ± 0.002	21.2 ± 1.3

Mean ± SD.

\* Different from D WT at  $P < 0.01$ .† Different from D iNOS<sup>-/-</sup> → WT at  $P < 0.01$ .

molecular changes within retinal neurons that cause dysfunction or even degeneration of neurons. Analysis of lens opacification in our animals indicated that the severity of cataract is not the cause of the difference in contrast sensitivity and spatial frequency threshold between diabetic and nondiabetic mice. Retinal edema also can contribute to loss of contrast sensitivity and visual acuity in diabetic patients, and this is the mechanism suggested for the ability of a protein kinase C inhibitor<sup>43–46</sup> to preserve visual acuity in diabetic patients. This mechanism seems unlikely to account for the observed defects in our diabetic mice, however, since neither retinal thickening nor edema has been detected in several studies of diabetic mice.<sup>47–49</sup> Alternatively, loss or remodeling of neurons in the retina or brain might account for the observed reduction in visual function in diabetes. Whether or not retinal ganglion cells degenerate in diabetic C57Bl/6 mice is controversial, with some investigators detecting rapid neurodegeneration,<sup>19,47,50–53</sup> in contrast to we and other investigators finding no evidence of ganglion cell loss at durations of diabetes up to one year.<sup>23,27,48,49,54,55</sup> We have detected retinal thinning in diabetic C57Bl/6 mice,<sup>56</sup> however, so a contribution of that thinning to the alteration in neural function in diabetes cannot be ruled out at present.

Molecular mechanism(s) by which diabetes impairs visual function is an important topic that, to our knowledge, has not been investigated previously. Administration of the protein

kinase C inhibitor, ruboxistaurin, to diabetic patients inhibited the deterioration of their visual acuity, but the effect was attributed to effects on retinal edema (see previous paragraph). It has been recognized for many years that AR has an important role in the peripheral neuropathy in diabetic animals,<sup>57</sup> and contributes to a variety of diabetes-induced molecular and physiologic alterations in the retina, including alterations in redox state, oxidative stress, nitric oxide generation, and VEGF production.<sup>58–62</sup> Deletion of AR has inhibited important diabetes-induced vascular lesions in mice,<sup>61,62</sup> but had no effect on ERG changes in the same animals.<sup>63</sup> Our report links AR to an aspect of vision, and demonstrated that deletion of AR in diabetes inhibits the diabetes-induced reduction in contrast sensitivity and spatial frequency threshold. AR has been localized to a variety of cell types in the retina,<sup>64–66</sup> but also is found in the brain and blood cells, any of which might influence the visual system. We do not know which cell types in the retina or brain are where AR alters cellular function, resulting in impaired visual function.

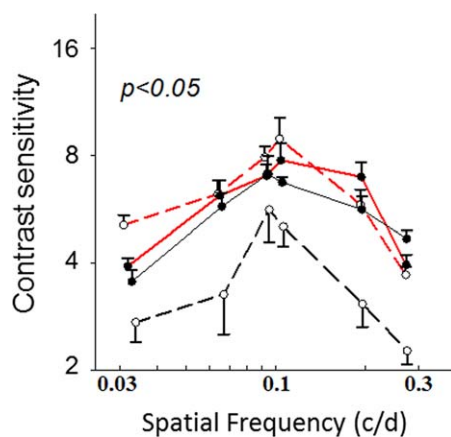
In contrast to results in AR-deficient diabetics, data presented herein demonstrated that neither inhibitors of p38 MAPK or RAGE, nor deletion of iNOS from bone marrow-derived cells significantly inhibited the diabetes-induced defect in contrast sensitivity. This is interesting because all of these therapeutic approaches have been shown by us to inhibit the degeneration of retinal capillaries in diabetic animals,<sup>22,23,27</sup> and because the molecular defects corrected by these therapies are largely the same as those known reported to be corrected by inhibition or deletion of AR. One obvious difference between AR deletion and the other approaches, however, pertains to effects on polyol production itself, and this requires further study. Nevertheless, the vascular lesions apparently can be inhibited independently of the neural dysfunction.

Measurements of visual psychophysics in animals encompass multiple levels of the visual system, from electrical activity in the retina through to more central visual structures. We present evidence that long-term diabetes impairs contrast sensitivity and spatial frequency threshold in mice. Mice are a useful rodent model for studies of vision in long-term diabetes, because like humans (and unlike rats), cataract development proceeds slowly in diabetes.<sup>67,68</sup> Thus, diabetes-induced reductions in visual processing in these animals might serve as a model to identify causes and treatments for the diabetes-induced defects in visual function in diabetic patients. The evidence that spatial frequency threshold and contrast sensitivity are reduced in diabetic mice is consistent with a retinal neuropathy that develops in parallel, but possibly independently, of the vascular lesions. The additional evidence that AR contributes to the defect in contrast sensitivity and spatial frequency threshold should offer initial insight into the mechanism(s) by which diabetes can impair visual function in diabetic patients, and offer targets at which the dysfunction might be inhibited.

### Acknowledgments

The authors thank Neal Peachey and Sherry Ball (Cole Eye Institute, Cleveland Clinic Foundation, and Stokes Veterans Administration Medical Center, Cleveland, Ohio, USA) for access to the OKT machine and helpful discussions; Pfizer, Inc. and Galactica Pharmaceuticals, Inc. for access to the drugs; and the CWRU Visual Science Research Center Core Facilities (P30EY11373) for their services.

Supported by NIH Grant R01EY00300, a grant from the Medical Research Service of the Department of Veteran Affairs (TSK), and a VA Career Development Award 2 (JT).



**FIGURE 3.** Diabetic mice deficient in AR did not develop the diabetes-induced defect in contrast sensitivity, and had values that were significantly greater than age-matched diabetic WT controls (repeated measures test) at 8 months diabetes. *Solid circles, solid line:* nondiabetic WT controls. *Hollow circles, solid line:* diabetic WT controls. *Solid circles, dashed red line:* nondiabetic AR<sup>-/-</sup> mice. *Hollow circles, dashed red line:* diabetic AR<sup>-/-</sup> mice.  $n \geq 5$  in each group. Mean ± SEM.

Disclosure: C.A. Lee, None; G. Li, None; M.D. Patel, None; J.M. Petrash, None; B.A. Benetz, None; A. Veenstra, None; J. Amengual, None; J. von Lintig, None; C.J. Burant, None; J. Tang, None; T.S. Kern, None

## References

- Bresnick GH, Korth K, Groo A, Palta M. Electroretinographic oscillatory potentials predict progression of diabetic retinopathy. Preliminary report. *Arch Ophthalmol*. 1984;102:1307-1311.
- Bresnick GH, Palta M. Oscillatory potential amplitudes. Relation to severity of diabetic retinopathy. *Arch Ophthalmol*. 1987;105:929-933.
- Holopigian K, Seiple W, Lorenzo M, Carr R. A comparison of photopic and scotopic electroretinographic changes in early diabetic retinopathy. *Invest Ophthalmol Vis Sci*. 1992;33:2773-2780.
- Fortune B, Schneck ME, Adams AJ. Multifocal electroretinogram delays reveal local retinal dysfunction in early diabetic retinopathy. *Invest Ophthalmol Vis Sci*. 1999;40:2638-2651.
- Tzekov R, Arden GB. The electroretinogram in diabetic retinopathy. *Surv Ophthalmol*. 1999;44:53-60.
- Tyrberg M, Ponjavic V, Lövestam-Adrian M. Multifocal electroretinogram (mfERG) in patients with diabetes mellitus and an enlarged foveal avascular zone (FAZ). *Doc Ophthalmol*. 2008;117:185-189.
- Moss SE, Klein R, Klein BE. The incidence of vision loss in a diabetic population. *Ophthalmology*. 1988;95:1340-1348.
- Moss SE, Klein R, Klein BE. The 14-year incidence of visual loss in a diabetic population. *Ophthalmology*. 1998;105:998-1003.
- Aiello LP, Davis MD, Girach A, et al. Effect of ruboxistaurin on visual loss in patients with diabetic retinopathy. *Ophthalmology*. 2006;113:2221-2230.
- Ewing FM, Deary IJ, Strachan MW, Frier BM. Seeing beyond retinopathy in diabetes: electrophysiological and psychophysical abnormalities and alterations in vision. *Endocr Rev*. 1998;19:462-476.
- Klein R, Klein BE, Moss SE. Visual impairment in diabetes. *Ophthalmology*. 1984;91:1-9.
- Mones J, Rubin GS. Contrast sensitivity as an outcome measure in patients with subfoveal choroidal neovascularisation due to age-related macular degeneration. *Eye (Lond)*. 2005;19:1142-1150.
- Lord SR, Clark RD, Webster IW. Visual acuity and contrast sensitivity in relation to falls in an elderly population. *Age Ageing*. 1991;20:175-181.
- Tang Y, Zhou Y. Age-related decline of contrast sensitivity for second-order stimuli: earlier onset, but slower progression, than for first-order stimuli. *J Vis*. 2009;9:18.
- Tang J, Kern TS. Inflammation in diabetic retinopathy. *Prog Retin Eye Res*. 2011;30:343-358.
- Kusari J, Zhou S, Padiillo E, Clarke KG, Gil DW. Effect of memantine on neuroretinal function and retinal vascular changes of streptozotocin-induced diabetic rats. *Invest Ophthalmol Vis Sci*. 2007;48:5152-5159.
- Zheng L, Howell SJ, Hatala DA, Huang K, Kern TS. Salicylate-based anti-inflammatory drugs inhibit the early lesion of diabetic retinopathy. *Diabetes*. 2007;56:337-345.
- Kern TS, Barber AJ. Retinal ganglion cells in diabetes. *J Physiol*. 2008;586:4401-4408.
- Smith SB, Duplantier JN, Dun Y, et al. In vivo protection against retinal neurodegeneration by the  $\sigma_1$  ligand (+)-pentazocine. *Invest Ophthalmol Vis Sci*. 2008;49:4154-4161.
- Kim YH, Kim YS, Kang SS, Cho GJ, Choi WS. Resveratrol inhibits neuronal apoptosis and elevated Ca<sup>2+</sup>/calmodulin-dependent protein kinase II activity in diabetic mouse retina. *Diabetes*. 2010;59:1825-1835.
- Fan J, Xu G, Jiang T, Qin Y. Pharmacologic induction of heme oxygenase-1 plays a protective role in diabetic retinopathy in rats. *Invest Ophthalmol Vis Sci*. 2012;53:6541-6556.
- Du Y, Tang J, Li G, et al. Effects of p38 MAPK inhibition on early stages of diabetic retinopathy and sensory nerve function. *Invest Ophthalmol Vis Sci*. 2010;51:2158-2164.
- Li G, Tang J, Du Y, Lee CA, Kern TS. Beneficial effects of RAGE-Ig fusion protein on early diabetic retinopathy and tactile allodynia. *Mol Vis*. 2011;17:3156-3165.
- Kandpal RP, Rajasimha HK, Brooks MJ, et al. Transcriptome analysis using next generation sequencing reveals molecular signatures of diabetic retinopathy and efficacy of candidate drugs. *Mol Vis*. 2012;18:1123-1146.
- Ho HT, Chung SK, Law JW, et al. Aldose reductase-deficient mice develop nephrogenic diabetes insipidus. *Mol Cell Biol*. 2000;20:5840-5846.
- Talahalli R, Zarini S, Tang J, et al. Leukocytes regulate retinal capillary degeneration in the diabetic mouse via generation of leukotrienes. *J Leukoc Biol*. 2012;93:135-143.
- Li G, Veenstra AA, Talahalli RR, et al. Marrow-derived cells regulate the development of early diabetic retinopathy and tactile allodynia in mice. *Diabetes*. 2012;61:3294-3303.
- Prusky GT, Alam NM, Beekman S, Douglas RM. Rapid quantification of adult and developing mouse spatial vision using a virtual optomotor system. *Invest Ophthalmol Vis Sci*. 2004;45:4611-4616.
- Prusky GT, Douglas RM. Characterization of mouse cortical spatial vision. *Vision Res*. 2004;44:3411-3418.
- Chylack LT Jr, Wolfe JK, Singer DM, et al. The Lens Opacities Classification System III. The Longitudinal Study of Cataract Study Group. *Arch Ophthalmol*. 1993;111:831-836.
- Ghafour IM, Foulds WS, Allan D, McClure E. Contrast sensitivity in diabetic subjects with and without retinopathy. *Br J Ophthalmol*. 1982;66:492-495.
- Della Sala S, Bertoni G, Somazzi L, Stubbe F, Wilkins AJ. Impaired contrast sensitivity in diabetic patients with and without retinopathy: a new technique for rapid assessment. *Br J Ophthalmol*. 1985;69:136-142.
- Banford D, North RV, Dolben J, Butler G, Owens DR. Longitudinal study of visual functions in young insulin dependent diabetics. *Ophthalmic Physiol Opt*. 1994;14:339-346.
- Verrotti A, Lobefalo L, Petitti MT, et al. Relationship between contrast sensitivity and metabolic control in diabetics with and without retinopathy. *Ann Med*. 1998;30:369-374.
- Sokol S, Moskowitz A, Skarf B, Evans R, Molitch M, Senior B. Contrast sensitivity in diabetics with and without background retinopathy. *Arch Ophthalmol*. 1985;103:51-54.
- Trick GL, Burde RM, Gordon MO, Santiago JV, Kilo C. The relationship between hue discrimination and contrast sensitivity deficits in patients with diabetes mellitus. *Ophthalmology*. 1988;95:693-698.
- Di Leo MA, Caputo S, Falsini B, et al. Nonselective loss of contrast sensitivity in visual system testing in early type I diabetes. *Diabetes Care*. 1992;15:620-625.
- Juen S, Kieselbach GF. Electrophysiological changes in juvenile diabetics without retinopathy. *Arch Ophthalmol*. 1990;108:372-375.
- Liska V, Dostalek M. Are contrast sensitivity functions impaired in insulin dependent diabetics without diabetic retinopathy? *Acta Medica (Hradec Kralove)*. 1999;42:133-138.
- Brinchmann-Hansen O, Bangstad HJ, Hultgren S, et al. Psychophysical visual function, retinopathy, and glycemic control in insulin-dependent diabetics with normal visual acuity. *Acta Ophthalmol (Copenh)*. 1993;71:230-237.

41. Akimov NP, Renteria RC. Spatial frequency threshold and contrast sensitivity of an optomotor behavior are impaired in the Ins2Akita mouse model of diabetes. *Behav Brain Res*. 2012;226:601-605.
42. Owsley C, Sekuler R, Siemsen D. Contrast sensitivity throughout adulthood. *Vision Res*. 1983;23:689-699.
43. PKC-DRS Study Group. The effect of ruboxistaurin on visual loss in patients with moderately severe to very severe nonproliferative diabetic retinopathy: initial results of the Protein Kinase C beta Inhibitor Diabetic Retinopathy Study (PKC-DRS) multicenter randomized clinical trial. *Diabetes*. 2005;54:2188-2197.
44. Strom C, Sander B, Klemp K, Aiello LP, Lund-Andersen H, Larsen M. Effect of ruboxistaurin on blood-retinal barrier permeability in relation to severity of leakage in diabetic macular edema. *Invest Ophthalmol Vis Sci*. 2005;46:3855-3858.
45. Aiello LP, Davis MD, Girach A, et al. Effect of ruboxistaurin on visual loss in patients with diabetic retinopathy. *Ophthalmology*. 2006;113:2221-2230.
46. Davis MD, Sheetz MJ, Aiello LP, et al. Effect of ruboxistaurin on the visual acuity decline associated with long-standing diabetic macular edema. *Invest Ophthalmol Vis Sci*. 2009;50:1-4.
47. Barber AJ, Antonetti DA, Kern TS, et al. The Ins2Akita mouse as a model of early retinal complications in diabetes. *Invest Ophthalmol Vis Sci*. 2005;46:2210-2218.
48. Feit-Leichman RA, Kinouchi R, Takeda M, et al. Vascular damage in a mouse model of diabetic retinopathy: relation to neuronal and glial changes. *Invest Ophthalmol Vis Sci*. 2005;46:4281-4287.
49. Zheng L, Du Y, Miller C, et al. Critical role of inducible nitric oxide synthase in degeneration of retinal capillaries in mice with streptozotocin-induced diabetes. *Diabetologia*. 2007;50:1987-1996.
50. Martin PM, Roon P, Van Ells TK, Ganapathy V, Smith SB. Death of retinal neurons in streptozotocin-induced diabetic mice. *Invest Ophthalmol Vis Sci*. 2004;45:3330-3336.
51. Smith SB, Duplantier J, Dun Y, et al. In vivo protection against retinal neurodegeneration by sigma receptor 1 ligand (+)-pentazocine. *Invest Ophthalmol Vis Sci*. 2008;49:4154-4161.
52. Sasaki M, Ozawa Y, Kurihara T, et al. Neurodegenerative influence of oxidative stress in the retina of a murine model of diabetes. *Diabetologia*. 2010;53:971-979.
53. Zhu SS, Ren Y, Zhang M, et al. Wld(S) protects against peripheral neuropathy and retinopathy in an experimental model of diabetes in mice. *Diabetologia*. 2011;54:2440-2450.
54. Asnaghi V, Gerhardinger C, Hoehn T, Adeboje A, Lorenzi M. A role for the polyol pathway in the early neuroretinal apoptosis and glial changes induced by diabetes in the rat. *Diabetes*. 2003;52:506-511.
55. Gubitosi-Klug RA, Talahalli R, Du Y, Nadler JL, Kern TS. 5-Lipoxygenase, but not 12/15-lipoxygenase, contributes to degeneration of retinal capillaries in a mouse model of diabetic retinopathy. *Diabetes*. 2008;57:1387-1393.
56. Berkowitz BA, Gadianu M, Bissig D, Kern TS, Roberts R. Retinal ion regulation in a mouse model of diabetic retinopathy: natural history and the effect of Cu/Zn superoxide dismutase overexpression. *Invest Ophthalmol Vis Sci*. 2009;50:2351-2358.
57. Oates PJ. Aldose reductase, still a compelling target for diabetic neuropathy. *Curr Drug Targets*. 2008;9:14-36.
58. Hotta N, Koh N, Sakakibara F, et al. Effect of an aldose reductase inhibitor on abnormalities of electroretinogram and vascular factors in diabetic rats. *Eur J Pharmacol*. 1997;326:45-51.
59. El-Remessy AB, Abou-Mohamed G, Caldwell RW, Caldwell RB. High glucose-induced tyrosine nitration in endothelial cells: role of eNOS uncoupling and aldose reductase activation. *Invest Ophthalmol Vis Sci*. 2003;44:3135-3143.
60. Obrosova IG, Minchenko AG, Vasupuram R, et al. Aldose reductase inhibitor fidarestat prevents retinal oxidative stress and vascular endothelial growth factor overexpression in streptozotocin-diabetic rats. *Diabetes*. 2003;52:864-871.
61. Cheung AK, Fung MK, Lo AC, et al. Aldose reductase deficiency prevents diabetes-induced blood-retinal barrier breakdown, apoptosis, and glial reactivation in the retina of db/db mice. *Diabetes*. 2005;54:3119-3125.
62. Tang J, Du Y, Petrash JM, Sheibani N, Kern TS. Deletion of aldose reductase from mice inhibits diabetes-induced retinal capillary degeneration and superoxide generation. *PLoS One*. 2013;8:e62081.
63. Samuels IS, Lee CA, Petrash JM, Peachey NS, Kern TS. Exclusion of aldose reductase as a mediator of ERG deficits in a mouse model of diabetic eye disease. *Vis Neurosci*. 2012;29:267-274.
64. Ludvigson MA, Sorenson RL. Immunohistochemical localization of aldose reductase II. Rat eye and kidney. *Diabetes*. 1980;29:450-459.
65. Kern TS, Engerman RL. Distribution of aldose reductase in ocular tissue. *Exp Eye Res*. 1981;33:175-182.
66. Chakrabarti S, Sima AA, Nakajima T, Yagihashi S, Greene DA. Aldose reductase in the BB rat: isolation, immunological identification and localization in the retina and peripheral nerve. *Diabetologia*. 1987;30:244-251.
67. Hegde KR, Hencin MG, Varma SD. Establishment of the mouse as a model animal for the study of diabetic cataracts. *Ophthalmic Res*. 2003;35:12-18.
68. Varma SD, Kinoshita JH. The absence of cataracts in mice with congenital hyperglycemia. *Exp Eye Res*. 1974;19:577-582.