

Necrotizing pneumonia and empyema caused by *Neisseria flavescens* infection

Ling Huang^{1,2*}, Lan Ma^{1,3*}, Kun Fan^{1,4}, Yang Li^{1,4}, Le Xie^{1,4}, Wenying Xia^{1,4}, Bing Gu^{1,4}, Genyan Liu^{1,4}

¹Department of Laboratory Medicine, the First Affiliated Hospital of Nanjing Medical University, Nanjing 210029, China; ²Department of Laboratory Medicine, the Second Hospital of Nanjing, Nanjing 210003, China; ³Department of Laboratory Medicine, Gaochun People's Hospital of Nanjing, Nanjing 211300, China; ⁴National Key Clinical Department of Laboratory Medicine, Nanjing 210029, China

*These authors contributed equally to this work.

Correspondence to: Genyan Liu. Department of Laboratory Medicine, the First Affiliated Hospital of Nanjing Medical University Guangzhou Road, No.300, Nanjing 210029, China. Email: liugenyan@njmu.edu.cn.

Abstract: *Neisseria flavescens* is an uncommon pathogen of human infection, pneumonia and empyema caused by *N. flavescens* is rarely reported. Herein, we report a 56-year-old diabetic patient presenting necrotising pneumonia and empyema due to *N. flavescens* infection. The main clinical manifestation of this patient was high fever, sticky pus and gradually aggravating dyspnea. The chest computed tomography (CT) scan showed there are mass of high density areas around hilus of the left lung, hollow sign with inflammation also appeared. A biopsy specimen was taken from the left principal bronchus by lung puncture biopsy and showed necrosis and inflammation. Microscopic examination of direct smear and culture of sticky pus, much more gram-negative diplococcus was present, pathogen was further identified by Vitek NH card, Vitek MS and confirmed as *N. flavescens* by 16S rRNA gene sequencing finally. Anti-infection therapy following the antimicrobial susceptibility test results was effectively. To our knowledge, this is the first report of pulmonary infection caused by *N. flavescens*.

Keywords: *Neisseria flavescens*; pneumonia; empyema; MALDI-TOF MS; 16S rRNA gene sequencing

Submitted Jan 18, 2014. Accepted for publication Feb 26, 2014.

doi: 10.3978/j.issn.2072-1439.2014.02.16

View this article at: <http://www.jthoracdis.com/article/view/2354/2942>

Introduction

Neisseria spp. are part of the commensal flora of mucosal membranes of humans and some animals, and are generally considered non-pathogenic except for *N. gonorrhoea* and *N. meningitidis*. *N. flavescens* often be found in the upper respiratory tract and the oropharynx of humans, and are rarely associated with infectious processes (1). However, when patients in special or immunocompromised conditions, *N. flavescens* can be isolated from blood or cerebrospinal fluid (CSF) occasionally (2-8), but never been isolated from lower respiratory tract.

Herein, we reported a case of a 58-year-old diabetic patient with fatal necrotising pneumonia and empyema due to *N. flavescens* infection. To our knowledge, this is the

first report that *N. flavescens* as the pathogen of severe low respiratory tract infection.

Case report

A 58-year-old man was admitted to the hospital because of necrotizing pneumonia and empyema in October 2013. He had experienced nausea, vomiting and little cough ten days before admission, after anti-infection therapy with some cephalosporin in local clinic, the symptoms once getting better, but two days before admission, the patient felt anhelation and dyspnea, then presented to the emergency department of our hospital, non symptomatic remission after dealing with cefodizime and methylprednisolone through intravenous injection temporary, then transferred to the

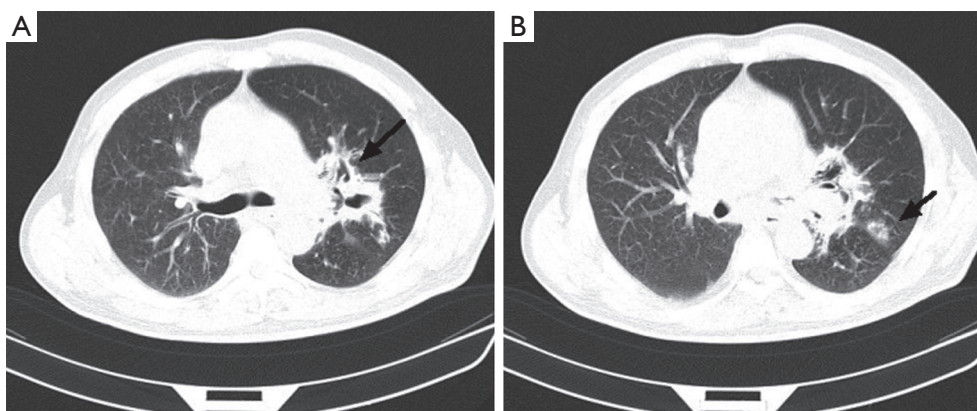


Figure 1 CT scan of the chest. (A) High-density shadow around the hilum of left lung (black arrow); (B) It appears that there is a hollow sign (black arrow) in the peripheral pulmonary. CT, computed tomography.

department of respiration with symptoms of high grade fever (highest temperature is 39.9 °C/103.82 F), chilling and severe cough with productive of yellow sputum finally.

He has hypertension for four years and controlled well. Four year history of type 2 diabetes and treated with melbine (DMBG) as well as Glipizide, but curative effect is not ideal for fasting blood-glucose more than 10 mmol/L. He also has a smoking history of 20 cigarettes per day for 40 years.

A chest computed tomogram (CT) showed high-density shadow around the hilum of left lung (*Figure 1A* as signed by black arrow), a hollow sign (*Figure 1B* as signed by black arrow) also exists in the left peripheral pulmonary. Initial laboratory tests showed the white blood cell (WBC) count was $36.04 \times 10^9/L$ (reference level, $4.0 \times 10^9 - 10.0 \times 10^9/L$), the neutrophil cell count and ratio was $33.3 \times 10^9/L$ (92.4%), the erythrocyte sedimentation rate (ESR) was 115 mm/H, the C-reactive protein (CRP) was 54.1 mg/L (reference level, <5 mg/L).

A transthoracic pulmonary fine-needle aspiration was performed when transferred to the department of respiration. Approximately 2 mL of purulent secretion was obtained and sent for microbiology tests. Direct smear Gram stain was performed and gram-negative diplococci and lots of polymorphonuclear leukocytes can be observed under microscope (*Figure 2A*), acid fast stain was also done and got negative results. The same material was inoculated onto chocolate agar and 5% sheep blood agar (bioMérieux, Shanghai, China). The agar media were incubated at 35 °C for 48 h, middle size, bluish grey round opaque colonies were observed. Gram-stain of the pure culture colony was also gram negative cocci. Elementary biochemical properties of this strain were oxidase positive, catalase positive while deoxyribonuclease (DNase) was negative.

The organism was identified with Vitek NH card and Vitek MS successively, but inconsistent results were got, Vitek NH (Ref. V1308 database) identified as *N. flavescens* (99% probability) while Vitek MS (Ref. V2.0 database) identified as *N. subflava* (89.70% probability). Finally, we confirmed this identification as *N. flavescens* (99% probability) by 16S rRNA gene sequencing.

In vitro susceptibility test with agar dilution method was done following the method mentioned in CLSI M45 for *Moraxella catarrhalis*. It is susceptible to penicillin, ampicillin/sulbactam, amikacin, ceftazidime, ciprofloxacin, Trimethoprim-sulfamethoxazole and piperacillin-tazobactam. After one week anti-infection therapy combined piperacillin-tazobactam and Trimethoprim-sulfamethoxazole, the gram negative diplococci was almost disappeared (*Figure 2B*). But the empyema was not released because of the inflammation and necrosis of cartilages tracheales (*Figure 3A,B*). Necrosis of cartilages tracheales lead to tracheal collapse and purulent secretion drainage very ineffective. Finally, the patient was got well after tracheal scaffold implantation and further anti-infective therapy for three weeks.

Discussion

Neisseria is a large genus of commensal bacteria that inhabit mucous membrane surfaces of warm-blooded hosts. There are 11 species that colonize humans include *N. gonorrhoeae*, *N. meningitidis*, *N. lactamica*, *N. flavescens*, *N. sicca*, *N. subflava*, *N. mucosa*, *N. cinerea*, *N. elongata*, *N. glycolytica* and *N. nitroreducens*. Most of these *Neisseria* species are normal inhabitants of the upper respiratory tract and are not considered pathogens (1,9). Up to date, only *N. meningitidis*, *N. gonorrhoeae*, *N. mucosa* and *N. sicca* have been reported as causative agents of pneumonia,

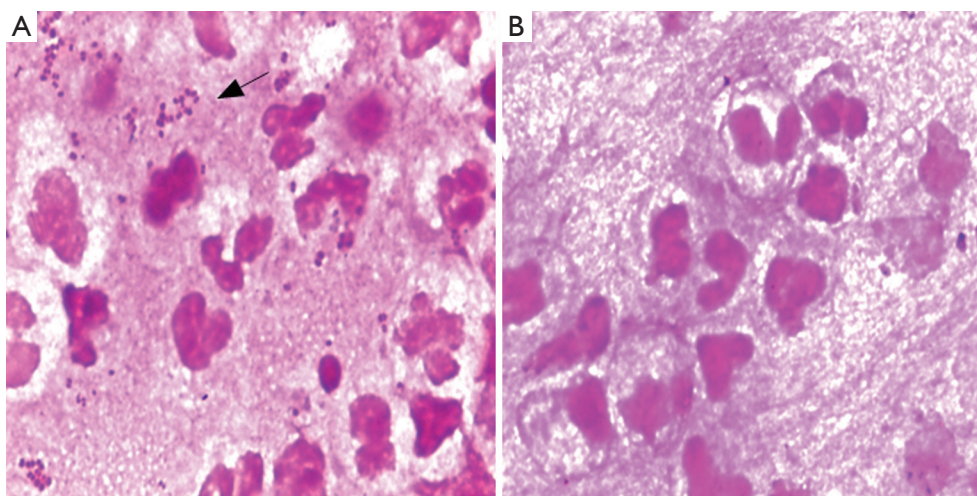


Figure 2 Direct smear Gram stain before and after anti-infection. (A) Direct smear Gram stain of pyogenic fluids before treatment. There are lots of gram-negative diplococcus as well as pyocyte infiltration; (B) Direct smear Gram stain of pyogenic fluids after effective treatment, the diplococcus disappeared. (Gram stain, 1,000 \times).

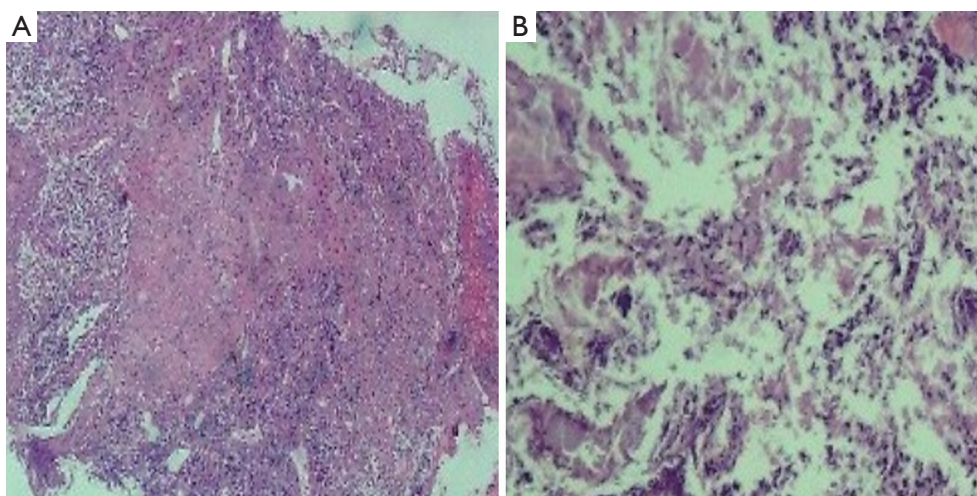


Figure 3 Biopsy of principal bronchus mucous membrane. (A) Biopsy of distal end of left principal bronchus mucous membrane with deeply acidophilic and fibrinoid necrosis; (B) Biopsy of distal end of left principal bronchus cartilage with deeply acidophilic, fibrinoid necrosis and exudation. (H&E stain, 200 \times).

empyema, bronchopneumonia or bronchiectasis (10-17). Necrotizing pneumonia with empyema caused by *N. flavescens* is the first time reported as we known. Besides as causative agent of pneumonia and empyema *N. flavescens* have else been published as pathogens of septicaemia, meningitis and endocarditis (4-8,18-20).

The clinical symptom and lab tests properties of this case are high fever rate, empyema, elevated WBC, increased CRP value and distinctive imaging changes, all these often lead to a fatal infection as reported infection caused by *N. flavescens* in

the other systems (4,6,7,19). We reviewed the literatures and analysed the possible reason may be included the following issues: *N. flavescens* is among the commensal flora of human upper respiratory tract, seldom cause human infection. Most of *N. flavescens* infected patients have severe basic diseases, for example, immunodeficiency and diabetes (2); There are remote causes like dental surgery history, vomiting, chemotherapy and co-infection with HIV or pseudomonas aeruginosa (18,21); Initial experienced clinical application of penicillin and cefixime often failed to cure

Table 1 Supplemental tests which permit differentiation among common gram negative diplococcus (GND)

GND	Oxidase test	Catalase reaction	DNAse test	Nitrate reduction	Acid from				Colistin susceptibility
					G	M	L	S	
<i>N. flavescens</i>	+	Weak	-	-	-	-	-	-	S
<i>N. gonorrhoeae</i>	+	Srong	-	-	+	-	-	-	R
<i>N. meningitides</i>	+	Strong	-	-	+	+	-	-	R
<i>M. catarrhalis</i>	+	Variable	+	+	-	-	-	-	R

Abbreviations: +, most strains positive; -, most strains negative; R, strains grow well on selective medium for *N. gonorrhoeae* and/or show no inhibition around a colistin disk (ten micrograms); acid from G (glucose), M (maltose), L (lactose), S (sucrose).

the *N. flavescens* infection for beta-lactamase producing and *penA* resistant gene expression (5,22-30); severe virulence and inflammatory response caused by lipooligosaccharide of *Neisseria* lead to septic shock and fibrinoid necrosis and exudation (31). In conclusion, we should pay more attention to human infection caused by *N. flavescens*.

Due to *N. flavescens* may cause severe infection, rapid and accurate identify this organism is more important. As described in this paper, Vitek NH card can be used for accurate identification, but Vitek MS V2.0 database doesn't include *N. flavescens* and should be developed in the future. Among the gram negative diplococcus often cause pulmonary infection, *N. flavescens* can be differentiated from *Moraxella catarrhalis* with DNAse test, differentiated from *N. gonorrhoeae* and *N. meningitides* with rapid acid detection tests and Colistin-susceptible test as summarized in *Table 1*.

Acknowledgements

We acknowledge bioMérieux for supplying Vitek MS and related reagents. This study was funded by the Key Laboratory for Laboratory Medicine of Jiangsu Province of China (No. XK201114). The funders had no role in study design, data collection and analysis, decision to publish, or preparation of the manuscript.

Disclosure: The authors declare no conflict of interest.

References

- Versalovic J. eds. Manual of Clinical Microbiology Bundle (Print and Digital Edition). ASM Press; 2011.
- Dang AT, Cotton S, Sankaran-Walters S, et al. Evidence of an increased pathogenic footprint in the lingual microbiome of untreated HIV infected patients. *BMC Microbiol* 2012;12:153.
- Kovalyk AP, Govda AV. Characteristics of microflora of laryngeal mucosa in healthy subjects and patients with cicatricial stenosis of the larynx. *Vestn Otorinolaringol* 2010;2:17-20.
- Quintero Otero S, Rubio Quiñones F, Hernández Gonzalez A, et al. Septic shock caused by *Neisseria flavescens*. *An Esp Pediatr* 1990;33:64-5.
- Sinave CP, Ratzan KR. Infective endocarditis caused by *Neisseria flavescens*. *Am J Med* 1987;82:163-4.
- Coovadia YM. *Neisseria flavescens* septicaemia with meningitis. A case report. *S Afr Med J* 1984;66:308-9.
- Wertlake PT, Williams TW Jr. Septicaemia caused by *Neisseria flavescens*. *J Clin Pathol* 1968;21:437-9.
- Prentice AW. *Neisseria flavescens* as a cause of meningitis. *Lancet* 1957;272:613-4.
- Ryan K, Ray CG, Ahmad N, et al. eds. *Sherris Medical Microbiology*, Fifth Edition. Mcgraw-hill, 2010.
- Gris P, Vincke G, Delmez JP, et al. *Neisseria sicca* pneumonia and bronchiectasis. *Eur Respir J* 1989;2:685-7.
- Thorsteinsson SB, Minuth JN, Musher DM. Postpneumonectomy empyema due to *Neisseria mucosa*. *Am J Clin Pathol* 1975;64:534-6.
- Enos WF, Beyer JC, Zimmet SM, et al. Unilateral lobar pneumonia with empyema caused by *Neisseria gonorrhoeae*. *South Med J* 1980;73:266-7.
- Yagyu Y, Sawaki M, Mikasa K, et al. A clinical study on five cases of respiratory infections caused by *Neisseria meningitidis*. *Kansenshogaku Zasshi* 1990;64:822-9.
- Ohtaki M, Tabeta H, Suzuki Y. Bronchopneumonia caused by *Neisseria meningitidis*--probable transmission by a family member who had been in Hong Kong. *Nihon Kyobu Shikkan Gakkai Zasshi* 1997;35:461-5.
- Legaria MC, Chadarevian M, Regueira M, et al. Non-pneumonia lower respiratory infection by *Neisseria meningitidis*. *Enferm Infecc Microbiol Clin* 1996;14:508-9.
- Ferrer Marcellés A, Andonegui Navarro M, Falcó Ferrer

- V, et al. *Neisseria meningitidis*: isolation from low respiratory tract secretions of adult patients. *Rev Clin Esp* 1996;196:741-6.
17. Barnes RV, Dopp AC, Gelberg HJ, et al. *Neisseria meningitidis*: a cause of nosocomial pneumonia. *Am Rev Respir Dis* 1975;111:229-31.
 18. Radke RA, Cunningham GC. A case of meningitis due to *Pseudomonas aeruginosa* (*Bacillus pyocyaneus*) and *Neisseria flavescens* with recovery. *J Pediatr* 1949;35:99-101.
 19. Jaroszyńska-Weinberger B, Slubicka A. 2 cases of purulent meningitis caused by *Neisseria flavescens* in the same environment. *Przegl Epidemiol* 1968;22:257-9.
 20. Branham SE, U.S. Public health service. A new meningococcus-like organism (*Neisseria flavescens* n. sp.) from epidemic meningitis. Washington,: U.S. Govt. print. off.; 1930.
 21. Szabo S, Lieberman JP, Lue YA. Unusual pathogens in narcotic-associated endocarditis. *Rev Infect Dis* 1990;12:412-5.
 22. Spratt BG, Zhang QY, Jones DM, et al. Recruitment of a penicillin-binding protein gene from *Neisseria flavescens* during the emergence of penicillin resistance in *Neisseria meningitidis*. *Proc Natl Acad Sci U S A* 1989;86:8988-92.
 23. Ameyama S, Onodera S, Takahata M, et al. Mosaic-like structure of penicillin-binding protein 2 Gene (penA) in clinical isolates of *Neisseria gonorrhoeae* with reduced susceptibility to cefixime. *Antimicrob Agents Chemother* 2002;46:3744-9.
 24. Tanaka M, Nakayama H, Huruya K, et al. Analysis of mutations within multiple genes associated with resistance in a clinical isolate of *Neisseria gonorrhoeae* with reduced ceftriaxone susceptibility that shows a multidrug-resistant phenotype. *Int J Antimicrob Agents* 2006;27:20-6.
 25. Spratt BG, Bowler LD, Zhang QY, et al. Role of interspecies transfer of chromosomal genes in the evolution of penicillin resistance in pathogenic and commensal *Neisseria* species. *J Mol Evol* 1992;34:115-25.
 26. Osaka K, Takakura T, Narukawa K, et al. Analysis of amino acid sequences of penicillin-binding protein 2 in clinical isolates of *Neisseria gonorrhoeae* with reduced susceptibility to cefixime and ceftriaxone. *J Infect Chemother* 2008;14:195-203.
 27. Maggs AF, Logan JM, Carter PE, et al. The detection of penicillin insensitivity in *Neisseria meningitidis* by polymerase chain reaction. *J Antimicrob Chemother* 1998;42:303-7.
 28. Lujan R, Zhang QY, Sáez Nieto JA, et al. Penicillin-resistant isolates of *Neisseria lactamica* produce altered forms of penicillin-binding protein 2 that arose by interspecies horizontal gene transfer. *Antimicrob Agents Chemother* 1991;35:300-4.
 29. Bowler LD, Zhang QY, Riou JY, et al. Interspecies recombination between the penA genes of *Neisseria meningitidis* and commensal *Neisseria* species during the emergence of penicillin resistance in *N. meningitidis*: natural events and laboratory simulation. *J Bacteriol* 1994;176:333-7.
 30. Genco CA, Knapp JS, Clark VL. Conjugation of plasmids of *Neisseria gonorrhoeae* to other *Neisseria* species: potential reservoirs for the beta-lactamase plasmid. *J Infect Dis* 1984;150:397-401.
 31. Zarantonelli ML, Huerre M, Taha MK, et al. Differential role of lipooligosaccharide of *Neisseria meningitidis* in virulence and inflammatory response during respiratory infection in mice. *Infect Immun* 2006;74:5506-12.

Cite this article as: Huang L, Ma L, Fan K, Li Y, Xie L, Xia W, Gu B, Liu G. Necrotizing pneumonia and empyema caused by *Neisseria flavescens* infection. *J Thorac Dis* 2014;6(5):553-557. doi: 10.3978/j.issn.2072-1439.2014.02.16