

# Optical Topography to measure variations in Regional Cerebral Oxygenation in an Infant supported on veno-arterial Extra-Corporeal Membrane Oxygenation

Maria D. Papademetriou<sup>1</sup>, Ilias Tachtsidis<sup>1</sup>, Murad Banaji<sup>1</sup>, Martin J. Elliott<sup>2</sup>, Aparna Hoskote<sup>2</sup> and Clare E. Elwell<sup>1</sup>

<sup>1</sup>Biomedical Optics Research Laboratory, Department of Medical Physics and Bioengineering, University College London, Gower Street, London WC1E 6BT

<sup>2</sup>Cardiothoracic Unit, Great Ormond Street Hospital for Children, London WC1N 3JH

**Abstract** Extracorporeal membrane oxygenation (ECMO) is a rescue therapy for patients with cardio-respiratory failure which exposes the patient to the risk for intracranial injury. We used a 12-channel optical topography system to monitor cerebral oxygenation in a venoarterial (VA) ECMO patient during alterations in the ECMO flows. Changes in oxy-(HbO<sub>2</sub>), deoxy-(HHb) and total-(HbT) haemoglobin concentrations were measured simultaneously with systemic and ECMO circuit parameters. Decreasing the flows resulted in a decrease in venous (SvO<sub>2</sub>) and arterial (SpO<sub>2</sub>) saturations. These were reflected in the haemoglobin data by a significant increase in HHb of varying magnitude across the 12 channels and moderate changes in HbO<sub>2</sub> suggestive of cerebral arterial dilation to compensate for the lack of oxygen delivery. In the patient studied here ECMO flows appear to present a significant haemodynamic challenge to cerebral circulation.

## 1 Introduction

Extracorporeal membrane oxygenation (ECMO) is a life support system incorporating cardiopulmonary bypass in infants and children with intractable cardio-respiratory failure. Establishing ECMO involves cannulation of major vessels in the neck—right common carotid artery (RCCA) and internal jugular vein (IJV). Maintaining and weaning from ECMO requires manipulation of ECMO flows, which can affect cerebral blood flow and potentially lead to neurologic complications. Reports show that about 28-52% of ECMO survivors show abnormal neuroimaging related both to pre-ECMO events and to the ECMO procedure itself [1].

Near infrared spectroscopy (NIRS) has the advantage of monitoring cerebral oxygenation non-invasively and continuously by the bedside. NIRS was used on

ECMO patients to study the effect of cannulation on cerebral oxygenation. Ligation of RCCA was associated with a decrease in HbO<sub>2</sub>, an increase in HHb [2] and a decrease in tissue oxygen saturation (TOS) [3] while no changes were seen during IJV ligation. Also, an increase in HbO<sub>2</sub>, a decrease in HHb and an increase in TOS was reported after ECMO was established compared to pre-cannulation values. In a previous study we used spectral analysis on HbO<sub>2</sub> and identified vasomotion, respiratory, cardiac and ECMO circuit roller pump oscillations in cerebral and peripheral circulation during ECMO flow changes [4]. To date, conventional NIRS uses single or dual channel systems with the optodes usually placed on the forehead of the patients providing information related to perfusion of only a small area of the anterior cerebrum and therefore do not allow evaluation of the status of the cerebral circulation and oxygenation in the extended cerebral regions.

The aim of this study is to use optical topography (OT) to monitor multisite brain oxygenation responses during manipulations in the ECMO circuit flows.

## 2 Methods

In this pilot study OT data were obtained from a one-month-old veno-arterial (VA) ECMO patient undergoing changes in the ECMO circuit flows. Flow in the ECMO circuit was successively decreased by 10% from initial flow every 10-15 minutes, down to 70% of the initial flow and it was then gradually brought back to initial flow. During this procedure ETG-100 OT system (Hitachi Medical Ltd.) was used to measure changes in HbO<sub>2</sub>, HHb and HbT (HbO<sub>2</sub> + HHb) haemoglobin concentrations using the modified Beer-Lambert Law. A novel neonatal cap was designed and constructed to accommodate the optical fibres in a 3x3 array (inter-optode distance = 3cm) utilizing spring-loaded optical fibre holders. The probe array was positioned on the patient's head with the middle optode corresponding to C<sub>z</sub> of the 10-20 EEG electrode placement system [5]. This optode configuration allows for optical data to be collected from 12 channels distributed symmetrically around C<sub>z</sub> and covering an area of 6x6 cm<sup>2</sup>. Optical data collected at a sampling frequency of 5Hz were resampled at 1Hz and low pass filtered at 0.05Hz to remove physiological noise. For the conversion of the optical attenuation changes to chromophore concentration changes a differential pathlength factor (DPF) of 4.99 was applied [6]. Multimodal data were collected synchronously with the optical data that included systemic parameters: arterial blood pressure (ABP), heart rate (HR), respiration rate (RR), end-tidal CO<sub>2</sub>, temperature and arterial saturation (SpO<sub>2</sub>); and ECMO circuit parameters: venous saturation (SvO<sub>2</sub>), arterial saturation measured at the arterial cannula side (SaO<sub>2</sub>), haematocrit and ECMO flow.

Changes in HbO<sub>2</sub>, HHb and HbT between phase I [from baseline flow (100%) to minimum flow (70%)] and phase II [from 70% flow back to baseline flow] were calculated from the differences in mean values over a 60-s period just before changing the flow. The results were analysed using a paired t-test (p<0.05).

### 3 Results

Figure 1 shows concentration changes in HbO<sub>2</sub> (red), HHb (blue) and HbT (black) collected from the 12 channels during changes in ECMO flows. The channel configuration is shown by the schematic at the top left of the figure. As annotated in the haemoglobin plots of channel 1, the vertical dotted lines represent the time at which a change in flow was induced so that each section in the plots corresponds to a specific flow. Sequential reduction in ECMO flows resulted in considerable increase in HHb and HbT in all 12 channels, with moderate increases seen in HbO<sub>2</sub>. Table 1 lists the responses in HHb, HbO<sub>2</sub> and HbT during phase I and phase II. The range in the change of HHb concentration during phase I was from 9.7µM (channel 8) to 25.1µM (channel 10). Regional variations in cerebral oxygenation can be seen, particularly interhemispheric differences, e.g. comparing channel 10 (right parietal lobe) with channel 8 (left parietal lobe).

The variation in HR, MAP, SpO<sub>2</sub> and SvO<sub>2</sub> during flow changes are shown in Figure 2. Figure 3 shows the responses of these parameters during phase I and phase II. In this patient a decrease in ECMO flow is associated with a decrease in SvO<sub>2</sub> and SpO<sub>2</sub> and an increase in HR and MAP. The effect is reversed when the flow is gradually increased back to baseline. Similar to the haemoglobin concentration data, these systemic and ECMO circuit parameters do not return to their baseline values by the end of the monitoring period.

### 4 Discussion

This single patient study showed significant changes in systemic oxygenation parameters and cerebral haemoglobin concentration in response to changes in ECMO flows. Reduction in flows was associated with a decrease in SvO<sub>2</sub> and SpO<sub>2</sub> and a significant increase in HHb but in the absence of a decrease in HbO<sub>2</sub>.

A decrease in ECMO flow is associated with a decrease in oxygen delivery especially in the early course of ECMO treatment when the heart and lungs have not fully recovered. If ECMO flow is inadequate, there is a reduction in SvO<sub>2</sub> and a subsequent decrease in SpO<sub>2</sub>. Consequently, in an effort to increase cardiac output, there is a compensatory increase in HR. The decrease in SpO<sub>2</sub> and SvO<sub>2</sub> seen in this patient suggest that the lowering ECMO flows has a similar effect to a hypoxemic challenge and the absence of decrease in HbO<sub>2</sub> in relation to increase in HHb could be explained by arterial dilation as a compensatory response to decreased blood flow due to decreased ECMO flows [7].

The changes seen in the total haemoglobin during this challenge in this patient are relatively large compared to the suggested total cerebral blood volume in an infant of 2.2mL/100g (50µM) [8]. Van Heijst et al. [2] report changes in HbO<sub>2</sub> and HHb in the order of 1µmol/100g (10µM) 60 min after ECMO induction and suggest no interhemispheric differences. Eljike et al. [3] report no relationship be-

tween ECMO flow and tissue oxygen saturation but changes in the individual HbO<sub>2</sub> and HHb parameters were not reported.

We noted significant differences between channel 10 and 8 which are difficult to explain and could be related to alterations in cerebral blood flow related to ligation of the RCCA and IJV; however, we need further data to support this. In addition, regional variations in cerebral oxygenation could be related both to the procedure itself and to inhomogeneous differential pathlength factor [9]. The changes associated with ECMO flows did not return to baseline as the flow changes were reversed in the time period of the study. This might have been seen if we had extended the duration of the monitoring which we plan to do with further studies.

## 5 Conclusions

Multichannel optical topography can provide information on regional cerebral haemodynamics and oxygenation in ECMO patients. Simultaneous measurement of systemic and cerebral parameters can be used to characterise the response to changes in ECMO flows. In the patient studied here ECMO flows appear to present a significant haemodynamic challenge to cerebral circulation. ECMO flow changes may have the potential to inform on cerebral autoregulation but further studies are required to more fully explore the relationship between regional variations in cerebral oxygenation during different ECMO phases.

**Acknowledgment** This work is supported by Hitachi Medical Ltd.

## References

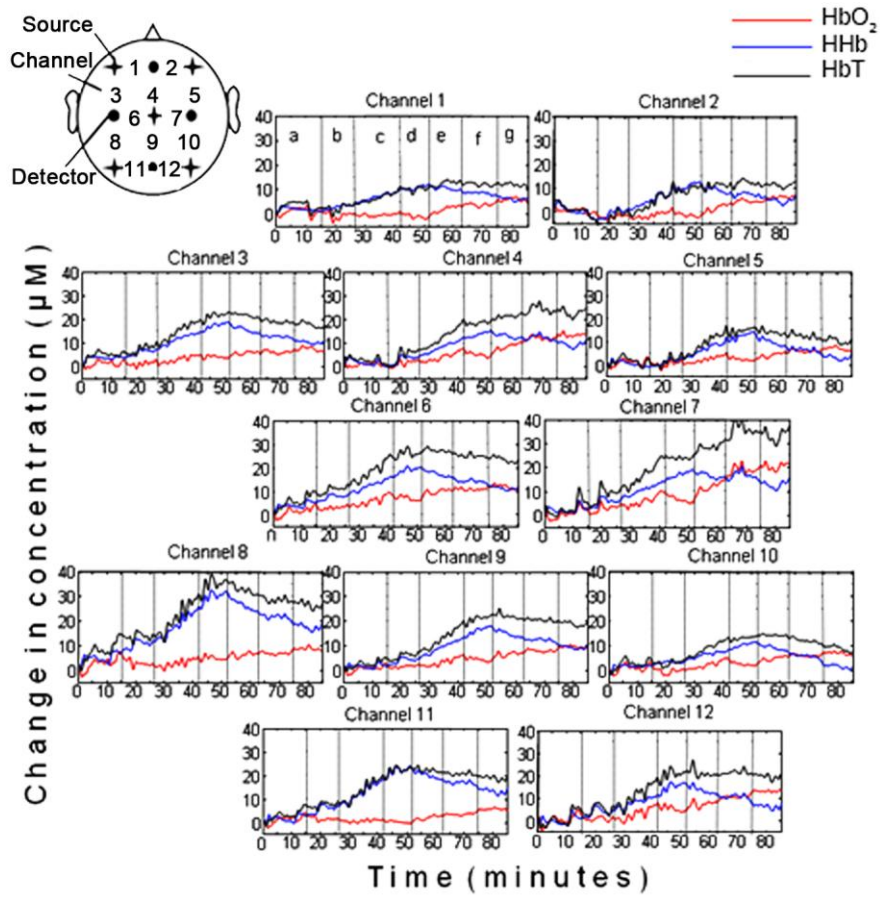
1. Bulas D, Glass P (2005) Neonatal ECMO: Neuroimaging and neurodevelopmental outcome. *Seminars in Perinatology* 29: 58-65
2. Van Heijst A, Liem D, Hopman J, Van der Staak F, Sengers R (2004) Oxygenation and hemodynamics in the left and right cerebral hemispheres during induction of veno-arterial extracorporeal membrane oxygenation. *J Pediatr* 144: 223-228
3. Ejike JC, Schenkman KA, Seidel K, Ramamoothy C, Roberts JS (2006) Cerebral oxygenation in neonatal and pediatric patients during veno-arterial extracorporeal life support. *Pediatr Crit Care Med* 7: 154-158
4. Papademetriou MD, Tachtsidis I, Leung TE, Elliott MJ, Hoskote A, Elwell CE (2010) Cerebral and Peripheral tissue oxygenation in Infants and Children supported on ECMO for Cardio-Respiratory failure. *Adv Exp Med Biol* 662: 447-453
5. Jasper H (1958) Report to the committee on methods and clinical examination in Electroencephalography. *Electroencephalogr Clin Neurophysiol* 10: 371-375
6. Duncan A, Meek JH, Clemence M, Elwell CE, Tysczuk L, Cope M, Delpy DT (1995) Optical pathlength measurements on adults head, calf and forearm and the head of the newborn infant using phase resolved optical spectroscopy. *Phys Med Biol* 40: 295-304

7. Hurn PD, Traystman RJ (2002) Changes in arterial gas tension. In: Edvinsson L, Krause DN, eds. Cerebral Blood Flow and Metabolism. Philadelphia: Lippincott Williams & Wilkins, 384-394
8. Wyatt JS, Cope M, Delpy DT, Richardson CE, Edwards AD, Wray S, Reynolds EOR (1990) Quantitation of cerebral blood volume in human infants by near-infrared spectroscopy. J Appl Physiol 68: 1086-1091
9. Katagiri A, Dan I, Tuzuki D, Okamoto M, Yokose N, Igarashi K, Hoshino T, Fujiwara T, Katayama Y, Yamaguchi Y, Sakatani K (2010) Mapping of the optical pathlength of human adult head at multi-wavelengths in near infrared spectroscopy. Adv Exp Med Biol 662: 213-

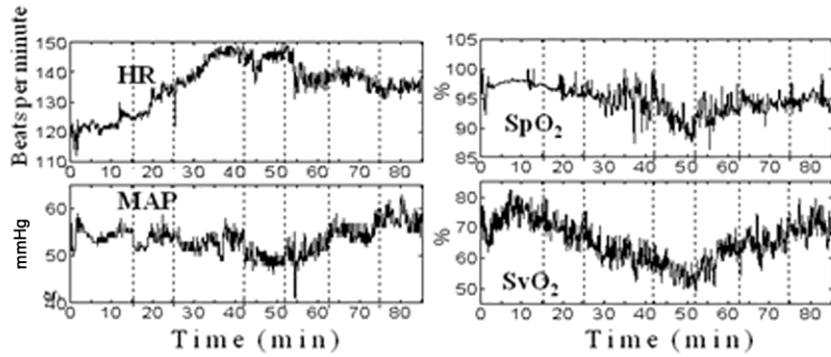
Table 1: Mean changes in HHb, HbO<sub>2</sub> and HbT during phases I [between baseline flow (100%) and minimum flow (70%)] and II (between minimum flow and return to baseline )

Channel	HHb (μM)		HbO <sub>2</sub> (μM)		HbT (μM)	
	I	II	I	II	I	II
1	<b>11.2</b>	<b>-6.1</b>	<b>-2.9</b>	<b>7.0</b>	<b>8.3</b>	<b>1.0</b>
2	<b>15.9</b>	<b>-6.5</b>	<b>-1.2</b>	<b>8.2</b>	<b>14.7</b>	<b>1.7</b>
3	<b>15.2</b>	<b>-8.7</b>	<b>1.4</b>	<b>2.8</b>	<b>16.5</b>	<b>-5.9</b>
4	<b>14.8</b>	<b>-4.7</b>	<b>3.8</b>	<b>9.2</b>	<b>18.6</b>	<b>4.5</b>
5	<b>14.9</b>	<b>-10.8</b>	<b>-0.3</b>	<b>4.2</b>	<b>11.8</b>	<b>-6.6</b>
6	<b>15.0</b>	<b>-9.2</b>	<b>1.9</b>	<b>4.8</b>	<b>14.6</b>	<b>-4.5</b>
7	<b>16.2</b>	<b>-4.4</b>	<b>3.1</b>	<b>15.8</b>	<b>16.9</b>	<b>11.4</b>
8	<b>25.1</b>	<b>-14.7</b>	<b>-2.8</b>	<b>3.7</b>	<b>19.4</b>	<b>-11.1</b>
9	<b>16.1</b>	<b>-8.7</b>	<b>1.3</b>	<b>5.2</b>	<b>22.3</b>	<b>-3.5</b>
10	<b>9.7</b>	<b>-10.8</b>	<b>-0.6</b>	<b>4.3</b>	<b>17.4</b>	<b>-6.5</b>
11	<b>20.6</b>	<b>-10.7</b>	<b>-4.3</b>	<b>5.8</b>	<b>16.3</b>	<b>-5.0</b>
12	<b>15.7</b>	<b>-11.0</b>	<b>0.5</b>	<b>9.2</b>	<b>16.2</b>	<b>-1.8</b>

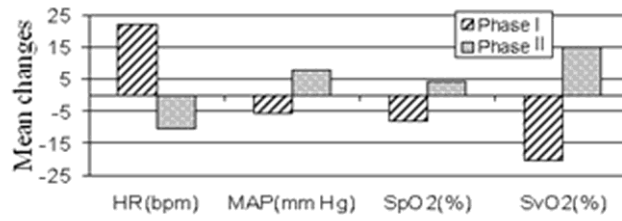
Note: Bold letters indicate that changes are statistically significant (p<0.05)



**Fig. 1** HbO<sub>2</sub>, HHb and HbT concentration changes from 12 channels during ECMO circuit flow changes. Each vertical line in the figures denotes where the ECMO circuit flow change occurred as annotated on channel 1 [a=baseline (100% flow), b=90% flow, c=80% flow, d=70% flow, e=80% flow, f=90% flow, g=100% flow].



**Fig 2** HR, MAP, SpO<sub>2</sub> and SvO<sub>2</sub> during ECMO circuit flow changes.



**Fig 3** Mean changes in systemic and ECMO parameters during phases I and II.