

Imatinib and ruxolitinib association: first experience in two patients

We report the first case of 2 patients with a previous diagnosis of post-polycythemic (PV) myelofibrosis who developed chronic myeloid leukemia (CML) seven years later, both treated with an association of a tyrosine-kinase inhibitor (imatinib) and a JAK1/JAK2 inhibitor (ruxolitinib).

In 1992, a 46-year old man presented with splenomegaly and elevated red cell counts. Bone marrow morphological analysis was performed and a diagnosis of PV was made according to Polycythemia Vera Study Group (PVSG) criteria. The patient was first treated with phlebotomy and subsequently with hydroxyurea. In April 2005, after increase of splenomegaly (20 cm below costal margin), decrease of hemoglobin (Hb) and loss of phlebotomy requirement, bone marrow evaluation was performed documenting post-PV myelofibrosis. Cytogenetic analysis showed normal karyotype. Molecular study was negative for BCR-ABL1 rearrangement, and positive for JAK2 V617F mutation, with an allele burden of 47%. Retrospective evaluation of the International Prognostic Scoring System (IPSS) resulted as intermediate risk-1.¹ As myeloblasts appeared in peripheral blood, in September 2011 bone marrow analysis confirmed the diagnosis of post-PV myelofibrosis with marked increase of collagen fibers (MF-3).² Cytogenetic analysis revealed t(9;22)(q34;q11.2) (2/30), suggesting the presence of a BCR-ABL1-positive-CML clone. PCR analysis showed a BCR-ABL1 transcript (b2a2). As a consequence, imatinib therapy was administered at 400 mg daily, while cytoreductive treatment was stopped. In January 2013, complete cytogenetic and major molecular responses were achieved, but no effect was observed on the myelofibrosis. Moreover, JAK2 V617F quantitative analysis displayed a gradual increase in allele burden; meanwhile, splenomegaly growth and the appearance of constitutional symptoms were observed. JAK1/JAK2 inhibitor ruxolitinib at 15 mg BID was added to imatinib therapy, the dosage of which was reduced to 300 mg daily. Already after three months of ruxolitinib treatment, there was a significant decrease in splenomegaly (12 cm below costal margin), an improvement of constitutional symptoms and a reduction of JAK2 allele burden (Figure 1). No significant change in bone marrow fibrosis was detected. However, a dosage reduction of ruxolitinib to 10 mg BID was required as hematologic toxicity (grade 3 anemia and grade 1 thrombocytopenia) was observed. At the last follow up, a significant reduction of spleen length (up to 8 cm below costal margin) was detected, no constitutional symptoms emerged, and the patient required only a slightly more frequent transfusion support.

In December 2000, a 48-year old man with splenomegaly was diagnosed with PV after recovering for transient ischemic attack (TIA). Cytogenetic analysis showed normal karyotype. He started warfarin and hydroxyurea, at a dose of 1500 mg daily until May 2005, these were suspended due to the appearance of perimallolar ulcers, after which 6-mercaptopurine therapy was started. JAK2 V617F mutation was detected with an allele burden of 89%. Seven years later, increase of splenomegaly (21 cm below costal margin) was observed. Bone marrow biopsy was performed and post-PV myelofibrosis was appreciated (MF-2 to MF-3).²

At cytogenetic evaluation t(9;22)(q34;q11.2) (20/20) was detected and PCR analysis showed BCR-ABL1 transcript (b3a2). CML diagnosis associated with post-PV myelofibrosis (IPSS: intermediate risk-1)¹ was made. The patient stopped the previous therapy and started imatinib at a daily

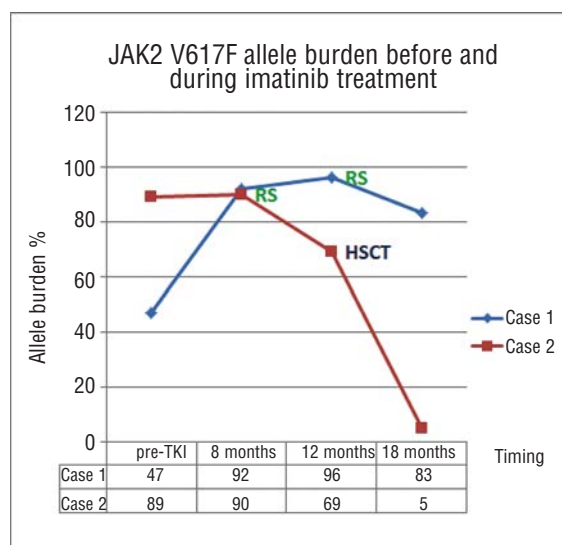


Figure 1. JAK2 V617F allele burden over time. RS: ruxolitinib start; HSCT: allogeneic hematopoietic stem cell transplantation.

dose of 400 mg. Imatinib was well tolerated with only minor side effects, and a complete cytogenetic response was achieved after six months. JAK2 V617F quantitative analysis displayed a gradual increase of allele burden up to 91%. Moreover, in November 2012, constitutional symptoms appeared and spleen size grew; JAK1/JAK2 inhibitor ruxolitinib was added initially at a daily dose of 20 mg BID and subsequently increased at 25 mg. Treatment was initially well tolerated, with a reduction of splenomegaly (17 cm below costal margin), allele burden (Figure 1) and increase in Hb level; unfortunately, two months later, the emergency of hematologic toxicity (grade 3 anemia and grade 3 thrombocytopenia) led clinicians to stop both ruxolitinib and imatinib treatments. Bone marrow biopsy showed slight and focal reduction of collagen fibers (Figure 2), but considering the side-effects of the previous therapy and an available HLA identical sibling donor, allogeneic hematopoietic stem cell transplantation was performed.

Seven months later cytogenetic analysis showed normal karyotype, BCR-ABL1 rearrangement was undetectable, and JAK2 V617F quantitative analyses displayed a significant decrease up to 5%.

Imatinib mesylate is the first TKI approved for the treatment of patients with CML-chronic phase,³ JAK1/JAK2 inhibitor ruxolitinib is the first in-class drug approved for the treatment of intermediate and high-risk MF and marked significant advancement in the therapeutic approach to this disorder.⁴⁻⁷ Recently, Quintarelli *et al.*⁸ demonstrated *in vitro* that ruxolitinib synergizes with TKIs to induce CML progenitors apoptosis; therefore, their association could eradicate BCR-ABL1-positive cells, thus overcoming drug resistance in CML patients. In the cases we report, imatinib was highly active on CML clone, but it was followed by a progressive increase of JAK2 V617F allele burden. This is in line with the previous findings that inhibition of the BCR-ABL1-positive clone is associated with the expansion of the JAK2 V617F-positive one.^{9,10} Meanwhile, ruxolitinib treatment was effective on splenomegaly and constitutional symptoms, but an adjustment of dose was required after the appearance of bone marrow toxicity, e.g. thrombocytopenia and anemia, which are reported to occur in 39% and 43% of cases, respectively.¹¹⁻¹³ In case 1, as the Hb level was already signif-

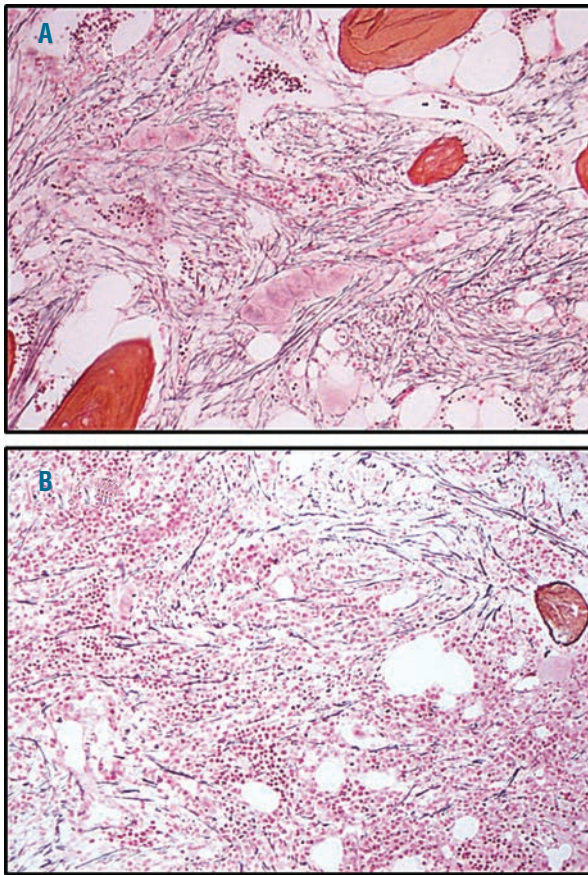


Figure 2. Case 2 (A) post-PV myelofibrosis at baseline displaying diffuse and dense increase in reticulin fibers, with extensive inter-sections and coarse bundles of collagen (MF-3); (B) slight and focal reduction of reticulin and collagen fibers after ruxolitinib therapy.

icantly reduced, we preferred a low dose of ruxolitinib and a reduction of imatinib therapy in order to prevent the well-known hematologic side-effects of these treatments. On the contrary, in case 2, the full dose of both drugs was given and the appearance of hematologic toxicity required either imatinib or ruxolitinib to be stopped. In both cases, after four months of ruxolitinib therapy, a considerable reduction of JAK2 V617F allele burden was observed, thus suggesting the efficacy of ruxolitinib in inhibiting the JAK2 V617F-positive clone (Figure 1).

Of note, in case 2, a slight and focal reduction of reticulin and collagen fibrosis was documented (Figure 2) and this observation is in line with those recently reported from Kvaniscka *et al.*¹⁴ and Wilkins *et al.*¹⁵

In conclusion, our experience suggests that the association of imatinib and ruxolitinib for the treatment of patients with the coexistence of BCR-ABL1 rearrangement and JAK2 V617F mutation could be considered after a dosage adjustment of both tyrosine-kinase and JAK1/JAK2 inhibitors.

Alessandra Iurlo,^{1,4} Umberto Gianelli,² Davide Rapezzi,³ Daniele Cattaneo,⁴ Elisa Fermo,⁴ Francesca Binda,⁴ Elisa Santambrogio,⁴ Cristina Bucelli,⁴ and Agostino Cortelezzi²

¹Oncohematology Unit of the Elderly, Oncohematology Division, IRCCS Ca' Granda – Maggiore Policlinico Hospital Foundation, and

University of Milan Medical School, Milan; ²Hematopathology Service, Division of Pathology, IRCCS Ca' Granda – Maggiore Policlinico Hospital Foundation, and University of Milan Medical School, Milan; ³Division of Hematology, Santa Croce e Carle Hospital, Cuneo; and ⁴Oncohematology Division, IRCCS Ca' Granda – Maggiore Policlinico Hospital Foundation, and University of Milan Medical School, Italy

Correspondence: aiurlo@policlinico.mi.it
doi:10.3324/haematol.2013.102525

Key words: myelofibrosis, post-polycythemia vera, imatinib, ruxolitinib, chronic myeloid leukemia.

Information on authorship, contributions, and financial & other disclosures was provided by the authors and is available with the online version of this article at www.haematologica.org.

References

- Cervantes F, Dupriez B, Pereira A, Passamonti F, Reilly JT, Morra E, et al. New prognostic scoring system for primary myelofibrosis based on a study of the International Working Group for Myelofibrosis Research and Treatment. *Blood*. 2009;113(13):2895-901.
- Thiele J, Kvasnicka HM, Facchetti F, Franco V, van der Walt J, and Orazi A. European consensus on grading bone marrow fibrosis and assessment of cellularity. *Haematologica*. 2005;90(8):1128-32.
- Druker BJ, Lydon NB. Lessons learned from the development of an abl tyrosine kinase inhibitor for chronic myelogenous leukemia. *J Clin Invest*. 2000;105:3-7.
- Verstovsek S, Kantarjian H, Mesa RA, Pardanani AD, Cortes-Franco J, Thomas DA, et al. Safety and efficacy of INCB018424, a JAK1 and JAK2 inhibitor, in myelofibrosis. *N Engl J Med*. 2010;363(12):1117-27.
- Harrison C, Vannucchi AM. Ruxolitinib: a potent and selective Janus kinase 1 and 2 inhibitor in patients with myelofibrosis. An update for clinicians. *Ther Adv Hematol*. 2012;3(6):341-54.
- Mascarenhas JO, Orazi A, Bhalla KN, Champlin RE, Harrison CN, Hoffman R. Advances in myelofibrosis: a clinical case approach. *Haematologica*. 2013;98(10):1499-509.
- Mesa RA, Kiladjan JJ, Verstovsek S, Al-Ali HK, Gotlib JR, Gisslinger H, et al. Comparison of placebo and best available therapy for the treatment of myelofibrosis in the phase 3 COMFORT studies. *Haematologica* 2013 [Epub ahead of print].
- Quintarelli C, De Angelis B, Erichiello S, Caruso S, Esposito N, Colavita I, et al. Selective strong synergism of Ruxolitinib and second generation tyrosine kinase inhibitors to overcome bone marrow stroma related drug resistance in chronic myelogenous leukemia. *Leuk Res*. 2014;38(2):236-42.
- Jallades L, Hayette S, Tigaud I, Johnston A, Coiffier B, Magaud JP, Ffrench M. Emergence of therapy-unrelated CML on a background of BCR-ABL-negative JAK2V617F-positive chronic idiopathic myelofibrosis. *Leuk Res*. 2008;32(10):1608-10.
- Cambier N, Renneville A, Cazaentre T, Soenen V, Cossement C, Giraudier S, et al. JAK2V617F-positive polycythemia vera and Philadelphia chromosome-positive chronic myeloid leukemia: one patient with two distinct myeloproliferative disorders. *Leukemia*. 2008;22(7):1454-5.
- Tefferi A, Litzow M, Pardanani A. Long-term outcome of treatment with ruxolitinib in myelofibrosis. *N Engl J Med*. 2011;365(15):1455-7.
- Mesa RA, Gotlib J, Gupta V, Catalano JV, Deininger MW, Shields AL, et al. Effect of ruxolitinib therapy on myelofibrosis-related symptoms and other patient-reported outcomes in COMFORT-I: a randomized, double-blind, placebo-controlled trial. *J Clin Oncol*. 2013;31(10):1285-92.
- Harrison C, Kiladjan JJ, Al-Ali HK, Gisslinger H, Waltzman R, Stalbovska V, et al. JAK inhibition with ruxolitinib versus best available therapy for myelofibrosis. *N Engl J Med*. 2012;366(9):787-98.
- Kvasnicka H, Thiele J, Bueso-Ramos CE, Sun W, Cortes J, Kantarjian HM, and Verstovsek S. Long-term intervention effects on bone marrow morphology in myelofibrosis: patients treated with ruxolitinib and best available therapy. *Haematologica*. 2013;98(Suppl 1): Abstract S591.
- Wilkins BS, Radia D, Woodley C, El Farhi S, Keohane C, Harrison CN. Resolution of bone marrow fibrosis in a patient receiving JAK1/JAK2 inhibitor treatment with ruxolitinib. *Haematologica*. 2013;98(12):1872-6.