



Contents lists available at ScienceDirect

International Journal for Parasitology: Parasites and Wildlife

journal homepage: www.elsevier.com/locate/ijppaw

Brief Report

Angiostrongylus vasorum in wolves in Italy ☆

Claudia Eleni ^a, Claudio De Liberato ^a, Dena Azam ^b, Eric R. Morgan ^{b,*}, Donato Traversa ^c

^a Istituto Zooprofilattico Sperimentale delle Regioni Lazio e Toscana, Italy

^b School of Biological Sciences, University of Bristol, UK

^c Faculty of Veterinary Medicine, University of Teramo, Italy



ARTICLE INFO

Article history:

Received 31 December 2012

Revised 28 October 2013

Accepted 29 October 2013

Keywords:

Lungworm
Angiostrongylosis
Canid
Epidemiology
Wolf
Wildlife disease
Pathology
One health

ABSTRACT

In the past decade, the parasitic nematode *Angiostrongylus vasorum* has attracted attention for its emergence in previously free areas and for the rise in clinical cases in domestic dogs. Italy is regarded as one of the countries where this potentially life-threatening parasite is spreading, especially due to bridging infections between wildlife and domestic dogs. The present article describes the presence of *A. vasorum* in wolves from Italy. Nematodes were observed in histological sections of three wolves found dead in Rome province, central Italy. Morphological and molecular identification of the nematodes, by polymerase chain reaction of rDNA ITS-2 and sequencing, confirmed the nematodes to be *A. vasorum*, with 99% genetic homology with *A. vasorum* from sympatric dogs. This is the second report of this species in wolves and the first in this host in Italy, and coincides with increasing records of *A. vasorum* in dogs and foxes in Italy. Implications for the epidemiology of this emerging parasite and for wildlife health are concisely discussed.

© 2013 The Authors. Published by Elsevier Ltd. All rights reserved.

1. Introduction

The wolf (*Canis lupus*) is undergoing a population recovery in Europe, aided by legal protection and changes in human attitudes towards wolves and their conservation (Boitani, 2003). Disease has been frequently acknowledged as a major issue in the conservation of wild carnivores, especially where potential exists for spillover of generalist pathogens from domestic and wild canids (Craft et al., 2009; Alexander et al., 2010), and disease control has been employed to support conservation of wolves in Ethiopia (Randall et al., 2006). However, limited published information exists on the health status or parasite fauna of wolves in Europe. Sarcopic mange is considered to have potential but unconfirmed impacts on wolf populations in Spain (Oleaga et al., 2011). In Italy, wolves are also expanding from previously small, isolated populations (Lucchini et al., 2004; Galaverni et al., 2013). The emerging eye-worm *Thelazia callipaeda* has been found in Italian wolves and discussed in the light of reservoirs of zoonotic disease (Otranto

et al., 2007), but parasite impacts on Italian wolf health and population viability remain unstudied.

Angiostrongylus vasorum is a nematode parasite of dogs and other canids, occupying the heart and pulmonary blood vessels in its adult form, and using gastropod mollusc intermediate hosts (Morgan et al., 2005). Infection can cause a wide range of disease outcomes in dogs, including mild to severe respiratory disease, as well as bleeding disorders that manifest in various ways (Koch and Willeesen, 2009), while in foxes cardio-respiratory pathology has been demonstrated (Morgan et al., 2008; Willeesen et al., 2008). Although the parasite has long been recognised, in recent years it has emerged as an increasing clinical concern in dogs in endemic areas, as well as in new areas in which parasite presence was not previously recorded (Jefferies et al., 2010; Traversa et al., 2010; Conboy, 2011). The expansion of current endemic foci of *A. vasorum* and the establishment of further new endemic foci are supported by recent events described from Italy, with several published clinical cases in dogs and antibody seroprevalence of 0.8% in the general canine population in Tuscany (Guardone et al., 2013). In fact, in this country *A. vasorum* infection was first reported over 20 years ago in red foxes and for a long time the infection was likely confined to this host with no descriptions in domestic dogs. By 2002 angiostrongylosis was reported with increasing frequency in dogs, in which it can cause severe pathology, and now it is considered endemic throughout the country (Traversa et al., 2013).

☆ This is an open-access article distributed under the terms of the Creative Commons Attribution-NonCommercial-No Derivative Works License, which permits non-commercial use, distribution, and reproduction in any medium, provided the original author and source are credited.

* Corresponding author. Address: University of Bristol, School of Veterinary Medicine, Langford House, Langford, North Somerset BS40 5DU, UK. Tel.: +44 1179287485.

E-mail address: eric.morgan@bristol.ac.uk (E.R. Morgan).

This paper reports the discovery of *A. vasorum* in wolves in the Rome region, the second report in this host species and the first in Italy. This finding is discussed in the context of the current epidemiological situation in Italy with respect to angiostrongylosis, and possible effects on wolf health and conservation.

2. Materials and methods

Between December 2011 and January 2012, three wolves (*Canis lupus*) found dead in Rome province (Central Italy) were submitted to Istituto Zooprofilattico Sperimentale delle Regioni Lazio e Toscana for *post mortem* examination to investigate the cause of death. Animals were a juvenile female (W.1), an adult female (W.2) and an adult male (W.3). In order to ascertain if they were pure wolves or possible hybrids with the dog (Boitani, 2003), 18 autosomal microsatellite markers were used to genotype each of the three animals (Lorenzini et al., 2013).

For histological tests, representative samples of lungs, heart, liver, spleen, kidneys and brain, were taken from all three animals and fixed in buffered formalin, embedded in paraffin wax, sectioned at 4 µm and stained with haematoxylin and eosin. Histopathological changes in the lung and the presence of nematode material (see below) prompted further investigation of parasitic infection. Hence, although *A. vasorum* was previously reported only once from a wolf, in Spain (Segovia et al., 2001), microscopic examination of the larvae (McGarry and Morgan, 2009; Taubert et al., 2009) and anatomical localization of adults, led to the suspicion that this could be the parasite present in the three examined wolves. To confirm this possible unusual host/parasite association, the parasites were subjected to molecular identification. In order to further discern the relationship between the nematodes infecting these wolves and in local dogs naturally infected with *A. vasorum*, faecal samples from three dogs that had tested positive for *A. vasorum* L1s on clinical investigation were also subjected to DNA extraction and compared with the material from the wolves.

Molecular analysis was carried out as previously described (Jefferies et al., 2009a), with minor modification. Briefly, DNA was extracted from the lung tissues using DNeasy blood and tissue kit (Qiagen, Germany) following the manufacturer's instructions. The lysing step was performed overnight instead of over 3 h to ensure complete lysis of the tissues. The manufacturer's protocol was then followed until DNA was eluted in 200 µl of RNase free water. DNA was stored at -20 °C until required. The internal transcribed spacer (ITS2) of ribosomal DNA was amplified using primers NC1 (5'-ACGTCTGGTTCAGGGTTGTT-3') AND NC2 (5'-TTAGTTTCTTTCTCCGCT-3') as described by Gasser et al. (1993).

Polymerase chain reactions (PCR) were performed in a final total volume of 25 µl consisting of 2.5 µl of 10× polymerase buffer, 0.5 µl each of the deoxyribonucleotide triphosphate (dNTPs; 10 mmol each), 0.125 µl of Hot star Taq DNA polymerase (5 U/ml), 18.625 µl of dH₂O and 2 µl of DNA.

Targets were amplified under the PCR conditions of 95 °C for 15 min followed by 40 cycles of 95 °C for 30 s, 55 °C for 30 s and 72 °C for 1 min; followed by a final extension step of 72 °C for 5 min. The PCR products were visualised with use of ethidium bromide and ultraviolet illumination on 1% agarose gel. Un-purified PCR products were sent for purification and sequencing using the value read tube sequencing service (Eurofins MWG Operon, London). Sequences were compared with those available in the GenBank database by nucleotide sequence homology searches made at the network server of the National Centre for Biotechnology Information (NCBI) using BLAST. Multiple sequence alignments were performed using the program ClustalW2 (EMBL-EBI database).

3. Results and discussion

Genotyping showed no evidence of genetic admixture with dogs for any of the three wolves. At necropsy, all wolves showed traumatic lesions, with multiple bone fractures, in particular of the cranium. Anatomopathological examination of cavitory organs of W.1 revealed congestion and presence of small, whitish and firm nodules scattered in lung parenchyma, especially near the edges of pulmonary lobes. W.2 and W.3 showed diffuse lung congestion and rare foci, similar to W.1. No macroscopic lesion was detected in any of the other organs of the three animals. At histological examination, microscopic changes consisted of the presence of parasitic granulomatous foci in lung parenchyma, in all individuals, characterized by peripheral fibrosis and inflammatory infiltrates of lymphocytes, plasma cells, macrophages, granulocytes and a few multinucleated giant cells (Fig. 1). In the centre of granulomata, numerous nematode larvae and eggs were visible. In each host, one or more adult worms were detected in pulmonary arteries (Fig. 2), occasionally associated with obliterative thrombotic endarteritis. These findings were more severe in W.1, where histological examination showed also rare microgranulomata in the heart. The anatomopathological and histological pictures in the three animals were overlapping with those usually shown by dogs harbouring *A. vasorum* (Bourque et al., 2008). No significant microscopic lesions were observed in other organs. Given the small sample size and the destructive nature of sampling for adult

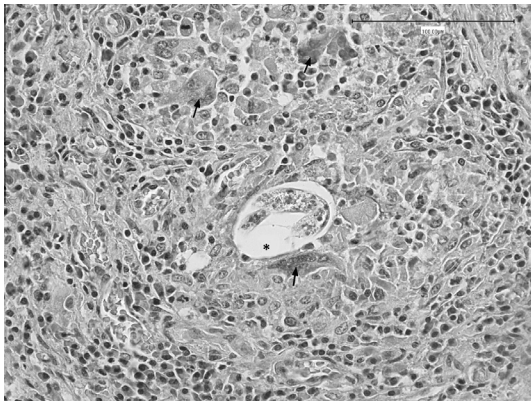


Fig. 1. Lung: granuloma containing a parasitic developing larva (asterisk), surrounded by multinucleated giant cells (arrows). Hematoxylin and eosin. Scale bar represents 100 µm.

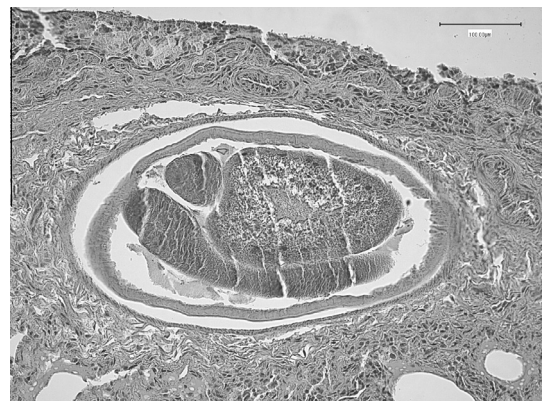

Fig. 2. Lung: adult nematode within a pulmonary artery. Hematoxylin and eosin. Scale bar represents 100 µm.

Table 1
Alignment scores of ITS-2 rDNA PCR products from the nematode samples recovered from dogs (sequence 1) and wolves (sequence 2), and publicly available sequences from Genbank. *Angiostrongylus cantonensis* was included as an outlier, and sequence 4 is from a recently described novel metastrongyloid nematode described in badgers in Spain (Gerrikagoitia et al., 2010). Sequence 3 is the closest matching confirmed *Angiostrongylus vasorum* sequence in Genbank. bp = base pairs.

Sequence	Identifier	Source	Length (bp)	Percent alignment				
				1	2	3	4	5
1	LARVfs_1.0	Dogs, Italy	532	–	98	99	89	84
2	Ltw_1.0	Wolves, Italy	490	–	–	99	89	82
3	gi 194246349 gb EU627595.1	<i>A. vasorum</i> , Genbank	580	–	–	–	90	82
4	gi 299835292 gb GU323341.1	Badgers, Spain	533	–	–	–	–	82
5	gi 321270990 gb HQ540548.1	<i>A. cantonensis</i>	1547	–	–	–	–	–

nematodes (Morgan et al., 2008), correlation between nematode burden and extent of histopathological change was not attempted.

Sequencing of the PCR products confirmed the presence of *A. vasorum* in the faecal sediments of the infected dogs as well as the lung tissues of the wolves. The ITS-2 sequences of both the L1s from dogs and lung tissues from wolves were 99% identical to *A. vasorum* (GenBank EU627595.1). Table 1 shows the alignment scores with different sequences available on GenBank.

A wide range of wild carnivores has been found to be infected by *A. vasorum* to date, as well as domestic dogs in several geographic areas (Jefferies et al., 2009b, 2010). In Newfoundland, Canada, this nematode is found in red foxes and more recently has been described in coyotes (Bridger et al., 2009). In several European countries *A. vasorum* is commonly found in wild red foxes (e.g. Gerrikagoitia et al., 2010), in which it causes detectable pathology (Morgan et al., 2008). Only one previous record has been published from wolves (Segovia et al., 2001). This raises the question of whether wolves have acted as ancestral hosts to this parasite, forming part of the sylvatic reservoir from which emerging cases in dogs are presumably infected, or whether infection in wolves results from more recent spill-over from dogs. Molecular analyses using several mitochondrial as well as nuclear DNA markers confirm that *A. vasorum* genotypes are well mixed between dogs and foxes in Europe (Jefferies et al., 2010). More detailed molecular studies would be needed to better elucidate the evolutionary relationships and transmission dynamics of *A. vasorum* between wild canids (especially foxes) and dogs in Italy, where infection with the parasite appears to be expanding in dogs (Traversa et al., 2010, 2013). In conclusion, although death of these wolves cannot be ascribed to angiostrongylosis, with the injuries described likely to be fatal, the parasite is known to be highly pathogenic in dogs and to cause significant pathology in foxes, and should be considered as a wildlife health issue in regions in which the parasitosis is endemic and wolves are of conservation concern.

Acknowledgements

We thank Ryan Jefferies for advice on the molecular analyses, Rita Lorenzini for genetic analysis of wolves and Mark Viney for providing laboratory assistance. The authors have no conflicts of interest.

References

- Alexander, K.A., McNutt, J.W., Briggs, M.B., Standers, P.E., Funston, P., Hemson, G., Keet, D., van Vuuren, M., 2010. Multi-host pathogens and carnivore management in southern Africa. *Comp. Immunol. Microbiol. Infect. Dis.* 33, 249–265.
- Boitani, L., 2003. Wolf conservation and recovery. In: Mech, L.D., Boitani, L. (Eds.), *Wolves: Behaviour Ecology and Conservation*. University of Chicago Press, Chicago, pp. 317–340.
- Bourque, A.C., Conboy, G., Miller, L.M., Whitney, H., 2008. Pathological findings in dogs naturally infected with *Angiostrongylus vasorum* in Newfoundland and Labrador, Canada. *J. Vet. Diagn. Invest.* 20, 11–20.
- Bridger, K.E., Baggs, E.M., Finney-Crawley, J., 2009. Endoparasites of the coyote (*Canis latrans*), a recent migrant to insular Newfoundland. *J. Wildl. Dis.* 45, 1221–1226.
- Conboy, G.A., 2011. Canine angiostrongylosis: the French heartworm: an emerging threat in North America. *Vet. Parasitol.* 176, 382–389.
- Craft, M.E., Volz, E., Packer, C., Meyers, L.A., 2009. Distinguishing epidemic waves from disease spillover in a wildlife population. *Proc. R. Soc. London, Sect. B* 276, 1777–1785.
- Galaverni, M., Caniglia, R., Fabbri, E., Lalapombella, S., Randi, E., 2013. MHC variability in an isolated wolf population in Italy. *J. Hered.* 104, 601–612.
- Gasser, R.B., Chilton, N.B., Hoste, H., Beveridge, I., 1993. Rapid sequencing of rDNA from single worms and eggs of parasitic helminths. *Nucleic Acids Res.* 21, 2525–2526.
- Gerrikagoitia, X., Barral, M., Juste, R.A., 2010. *Angiostrongylus* species in wild carnivores in the Iberian peninsula. *Vet. Parasitol.* 174, 175–180.
- Guardone, L., Schnyder, M., Macchioni, F., Deplazes, P., Magi, M., 2013. Serological detection of circulating *Angiostrongylus vasorum* antigen and specific antibodies in dogs from central and northern Italy. *Vet. Parasitol.* 192, 192–198.
- Jefferies, R., Morgan, E.R., Shaw, S.E., 2009a. A SYBR green real-time PCR assay for the detection of the nematode *Angiostrongylus vasorum* in definitive and intermediate hosts. *Vet. Parasitol.* 166, 112–118.
- Jefferies, R., Shaw, S.E., Viney, M.E., Morgan, E.R., 2009b. *Angiostrongylus vasorum* from South America and Europe represent distinct lineages. *Parasitology* 136, 107–115.
- Jefferies, R., Shaw, S.E., Willeesen, J., Viney, M.E., Morgan, E.R., 2010. Elucidating the spread of the emerging canid nematode *Angiostrongylus vasorum* between Palearctic and Nearctic ecozones. *Infect. Genet. Evol.* 10, 561–568.
- Koch, J., Willeesen, J., 2009. Canine pulmonary angiostrongylosis: an update. *Vet. J.* 179, 348–359.
- Lorenzini, R., Fanelli, R., Grifoni, G., Scholl, F., Fico, R., 2013. Wolf–dog crossbreeding: “smelling” a hybrid may not be easy. *Mamm. Biol.* (in press).
- Lucchini, V., Galov, A., Randi, E., 2004. Evidence of genetic distinction and long-term population decline in wolves (*Canis lupus*) in the Italian Apennines. *Mol. Ecol.* 13, 523–536.
- McGarry, J.W., Morgan, E.R., 2009. Identification of first-stage larvae of metastrongyles from dogs. *Vet. Rec.* 165, 258–261.
- Morgan, E.R., Shaw, S.E., Brennan, S.F., De Waal, T.D., Jones, B.R., Mulcahy, G., 2005. *Angiostrongylus vasorum*: a real heartbreaker. *Trends Parasitol.* 21, 49–51.
- Morgan, E.R., Tomlinson, A., Hunter, S., Nichols, T., Roberts, E., Fox, M.T., Taylor, M.A., 2008. *Angiostrongylus vasorum* and *Eucoleus aerophilus* in foxes (*Vulpes vulpes*) in Great Britain. *Vet. Parasitol.* 154, 48–57.
- Oleaga, A., Casais, R., Balseiro, A., Espi, A., Llana, L., Hartasánchez, A., Gortazar, C., 2011. New techniques for an old disease: sarcoptic mange in the Iberian wolf. *Vet. Parasitol.* 181, 255–266.
- Otranto, D., Cantacessi, C., Mallia, E., Lia, R.P., 2007. First report of *Thelazia callipaeda* (Spirurida, Thelaziidae) in wolves in Italy. *J. Wildl. Dis.* 43, 508–511.
- Randall, D.A., Marino, J., Haydon, D.T., Sillero-Zubiri, C., Knobel, D.L., Tallents, L.A., MacDonald, D.W., Laurenson, M.K., 2006. An integrated disease management strategy for the control of rabies in Ethiopian wolves. *Biol. Conserv.* 131, 151–162.
- Segovia, J.M., Torres, J., Miguel, J., 2001. Helminths in the wolf, *Canis lupus*, from north-western Spain. *J. Helminthol.* 75, 183–192.
- Taubert, A., Pantchev, N., Vrhovec, M.G., Bauer, C., Hermosilla, C., 2009. Lungworm infections (*Angiostrongylus vasorum*, *Crenosoma vulpis*, *Aelurostrongylus abstrusus*) in dogs and cats in Germany and Denmark in 2003–2007. *Vet. Parasitol.* 159, 175–180.
- Traversa, D., Di Cesare, A., Conboy, G., 2010. Canine and feline cardiopulmonary parasitic nematodes in Europe: emerging and underestimated. *Parasites Vectors* 3, 62.
- Traversa, D., Di Cesare, A., Meloni, S., di Regalbono, A.F., Milillo, P., Pampurini, F., Venco, L., 2013. Canine angiostrongylosis in Italy: occurrence of *Angiostrongylus vasorum* in dogs with compatible clinical pictures. *Parasitol. Res.* 112, 2473–2480.
- Willeesen, J.L., McEvoy, F.J., Webster, P., Monrad, J., Jensen, A.T., Svalatoga, E.L., Koch, J., 2008. Radiological changes in foxes (*Vulpes vulpes*) experimentally infected with *Angiostrongylus vasorum*. *J. Vet. Int. Med.* 22, 707.