

## Case Report

# Herpes Simplex Pneumonia: Combination Therapy with Oral Acyclovir and Aerosolized Ribavirin in an Immunocompetent Patient

Claudio Terzano, MD, PhD, Angelo Petroianni, MD, and Alberto Ricci, MD

*Respiratory Diseases Unit, Department of Cardiovascular and Respiratory Sciences, Fondazione E. Lorillard Spencer Cenci, University "La Sapienza," Rome, Italy*

### ABSTRACT

**Background:** Herpes simplex viruses (HSVs) are known to cause respiratory tract infections in immunocompromised hosts and, in rare instances, in immunocompetent hosts. Numerous *in vitro* and *in vivo* studies have shown that aerosolized administration of ribavirin can potently and selectively inhibit viral replication in pulmonary disease, thereby increasing the effectiveness of acyclovir in HSV.

**Objective:** In this case study, we reported on a 46-year-old immunocompetent woman with HSV type 1 pneumonia with bilateral pulmonary infiltrates but without mucocutaneous lesions.

**Methods:** The diagnosis was confirmed using cytology, viral culture, and serology. Because of the persistence of fever and dyspnea, we chose an antiviral therapy. The patient received oral acyclovir and aerosolized ribavirin to improve the antiviral effectiveness of the acyclovir and to reduce the symptoms and the time to resolution of the pulmonary disease.

**Results:** After 3 days of therapy, dyspnea and fever decreased and hypoxemia improved. After 2 weeks, computed tomography showed complete resolution of pulmonary abnormalities. The patient did not report any adverse effects.

**Conclusions:** In our case study, we demonstrated that therapy with a combination of aerosolized ribavirin and oral acyclovir may be useful to reduce the severity of viral infection, the adverse effects, and the days of hospitalization. To our knowledge, this is the first report in the literature of the synergistic effects of the combination of aerosolized ribavirin and oral acyclovir in the treatment of an immunocompetent patient with HSV pneumonia. (*Curr Ther Res Clin Exp.* 2004;65:90–96) Copyright © 2004 Excerpta Medica, Inc.

**Key words:** herpes simplex virus, pneumonia, ribavirin, acyclovir.

## INTRODUCTION

Although herpes simplex virus (HSV) is a common pathogen, with 85% of the general worldwide population having serologic evidence of previous exposure,<sup>1,2</sup> HSV pneumonia is generally considered to be an opportunistic infection in immunocompromised patients.<sup>3,4</sup>

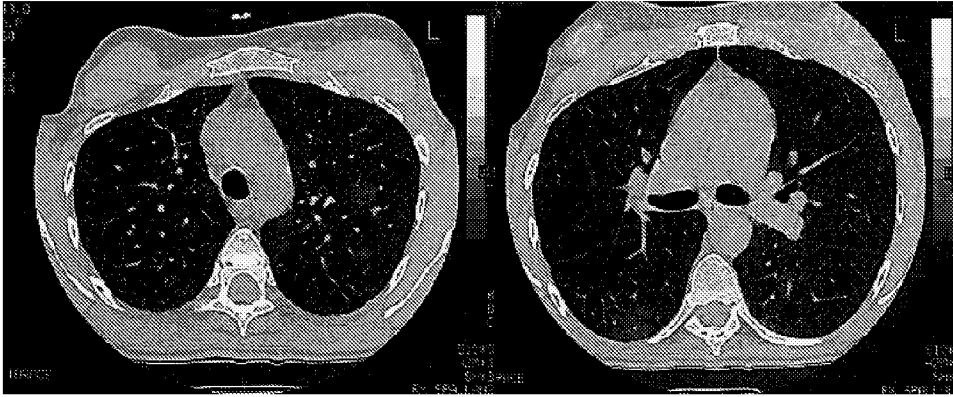
HSV pneumonia has been described in adult patients with immunodeficiency due to human immunodeficiency virus (HIV) infection,<sup>5</sup> chemotherapy,<sup>6</sup> organ transplantation, or burns, or with airway injury due to trauma, thoracic surgery, or intubation. Moreover, HSV pneumonia may be a complication of or may be associated with acute respiratory distress syndrome (ARDS) or polymicrobial pneumonia.<sup>7</sup> Antiviral treatment has been associated with the cure of severe HSV type 1 (HSV-1) pneumonia in children and elderly patients with normal immune defenses.<sup>8</sup>

HSV infection of the lower respiratory tract may cause tracheobronchitis with characteristic ulcerations of membranes or pneumonia. The presence of HSV in immunocompromised patients has been associated with increased mortality and the necessity for prolonged ventilatory support.<sup>7</sup>

According to a MEDLINE search (key terms: herpes simplex virus, pneumonia, ribavirin, and acyclovir; years: 1983–2003), this is the first report of the synergistic effects of the combination of aerosolized ribavirin and oral acyclovir in the treatment of an immunocompetent patient with HSV pneumonia. We describe a case of HSV-1 pneumonia in a 46-year-old immunocompetent woman treated with an original approach of antiviral combination therapy with oral acyclovir and aerosolized ribavirin.

## CASE REPORT

A 46-year-old woman with dry cough, malaise, chest pain, and fever was hospitalized in the Respiratory Diseases Unit, Department of Cardiovascular and Respiratory Sciences, Fondazione E. Lorillard Spencer Cenci, University “La Sapienza” (Rome, Italy) for rapidly worsening pneumonia. The patient did not report the use of tobacco or any other substance abuse or immunosuppressive therapy. She had been working as a nurse for 15 years, during which time she cared for patients with pulmonary infectious diseases and/or HIV infection. Her medical history was unremarkable. Before hospitalization, clarithromycin and cefotaxime sodium were administered for 1 week without significant improvement. Physical examination revealed no mucocutaneous or genital lesions or lymphadenopathy; findings were normal on examination of the chest, heart, and abdomen. Axillary temperature was 39.2°C; heart rate, 105 bpm; and respiratory rate, 36 breaths/min. Arterial blood gas analysis showed hypoxemia (partial pressure of oxygen in arterial blood, 58 mm Hg) and pH 7.47. Chest radiography showed bilateral nodular upper lobe opacities (not shown), and computed tomography showed bilateral multifocal segmental and subsegmental ground-glass pulmonary infiltrates (**Figure**).



**Figure.** Computed tomography scan showing bilateral multifocal segmental and subsegmental ground-glass pulmonary infiltrates.

Leukocyte count was  $10.2 \times 10^9$  cells/mm<sup>3</sup>; T-cell count was CD4, 686 cells/mm<sup>3</sup>, and CD8, 344 cells/mm<sup>3</sup>. Neither anemia (hemoglobin concentration, 12.9 g/dL) nor serum immunoglobulin (Ig) deficiency (IgG, 1580 mg/dL; IgA, 102 mg/dL; IgM, 95 mg/dL) were found. Tests for HIV antigen and antibody were negative. No antibodies for *Mycoplasma*, *Chlamydia*, *Rickettsia*, or respiratory viruses were found, and urine did not contain *Legionella* antigen. Tuberculin skin test and pregnancy test were negative.

Bronchoscopy showed airway erythema, edema, and nonpurulent secretions. Bronchoalveolar lavage (BAL) was negative for *Pneumocystis carinii*, fungi, acid-fast bacilli, and any respiratory virus. However, BAL cultures were positive for HSV-1, and histologic examination of a bronchial biopsy showed Cowdry type A intranuclear inclusion. IgM and IgG serum antibodies for HSV-1 were found at admission and after 10 days, and a specific IgG increment was observed. Because of the pulmonary infiltrates, persistent fever (38.5°C), increased dyspnea, and the positive BAL cultures for HSV-1, we began antiviral therapy to reduce pulmonary viral replication. Treatment with oral acyclovir (800 mg 5 times daily for 10 days) and aerosolized, high-dose, short-duration ribavirin (6 g/d, at 60 mg/mL for 2 hours 3 times daily, for 7 days) was started after verbal informed consent was obtained.

After 3 days of this therapy, dyspnea and fever decreased and hypoxemia improved. After 2 weeks, computed tomography showed complete resolution of pulmonary abnormalities. The patient did not report any adverse effects (AEs). No significant changes were seen in laboratory findings (hemoglobin; platelet count; and serum creatinine, uric acid, and bilirubin concentrations). At 6-month follow-up, the patient reported that she had tested negative for HIV antibodies and stated she was in good health.

## DISCUSSION

HSV infection can affect multiple systems and organs, causing mucocutaneous and visceral diseases, but it rarely affects the lower respiratory tract. Bilateral interstitial infiltrates are typical radiologic findings in viral pneumonia.<sup>9</sup> Diagnosis of HSV pneumonia is based on clinical findings, BAL cultures, immunofluorescence, and serology.<sup>1,4,8</sup> In our study, diagnosis was confirmed using cytology, viral culture, and serology. Patients at risk for lower respiratory tract HSV infection include immunocompromised individuals (eg, neonates, transplant recipients, patients receiving cytotoxic treatment, those with AIDS) and those with congenital deficiency of cell-mediated immunity, severe burns, or malnutrition.<sup>5,7</sup>

The pathogenesis of HSV pneumonia remains unclear. Factors that cause squamous metaplasia of the tracheobronchial tree are thought to predispose patients to lower respiratory tract infection with HSV due to the ability of the virus to infect squamous epithelia. Such factors include traumatic endotracheal intubation, burns, radiation therapy, cytotoxic chemotherapy, and smoking.<sup>7</sup> However, HSV-1 pneumonia can occur in patients with normal immune status who are elderly (aged  $\geq 65$  years), who have chronic disorders, or who have been intubated or have received mechanical ventilation.<sup>6</sup> HSV-1 infection commonly occurs in the lower respiratory tract of seriously ill patients, particularly those with ARDS; however, whether HSV is a benign mucosal colonizer or a pathogen is unknown.<sup>7</sup>

The presence of HSV in patients without AIDS has been associated with increased mortality and prolonged ventilatory support.<sup>7</sup> In these patients, pneumonia can be diffuse or focal.<sup>4</sup> The isolation of HSV from the lower respiratory tract does not distinguish between active disease, oropharyngeal contamination, or asymptomatic shedding of the virus. It would be reasonable to treat patients with antiviral therapy when HSV is the only pathogen recovered during BAL and severe disease is present.<sup>10</sup>

Acyclovir therapy has been reported to resolve HSV pneumonia in immunocompetent patients.<sup>8,11</sup> HSV-1 pneumonia in immunocompetent patients without risk factors, such as smoking and endotracheal intubation, may follow a clinical course similar to other types of viral pneumonia.<sup>6</sup>

In our case study, exposure to patients with pulmonary infectious diseases and HIV suggests a nosocomial spread. Because of the persistent symptoms and the exposure to patients who presumably had been treated repeatedly with acyclovir, we used 2 drugs.

Acyclovir is widely used as prophylactic treatment for HSV infection in immunocompromised patients.<sup>5</sup> Activation of acyclovir requires initial phosphorylation by viral thymidine kinase (TK). The most common acyclovir-resistant mutant strain of HSV does not induce TK stimulation.<sup>12</sup>

Ribavirin inhibits inosine monophosphate dehydrogenase, causing depletion of intracellular guanine nucleotide acyclovir against HSV-1, HSV type 2, and TK-HSV-1.<sup>13,14</sup> Two dosages of ribavirin have been used: a conventional regimen

(6 g/d at 20 mg/mL for 18 h/d) and a high-dose, short-duration regimen (6 g/d at 60 mg/mL for 2 hours every 8 hours).<sup>15-17</sup> The use of ribavirin in HSV infection has been limited because it is expensive and because it has not been proved to be beneficial in the clinical outcome. However, compared with endovenous administration, the aerosolized drug has demonstrated a significant decrease in systemic effects (hemolytic anemia, thrombocytopenia, neutropenia, hyperuricemia, cephalgia, nausea, diarrhea, and alopecia), with moderate local effects (cough).

The results of 3 trials<sup>15-17</sup> have shown that ribavirin therapy in respiratory syncytial virus infection reduces the length of mechanical ventilation and may reduce days of hospitalization. Moreover, ribavirin reduces systemic AEs, cough, and fever.<sup>16</sup> Compared with endovenous administration, aerosolized ribavirin produced significantly greater improvement in cough, intercostal muscle retractions, lethargy, arterial oxygen saturation, and viral shedding, whereas temperature, nasal congestion, rhinorrhea, and wheezing were unaffected. No AEs or toxicity were associated with the aerosolized therapy.<sup>17</sup>

In their *in vivo* studies, Debs et al<sup>16</sup> (in rats) and Bray et al<sup>18</sup> (in mice) showed that aerosolized administration of antiviral agents can potently and selectively inhibit viral replication in the lung.

The target protein with which antiviral agents interact determines their activity spectrum. The synergistic action of acyclovir and ribavirin is supported by several *in vitro* and *in vivo* studies.<sup>14,19,20</sup> Neyts and De Clercq<sup>13</sup> and Neyts et al<sup>14</sup> reported that combination therapy with acyclovir and ribavirin in HSV infection reduced viral-induced pathologic effects in Vero cells. The increased inhibition of HSV replication with this combination therapy has been observed by Marcelletti<sup>19</sup> *in vitro* and *in vitro* by Pancheva<sup>20</sup> and in rabbits. Furthermore, the combination has been shown to be more effective in the treatment of experimental HSV than monotherapy.<sup>19,20</sup> Compared with single drug use, the better therapeutic effect of the combination therapy is supported by the decreased severity of the infection and the reduction in viral shedding, as well as by the shorter duration of the infection.<sup>19,20</sup>

To our knowledge, this is the first report in the literature of the synergistic effects of the combination of aerosolized ribavirin and oral acyclovir in the treatment of an immunocompetent patient with HSV pneumonia. This combined therapeutic approach may be important in the treatment of intercurrent HSV infections in immunosuppressed patients or in immunocompetent patients with persistent symptoms who have an increased risk for ARDS.

## CONCLUSIONS

Antiviral therapy is most effective when used as prophylaxis or at the onset of infection. A potential problem in viral chemotherapy with acyclovir is the emergence of drug-resistant strains. Combined chemotherapy represents a way to potentiate the effects of the drugs at lower therapeutic doses. Further con-

trolled trials may assess the real effectiveness of this combination therapy in reducing the elevated risk for mortality and ARDS in immunocompromised and immunocompetent patients with severe viral pneumonia. In our case study, we demonstrated that therapy with a combination of aerosolized ribavirin and oral acyclovir may be useful to reduce the severity of viral infection, the AEs, and the days of hospitalization.

## REFERENCES

1. Ruben FL, Nguyen ML. Viral pneumonitis. *Clin Chest Med*. 1991;12:223–235.
2. Francois-Dufresne A, Garbino J, Ricou B, Wunderli W. ARDS caused by herpes simplex virus pneumonia in a patient with Crohn's disease: A case report. *Intensive Care Med*. 1997;23:345–347.
3. Cherr GS, Meredith JW, Chang M. Herpes simplex virus pneumonia in trauma patients. *J Trauma*. 2000;49:547–549.
4. Ramsey PG, Fife KH, Hackman RC, et al. Herpes simplex virus pneumonia: Clinical, virologic, and pathologic features in 20 patients. *Ann Intern Med*. 1982;97:813–820.
5. Chien JW, Johnson JL. Viral pneumonias. Infection in the immunocompromised host. *Postgrad Med*. 2000;107:67–70,73–74,77–80.
6. Schuller D. Lower respiratory tract reactivation of herpes simplex virus. Comparison of immunocompromised and immunocompetent hosts. *Chest*. 1994;106(Suppl):S3–S7,S34–S35.
7. Tuxen DV, Cade JF, McDonald MI, et al. Herpes simplex virus from the lower respiratory tract in adult respiratory distress syndrome. *Am Rev Respir Dis*. 1982;126:416–419.
8. Martinez E, de Diego A, Paradis A, et al. Herpes simplex pneumonia in a young immunocompetent man. *Eur Respir J*. 1994;7:1185–1188.
9. Aquino SL, Dunagan DP, Chiles C, Haponik EF. Herpes simplex virus 1 pneumonia: Patterns on CT scans and conventional chest radiographs. *J Comput Assist Tomogr*. 1998;22:795–800.
10. Connolly MG Jr, Baughman RP, Dohn MN, Linnemann CC Jr. Recovery of viruses other than cytomegalovirus from bronchoalveolar lavage fluid. *Chest*. 1994;105:1775–1781.
11. Miyazato A, Kishimoto H, Tamaki K, et al. Herpes simplex virus bronchopneumonia in a non-immunocompromised individual. *Intern Med*. 2001;40:836–840.
12. Ljungman P, Ellis MN, Hackman RC, et al. Acyclovir-resistant herpes simplex virus causing pneumonia after marrow transplantation. *J Infect Dis*. 1990;162:244–248.
13. Neyts J, De Clercq E. The immunosuppressive agent mycophenolate mofetil markedly potentiates the activity of lobucavir [1R(1alpha,2beta,3alpha)]-9-[2,3-bis(hydroxymethyl)cyclobutyl]guanine against different herpes viruses. *Transplantation*. 1999;67:760–764.
14. Neyts J, Andrei G, De Clercq E. The antiherpesvirus activity of H2G [(R)-9-[4-hydroxy-2-(hydroxymethyl)butyl]guanine] is markedly enhanced by the novel immunosuppressive agent mycophenolate mofetil. *Antimicrob Agents Chemother*. 1998;42:3285–3289.
15. Nicholson KG. Antiviral therapy. Respiratory infections, genital herpes, and herpetic keratitis. *Lancet*. 1984;2:617–621.

16. Debs RJ, Montgomery AB, Brunette EN, et al. Aerosol administration of antiviral agents to treat lung infection due to murine cytomegalovirus. *J Infect Dis.* 1988;157:327–331.
17. Hall CB, McBride JT, Walsh EE, et al. Aerosolized ribavirin treatment of infants with respiratory syncytial viral infection. A randomized double-blind study. *N Engl J Med.* 1983;308:1443–1447.
18. Bray M, Martinez M, Kefauver D, et al. Treatment of aerosolized cowpox virus infection in mice with aerosolized cidofovir. *Antiviral Res.* 2002;54:129–142.
19. Marcelletti JF. Synergistic inhibition of herpesvirus replication by docosanol and antiviral nucleoside analogs. *Antiviral Res.* 2002;56:153–166.
20. Pancheva SN. Potentiating effect of ribavirin on the anti-herpes activity of acyclovir. *Antiviral Res.* 1991;16:151–161.

---

**Address correspondence to:** Claudio Terzano, MD, PhD, via Ugo Bartolomei, Rome 18–00136, Italy. E-mail: cterzano@tin.it