

A large Right atrial mass in a patient with hepatocellular carcinoma: Case report and literature review



Hanan B. Albackr^{a,*}

King Fahad Cardiac Center, King Khalid University Hospital College of Medicine, King Saud University

^a Saudi Arabia

Background: Hepatocellular carcinoma (HCC) is a common malignancy and the most frequent sites of metastasis include lungs, bone, lymphatic, and brain, however, Intra-cardiac involvement rarely develops in patients with HCC and it has poor prognosis. The clinical course may be complicated by many fatal cardiovascular complications. Absence of cardiac symptoms, however, is an unusual condition.

Case report: We reported a rare case of hepatocellular carcinoma with large invasion into the right atrium and no cardiac symptoms.

Conclusion: Cardiac metastases occur in 10% of all cancer patients. Heart involvement should be suspected in all patients.

© 2014 King Saud University. Production and hosting by Elsevier B.V. All rights reserved.

Keywords: Carcinoma, Hepatocellular, Heart atria, Heart neoplasms, Secondary, Vena cava and inferior

Introduction

Cardiac tumors are a rare entity, comprised of tumors with diverse histology and natural history [1]. Cardiac tumors are classified into primary benign or malignant tumors that arise from the heart or into secondary, metastatic tumors that invade the heart. Primary cardiac tumors occur with a low incidence. It is estimated that secondary tumors are a hundred times more common than primary cardiac lesions [1–3].

Malignant tumors of various organs and tissues, originating from all over the body, may disseminate to the right atrium (RA) by a nodular embolus and rarely by direct extension. Current literature reports that malignant tumors, such as HCC, pancreatic carcinoma, adrenal carcinoma, testicular cancer, lymphoma, leiomyosarcoma, nasopharyngeal cancer, esophageal cancer, Ewing's sarcoma and Wilm's tumor can encroach on the RA [4]. Portal vein (PV), hepatic vein (HV), and the inferior vena cava (IVC) are often affected.

Disclosure: Authors have nothing to disclose with regard to commercial support.

Received 13 November 2013; accepted 19 November 2013.
Available online 20 February 2014

* Address: King Fahad Cardiac Centre, King Khalid University Hospital, King Saud University, P.O. Box 7805, Riyadh 11472, Saudi Arabia. Tel.: +966 1 467 1161/1854; fax: +966 1 467 1581.
E-mail addresses: halbackr@gmail.com, halbackr@ksu.edu.sa



P.O. Box 2925 Riyadh – 11461KSA
Tel: +966 1 2520088 ext 40151
Fax: +966 1 2520718
Email: sha@sha.org.sa
URL: www.sha.org.sa



1016–7315 © 2014 King Saud University. Production and hosting by Elsevier B.V. All rights reserved.

Peer review under responsibility of King Saud University.
URL: www.ksu.edu.sa
<http://dx.doi.org/10.1016/j.jsha.2014.02.002>



Production and hosting by Elsevier

On the other hand, HCC ranks as the eighth most common cancer, fifth among males and seventh among females [5]. In fact, HCC is the commonest primary tumor of the liver [6]. The highest incidence rates were in developing countries where infection with hepatitis B virus (HBV) is common [5]. Moreover, liver cancer is considered to be the third leading cause of cancer death with an estimated more than half a million deaths in 2007 [7]. The usual sites of HCC metastasis are lung, bone, and lymphnode [8]. However, cardiac metastasis from HCC is rare [9].

This case report demonstrates an unusual metastasis of HCC as a large mass in the right atrium of a patient diagnosed with Hepatitis B.

Case report

In September 2012, a 70-year-old gentleman known to have Hypertension and hepatitis B virus carrier, most likely from remote blood transfusion more than 30 years ago, presented to the emergency department with history of right upper quadrant abdominal pain for 2 months, which was dull in nature, intermittent, with no specific

aggravating or relieving factors. This was associated with decreased appetite and weight loss. There were no nausea, vomiting, melena, hematemesis, dysphagia or fever. Patient denied any cardiac symptoms in form of shortness of breath, chest pain, orthopnea and PND. On physical exam, the patient looked cachectic, he was conscious, well oriented, not pale or jaundiced with no signs of chronic liver disease. Cardiac examination revealed normal heart sounds, abdomen was soft with liver span of 18 cm and palpable epigastric mass measured 6 × 6 cm not separable from the liver with no tenderness or ascites. No lower limb edema.

Laboratory findings were as follows

White cell count (WCC): 2.70/mm³; hemoglobin (Hb): 13.3 mg/dL; platelet (Plt): 76,000/mm³; ESR 95 mm/h PT: 15.7 s; International normalized ratio (INR):1.23; total protein: 83 g/L; albumin: 27 g/L; aspartate aminotransferase (AST): 93 IU/L (N: 12-37); alanine transaminase (ALT): 54 IU/L (N: 20-65); ALP: 110 IU/L (N: 50-136); GGT: 75 IU/L (N:15-85); total bilirubin: 21 μmol/L (N: 3-117),

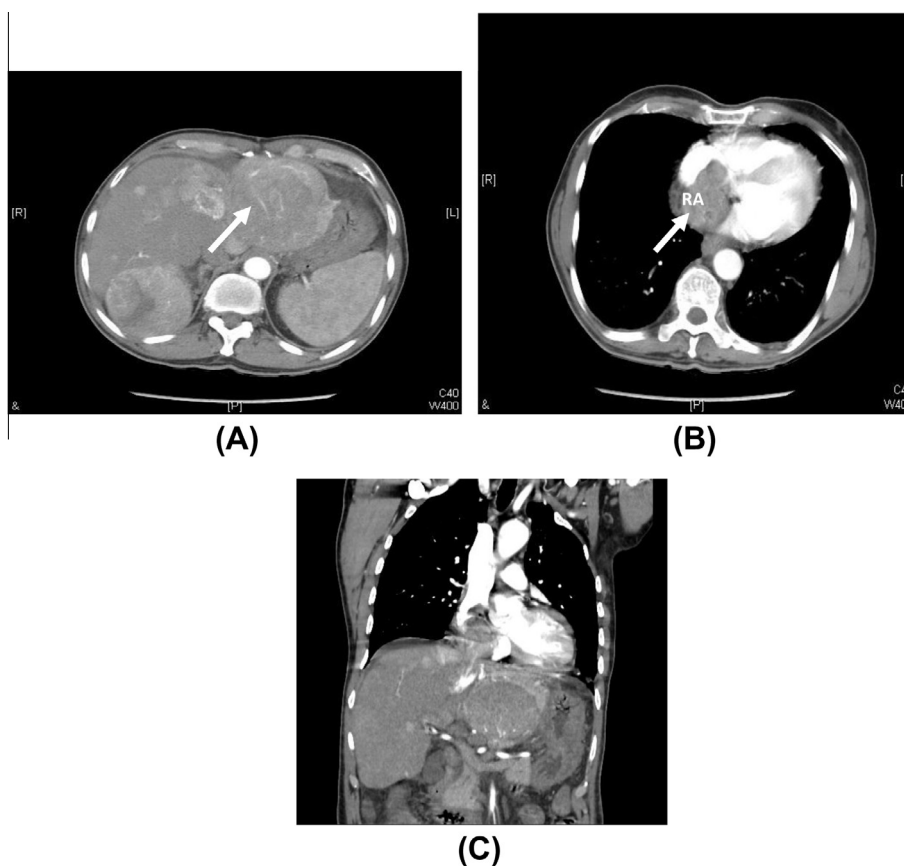


Figure 1. (A) CT scan of abdomen shows the hepatic mass. (B) CT scan of chest shows the Right atrial mass. (C) Coronal CT showing the extension of the tumor to RA (see arrows).

and direct bilirubin: 6 $\mu\text{mol/L}$. Hepatitis B virus surface antigen was positive. Serological markers of hepatitis C were negative. Alpha feto protein (AFP): 212.5 KIU/L (N: 0-5.8). Electrocardiogram (EKG) was normal and Chest X-ray (CXR) showed small nodules bilaterally suggestive of metastasis.

Imaging study

Ultrasound Abdomen: The liver was enlarged with coarse parenchyma together with multiple large solid hypoechoic hepatic mass lesions seen in both right and left lobes, from which the largest was located in the left lobe. Bulky spleen and ascitic fluid were observed in the abdominal and pelvic cavity. Bones scan showed no evidence of metastatic lesion.

CT scan of chest, abdomen and pelvis

Multiple hypervascular hepatic lesions with rapid wash out associated with multiple pulmonary nodules and significant abdominal lymphadenop-

athy were shown as well as large Right atrial lesion extending into the proximal IVC and hepatic veins (Fig. 1) suggesting direct intravascular extension of the HCC to the right atrium. However, HCC in non-cirrhotic liver parenchyma with multiple metastases was also a possibility.

Transthoracic echocardiogram (TTE)

A large mass was shown in the right atrium seems to be extending to or originating from the inferior vena cava (IVC) Fig. 2B. Normal left and right ventricles systolic function. Normal left and Right atria size. No significant valve pathology seen.

Transesophageal echocardiogram (TEE)

Revealed a large Right atrial mass, occupying almost the whole right atrium and extending into the IVC. A spontaneous contrast seen in the IVC distal to the mass.

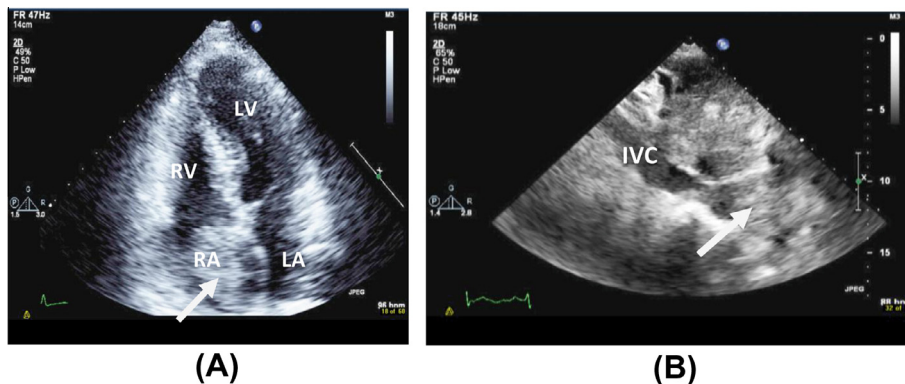


Figure 2. (A) TTE showing four-chamber view with a large right atrium mass filling (arrow) most of the right atrium. (B) Sub costal view revealing a large RA mass extending to the inferior vena cava (IVC).

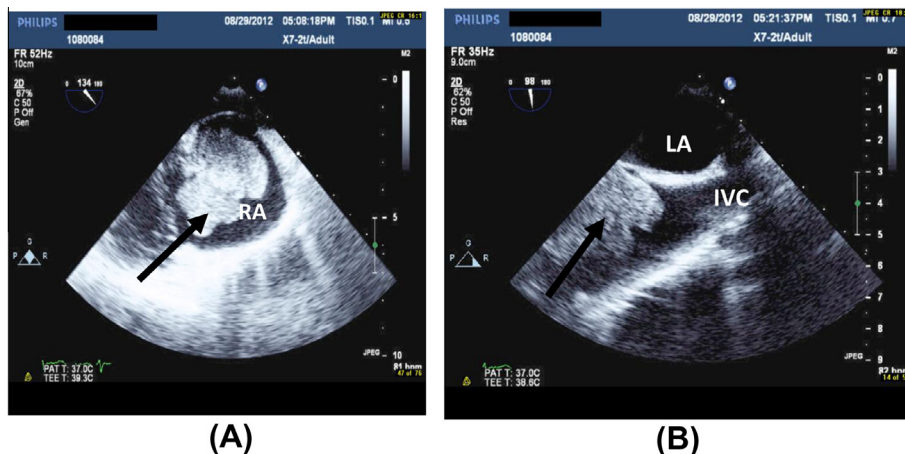


Figure 3. TEE is showing a large lobular mass (9 \times 7 cm in diameter) (A) (arrow) occupying almost the whole right atrium extending to the IVC (B).

The mass was vascular, lobular with small mobile component; the echo picture was suggestive of a vascular malignant tumor with no extension to the pulmonary artery. The mass did not protrude to right ventricle (RV) and did not cause RV inflow obstruction (Fig. 3A).

CT-guided liver biopsy was done and histopathology

CT-guided liver biopsy was done and histopathology of the lesion came to be consistent with a moderately differentiated hepatocellular carcinoma.

Treatment and course

Patient was reviewed by medical oncology team and started on Nexavar (sorafenib), he had poor tolerance with on-going thrombocytopenia and died 2 months later with sepsis complicated by multi-organ failure. No symptoms of CHF were present even at later stage.

Discussion

Worldwide, the prevalence of HCC is estimated to be about 180 million people and the incidence continues to rise annually [10]. The majority of HCC arises from viral hepatitis. In the U.S., 16% of HCC are attributed to HBV and 48% to HCV [10]. HBV-related HCC, tend to develop 25–30 years after chronic infection [11].

Various cardiac symptoms or findings such as sudden dyspnea, massive lower extremity edema, sudden death, or dilatation of the jugular veins are generally seen in HCC patients with intracardiac involvement. [1,2].

HCC metastases tend to spread through intra-hepatic blood vessels, lymphatics, or direct infiltration. It is known to have a marked propensity for vascular invasion and extension. Hematogenous extension may be result of hepatic, portal veins or vena cava involvement and this appears to have been the route of metastasis in the patient reported here. In a study of 439 HCC autopsied cases, intra-atrial tumor growth was found in 18 cases. Moreover, continuous tumor thrombus involving the RA, IVC and the hepatic vein was seen in 15 cases. Tricuspid valve was crossed entering the right ventricle in 5 cases [16]. The mechanism of cardiac involvement is related to the tendency of this tumor to invade the vena cava, thus easily reaching the cardiac cavities. In spite of this fact cardiac metastasis is still considered an unusual presentation of HCC. Cardiac

symptoms may be insignificant as evident in this reported case. The most common symptoms of cardiac metastasis reported in one study included: asymptomatic in 39.5%, bilateral lower leg edema in 37.5% and exertional dyspnea in 31.3% [17].

Advanced HCC is a disease with poor prognosis and median survival time of 4 to 7 months [12]. Extra hepatic metastasis of HCC may reach around 18% and the most common sites of involvement are: lungs, lymph nodes, adrenal glands, and bones [13]. Intracardiac involvement rarely occurs in patients with HCC and its frequency was found around 2% in various series [2]. The prognosis of HCC with intracardiac involvement is poor, with a median survival range of 1–4 months [14]. The risk for cardiopulmonary collapse is high in such patients. Possible cardiopulmonary complications include heart failure, tricuspid stenosis or insufficiency, ventricular outflow tract obstruction, sudden cardiac death, secondary Budd–Chiari syndrome, pulmonary embolism, and pulmonary metastasis [15].

It was reported that the mean survival time from the time of diagnosis of cardiac metastasis was 161 days and the main reason of mortality was related to HCC. Only few patients expired because of cardiac metastases [17].

Yusuf SW and his colleagues reported the clinical characteristics, echocardiographic findings, therapy and outcome of 59 patients with primary and metastatic cardiac tumors. Their institutional echocardiogram database from 1993 through 2005 was reviewed to identify patients diagnosed with intra-cardiac tumor. For both primary and secondary tumors, dyspnea was the most common symptom and right atrium was most frequently involved. Sarcoma was the most common primary cardiac tumor while metastasis from renal cell carcinoma was the most common secondary tumor [1].

Multidisciplinary treatments to control the growth of HCC offer patients with cardiac involvement a useful chance of cure. However, such therapeutic modalities may not be feasible especially if the patient has a poor general performance, metastatic disease or underlying hepatic dysfunction [14]. This explains the management plan applied on this patient here who was given sorafenib, which is usually given for such advanced cases and proved to prolong survival in such population [18].

In conclusion, this case report alerts physicians to HCC patients with cardiac metastasis and based on the above mentioned literature data, we suggest that heart involvement should be sus-

pected in all HCC patients and probably a screening TTE may be done even in absence of any cardiac manifestations. This is important since HBV infection is endemic and prevalent in Saudi Arabia ranging from 3% to 6% [19]. To our knowledge, our patient seems to be the third reported case with HCC metastasis in Saudi Arabia. Interestingly this patient despite the large size of the RA mass was asymptomatic from cardiac point of view, unlike other reported cases with a comparable size of tumor [1].

Acknowledgement

This project is supported by college of medicine research center, deanship of scientific research, King Saud University.

References

- [1] Yusuf SW, Bathina JD, Qureshi S, Kaynak HE, Banchs J, Trent JC, Ravi V, Daher IN, Swafford J. Cardiac tumors in a tertiary care cancer hospital: clinical features, echocardiographic findings, treatment and outcomes. *Heart Int.* 2012;7(1):e4. Epub 2012 Feb 13.
- [2] Yu K, Liu Y, Wang H, Hu S, Long C. Epidemiological and pathological characteristics of cardiac tumors: a clinical study of 242 cases. *Interact Cardiovasc Thorac Surg* 2007;6(5):636–9. Epub 2007 Jul 4.
- [3] Roberts WC. Primary and secondary neoplasms of the heart. *Am J Cardiol* 1997;80:671–82.
- [4] Cheng HY, Wang XY, Zhao GL, Chen D. Imaging findings and transcatheter arterial chemoembolization of hepatic malignancy with right atrial embolus in 46 patients. *World J Gastroenterol* 2008;14(22):3563–8.
- [5] World Health Organization, International Agency for Research on Cancer. GLOBOCAN 2008. (<http://globocan.iarc.fr>).
- [6] Anthony PP. Hepatocellular carcinoma: an overview. *Histopathology* 2001;39:109–18.
- [7] Michael J. Thun, John Oliver DeLancey, Melissa M. Center, Ahmedin Jemal, Elizabeth M. Ward. The global burden of cancer: priorities for prevention. American Cancer Society, Research Department, 250 Williams Street, Northwest Atlanta, GA 30303-1002, USA.
- [8] Hong SS, Kim TK, Sung KB, et al.. Extrahepatic spread of hepatocellular carcinoma: a pictorial review. *Eur Radiol* 2003;13:874–82.
- [9] Anwar AM, Nosir YF, Chamsi-Pasha MA, Ajam A, Chamsi-Pasha H. Right atrial metastasis mimicking myxoma in advanced hepatocellular carcinoma. *Echocardiography* 2010;27(1):80–3.
- [10] American Cancer Society. Cancer Facts & Figures 2012. Atlanta: American Cancer Society; 2012; Available from: <http://www.cancer.org/Research/CancerFactsFigures/index>.
- [11] Jennifer Ng, Jennifer Wu, Hepatitis B- and hepatitis C-related hepatocellular carcinomas in the United States: similarities and differences. *Hepat Mon* 2012;12(10 HCC):e7635.
- [12] Natsuzaka M, Omura T, Akaike T, Kuwata Y, Yamazaki K, Sato T, Karino Y, Toyota J, Suga T, Asaka M. Clinical features of hepatocellular carcinoma with extrahepatic metastases. *J Gastroenterol Hepatol* 2005; 20: 1781–7.
- [13] Pawarode A, Voravud N, Sriuranpong V, Kullavanijaya P, Patt YZ. Natural history of untreated primary hepatocellular carcinoma: a retrospective study of 157 patients. *Am J Clin Oncol* 1998;21:386–91.
- [14] Chang JY, Ka WS, Chao TY, Liu TW, Chuang TR, Chen LT. Hepatocellular carcinoma with intra-atrial tumor thrombi. A report of three cases responsive to thalidomide treatment and literature review. *Oncology* 2004;67:320–6.
- [15] Sung AD, Cheng S, Moslehi J, Scully EP, Prior JM, Loscalzo J. Hepatocellular carcinoma with intracavitary cardiac involvement: a case report and review of the literature. *Am J Cardiol* 2008;102:643–5.
- [16] Kojiro M, Nakahara H, Sugihara S, Murakami T, Nakashima T, Kawasaki H. Hepatocellular carcinoma with intra-atrial tumor growth. A clinicopathologic study of 18 autopsy cases. *Arch Pathol Lab Med* 1984;108:989–92.
- [17] Liu YC, Ho YL, Huang GT, Chen DS, Sheu JC, Chen CH. Clinical manifestations and survival of patients with hepatocellular carcinoma and cardiac metastasis. *J Gastroenterol Hepatol* 2010;25:150–5.
- [18] Josep M. Llovet, Sergio Ricci, Vincenzo Mazzaferro, Philip Hilgard, Edward Gane, Jean-Frédéric Blanc, Andre Cosme de Oliveira, Armando Santoro, Jean-Luc Raoul, Alejandro Forner, Myron Schwartz, Camillo Porta, Stefan Zeuzem, Luigi Bolondi, Tim F. Greten, Peter R. Galle, Jean-François Seitz, Ivan Borbath, Dieter Häussinger, Tom Giannaris, Minghua Shan, Marius Moscovici, Dimitris Voliotis, Jordi Bruix for the SHARP Investigators Study Group. *N Engl J Med* 2008; 359:378–90.
- [19] Abdo AA, Sanai FM, Al-Faleh FZ. Epidemiology of viral hepatitis in Saudi Arabia: Are we off the hook? *Saudi J Gastroenterol [serial online]* 2012;18:349–57.