

## Pathogenic properties of enterohepatic *Helicobacter* spp. isolated from rhesus macaques with intestinal adenocarcinoma

Kvin Lertpiriyapong,<sup>1†</sup> Laurence Handt,<sup>2</sup> Yan Feng,<sup>1</sup> Thomas W. Mitchell,<sup>2</sup> Kenneth E. Lodge,<sup>2</sup> Zeli Shen,<sup>1</sup> Floyd E. Dewhurst,<sup>3,4</sup> Sureshkumar Muthupalani<sup>1</sup> and James G. Fox<sup>1</sup>

### Correspondence

James G. Fox  
jgfox@mit.edu

<sup>1</sup>Division of Comparative Medicine, Massachusetts Institute of Technology, Cambridge, MA, USA

<sup>2</sup>Merck Research Laboratories, West Point, PA, USA

<sup>3</sup>Department of Microbiology, Forsyth Institute, 245 First Street, Cambridge, MA, USA

<sup>4</sup>Department of Oral Medicine, Infection and Immunity, Harvard School of Dental Medicine, Boston, MA, USA

Considerable progress has been made in understanding the roles of *Helicobacter pylori* in inflammation and gastric cancer; however, far less is known about the roles of enterohepatic *Helicobacter* species (EHS) in carcinogenesis and their zoonotic or pathogenic potential. We determined the prevalence of EHS infection in a cohort of geriatric rhesus monkeys in which intestinal adenocarcinoma (IAC) is common and investigated the association between EHS infection and IAC. The cohort consisted of 36 animals, 14 of which (age 26–35 years) had IAC. Of the 36 rhesus, 35 (97%) were positive for EHS using PCR or bacterial isolation from faeces, colonic or tumour tissues. Only a single rhesus, which had IAC, was negative for EHS by all detection methods. The EHS identified by 16S rRNA sequencing in this study were from three *Helicobacter* taxa: *Helicobacter macacae* (previously rhesus monkey taxon 1), *Helicobacter* sp. rhesus monkey taxon 2, previously described from strain MIT 99-5507, and *Helicobacter* sp. rhesus monkey taxon 4, related to *Helicobacter fennelliae*. Thirteen of 14 monkeys with IAC were positive for either *H. macacae* (7/13, 54%), EHS rhesus monkey taxon 4 (4/13, 31%) or a mixture of the two EHS (2/13, 15%). These results indicate that EHS are prevalent among aged rhesus macaques with IAC. Using *Helicobacter* genus-specific fluorescent *in situ* hybridization, EHS were detected on the surface of colonic epithelia of infected monkeys. All *Helicobacter* isolates, including *H. macacae*, effectively adhered to, invaded, and significantly induced proinflammatory genes, including *IL-8*, *IL-6*, *TNF- $\alpha$*  and *iNOS*, while downregulating genes involved in the function of inflammasomes, particularly *IL-1 $\beta$* , *CASPASE-1*, *NLRP3*, *NLRP6* and *NLRC4* in the human colonic T84 cell line ( $P < 0.0001$ ). These results suggest that EHS may represent an aetiological agent mediating diarrhoea, chronic inflammation, and possibly intestinal cancer in non-human primates, and may play a role in similar disease syndromes in humans. Downregulation of inflammasome function may represent an EHS strategy for long-term persistence in the host and play a role in inducing pathological changes in the host's lower bowel.

Received 24 December 2013

Accepted 31 March 2014

<sup>†</sup>Present address: East Carolina University, Brody School of Medicine, Department of Comparative Medicine 600 Moye Boulevard, LSB 217, Greenville, NC 27834, USA.

**Abbreviations:** CDT, cytolethal distending toxin; EHS, enterohepatic *Helicobacter* species; FISH, fluorescent *in situ* hybridization; IAC, intestinal adenocarcinoma; IBD, inflammatory bowel disease; STLV, simian T-cell leukaemia virus; SRV, simian retrovirus.

## INTRODUCTION

Enterohepatic *Helicobacter* species (EHS) are Gram-negative, helical microaerophilic proteobacteria that have been implicated in the development of gastrointestinal diseases in humans and animals (Fox, 2002; Fox *et al.*, 2002; Ceelen *et al.*, 2005; Goldman & Mitchell, 2010). Unlike the stomach-colonizer *Helicobacter pylori*, which is a known aetiological agent for gastritis and gastric adenocarcinoma in humans, EHS reside in the host's intestinal and hepatobiliary tracts,

with the potential of eliciting pathological changes in infected tissues (Goldman & Mitchell, 2010; Fox *et al.*, 2011).

In experimentally and naturally infected cases, several EHS can cause inflammatory conditions and neoplasia in various species of animals (Cimolai *et al.*, 1987; Burnens *et al.*, 1994; Burman *et al.*, 1995; Cahill *et al.*, 1998; Foley *et al.*, 1998, 1999; Avenaoud *et al.*, 2000; Ceelen *et al.*, 2005; Thomson *et al.*, 2011). In susceptible mouse strains, chronic infection with *Helicobacter hepaticus* induces hepatitis, hepatic adenoma and hepatocellular carcinoma (Fox *et al.*, 1996b; García *et al.*, 2011). In immunocompromised mice, EHS infection causes typhlocolitis, enterocolitis and neoplasia of the lower bowel (Foltz *et al.*, 1998; Chin *et al.*, 2000; Erdman *et al.*, 2009; Mangerich *et al.*, 2012).

Several EHS, including *Helicobacter pullorum*, *H. cinaedi*, *H. fennelliae*, *H. canadensis*, *H. bilis*, *H. winghamensis* and *H. canis*, have been isolated from the gastrointestinal tract of human patients with ulcerative colitis, proctitis and diarrhoea (Hung *et al.*, 1997; Foley *et al.*, 1999; Hsueh *et al.*, 1999; Fox *et al.*, 2000; Melito *et al.*, 2001; Hansen *et al.*, 2011). One of the EHS, *H. cinaedi*, has been shown to cause bacteraemia, gastroenteritis, osteomyelitis and cellulitis in immunocompetent and immunocompromised humans and has recently been shown to persistently colonize the intestinal tract of humans (Kitamura *et al.*, 2007; Hansen *et al.*, 2011; Oyama *et al.*, 2012). Importantly, experimental inoculation of infant pigtail macaques with the human isolates *H. cinaedi* or *H. fennelliae* resulted in colitis and bacteraemia (Flores *et al.*, 1990). These findings raise the possibility that chronic EHS infection may lead to development of inflammatory bowel disease (IBD) and neoplasia in humans (Haggerty *et al.*, 2005; Thomson *et al.*, 2011). Furthermore, it has been previously observed that there is zoonotic transmission infection with EHS, particularly between humans and pets (Fox, 2002).

A novel EHS has been isolated from colitis-affected cotton-top tamarins, which are predisposed to developing IBD and colon cancer (Saunders *et al.*, 1999). We previously surveyed a cohort of rhesus and cynomolgus monkeys in which idiopathic colitis was endemic, and found that many of them were infected with multiple EHS, including *Helicobacter macacae* (Fox *et al.*, 2001b, 2007). Another colony of rhesus, where colitis was not endemic, also had *Helicobacter* spp. isolated from their faeces. Ten years after this initial survey, one of the monkeys in the non-colitis cohort, but persistently infected with *H. macacae*, developed intestinal adenocarcinoma (IAC) (Marini *et al.*, 2010), the most common neoplasia in geriatric (>20 years of age) rhesus macaques (Uno *et al.*, 1998; Valverde *et al.*, 2000; Rodriguez *et al.*, 2002). This observation led us to hypothesize that chronic EHS infection produces colitis, but also persistent EHS infection, similar to *H. hepaticus*-infected *Rag*<sup>-/-</sup> mice, which develop colon carcinoma, could play a role in the genesis of intestinal neoplasia (Erdman *et al.*, 2009; Mangerich *et al.*, 2012). In this study,

we surveyed a cohort of ageing rhesus monkeys, in which IAC is common, to determine whether infection with EHS is prevalent among these animals. Recognizing that rhesus EHS were detected in a diarrhoeic child (Haggerty *et al.*, 2005) and that EHS isolated from humans can experimentally cause disease in non-human primates, we also explored the pathogenic potential of the rhesus EHS using *in vitro* assays.

## METHODS

**Rhesus monkey population.** The study population consisted of 36 geriatric rhesus macaques (7 males and 29 females) with ages ranging from 26 to 35 years, 14 of which were diagnosed with IAC. Thirty animals were positive for simian T-cell leukaemia virus (STLV) by serology and one monkey was positive for both STLV and simian retrovirus (SRV). All animals were negative for simian immunodeficiency virus and B virus, as well as for enteric pathogenic bacteria, *Shigella* spp. and *Salmonella* spp.

**Bacteria isolation and culture.** EHS isolation from faecal, colonic and tumour samples was performed as previously described (Fox *et al.*, 2001b). Briefly, the faecal samples were suspended in *Brucella* broth and the suspension was filtered through a 0.65 µm Acrodisc syringe filter (M.D. Laboratory Supplies) to enrich for EHS. The filtrate was spotted on the surface of the blood agar plates (Remel). Colon and tumour samples were homogenized in *Brucella* broth and the mixtures were filtered as mentioned above and spotted on blood agar media. After 7–10 days of incubation under microaerobic conditions (10% H<sub>2</sub>, 10% CO<sub>2</sub>, 80% N<sub>2</sub>) in a vented jar at 37 °C, the plates were inspected for evidence of EHS growth. The bacteria were collected with a sterilized cotton swab and resuspended in PBS. Their genomic DNA was isolated using the High Pure PCR Template Preparation kit (Roche Molecular Biochemicals) (Fox *et al.*, 2007). All *Helicobacter* isolates were preserved at -80 °C in *Brucella* broth containing 20% glycerol (v/v) for subsequent analyses.

**Molecular techniques.** Faecal samples were collected, and stored at -80 °C until they were used for analysis. Faecal DNA was obtained using the Qiagen DNA stool mini extraction kit according to the manufacturer's recommendations. Faecal PCR was performed using *Helicobacter* genus 16S rRNA gene-specific primers (C05 and C97), which amplify an ~1200 bp conserved region of the 16S rRNA, as previously described (Fox *et al.*, 2007). The identity of the 16S rRNA PCR products was determined by a combination of RFLP analysis, DNA sequencing and BLAST analysis of the DNA sequences against the NCBI DNA sequence database. RFLP analyses were performed using *AluI* and *HhaI* restriction endonucleases (New England Biolabs) as previously described (Fox *et al.*, 2007). DNA sequencing was accomplished using the ABI prism Genetic Analyzer 3500 (Life Technologies). Full 16S rRNA sequences were obtained, sequences were aligned in our RNA database, and neighbour-joining trees were created as previously described (Dewhirst *et al.*, 2005). To determine the presence of the cytolethal distending toxin (CDT) gene in the genome of rhesus monkey EHS, a set of degenerate primers VAT2, WM11 and DHF1, previously used to identify CDT genes in other *Helicobacter* species, were used (Chien *et al.*, 2000).

**In vitro cell culture, cell adhesion, gentamicin protection assays.** T84 human colonic cells were obtained from the American Type Culture Collection (ATCC). A stock culture of T84 (a human colonic epithelial cell line; ATCC, CCL 6) was maintained in a 1:1 mixture of Han's F12 and Dulbecco's modified Eagle's medium (DMEM:F12; ATCC) supplemented with 5% (v/v) fetal bovine

serum, penicillin (100 U ml<sup>-1</sup>) and streptomycin (100 µg ml<sup>-1</sup>) according to ATCC's recommendation. T84 cells (10<sup>6</sup> per well) were seeded into 12-well cell culture plates and incubated at 37 °C in a humidified incubator aerated with 5% CO<sub>2</sub> for 48 h. Adhesion and gentamicin protection assays were performed according to a previously published procedure (Lertpiriyapong *et al.*, 2012) with minor modifications. Briefly T84 cells were inoculated with EHS at 50 m.o.i. in 1 ml fresh culture medium. EHS were propagated on blood agar under microaerobic conditions and collected at 48 h post-incubation, which corresponds to the mid-exponential phase of growth. Viable organisms were predominantly spiral in shape, and contamination by other types of bacteria was not noted as visualized by Gram staining. The plates were centrifuged at 200 g to facilitate bacterial cell adhesion and incubated under microaerobic conditions. EHS was subjected to heat treatment by boiling in water at 100 °C for 20 min. After 2 h of incubation for cell adhesion assays and 4 h of incubation for the gentamicin protection assays, T84 cells were lysed with 0.1% saponin and the bacteria were enumerated by 10-fold serial dilution and plating onto blood agar. The gentamicin concentration used in the gentamicin protection assay was 250 µg ml<sup>-1</sup>. An insignificant number of EHS (4 to 5 c.f.u. in 1 ml of media) were recovered from the supernatant with this concentration of gentamicin and 4 h duration of treatment.

**CDT assay.** *In vitro* assays for CDT activity and preparation of cell sonicates of EHS were performed according to our previously described method using HeLa cells (CCL-2, ATCC) (Young *et al.*, 2000b). Briefly, HeLa cells were cultured in Dulbecco's modified Eagle's medium supplemented with glutamine and 10% fetal calf serum. HeLa cells (10<sup>4</sup>) were seeded into each well of 24-well cell culture plates. The cells were allowed to acclimate for 2 h. Ten microlitres of filtered sterilized supernatant fractions of cell sonicate of rhesus EHS containing approximately 5 µg ml<sup>-1</sup> of total protein, as measured using a BCA protein assay kit (Thermo Scientific), suspended in 1 × PBS was then added to each well. As negative and positive controls, HeLa cells were also treated with 1 × PBS and filtered, sterilized supernatant fractions of cell sonicate of *H. hepaticus*, previously shown to produce CDT using this *in vitro* assay, at the same concentration of total protein, respectively. The cells were inspected for CDT activity, indicated by evidence of cell rounding and enlargement as well as the presence of multinucleated giant cells at 48 h of incubation.

**Histology.** Tumour samples and colonic tissues were collected during surgical resection, preserved in 10% neutral formalin buffer, and sectioned as previously described (Marini *et al.*, 2010). Tissue sections were then evaluated by a board-certified veterinary pathologists (plural) (T. W. M., S. M.).

**Florescent *in situ* hybridization (FISH) for *Helicobacter* spp.** Fluorescent *in situ* hybridization assays were performed as previously described, with modifications (Bridgford *et al.*, 2008). For whole cell *in situ* hybridization, cells were fixed with 4% paraformaldehyde, washed with PBS and air-dried. For paraffin-embedded tissue, the sections were deparaffinized by passage through xylene (three passages for 10 min each), 100% ethanol (three passages for 2 min each) and 95% ethanol (three passages for 2 min each) and air-dried. Two probes specific for the entire genus *Helicobacter*, HEL 274/HEL 717 (Chan *et al.*, 2005) were used for the FISH assay. The probes were labelled with cy3, reconstituted with sterile water, and diluted to a working concentration of 10 ng µl<sup>-1</sup> with hybridization buffer (20 mM Tris/HCl, 0.9 M NaCl, 0.1% SDS, 30% formamide, pH 7.2). Fifty microlitres of hybridization buffer with probe was applied to the slides. Sections were covered in Parafilm to minimize evaporation and placed in a hybridization chamber at 48 °C overnight. Washing buffers I (20 mM Tris/HCl, 0.9 M NaCl, 0.01% SDS) and II (20 mM Tris/HCl, 0.9 M NaCl) were applied and incubated at

48 °C for 15 min each. Slides were rinsed in double-distilled water, air-dried and mounted in Vectashield Hardmount with 4',6-diamidino-2-phenylindole (DAPI) (Vector Laboratories). Slides were examined using a Zeiss Axioskop 2 fluorescence microscope. A slide was designated positive if the distinctive spiral organisms fluoresced under the Rhod filter.

**Gene expression analysis in T84 cells.** To study inflammatory gene expression, T84 cells were seeded into a 12-well cell culture plate at 10<sup>6</sup> cells per well and incubated for 48 h. T84 cells were washed three times with 1 × PBS and then inoculated with EHS suspended in DMEM:F12 medium free of antibiotics and fetal bovine serum at an m.o.i. of 50. After 2 h of microaerobic culture, the cells were suspended in 1 ml Trizol reagent (Invitrogen). RNA extraction with Trizol was performed according to the manufacturer's recommendations. cDNA was synthesized from 3 µg total RNA using the High Capacity cDNA Archive kit (Applied Biosystems). mRNA levels were quantified with TaqMan gene expression assays (Applied Biosystems) in an ABI Prism Sequence Detection System 7700. Expression levels of inflammatory genes, *interleukin-6* (*IL-6*; *HS00985639\_M1*), *IL-8* (*HS00174103\_M1*), *IL-18*, *tumour necrosis factor-α* (*TNF-α*; *HS99999043\_M1*), *CASPASE-1* (*CASP1*; *HS00354836\_M1*), *inducible nitric oxide synthase* (*iNOS*; *HS01075529\_M1*), *IL-1β* (*HS01555410\_M1*), nucleotide-binding oligomerization-domain protein-like receptor proteins 3 (*NLRP3*; *HS00918082\_M1*), *NLRP6* (*HS00373246\_M1*) and NLR family, CARD domain-containing 4 (*NLRC4*; *HS00892666\_M1*), in T84 cells were evaluated using quantitative PCR. mRNA levels of inflammatory mediators were normalized to the mRNA level of endogenous control *glyceraldehyde-3-phosphate dehydrogenase* (*GAPDH*; *HS99999905\_M1*) using the standard  $\Delta C_T$  method (User Bulletin no.2, Applied Biosystems). Samples were run in duplicate or triplicate in two independent experiments.

**Statistical analysis.** A non-parametric two-tailed Mann U Whitney was used for statistical analyses of mRNA expression levels using GraphPad Prism 5.0 (GraphPad Software).

## RESULTS

### EHS are highly prevalent among a population of geriatric rhesus monkeys with a high IAC incidence

To investigate the association between EHS infection and IAC, we surveyed a population of geriatric rhesus macaques in which IAC is common, and determined EHS prevalence. Initially, the infection status of a cohort of 36 rhesus monkeys was evaluated by faecal PCR and bacterial isolation. From 36 animals, 34 faecal samples were available for the analysis. Thirty-two of 34 (94%) faecal samples were positive for *Helicobacter* spp. by faecal PCR (Table 1), whereas only 27/34 (79%) faecal samples were positive by EHS culture. Two animals that were negative by faecal PCR were also negative by faecal EHS isolation. Analyses using a combination of RFLP, 16S rRNA gene sequencing, and sequence analyses revealed that these isolates fall into four taxa. Specific isolates were >99% similar to *H. macacae*, previously isolated from rhesus with idiopathic colitis, normal rhesus and a rhesus with colonic adenocarcinoma (Fox *et al.*, 2001b, 2007; Marini *et al.*, 2010) (previously designated rhesus monkey taxon 1). *Helicobacter* sp. MIT 99-5507 rhesus monkey taxon 2 from a rhesus macaque

**Table 1.** *Helicobacter* spp. isolation from rhesus monkeys

Sample no.	Animal ID	Bacterial isolate ID	Faecal PCR	Bacterial isolation from faeces	ID of EHS
1	04-R118*	MIT11-6586	+	–	NA*
2	04-R122	MIT11-6587	+	–	NA*
3	05-R538	MIT10-6478	+	+	<i>Helicobacter</i> spp. MIT 99-10781 monkey taxon 4
4	07-R110	MIT11-6588	+	+	<i>H. macacae</i> , taxon 1
5	07-R111	MIT11-6589	+	–	NA*
6	07-R722*	MIT11-6590	–	–	NA*
7	07-R924	MIT10-6480	+	+	<i>Helicobacter</i> spp. MIT 99-10781 monkey taxon 4
8	07-R928	MIT10-6479	+	+	<i>Helicobacter</i> spp. MIT 99-10781 monkey taxon 4
9	09-R908	MIT11-6591	+	+	<i>Helicobacter</i> spp. MIT 99-10781 monkey taxon 4
10	07-R740	MIT11-6592	+	+	<i>Helicobacter</i> spp. MIT 99-10781 monkey taxon 4
11	07-R736	MIT11-6593	+	+	<i>H. macacae</i> , taxon 1
12	07-R732	MIT11-6594	+	+	<i>Helicobacter</i> spp. MIT 99-10781 monkey taxon 4
13	07-R730*	MIT11-6595	+	+	<i>Helicobacter</i> spp. MIT 99-10781 monkey taxon 4
14	09-R904	MIT11-6596	+	–	NA*
15	09-R905	MIT11-6597	+	+	<i>Helicobacter</i> spp. MIT 99-10781 monkey taxon 4
16	09-R903	MIT11-6598	+	+	<i>Helicobacter</i> spp. MIT 99-10781 monkey taxon 4
17	09-R902	MIT11-6599	+	–	NA*
18	09-R901	MIT11-6600	+	+	<i>Helicobacter</i> spp. MIT 99-10781 monkey taxon 4
19	04-R123	MIT11-6601	+	+	<i>Helicobacter</i> spp. MIT 99-10781 monkey taxon 4
20	07-R728*	MIT11-6602	+	+	<i>H. macacae</i> , taxon 1
21	04-R128	MIT11-6603	+	+	<i>Helicobacter</i> spp. MIT 99-10781 monkey taxon 4
22	04-R126	MIT11-6604	+	+	<i>H. macacae</i> , taxon 1
23	04-R432*	MIT11-6605	+	+	<i>H. macacae</i> , taxon 1
24	09-R906	MIT11-6606	+	+	<i>Helicobacter</i> spp. MIT 99-10781 monkey taxon 4
25	09-R907	MIT11-6607	+	+	<i>Helicobacter</i> spp. MIT 99-10781 monkey taxon 4
26	09-R927	MIT11-6608	+	+	<i>Helicobacter</i> spp. MIT 99-5507 monkey taxon 2
27	09-R929	MIT11-6609	+	+	<i>H. macacae</i> , taxon 1
28	04-R430	MIT11-6610	+	+	<i>Helicobacter</i> spp. MIT 99-10781 monkey taxon 4
29	07-R729*	MIT11-6611	–	–	NA*
30	07-R727*	MIT11-6612	+	+	<i>Helicobacter</i> spp. MIT 99-10781 monkey taxon 4
31	07-R108	MIT11-6613	+	+	<i>Helicobacter</i> spp. MIT 99-10781 monkey taxon 4
32	07-R129	MIT11-6614	+	+	<i>Helicobacter</i> spp. MIT 99-10781 monkey taxon 4
33	09-R910	MIT11-6615	+	+	<i>Helicobacter</i> spp. MIT 99-10781 monkey taxon 4 and <i>H. macacae</i> , taxon 1
34	09-R923	MIT11-6616	+	+	<i>H. macacae</i> , taxon 1
% Positive			94 %	79 %	

\*These animals had IAC.


with idiopathic colitis (Fox *et al.*, 2001b), and *Helicobacter* sp. rhesus monkey taxon 4, which is most closely related to *H. fennelliae* (98 % similarity), were also identified. The relationship between these three *Helicobacter* spp. isolates based on their 16S rRNA sequences is depicted in Fig. 1. Interestingly, one animal was confirmed positive for two EHS, *H. macacae* and the *H. fennelliae*-like *Helicobacter* sp. rhesus taxon 4, by faecal PCR, faecal bacterial isolation and DNA sequencing, whereas the remainder of the monkeys were positive for a single *Helicobacter* species. The RFLPs generated by using *AluI* and *HhaI* restriction endonucleases corresponding to each EHS are shown in Fig. 2 and were consistent with our previous report (Marini *et al.*, 2010). Two RFLP patterns represented the *H. fennelliae*-like EHS.

This was due to a single base pair substitution (T to C) which created an additional *HhaI* site (Fig. 2).

### EHS were detected in tumours of rhesus macaques with IAC

Of the 36 animals evaluated, 14 (40 %) were diagnosed with IAC by exploratory and histological evaluation. These tumours were detected primarily in the ileo-caeco-colic junction (Fig. 3). The age of the affected monkeys ranged from 26 to 35 years, although 9/14 (64 %) animals were 30 years or older (Table 2). Twelve of the affected monkeys were females and two were males; all of which were positive for STLTV, and one animal was positive for both STLTV and

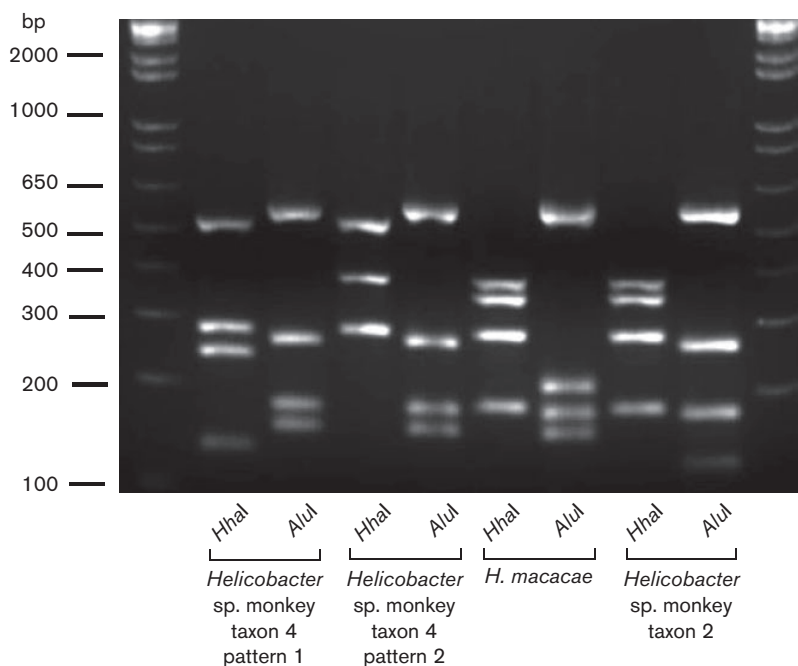




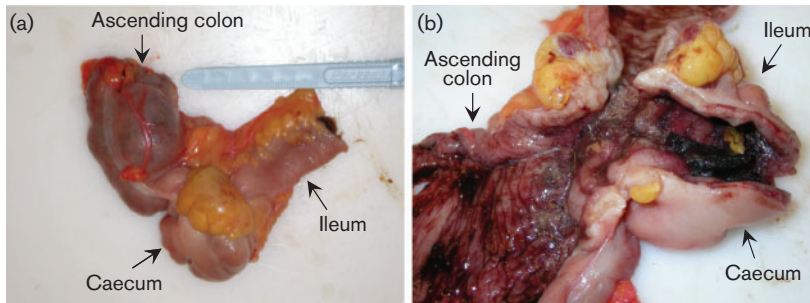
**Fig. 1.** Dendrogram depicting the relationship, based on the full-length sequences of 16S rRNA gene, between the three rhesus *Helicobacter* isolates identified in this study and the most closely related named *Helicobacter* species. The scale bar shows a 3% sequence difference.

SRV (Table 2). Surgical removal of the tumour was the treatment of choice in all of the IAC-affected monkeys. Resection of the colonic tumours extended life as long as 6 years (Table 2). To definitively determine whether EHS were intimately associated with the tumour tissue, bacterial isolation was performed from tumour tissue in 10 of 14 animals available for analysis. EHS were recovered from the IAC of 9/10 of the affected monkeys. EHS were isolated

from the tumour tissue of an animal, 07-R722, which was initially tested negative by both faecal PCR and faecal bacterial isolation. However, EHS were not recovered from one animal, 07-R729, the only other animal that initially tested negative by both faecal PCR and faecal bacterial isolation. Interestingly, by bacterial culture from tumour tissue, two animals with IAC were found to be co-infected with both *H. macacae* and *H. fennelliae*-like EHS (Table 1).



**Fig. 2.** RFLP patterns of *Helicobacter* sp. monkey taxon 4, *H. macacae* and *Helicobacter* sp. monkey taxon 2 generated by *AluI* and *HhaI*.



**Fig. 3.** (a) Intact resected section of intestine, including distal ileum, ileo-caeco-colic (ICC) junction (caecum and proximal portion of ascending colon). Beneath the anterior serosal adipose pad noted over the ICC, there are multifocal areas that are expanded by an internal mass that includes the ICC, caecum, ileum and colon. The tumour does not expand grossly past this anatomical area. (b) Anterior midline dissection of intestine, including distal ileum, ICC junction, caecum and proximal portion of ascending colon. Intestinal wall of the ileum, ICC, caecum and ileo-caecal and caeco-colic valve (sphincters) are thickened by as much as 6–8 mm. Mucosa is eroded with focal ulcers, with blood noted within the lumen and lining the intestinal mucosa. Tumour is circumferential and causes stenosis.

### Tumour characteristics

From the 14 monkeys previously diagnosed by biopsy as having intestinal IACs, post-mortem specimens from 5 animals (04-R432, 07-R728, 07-R727, 09-R923 and 07-R108) were available for examination as part of this study. Of these, one animal had undergone prior resection of the ileal-caeco-colic tumour and hence histological assessment in this instance only included non-neoplastic colon. In cases with obvious tumour, the masses were often localized to the ileo-caecal junction or involved the caecum and colon to varying degrees. Grossly, these were characterized either by discrete nodular thickening at the ileo-caecal origin or by variable degrees of thickening of the caeco-colonic mucosa with associated mucosal ulceration, haemorrhage and/or mucus-filled cysts in the mucosa extending to the serosa and mesentery with variable serosal thickening and mesenteric adhesions.

Histologically, the four grossly observed tumours had a varying appearance and all were classified as intestinal carcinomas. The tumour of 09-R923 was localized to the caeco-colic junction with involvement of both the adjacent caecum and ascending colon. This tumour was histologically classified as a well-differentiated mucinous cystic adenocarcinoma. There were numerous variably distended cystic mucus-filled neoplastic glands with partial cell loss extending into the muscularis, serosa and adjacent mesentery in association with a background of prominent mucosal ulceration/necrosis/haemorrhage and a mixed population of inflammatory cells as well as oedema and fibrosis (Fig. 4a, b). The tumour of 07-R728 was classified as tubular, moderately differentiated adenocarcinoma with invasive spread into the muscularis, serosa and adjacent mesentery (Fig. 4c, d). There was also mild to moderate lympho-plasmacytic and histiocytic inflammation in the non-neoplastic segments of the colon and caecum.

The tumour from 04-R432 involved the ileal-caeco-colic junction and was classified histologically as signet ring cell

adenocarcinoma characterized by multifocal effacement of the lamina propria by mucus-filled cells with marginated nucleus thus imparting a signet ring cell appearance. The neoplastic cells in this mass showed multifocal invasion into the submucosa, muscularis and mesentery as well as prominent intravascular neoplastic plugs in the affected regions (Fig. 4e, f). Inflammatory aggregates were also noted within the neoplastic foci. In addition, there was also multifocal to coalescing moderate lympho-plasmacytic ileitis and typhlocolitis admixed with variable numbers of macrophages, neutrophils and eosinophils as well as oedema and ulceration.

The tumour of 07-R727 was classified as a poorly differentiated invasive carcinoma arising from the base of the colonic glandular crypts with formation of neoplastic cords and nests of cells extending into submucosa (not shown) with associated mild diffuse lympho-histiocytic colitis. The intestine of one animal, 07-R108, with a history of prior surgical tumour resection did not have any discernible mass at necropsy and on histological examination there was moderate diffuse plasmacytic mucosal inflammation involving the caecum and colon, with mild associated epithelial hyperplasia (image not shown).

### EHS are capable of adhering to and invading a T84 colonic cell line

Previously, EHS from rhesus monkeys were identified in the stools of diarrhoeic children (Haggerty *et al.*, 2005), suggesting that EHS could be of zoonotic importance. To succeed as an enteric pathogen, EHS must be able to establish colonization within its host, which may require the ability to adhere to and/or invade host mucosal epithelia. We investigated whether the three rhesus EHS were capable of adhering to and invading human colonic epithelia. As illustrated in Fig. 5, spiral organisms representing the three EHS were detected by FISH on the surface of T84 cells after 2 h post-inoculation (Fig. 5a–c). FISH-positive bacteria

**Table 2.** Prevalence of EHS in rhesus monkeys with IAC

Sample	Animal ID	Age at time IAC diagnosed/treated (years)	Survival after surgical resection IAC	Status of EHS isolated from colonic/tumour/faecal samples	Gender	<i>Helicobacter</i> species
1	02-R028	26	5 years	+	M	<i>H. macacae</i>
2	04-R118	32	2 years	+	F	<i>H. macacae</i>
3	04-R432	32	2 years	+	F	<i>H. macacae</i>
4	04-R127	25	6 years	+	F	<i>Helicobacter</i> sp. MIT 99-10781 monkey taxon 4
5	07-R722	31	4 months	+	F	<i>H. macacae</i>
6	07-R727	30	4 months	+	F	<i>H. macacae</i>
7	07-R730	27	5 months	+	F	<i>H. macacae</i> and <i>Helicobacter</i> sp. MIT 99-10781 monkey taxon 4
8	07-R728	30	1 year	+	F	<i>H. macacae</i>
9	07-R729	28	3 years	–	F	NA
10	04-R128	31	4 years	+	F	<i>H. macacae</i> and <i>Helicobacter</i> sp. MIT 99-10781 monkey taxon 4
11	09-R903	31	NA	+	F	<i>Helicobacter</i> sp. MIT 99-10781 monkey taxon 4
12	09-R923	31	NA	+	M	<i>H. macacae</i>
13	07-R108	29	3 years	+	F	<i>Helicobacter</i> sp. MIT 99-10781 monkey taxon 4
14	04-R430	35	6 years	+	F	<i>Helicobacter</i> sp. MIT 99-10781 monkey taxon 4

could not be detected on the T84 cell surface with heat-treated EHS (Fig. 5d), indicating that cell adhesion requires live bacteria. The highest efficacy of cell adhesion, assessed by FISH, was observed for *Helicobacter* sp. monkey taxon 2. To confirm the FISH results, cell adhesion assays were conducted. Consistent with the FISH results, all EHS isolates adhered to T84 cells. *Helicobacter* sp. monkey taxon 2 adhered most effectively to T84 cells, followed by *Helicobacter* sp. monkey taxon 4 and *H. macacae* (*Helicobacter* sp. monkey taxon 2, 2.3% of the inoculum  $\pm$  0.17 SE versus *Helicobacter* sp. monkey taxon 4, 0.3%  $\pm$  0.02%, and *H. macacae*, 0.02%  $\pm$  0.0003). Additionally, all of the rhesus EHS invaded T84 cells, although at varying degrees of effectiveness (*Helicobacter* sp. monkey taxon 2, 0.001%  $\pm$  0.0002; *Helicobacter* sp. monkey taxon 4, 0.04%  $\pm$  0.03; *H. macacae*, 0.03%  $\pm$  0.0007).

Spiral *Helicobacter* could also be observed adhering to the surface of the colonic epithelia at high density in the region of the tumour tissue (Fig. 5e), confirming the intimate association of these EHS with the neoplastic tissues.

### EHS induce a strong pro-inflammatory gene expression in T84 cells

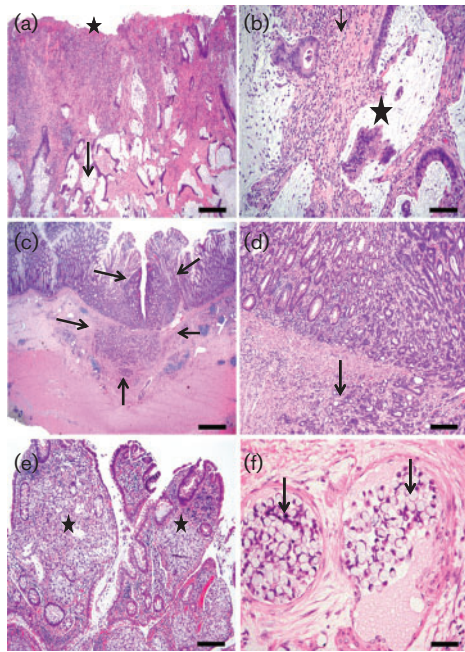
Chronic inflammation is a widely accepted mechanism mediating many cancer types (Grivennikov *et al.*, 2010; Grivennikov & Karin, 2010; Eiró & Vizoso, 2012; Candido & Hagemann, 2013). Importantly, there is strong evidence that chronic *H. pylori* infection promotes gastric cancer

in humans by inducing host pro-inflammatory responses (Bornschein *et al.*, 2010). To determine whether the three rhesus EHS were capable of inducing inflammatory responses after establishing colonization, T84 cells were inoculated with the rhesus EHS, and the mRNA levels of pro-inflammatory genes, particularly *IL-8*, *IL-6* and *TNF- $\alpha$* , were measured 2 h post-inoculation. Significant inductions of *IL-8*, *IL-6* and *TNF- $\alpha$*  were detected in EHS-treated cells ( $P < 0.0001$ ) compared with untreated cells (Fig. 6). Similarly, *iNOS* expression levels were significantly elevated in the T84 treated cells compared with the untreated control. These results suggest that EHS colonization is associated with transcriptional upregulation of pro-inflammatory genes as well as the nitric oxide synthase gene.

### EHS downregulate genes involved in inflammasome signalling in T84 cells

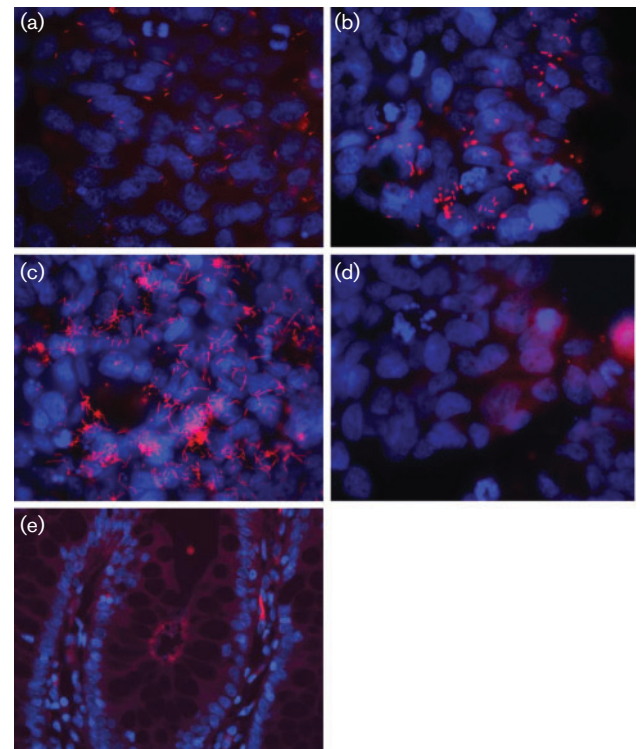
It has been shown that *H. macacae* can persistently infect rhesus macaques for a decade after initial isolation of the organism (Marini *et al.*, 2010). Similar persistence of EHS has also been reported for other EHS in other hosts (Fox *et al.*, 1996a; García *et al.*, 2011). Certain bacterial pathogens have the capability to interfere with inflammasome function, thereby preventing the host from recognizing and eliminating the bacterial pathogens (Rathinam *et al.*, 2012). Inflammasomes, particularly NLRP3 and NLRP6, expressed abundantly in intestinal epithelial cells, are targeted by multiple pathogenic bacteria, and are crucial





**Fig. 4.** Representative haematoxylin–eosin images of the various types of caeco-colonic carcinomas observed in different macaques. (a, b) Low- (a) and high- (b) magnification images of the neoplastic caeco-colic junction (09-R923) diagnosed as mucinous cystic invasive adenocarcinoma. At low magnification (a) there are numerous cystic mucus-filled invasive glands deep in the submucosa (arrow) with associated mucosal necrosis/ulceration (star), inflammation and fibrosis. The higher-magnification image (b) shows invasive mucus-filled glands with partial cell loss (star), rafts of neoplastic cells in lumen and encircling fibrous connective-tissue and inflammatory aggregates. (c, d) Low- and high-magnification haematoxylin–eosin images of the colonic tumour from a macaque (07-R726), showing the origin and borders (arrows) of a moderately differentiated tubular adenocarcinoma with submucosal invasion (arrows) and associated lymphoid aggregates. (e, f) Low- and high-magnification haematoxylin–eosin images of the neoplastic ileo-caecal junction of a macaque (04-R432) classified as signet ring cell adenocarcinoma. The low-magnification image (e) shows expansion of lamina propria of the villi by clusters of neoplastic pale mucus-filled signet ring cells (stars) whereas the high-magnification image (f) shows submucosal intravascular plugs (arrows) of neoplastic signet ring cells. Bars: (a) 400  $\mu$ m; (b) 80  $\mu$ m; (c) 800  $\mu$ m; (d) 80  $\mu$ m; (e) 160  $\mu$ m; (f) 40  $\mu$ m.

for maintaining intestinal homeostasis and preventing the development of colitis and tumorigenesis in mouse models (Kempster *et al.*, 2011; Huber *et al.*, 2012). Recognizing the importance of inflammasomes in pathogen elimination, intestinal inflammation and tumorigenesis, we investigated the impact of all three rhesus monkey EHS, *H. macacae*, *Helicobacter* sp. monkey taxon 2 and *Helicobacter* sp. monkey taxon 4, on known genes involved in inflammasome function, particularly *NLRP3*, *NLRC4* and *NLRP6*. We also analysed genes downstream of *NLRP3*, *NLRC4*



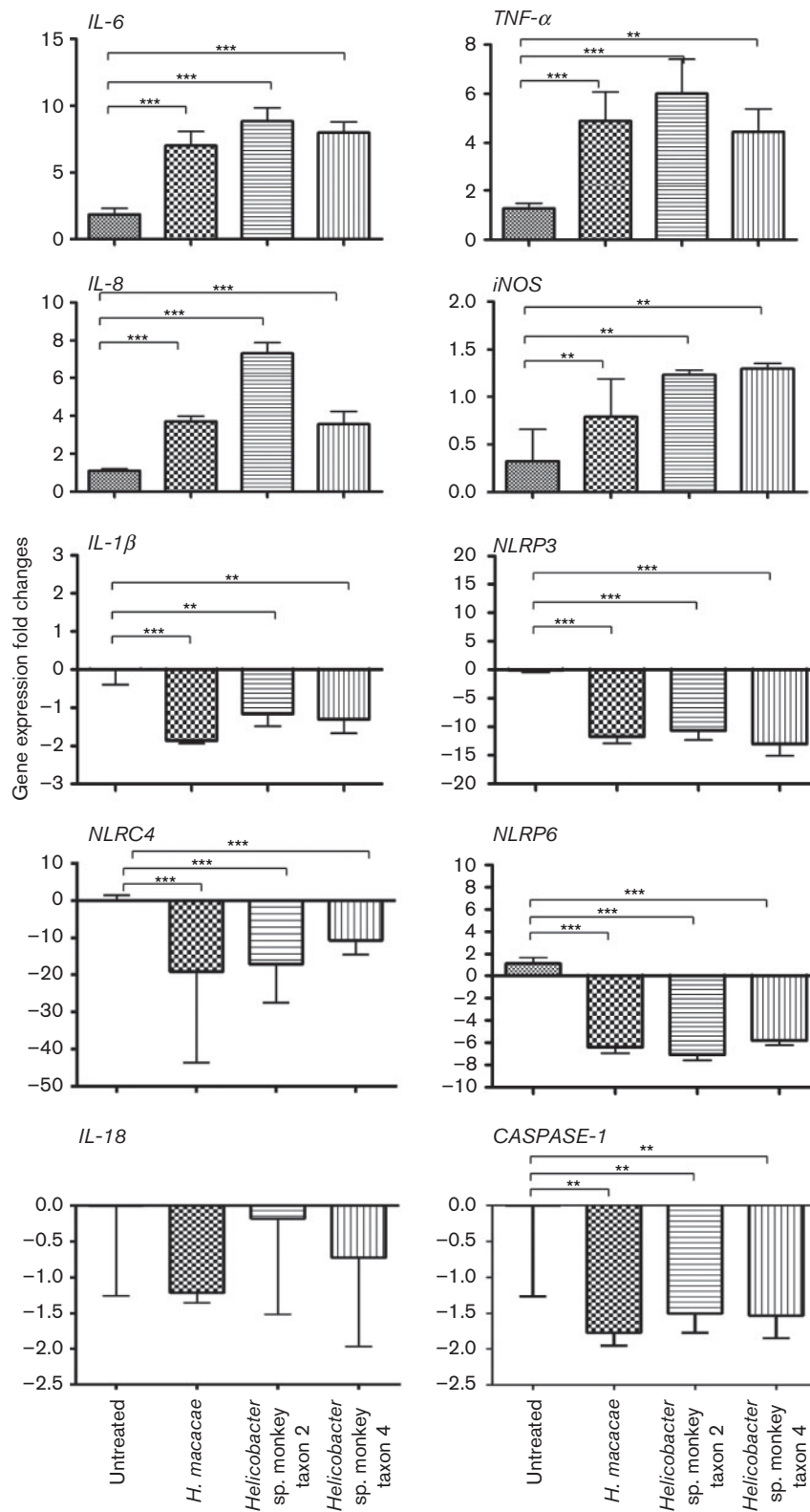
**Fig. 5.** FISH staining showing the presence of rhesus *Helicobacter* (pink fluorescent spots) adhering to the surface of T84 cells. (a) *H. macacae*, (b) *Helicobacter* sp. MIT 10-6479 rhesus monkey taxon 4, (c) *Helicobacter* sp. MIT 10-6608 rhesus monkey taxon 2, (d) heat-treated *Helicobacter* sp. MIT 10-6608 rhesus monkey taxon 2 with *in vitro* T84 cells, and in (e) intimate association with colonic epithelium in the rhesus intestine.

and *NLRP6*, specifically *CASPASE-1*, *IL-1 $\beta$*  and *IL-18*. At 2 h post-inoculation, *CASPASE-1* and *IL-1 $\beta$*  were moderately downregulated, while *NLRP3*, *NLRP6* and *NLRC4* ( $P < 0.0001$ ) were strongly downregulated in EHS-treated T84 cells compared with untreated controls. *IL-18* expression was unchanged in the treated compared with untreated T84 cells (Fig. 6). These results indicate that EHS are capable of modulating inflammasome signalling in the intestinal epithelial cells at the transcriptional level.

#### Rhesus EHS lack CDT activity *in vitro*

EHS species, such as *H. hepaticus*, *H. cineadi*, *H. pullorum* and *H. bilis*, contain CDT, which has been demonstrated to induce DNA damage and cell death (Sugai *et al.*, 1998; Cortes-Bratti *et al.*, 1999; Young *et al.*, 2000a; Taylor *et al.*, 2003; Shen *et al.*, 2009). To determine whether CDT was present in the three EHS isolated from rhesus, PCR amplifications of the *cdt* gene and *in vitro* assay for CDT activity were performed. PCR failed to amplify *cdt* genes from any of the EHS species investigated. Moreover, in two independent assays performed, none of rhesus EHS was capable of inducing cell rounding and enlargement,





**Fig. 6.** Expression levels of pro-inflammatory and inflammasome genes in T84 colonic cell lines not incubated and co-incubated with *H. macacae*, *Helicobacter* sp. monkey taxon 2, and *Helicobacter* sp. monkey taxon 4. Results are based on two independent experiments. Two independent assays were performed in triplicate. *P* value: \*\*  $\leq 0.05$ , \*\*\*  $\leq 0.001$ .

indicating that the three rhesus EHS are unlikely to contain CDT.

## DISCUSSION

In this study, we demonstrated that EHS are prevalent among geriatric rhesus monkeys with IAC. These animals were infected with at least three distinct EHS. Moreover, in some animals, two distinct EHS co-colonized individual monkeys, consistent with our previous reports (Fox *et al.*, 2001a, b). The significance of EHS co-infection requires further investigation. However, it is worth noting that in mouse models of EHS-induced colon cancer, co-infection with two or more species of EHS increased the prevalence of colon cancer in experimentally infected IL-10-deficient mice (Chichlowski *et al.*, 2008).

We found that tumour or colonic tissue bacterial isolation was sensitive in detecting EHS in rhesus monkeys. Using this method, we were able to confirm an animal positive for EHS when faecal PCR and faecal bacterial isolation were both negative. However, faecal PCR appears to be sensitive as an initial screen to identify *Helicobacter*-positive animals. Additionally, we observed that surgical resection of IAC at the early stage is associated with a favourable prognosis and extended the life span of an affected monkey for as long as 6 years, which is consistent with a previous report (Valverde *et al.*, 2000).

Interestingly, all animals with IAC were positive for STLV. Although STLV has been associated with lymphoma, it has not been associated with intestinal neoplasia in rhesus monkeys. The human counterpart of STLV, HTLV, has only been shown to be the cause of adult T-cell leukaemia/lymphoma and of tropical spastic paraparesis/HTLV-1-associated myelopathy, as well as dermatitis, uveitis, arthropathy and polymyositis (Proietti *et al.*, 2005). No evidence to date suggests that STLV is involved in the pathogenesis of intestinal neoplasms; however, considering that STLV has been associated with lymphoma in non-human primates and humans, and their presence can modulate lymphocytic function and cytokine profiles (Lapin & Yakovleva, 2014), it is possible that STLV could synergize with *Helicobacter* spp. to promote colonic tumorigenesis. Further investigation is needed to delineate this relationship.

The zoonotic potential of EHS has been reported (Fox, 2002). Thus far, several species of EHS isolated from animals have the ability to infect humans (Fox, 2002). Intriguingly, the rhesus EHS previously isolated by our laboratory, *Helicobacter* sp. MIT 99-5507 rhesus monkey taxon 2, which was also identified among rhesus monkeys in this study, was detected in the stool of a child with diarrhoea (Haggerty *et al.*, 2005). Moreover, *H. cinaedi* and *H. fennelliae*, which were shown to cause diarrhoea and bacteraemia when inoculated into infant pig-tailed macaques, have been isolated from humans with proctitis, proctocolitis and enteritis (Russell *et al.*, 1990). *H. cinaedi* is also isolated from

rhesus monkeys with and without clinical signs (Fox *et al.*, 2001a; Fernandez *et al.*, 2002). However, rhesus without diarrhoea did not have colonic biopsies to ascertain if histological colitis was present, a common feature in rhesus monkeys (Fernandez *et al.*, 2002). *H. cinaedi* has also been identified in the stools of symptomatic and asymptomatic patients (Oyama *et al.*, 2012).

Little is known about the pathogenic mechanism of EHS in non-human primates and humans; however, considerable knowledge has been gained in the past decades from studies involving mouse models of IBD and colon cancer (Erdman *et al.*, 2009; Fox *et al.*, 2011). Consistent with previous reports, IAC is detected primarily in the ileo-caeco-colic junction in the affected monkeys (Uno *et al.*, 1998; Valverde *et al.*, 2000; Rodriguez *et al.*, 2002; Erdman *et al.*, 2003, 2009). This anatomical location of IAC is consistent with EHS colonizing this site. In fact, EHS-associated colon cancer in mice has a high propensity to localize in the ileo-caeco-colic junction (Fox *et al.*, 2011). However, EHS also colonize other regions of the lower bowel, as does *H. macacae*.

EHS have also been shown to have abilities to modulate host adaptive and innate immune responses as well as nitric oxide synthesis pathways, leading to inflammation and the subsequent genetic mutations necessary for carcinogenesis (Erdman *et al.*, 2009). Furthermore, production of cytotoxin, particularly CDT, exerts its effect by arresting the target cell in the G1 and G2 phase of the cell cycle, resulting in cell death. CDT has been demonstrated in *H. hepaticus*, *H. cinaedi*, *H. pullorum* and other EHS *in vitro* (Chien *et al.*, 2000; Young *et al.*, 2000b). However, unlike these EHS, all three rhesus EHS identified in this study do not appear to produce secreted protein with CDT activity *in vitro*. Nevertheless, our *in vitro* studies demonstrated that the rhesus EHS have the ability to adhere to and invade human T84 colonic epithelia, supporting the view that these EHS are able to establish colonization within the gastrointestinal tract. Aside from adherence and invasion capability, we also found that upon adhesion to the intestinal epithelia these EHS induce a significant upregulation of pro-inflammatory genes including *IL-6*, *IL-8*, *TNF- $\alpha$*  and *iNOS* in T84 cells. *IL-6*, *IL-8*, *TNF- $\alpha$*  and NO production have been shown to play pivotal roles in inflammation-mediated carcinogenesis (Erdman *et al.*, 2009; Grivennikov & Karin, 2010). Importantly, *IL-6* and *TNF- $\alpha$* , by stimulating downstream ROS pathways and pathways involved in recruiting immune cells and induction of nitric oxide production, are known to be potent enhancers of cancer progression and cancer cell growth and survival (Grivennikov & Karin, 2010). The upregulation of *iNOS* expression detected in this study is also consistent with the view that *IL-6* and *TNF- $\alpha$*  induction promotes nitric oxide production (Erdman *et al.*, 2009; Grivennikov *et al.*, 2010; Mangerich *et al.*, 2012). As many neoplastic conditions in humans and animals have been linked to bacterial infection and chronic inflammation, decades of infection with EHS, which continuously stimulates mucosal

inflammatory responses via upregulation of *IL-6*, *IL-8*, *TNF- $\alpha$*  and *iNOS*, may contribute to colitis-associated carcinogenesis in rhesus monkeys.

Remarkably, while pro-inflammatory genes were stimulated by EHS in the colonic epithelial cells during the 2 h post-infection, genes involved in inflammasome function, including *CASPASE-1*, *IL-1 $\beta$* , *NLRP3*, *NLRP6* and *NLRC4*, were significantly downregulated during *in vitro* EHS infection. Multiple EHS have the capability to persistently colonize the host intestinal tract (Fox *et al.*, 1996b; Shen *et al.*, 2009; Ge *et al.*, 2011). *H. macacae* can also persistently infect rhesus macaques (Marini *et al.*, 2010). However, the mechanism of chronic persistence of EHS is unclear. Several bacterial pathogens, such as *Legionella pneumophila* and *Mycobacterium tuberculosis*, develop mechanisms to modulate inflammasome functions, thereby preventing the host from effectively eliminating the organism (Master *et al.*, 2008; Lamkanfi & Dixit, 2011). Inflammasomes are multiprotein oligomers known to be crucial in the recognition and the destruction of pathogenic bacteria by triggering an inflammation-induced cell death called pyroptosis. Downregulation of key genes involved in inflammasome function, including *NLRP3*, *NLRCP4* and *NLRP6*, and their downstream targets, *CASPASE-1* and *IL-1 $\beta$* , in EHS-treated T84 cell lines may represent a mechanism mediating EHS persistence and sustained inflammation in the host. Moreover, recent studies suggest that *NLRP3* is crucial for establishment of intestinal homeostasis and protection against colitis. *NLRP3* deficiency leads to loss of epithelial integrity, resulting in systemic dispersion of commensal bacteria, massive leukocyte infiltration and increased chemokine production in the colon (Zaki *et al.*, 2010). An association of EHS infection and *NLRP3* downregulation may in part explain why EHS infection can lead to inflammatory bowel conditions in humans and animals. Similar to *NLRP3*, *NLRP6* also has recently been shown to be a suppressor of colitis. In addition, *NLRP6* appears to function as a crucial regulator of colonic microbial ecology. The lower bowel of mice deficient in *NLRP6* showed an increased representation of members of colitogenic bacteria including *Prevotellaceae* as well as the uncultured candidate division TM<sub>7</sub> (TM for Torf, mittlere Schicht=peat, middle layer) and a reduction in members of the genus *Lactobacillus* (Elinav *et al.*, 2011). Also of interest was the observation that the intestinal microbiome contained *Helicobacter* sp. (Elinav *et al.*, 2011). It is appreciated that several EHS can be responsible for chronic inflammation in the colon of immunodysregulated mice (Fox *et al.*, 1999; Maggio-Price *et al.*, 2006; Whary *et al.*, 2006; Shen *et al.*, 2009; Ranatunga *et al.*, 2012). Both *Prevotellaceae* and TM<sub>7</sub> have been implicated in periodontal disease and the latter in inflammatory bowel diseases in humans. Further investigations using animal models should reveal whether EHS-mediated transcriptional downregulation of *NLRP3* and *NLRP6* can alter intestinal microbiota composition, modulate the intestinal microbiome and promote intestinal inflammation and carcinogenesis. Similarly, *NLRC4* has been shown to play a

crucial role in protecting the gut as mice deficient in *NLRC4* displayed more severe disease upon treatment with dextran sulphate, sodium and when challenged with *Salmonella* infection (Carvalho *et al.*, 2012). Moreover, *NLRC4*-deficient mice had an increased bacterial burden after pulmonary infection with *L. pneumophila*, suggesting the importance of *NLRC4* in limiting bacterial colonization (Pereira *et al.*, 2011). Thus, in addition to the negative effect of *NLRP3* and *NLRP6* downregulation, suppressive effects of EHS on *NLRC4* could further exacerbate inflammation and promote tumorigenesis. Considering the emerging evidence that EHS play a role in inflammatory conditions and cancer, our findings support the hypothesis that chronic EHS infections may participate in the development of gastrointestinal cancer in animals and humans (Thomson *et al.*, 2011).

## ACKNOWLEDGEMENTS

This study was supported by NIH grants T32 RR007036 (J.G.F.), P30-ES002109 (MIT Center for Environmental Health Sciences) and P01-CA26731. We thank Alyssa Terestre for assisting with manuscript preparation.

## REFERENCES

- Avenaud, P., Marais, A., Monteiro, L., Le Bail, B., Bioulac Sage, P., Balabaud, C. & M egraud, F. (2000). Detection of *Helicobacter* species in the liver of patients with and without primary liver carcinoma. *Cancer* **89**, 1431–1439.
- Bornschein, J., Kandulski, A., Selgrad, M. & Malfertheiner, P. (2010). From gastric inflammation to gastric cancer. *Dig Dis* **28**, 609–614.
- Bridgeford, E. C., Marini, R. P., Feng, Y., Parry, N. M., Rickman, B. & Fox, J. G. (2008). Gastric *Helicobacter* species as a cause of feline gastric lymphoma: a viable hypothesis. *Vet Immunol Immunopathol* **123**, 106–113.
- Burman, W. J., Cohn, D. L., Reves, R. R. & Wilson, M. L. (1995). Multifocal cellulitis and monoarticular arthritis as manifestations of *Helicobacter cinaedi* bacteremia. *Clin Infect Dis* **20**, 564–570.
- Burnens, A. P., Stanley, J., Morgenstern, R. & Nicolet, J. (1994). Gastroenteritis associated with *Helicobacter pullorum*. *Lancet* **344**, 1569–1570.
- Cahill, R. J., Foltz, C. J., Fox, J. G., Dangler, C. A., Powrie, F. & Schauer, D. B. (1997). Inflammatory bowel disease: an immunity-mediated condition triggered by bacterial infection with *Helicobacter hepaticus*. *Infect Immun* **65**, 3126–3131.
- Candido, J. & Hagemann, T. (2013). Cancer-related inflammation. *J Clin Immunol* **33** (Suppl 1), 79–84.
- Carvalho, F. A., Nalbantoglu, I., Aitken, J. D., Uchiyama, R., Su, Y., Doho, G. H., Vijay-Kumar, M. & Gewirtz, A. T. (2012). Cytosolic flagellin receptor NLR4 protects mice against mucosal and systemic challenges. *Mucosal Immunol* **5**, 288–298.
- Ceelen, L., Decostere, A., Verschraegen, G., Ducatelle, R. & Haesebrouck, F. (2005). Prevalence of *Helicobacter pullorum* among patients with gastrointestinal disease and clinically healthy persons. *J Clin Microbiol* **43**, 2984–2986.
- Chan, V., Crocetti, G., Grehan, M., Zhang, L., Danon, S., Lee, A. & Mitchell, H. (2005). Visualization of *Helicobacter* species within the murine cecal mucosa using specific fluorescence *in situ* hybridization. *Helicobacter* **10**, 114–124.



- Chichlowski, M., Sharp, J. M., Vanderford, D. A., Myles, M. H. & Hale, L. P. (2008). *Helicobacter typhlonius* and *Helicobacter rodentium* differentially affect the severity of colon inflammation and inflammation-associated neoplasia in IL10-deficient mice. *Comp Med* **58**, 534–541.
- Chien, C. C., Taylor, N. S., Ge, Z., Schauer, D. B., Young, V. B. & Fox, J. G. (2000). Identification of *cdtB* homologues and cytolethal distending toxin activity in enterohepatic *Helicobacter* spp. *J Med Microbiol* **49**, 525–534.
- Chin, E. Y., Dangler, C. A., Fox, J. G. & Schauer, D. B. (2000). *Helicobacter hepaticus* infection triggers inflammatory bowel disease in T cell receptor  $\alpha\beta$  mutant mice. *Comp Med* **50**, 586–594.
- Cimolai, N., Gill, M. J., Jones, A., Flores, B., Stamm, W. E., Laurie, W., Madden, B. & Shahrabadi, M. S. (1987). “*Campylobacter cinaedi*” bacteremia: case report and laboratory findings. *J Clin Microbiol* **25**, 942–943.
- Cortes-Bratti, X., Chaves-Olarte, E., Lagergård, T. & Thelestam, M. (1999). The cytolethal distending toxin from the chancroid bacterium *Haemophilus ducreyi* induces cell-cycle arrest in the G2 phase. *J Clin Invest* **103**, 107–115.
- Dewhirst, F. E., Shen, Z., Scimeca, M. S., Stokes, L. N., Boumenna, T., Chen, T., Paster, B. J. & Fox, J. G. (2005). Discordant 16S and 23S rRNA gene phylogenies for the genus *Helicobacter*: implications for phylogenetic inference and systematics. *J Bacteriol* **187**, 6106–6118.
- Eiró, N. & Vizoso, F. J. (2012). Inflammation and cancer. *World J Gastrointest Surg* **4**, 62–72.
- Elinav, E., Strowig, T., Kau, A. L., Henao-Mejia, J., Thaiss, C. A., Booth, C. J., Peaper, D. R., Bertin, J., Eisenbarth, S. C. & other authors (2011). NLRP6 inflammasome regulates colonic microbial ecology and risk for colitis. *Cell* **145**, 745–757.
- Erdman, S. E., Poutahidis, T., Tomczak, M., Rogers, A. B., Cormier, K., Plank, B., Horwitz, B. H. & Fox, J. G. (2003). CD4<sup>+</sup> CD25<sup>+</sup> regulatory T lymphocytes inhibit microbially induced colon cancer in Rag2-deficient mice. *Am J Pathol* **162**, 691–702.
- Erdman, S. E., Rao, V. P., Poutahidis, T., Rogers, A. B., Taylor, C. L., Jackson, E. A., Ge, Z., Lee, C. W., Schauer, D. B. & other authors (2009). Nitric oxide and TNF- $\alpha$  trigger colonic inflammation and carcinogenesis in *Helicobacter hepaticus*-infected, Rag2-deficient mice. *Proc Natl Acad Sci U S A* **106**, 1027–1032.
- Fernandez, K. R., Hansen, L. M., Vandamme, P., Beaman, B. L. & Solnick, J. V. (2002). Captive rhesus monkeys (*Macaca mulatta*) are commonly infected with *Helicobacter cinaedi*. *J Clin Microbiol* **40**, 1908–1912.
- Flores, B. M., Fennell, C. L., Kuller, L., Bronsdon, M. A., Morton, W. R. & Stamm, W. E. (1990). Experimental infection of pig-tailed macaques (*Macaca nemestrina*) with *Campylobacter cinaedi* and *Campylobacter fennelliae*. *Infect Immun* **58**, 3947–3953.
- Foley, J. E., Solnick, J. V., Lapointe, J. M., Jang, S. & Pedersen, N. C. (1998). Identification of a novel enteric *Helicobacter* species in a kitten with severe diarrhea. *J Clin Microbiol* **36**, 908–912.
- Foley, J. E., Marks, S. L., Munson, L., Melli, A., Dewhirst, F. E., Yu, S., Shen, Z. & Fox, J. G. (1999). Isolation of *Helicobacter canis* from a colony of Bengal cats with endemic diarrhea. *J Clin Microbiol* **37**, 3271–3275.
- Foltz, C. J., Fox, J. G., Cahill, R., Murphy, J. C., Yan, L., Shames, B. & Schauer, D. B. (1998). Spontaneous inflammatory bowel disease in multiple mutant mouse lines: association with colonization by *Helicobacter hepaticus*. *Helicobacter* **3**, 69–78.
- Fox, J. G. (2002). The non-*H. pylori* helicobacters: their expanding role in gastrointestinal and systemic diseases. *Gut* **50**, 273–283.
- Fox, J. G., Li, X., Yan, L., Cahill, R. J., Hurley, R., Lewis, R. & Murphy, J. C. (1996a). Chronic proliferative hepatitis in A/JCr mice associated with persistent *Helicobacter hepaticus* infection: a model of *Helicobacter*-induced carcinogenesis. *Infect Immun* **64**, 1548–1558.
- Fox, J. G., Yan, L., Shames, B., Campbell, J., Murphy, J. C. & Li, X. (1996b). Persistent hepatitis and enterocolitis in germfree mice infected with *Helicobacter hepaticus*. *Infect Immun* **64**, 3673–3681.
- Fox, J. G., Gorelick, P. L., Kullberg, M. C., Ge, Z., Dewhirst, F. E. & Ward, J. M. (1999). A novel urease-negative *Helicobacter* species associated with colitis and typhlitis in IL-10-deficient mice. *Infect Immun* **67**, 1757–1762.
- Fox, J. G., Chien, C. C., Dewhirst, F. E., Paster, B. J., Shen, Z., Melito, P. L., Woodward, D. L. & Rodgers, F. G. (2000). *Helicobacter canadensis* sp. nov. isolated from humans with diarrhea as an example of an emerging pathogen. *J Clin Microbiol* **38**, 2546–2549.
- Fox, J. G., Handt, L., Sheppard, B. J., Xu, S., Dewhirst, F. E., Motzel, S. & Klein, H. (2001a). Isolation of *Helicobacter cinaedi* from the colon, liver, and mesenteric lymph node of a rhesus monkey with chronic colitis and hepatitis. *J Clin Microbiol* **39**, 1580–1585.
- Fox, J. G., Handt, L., Xu, S., Shen, Z., Dewhirst, F. E., Paster, B. J., Dangler, C. A., Lodge, K., Motzel, S. & Klein, H. (2001b). Novel *Helicobacter* species isolated from rhesus monkeys with chronic idiopathic colitis. *J Med Microbiol* **50**, 421–429.
- Fox, J. G., Shen, Z., Xu, S., Feng, Y., Dangler, C. A., Dewhirst, F. E., Paster, B. J. & Cullen, J. M. (2002). *Helicobacter marmotae* sp. nov. isolated from livers of woodchucks and intestines of cats. *J Clin Microbiol* **40**, 2513–2519.
- Fox, J. G., Boutin, S. R., Handt, L. K., Taylor, N. S., Xu, S., Rickman, B., Marini, R. P., Dewhirst, F. E., Paster, B. J. & other authors (2007). Isolation and characterization of a novel helicobacter species, “*Helicobacter macacae*,” from rhesus monkeys with and without chronic idiopathic colitis. *J Clin Microbiol* **45**, 4061–4063.
- Fox, J. G., Ge, Z., Whary, M. T., Erdman, S. E. & Horwitz, B. H. (2011). *Helicobacter hepaticus* infection in mice: models for understanding lower bowel inflammation and cancer. *Mucosal Immunol* **4**, 22–30.
- Garcia, A., Zeng, Y., Muthupalani, S., Ge, Z., Potter, A., Mogley, M. W., Boussahmain, C., Feng, Y., Wishnok, J. S. & Fox, J. G. (2011). *Helicobacter hepaticus*-induced liver tumor promotion is associated with increased serum bile acid and a persistent microbial-induced immune response. *Cancer Res* **71**, 2529–2540.
- Ge, Z., Feng, Y., Muthupalani, S., Eurell, L. L., Taylor, N. S., Whary, M. T. & Fox, J. G. (2011). Coinfection with enterohepatic *Helicobacter* species can ameliorate or promote *Helicobacter pylori*-induced gastric pathology in C57BL/6 mice. *Infect Immun* **79**, 3861–3871.
- Goldman, C. G. & Mitchell, H. M. (2010). *Helicobacter* spp. other than *Helicobacter pylori*. *Helicobacter* **15** (Suppl 1), 69–75.
- Grivennikov, S. I. & Karin, M. (2010). Inflammation and oncogenesis: a vicious connection. *Curr Opin Genet Dev* **20**, 65–71.
- Grivennikov, S. I., Greten, F. R. & Karin, M. (2010). Immunity, inflammation, and cancer. *Cell* **140**, 883–899.
- Haggerty, T. D., Perry, S., Sanchez, L., Perez-Perez, G. & Parsonnet, J. (2005). Significance of transiently positive enzyme-linked immunosorbent assay results in detection of *Helicobacter pylori* in stool samples from children. *J Clin Microbiol* **43**, 2220–2223.
- Hansen, R., Thomson, J. M., Fox, J. G., El-Omar, E. M. & Hold, G. L. (2011). Could *Helicobacter* organisms cause inflammatory bowel disease? *FEMS Immunol Med Microbiol* **61**, 1–14.
- Hsueh, P. R., Teng, L. J., Hung, C. C., Chen, Y. C., Yang, P. C., Ho, S. W. & Luh, K. T. (1999). Septic shock due to *Helicobacter fennelliae* in a non-human immunodeficiency virus-infected heterosexual patient. *J Clin Microbiol* **37**, 2084–2086.
- Huber, S., Gagliani, N., Zenewicz, L. A., Huber, F. J., Bosurgi, L., Hu, B., Hedl, M., Zhang, W., O’Connor, W., Jr & other authors (2012).

- IL-22BP is regulated by the inflammasome and modulates tumorigenesis in the intestine. *Nature* **491**, 259–263.
- Hung, C. C., Hsueh, P. R., Chen, M. Y., Teng, L. J., Chen, Y. C., Luh, K. T. & Chuang, C. Y. (1997). Bacteremia caused by *Helicobacter cinaedi* in an AIDS patients. *J Formos Med Assoc* **96**, 558–560.
- Kempster, S. L., Belteki, G., Forhead, A. J., Fowden, A. L., Catalano, R. D., Lam, B. Y., McFarlane, I., Charnock-Jones, D. S. & Smith, G. C. (2011). Developmental control of the Nlrp6 inflammasome and a substrate, IL-18, in mammalian intestine. *Am J Physiol Gastrointest Liver Physiol* **300**, G253–G263.
- Kitamura, T., Kawamura, Y., Ohkusu, K., Masaki, T., Iwashita, H., Sawa, T., Fujii, S., Okamoto, T. & Akaike, T. (2007). *Helicobacter cinaedi* cellulitis and bacteremia in immunocompetent hosts after orthopedic surgery. *J Clin Microbiol* **45**, 31–38.
- Lamkanfi, M. & Dixit, V. M. (2011). Modulation of inflammasome pathways by bacterial and viral pathogens. *J Immunol* **187**, 597–602.
- Lapin, B. A. & Yakovleva, L. A. (2014). Spontaneous and experimental malignancies in non-human primates. *J Med Primatol* **43**, 100–110.
- Lertpiriyapong, K., Gamazon, E. R., Feng, Y., Park, D. S., Pang, J., Botka, G., Graffam, M. E., Ge, Z. & Fox, J. G. (2012). *Campylobacter jejuni* type VI secretion system: roles in adaptation to deoxycholic acid, host cell adherence, invasion, and *in vivo* colonization. *PLoS ONE* **7**, e42842.
- Maggio-Price, L., Treuting, P., Zeng, W., Tsang, M., Bielefeldt-Ohmann, H. & Iritani, B. M. (2006). *Helicobacter* infection is required for inflammation and colon cancer in SMAD3-deficient mice. *Cancer Res* **66**, 828–838.
- Mangerich, A., Knutson, C. G., Parry, N. M., Muthupalani, S., Ye, W., Prestwich, E., Cui, L., McFaline, J. L., Mobley, M. & other authors (2012). Infection-induced colitis in mice causes dynamic and tissue-specific changes in stress response and DNA damage leading to colon cancer. *Proc Natl Acad Sci U S A* **109**, E1820–E1829.
- Marini, R. P., Muthupalani, S., Shen, Z., Buckley, E. M., Alvarado, C., Taylor, N. S., Dewhirst, F. E., Whary, M. T., Patterson, M. M. & Fox, J. G. (2010). Persistent infection of rhesus monkeys with '*Helicobacter macacae*' and its isolation from an animal with intestinal adenocarcinoma. *J Med Microbiol* **59**, 961–969.
- Master, S. S., Rampini, S. K., Davis, A. S., Keller, C., Ehlers, S., Springer, B., Timmins, G. S., Sander, P. & Deretic, V. (2008). *Mycobacterium tuberculosis* prevents inflammasome activation. *Cell Host Microbe* **3**, 224–232.
- Melito, P. L., Munro, C., Chipman, P. R., Woodward, D. L., Booth, T. F. & Rodgers, F. G. (2001). *Helicobacter winghamensis* sp. nov., a novel *Helicobacter* sp. isolated from patients with gastroenteritis. *J Clin Microbiol* **39**, 2412–2417.
- Oyama, K., Khan, S., Okamoto, T., Fujii, S., Ono, K., Matsunaga, T., Yoshitake, J., Sawa, T., Tomida, J. & other authors (2012). Identification of and screening for human *Helicobacter cinaedi* infections and carriers via nested PCR. *J Clin Microbiol* **50**, 3893–3900.
- Pereira, M. S., Morgantetti, G. F., Massis, L. M., Horta, C. V., Hori, J. I. & Zamboni, D. S. (2011). Activation of NLR4 by flagellated bacteria triggers caspase-1-dependent and -independent responses to restrict *Legionella pneumophila* replication in macrophages and *in vivo*. *J Immunol* **187**, 6447–6455.
- Proietti, F. A., Carneiro-Proietti, A. B., Catalan-Soares, B. C. & Murphy, E. L. (2005). Global epidemiology of HTLV-I infection and associated diseases. *Oncogene* **24**, 6058–6068.
- Ranatunga, D. C., Ramakrishnan, A., Uprety, P., Wang, F., Zhang, H., Margolick, J. B., Brayton, C. & Bream, J. H. (2012). A protective role for human IL-10-expressing CD4<sup>+</sup> T cells in colitis. *J Immunol* **189**, 1243–1252.
- Rathinam, V. A., Vanaja, S. K. & Fitzgerald, K. A. (2012). Regulation of inflammasome signaling. *Nat Immunol* **13**, 333–342.
- Rodriguez, N. A., Garcia, K. D., Fortman, J. D., Hewett, T. A., Bunte, R. M. & Bennett, B. T. (2002). Clinical and histopathological evaluation of 13 cases of adenocarcinoma in aged rhesus macaques (*Macaca mulatta*). *J Med Primatol* **31**, 74–83.
- Russell, R. G., Sarmiento, J. I., Fox, J. & Panigrahi, P. (1990). Evidence of reinfection with multiple strains of *Campylobacter jejuni* and *Campylobacter coli* in *Macaca nemestrina* housed under hyperendemic conditions. *Infect Immun* **58**, 2149–2155.
- Saunders, K. E., Shen, Z., Dewhirst, F. E., Paster, B. J., Dangler, C. A. & Fox, J. G. (1999). Novel intestinal *Helicobacter* species isolated from cotton-top tamarins (*Saguinus oedipus*) with chronic colitis. *J Clin Microbiol* **37**, 146–151.
- Shen, Z., Feng, Y., Rogers, A. B., Rickman, B., Whary, M. T., Xu, S., Clapp, K. M., Boutin, S. R. & Fox, J. G. (2009). Cytolethal distending toxin promotes *Helicobacter cinaedi*-associated typhlocolitis in interleukin-10-deficient mice. *Infect Immun* **77**, 2508–2516.
- Sugai, M., Kawamoto, T., Pérès, S. Y., Ueno, Y., Komatsuzawa, H., Fujiwara, T., Kurihara, H., Suginaka, H. & Oswald, E. (1998). The cell cycle-specific growth-inhibitory factor produced by *Actinobacillus actinomycetemcomitans* is a cytolethal distending toxin. *Infect Immun* **66**, 5008–5019.
- Taylor, N. S., Ge, Z., Shen, Z., Dewhirst, F. E. & Fox, J. G. (2003). Cytolethal distending toxin: a potential virulence factor for *Helicobacter cinaedi*. *J Infect Dis* **188**, 1892–1897.
- Thomson, J. M., Hansen, R., Berry, S. H., Hope, M. E., Murray, G. I., Mukhopadhyay, I., McLean, M. H., Shen, Z., Fox, J. G. & other authors (2011). Enterohepatic *Helicobacter* in ulcerative colitis: potential pathogenic entities? *PLoS ONE* **6**, e17184.
- Uno, H., Alsum, P., Zimbric, M. L., Houser, W. D., Thomson, J. A. & Kemnitz, J. W. (1998). Colon cancer in aged captive rhesus monkeys (*Macaca mulatta*). *Am J Primatol* **44**, 19–27.
- Valverde, C. R., Tarara, R. P., Griffey, S. M. & Roberts, J. A. (2000). Spontaneous intestinal adenocarcinoma in geriatric macaques (*Macaca* sp.). *Comp Med* **50**, 540–544.
- Whary, M. T., Danon, S. J., Feng, Y., Ge, Z., Sundina, N., Ng, V., Taylor, N. S., Rogers, A. B. & Fox, J. G. (2006). Rapid onset of ulcerative typhlocolitis in B6.129P2-IL10tm1Cgn (IL-10<sup>-/-</sup>) mice infected with *Helicobacter trogontum* is associated with decreased colonization by altered Schaedler's flora. *Infect Immun* **74**, 6615–6623.
- Young, V. B., Chien, C. C., Knox, K. A., Taylor, N. S., Schauer, D. B. & Fox, J. G. (2000a). Cytolethal distending toxin in avian and human isolates of *Helicobacter pullorum*. *J Infect Dis* **182**, 620–623.
- Young, V. B., Knox, K. A. & Schauer, D. B. (2000b). Cytolethal distending toxin sequence and activity in the enterohepatic pathogen *Helicobacter hepaticus*. *Infect Immun* **68**, 184–191.
- Zaki, M. H., Boyd, K. L., Vogel, P., Kastan, M. B., Lamkanfi, M. & Kanneganti, T. D. (2010). The NLRP3 inflammasome protects against loss of epithelial integrity and mortality during experimental colitis. *Immunity* **32**, 379–391.