

Scar Endometriosis-A Sequel of Caesarean Section

NANDA J PATIL¹, VIJAY KUMAR², ANITA GUPTA³

ABSTRACT

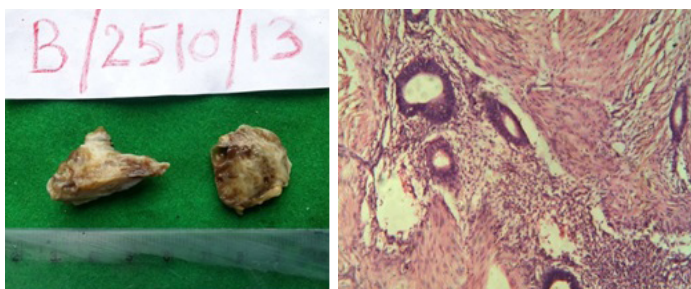
Endometriosis is presence of functioning endometrial tissue outside the uterine cavity, usually in the pelvis. However, its occurrence is very rare (0.03%-0.4%) in the scars which follow obstetrical and gynaecological surgeries. We are reporting two cases of scar endometriosis which occurred after caesarean sections. Both cases presented with abdominal pain at caesarean scar sites, one of which gave a cyclical history. Clinical examination revealed painful swellings in both cases, which were misdiagnosed as stitch granulomas. Wide surgical excisions were done and histopathology examination revealed a diagnosis of scar endometriosis. We are presenting these cases because of their rarity, their uncommon sites and difficulty in diagnosing the conditions clinically.

Keywords: Endometriosis, Misdiagnosis as stitch granuloma

CASE REPORT

CASE 1

A 25-year-old female patient came to Department of Obstetrics and Gynaecology with the complaint of pain at caesarean scar site, which had increased just before menstrual cycle. She had a prior caesarean delivery 3 years back. Abdominal examination revealed a swelling of size of about 4 x 3 cm at the site of caesarean scar, which was firm, tender and immobile, which was initially thought to be a stitch granuloma. Patient underwent excision of the swelling. Specimen was sent to the Department of Pathology for a histopathological examination. Grossly, it revealed a single globular soft tissue mass which measured 3x3 cm, which was firm in consistency. Cut section was grey brown in colour, solid and cystic, with areas of haemorrhages. Histopathology of the mass confirmed the diagnosis of scar endometriosis [Table/Fig-1, 2]. Her postoperative period was uneventful.



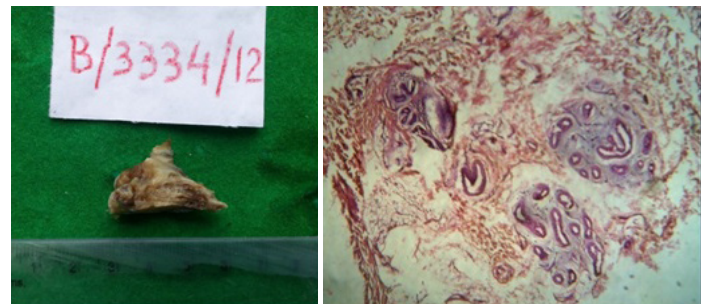
[Table/Fig-1]: Gross-A grey-brown mass with cystic areas and hemorrhage's

[Table/Fig-2]: Microscopy- Endometrial gland and stroma set in a fibro adipose tissue. (Hematoxyline and Eosine stain 100X)

CASE 2

A 30-year-old woman was seen in the Department of Surgery, in consultation for a painful swelling below the umbilical region, at caesarean scar. The pain did not reveal any cyclical pattern and it was not associated with any discharge. She was an otherwise healthy woman with no significant medical history. Her past history revealed a caesarean section which had been done 10 years back. Local examination revealed a 4x3 cm. nodular, irregular, painful, swelling at caesarean scar site. A preliminary diagnosis of a stitch granuloma was entertained, and the patient underwent an excision of the abdominal wound. The specimen was received for histopathological examination. Gross examination showed a single,

grey brown, soft to firm soft tissue mass which measured 4x3 cm, with cystic areas. Histopathology of the excised mass confirmed the case as scar endometriosis [Table/Fig-3,4]. The postoperative period was uneventful. The patient is on regular follow up for checking for recurrence.



[Table/Fig-3]: Gross- A grey-brown soft tissue with cystic areas

[Table/Fig-4]: Microscopy- Proliferating of endometrial glands mixed with stroma in a fibro adipose tissue (Hematoxyline and Eosine stain 100X)

DISCUSSION

Scar endometriosis is an extremely rare condition and surgical scar endometriosis which occurs after caesarean sections has an incidence of 0.03-0.4% [1,2]. We have encountered two such cases which followed caesarean sections. The interval between operation and clinical manifestations varies from three months to 10 years [3]. In our cases, this interval was three years to 10 years respectively. The common clinical presentation is swelling and pain at the site of surgical scar. Only 20% patients give history of cyclical changes in the intensity of pain during menstruation [1], as was seen in one of our cases, while the other case presented with abdominal pain without cyclical pattern and without any discharge. Most of these patients are misdiagnosed with other surgical conditions like haematomas, neuromas, hernias, stitch granulomas, abscesses or neoplastic tissues [4,5]. Both of our cases were misdiagnosed as stitch granulomas.

Diagnosis- CT and MRI have very high sensitivities (90-92%) and specificities (91-98%) for diagnosing this condition [4,5]. These diagnostic modalities were not tried on our cases. Histopathology is the accurate diagnostic method for this condition [5], as was observed in our cases, which revealed endometrial glands with stroma, along with haemosiderin laden macrophages.

Management- Wide surgical excision with a 1 cm margin is the definitive treatment [1,4]. The same treatment was applied for our

cases. Good surgical techniques and vigilance during caesarean sections may help in preventing scar endometriosis. Thorough cleaning and irrigation of abdominal wall wound before closure is recommended [3].

CONCLUSION

Caesarean section scar endometriosis is a very rare condition which can be misdiagnosed as other conditions like stitch granulomas, haematomas and hernias. Histopathology gives the definitive diagnosis. Gross features like reddish brown nodules along with cysts give a clue on its diagnosis. High index of suspicion should be maintained for cases which present with painful swellings in the abdominal scars, which have previous histories of obstetrical or gynaecological surgeries.

REFERENCES

- [1] PJ Danielpour, JC Layke, N Durie, LT Glickman. Scar endometriosis- a rare cause for a painful scar: A case report and review of the literature. *Can J Plast Surg.* 2010; 18(1):19-20.
- [2] Iker Sengul, Demet Sengul, Serkan Kahyaoglu, Inci Kahyaoglu. Incisional endometriosis: a report of 3 cases. *Can J Surg.* 2009; 52(5): 444-45.
- [3] P Goel, SS Sood, Romilla, A Dalal. Cesarean scar endometriosis- Report of two cases. *Indian J Med Sci.* 2005;59 (11);495-8.
- [4] Cihangir Uzuncakmak, Ahmet Guldaz, Hasene Ozcam, Kemal Dinc. Scar endometriosis-A Case report of This Uncommon Entity and Review of the Literature. *Case Reports in Obstetrics and Gynecology.* 2013; Article ID 386783.
- [5] Ashim K Lahiri, KiranSharma, Naser Busiri. Endometriosis of the uterine cesarean section scar: A case report. *Indian J Radiol Imaging.* 2008; 66-68.

PARTICULARS OF CONTRIBUTORS:

1. Associate Professor, Department of Pathology, Krishna Institute of Medical Sciences, Karad, Maharashtra, India.
2. PG Resident, Department of Pathology, Krishna Institute of Medical Sciences, Karad, Maharashtra, India.
3. PG Resident, Department of Pathology, Krishna Institute of Medical Sciences, Karad, Maharashtra, India.

NAME, ADDRESS, E-MAIL ID OF THE CORRESPONDING AUTHOR:

Dr. Vijay Kumar,

PG Resident, Department of Pathology, Krishna Institute of Medical Sciences, Karad, Maharashtra, India.

Phone: 8275368823, E-mail: dr.vijaysoni786@gmail.com

FINANCIAL OR OTHER COMPETING INTERESTS: None.

Date of Submission: **Sep 03, 2013**

Date of Peer Review: **Dec 15, 2013**

Date of Acceptance: **Jan 15, 2014**

Date of Publishing: **Apr 15, 2014**