

## Raine syndrome

B. Vishwanath, K. Srinivasa, M. Veera Shankar

Department of Pediatrics, Vijayanagar Institute of Medical Sciences, Cantonment, Bellary, Karnataka, India

Raine syndrome is a rare genetic disorder with characteristic features of exophthalmos, choanal atresia or stenosis, osteosclerosis and cerebral calcifications. Most of babies with this disorder die immediately after birth. We report a baby who was 7 weeks old at the time of presentation.

**Key words:** Lethal, osteosclerosis, Raine syndrome

### Introduction

Raine syndrome, also called as lethal osteosclerotic bone dysplasia, first described by Raine and Winter in 1989 in a term female baby, which died soon after birth. This has high mortality and most babies are still born or die during the neonatal period. This is very rare genetic disorder and very few cases have been reported all over. To the best of our knowledge, this second reported case from India.

### Case Report

A 1-month-20-day-old baby, born to second degree consanguineous parents, was brought with complaints of inability to suck at the breast and failure to thrive since birth. There was a history of episodes of cyanosis while feeding, which used to subside by crying. Baby

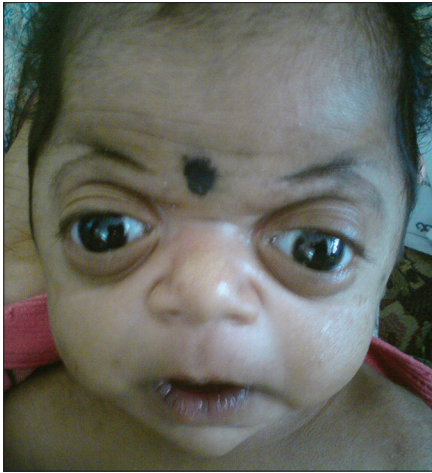
was fed with cow's milk and expressed breast milk. Mother was booked a case with no significant antenatal history. The baby cried soon after birth. This was fifth baby born to parents. The first baby and fourth baby died soon after birth and they had features suggestive of Raine syndrome. Third child is 4-year-old now and he is healthy.

Physical examination revealed stable vitals and there was no cyanosis. Baby was weighing 2.75 kg, length was 48 cm and head circumference was 33 cm. The anterior fontanel was bulged; it was measuring 6 cm × 4 cm and posterior fontanel 5 cm × 4 cm. There was exophthalmos, small nose with depressed nasal bridge, gum hyperplasia, high-arched narrow palate, long philtrum and dysplastic ears [Figure 1]. Baby was also having short fingers and toes. The infant feeding tube (sizes 5 and 6) could not be passed through the nose indicating associated choanal atresia/stenosis. Fibreoptic posterior rhinoscopy examination revealed the presence of choanal atresia. Baby's lungs were clear cardiovascular system, central nervous system and abdominal examinations were normal.

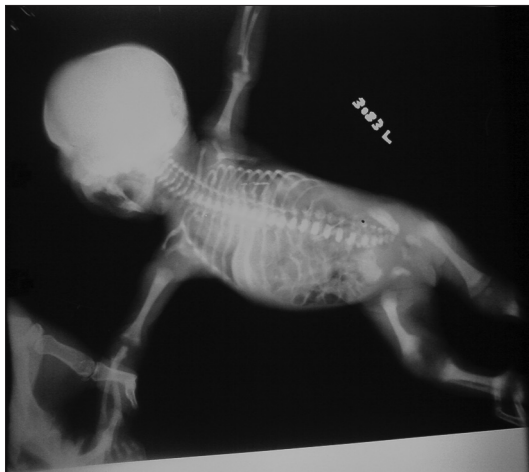Baby's routine blood investigations were normal. Infantogram of the baby showed generalized osteosclerosis [Figure 2]. Computed tomography scan of the brain showed diffuse hyperdense areas of calcification in periventricular region, corpus callosum and basal ganglia on both sides [Figure 3]. Serology for congenital cytomegalovirus infection was negative. The molecular studies could not be carried out due to the financial constraints. Diagnosis of Raine syndrome was made based on typical clinical presentation, radiographic picture and brain tomography findings.

Access this article online	
Quick Response Code:	Website: <a href="http://www.ijhg.com">www.ijhg.com</a>
	DOI: 10.4103/0971-6866.132761

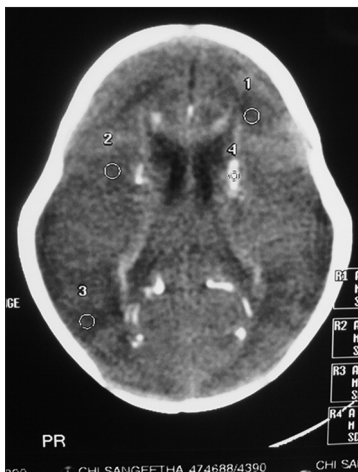**Address for correspondence:** Dr. B. Vishwanath, Department of Pediatrics, Vijayanagar Institute of Medical Sciences, Cantonment, Bellary - 583 104, Karnataka, India. E-mail: vishubee@rediffmail.com



**Figure 1: Raine syndrome baby showing exophthalmos, small nose with depressed nasal bridge, long philtrum and dysplastic ears**



**Figure 2: Infantogram of baby showing generalized osteosclerosis of bones**



**Figure 3: Computed tomography scan of the brain showing calcifications in periventricular white matter, corpus callosum and basal ganglia**

## Discussion

Raine syndrome, also known as lethal osteosclerotic bone dysplasia, is a rare autosomal recessive disorder characterized by exophthalmos, microcephaly, depressed nasal bridge, bilateral choanal atresia/stenosis, gum hyperplasia and osteosclerosis.<sup>[1]</sup> The osteosclerosis is usually generalized, but occasionally may be focal involving only few bones.<sup>[2]</sup> Palate usually shows cleft, but may be higharched and narrow. The babies affected with this disorder show intracranial calcifications.<sup>[3]</sup> Calcifications are seen in parietal and occipital periventricular white matter and corpus callosum, but never occur in cortex, temporal lobes, internal capsule, cerebellum and brain stem.<sup>[4]</sup>

Major association between sclerosing dysplasia and intracranial calcification is seen in osteopetrosis associated with renal tubular acidosis and carbonic anhydrase II deficiency.<sup>[5]</sup> However, in this disorder, the calcifications are usually seen after 2 years of age exclusively in basal ganglia and cortex and characteristic clinical features of Raine syndrome are lacking.<sup>[3,6]</sup>

It is inherited as autosomal recessive; mutations in FAM20C gene on chromosome 7 are identified in babies with this disorder.<sup>[7]</sup>

Initial reports showed that this disorder is lethal and most of babies with this disorder died in early months of their life. However, mutations in FAM20C gene were also noticed in older children with phenotypic features of Raine syndrome with osteosclerosis, indicating that lethality is not essential for diagnosis.<sup>[8]</sup>

## References

1. Raine J, Winter RM, Davey A, Tucker SM. Unknown syndrome: Microcephaly, hypoplastic nose, exophthalmos, gum hyperplasia, cleft palate, low set ears, and osteosclerosis. *J Med Genet* 1989;26:786-8.
2. Al-Gazali LI, Jehier K, Nazih B, Abtin F, Haas D, Sadaghatian R. Further delineation of Raine syndrome. *Clin Dysmorphol* 2003;12:89-93.
3. Al Mane KA, Coates RK, McDonald P. Intracranial calcification in Raine syndrome. *Pediatr Radiol* 1996;26:55-8.
4. Rickert CH, Rieder H, Rehder H, Hülkamp G, Hörnig-Franz I, Louwen F, et al. Neuropathology of Raine syndrome. *Acta Neuropathol* 2002;103:281-7.

5. Ohlsson A, Cumming WA, Paul A, Sly WS. Carbonic anhydrase II deficiency syndrome: Recessive osteopetrosis with renal tubular acidosis and cerebral calcification. *Pediatrics* 1986;77:371-81.
6. Nampoothiri S, Anikster Y. Carbonic anhydrase II deficiency a novel mutation. *Indian Pediatr* 2009;46:532-4.
7. Simpson MA, Hsu R, Keir LS, Hao J, Sivapalan G, Ernst LM, *et al.* Mutations in FAM20C are associated with lethal osteosclerotic bone dysplasia (Raine syndrome), highlighting a crucial molecule in bone development. *Am J Hum Genet* 2007;81:906-12.
8. Simpson MA, Scheuerle A, Hurst J, Patton MA, Stewart H, Crosby AH. Mutations in FAM20C also identified in non-lethal osteosclerotic bone dysplasia. *Clin Genet* 2009;75:271-6.

**Cite this article as:** Vishwanath B, Srinivasa K, Shankar MV. Raine syndrome. *Indian J Hum Genet* 2014;20:72-4.

**Source of Support:** Nil, **Conflict of Interest:** None declared.

### Author Help: Online submission of the manuscripts

Articles can be submitted online from <http://www.journalonweb.com>. For online submission, the articles should be prepared in two files (first page file and article file). Images should be submitted separately.

1) **First Page File:**

Prepare the title page, covering letter, acknowledgement etc. using a word processor program. All information related to your identity should be included here. Use text/rtf/doc/pdf files. Do not zip the files.

2) **Article File:**

The main text of the article, beginning with the Abstract to References (including tables) should be in this file. Do not include any information (such as acknowledgement, your names in page headers etc.) in this file. Use text/rtf/doc/pdf files. Do not zip the files. Limit the file size to 1 MB. Do not incorporate images in the file. If file size is large, graphs can be submitted separately as images, without their being incorporated in the article file. This will reduce the size of the file.

3) **Images:**

Submit good quality color images. Each image should be less than 4096 kb (4 MB) in size. The size of the image can be reduced by decreasing the actual height and width of the images (keep up to about 6 inches and up to about 1800 x 1200 pixels). JPEG is the most suitable file format. The image quality should be good enough to judge the scientific value of the image. For the purpose of printing, always retain a good quality, high resolution image. This high resolution image should be sent to the editorial office at the time of sending a revised article.

4) **Legends:**

Legends for the figures/images should be included at the end of the article file.