

# Usefulness of 3D CT in Diagnosis of Cervical Rib Presenting as Supraclavicular Swelling of Short Duration

SHRUTI CHANDAK<sup>1</sup>, ASHUTOSH KUMAR<sup>2</sup>

## ABSTRACT

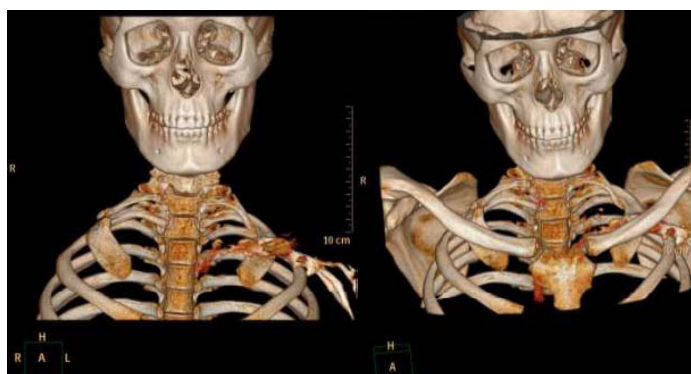This is a unique case of cervical rib since the patient presented as a firm neck swelling of short duration which was clinically palpable as a superficial neck mass and referred for FNAC for the same. Since FNAC did not yield any positive result, the patient was then referred for CT which showed bilateral cervical ribs with pseudoarticulation with the 1<sup>st</sup> thoracic rib on the right side which is quite rare. The clinical importance of our case is to keep in mind a differential diagnosis of cervical rib in firm to hard clinically palpable posterior triangle neck masses. It is also important to diagnose cervical ribs in patients undergoing CT of the neck since they are under reported as determined in previous studies.

## CASE REPORT

An 18-year-old boy presented with complains of lump in the right supraclavicular fossa noticed 15 days back. He was asymptomatic before that. There was no history of any numbness or weakness in the upper limbs. There was no history of trauma, weight loss, night sweats, fever or chills.

On examination, there was a superficial, clinically palpable swelling in the right supraclavicular region which was firm to hard and mildly tender to touch. There was no local rise of temperature. The swelling was not pulsatile. There was no palpable thyroid mass. The ears, nose, mouth and throat including neurologic and vascular systems were unremarkable. There was no cervical lymphadenopathy. Since the lump was superficially palpable, the patient was directly referred for an FNAC assuming it to be a lymph node. The patient underwent FNAC which yielded only hemorrhagic aspirate. On microscopic examination, the cellularity was scant. The patient was then first referred for an ultrasound which did not reveal any abnormality. A CT scan of the neck was then carried out to ascertain the nature of the swelling.

CT scan of the neck was done using the Phillips Brilliance 128 slice CT Scanner. Multiplanar & 3D reconstructions were done in the workstation. CT scan revealed Bilateral partial cervical ribs. The right cervical rib showed a pseudoarthrosis with the 1<sup>st</sup> thoracic rib on the right side [Table/Fig-1 a,b]. An accessory bone was also present at the articulation site with minimal soft tissue [Table/Fig-2]. There was



[Table/Fig-1 a&b]: 3D CT images showing bilateral cervical ribs with pseudoarthrosis on the rightside

**Keywords:** Cervical rib, supraclavicular swelling, CT

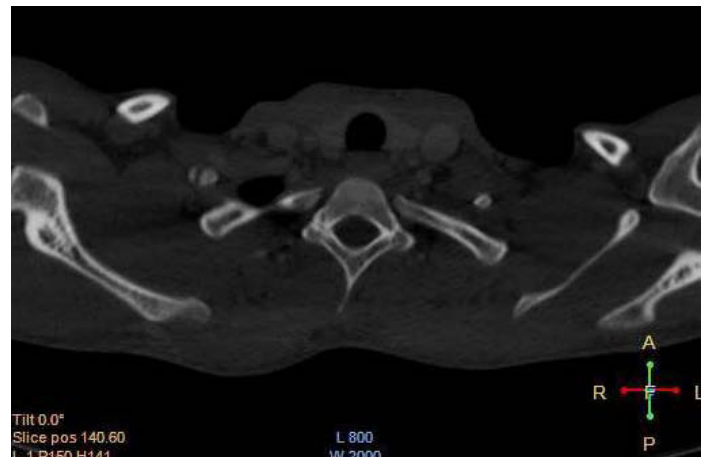
a partial cervical rib on the left side as well. However, this did not show articulation with any structure.

## DISCUSSION

Cervical ribs are fairly common anomalies with incidences of (0.05%–3.0%) based on series using radiographs [1-3]. They are generally asymptomatic or may present with thoracic outlet syndrome because of pressure on the brachial plexus nerves or vessels by the rib or a fibrous band that connects the cervical rib to the first rib [4]. Rarely, it may also cause a spurious “mass” to be palpated in the supraclavicular fossa [5]. Mahadev Dixit et al., reported a rare case of bilateral cervical ribs with pseudoarthrosis of cervical rib with first rib causing neurovascular complication in the form of total occlusion of subclavian artery [6].

This anomaly may vary from full size to just a riblet and may present as just an asymmetric and benign firm to hard neck lump. Two of the three cases studied by Jeong MS et al., also presented with Supraclavicular fossa mass [7]. Hence it is important to keep this diagnosis in mind while evaluating neck swellings.

Pseudoarthrosis is a false joint that is sometimes seen after a fracture. Pseudoarthrosis without fracture develops as an intermediate stage during the ossification process that involves two instead of one



[Table/Fig-2]: Axial CT image clearly shows pseudoarthrosis of right cervical rib with 1st right thoracic rib

ossification center [8]. Our patient had bilateral cervical ribs and an unusual pseudoarthrosis between the right cervical rib and 1<sup>st</sup> thoracic rib on the right side without any previous history of fracture. The palpable neck mass was this pseudoarthrosis with the minimal soft tissue. The mass must have been present for long but noticed by the patient only recently. In one of the previous case reports by Leong SC, who discussed a case of an asymptomatic cervical rib presenting as a hard neck lump in a 56-year-old woman which was detected incidentally, it was revealed that the patient had lost considerable weight from dieting in the past year which explained the recent detection of the cervical rib, where previously the bony protuberance would have been masked by thick cutaneous tissues [9].

Another important aspect is to recognize this entity in patients undergoing CT of the neck for other reasons since it has been reported by VG. Viertel et al., that cervical ribs go unreported 74.6% of the time in patients undergoing cervical spine CT [10].

When a cervical rib or ribs are suspected, chest radiographs may easily demonstrate the abnormality. In our case, since the diagnosis of cervical rib was not suspected clinically, radiography was not carried out. The use of ultrasound for the diagnosis ribs in children has also been described recently [11]. However three dimensional CT scan is extremely useful for the excellent anatomical depiction of this anomaly and treatment planning. The length and the attachment zone of cervical ribs and pseudoarthrosis if any, can be easily evaluated. Since three-dimensional CT images are realistic and can be rotated 360 degrees in any direction, they are valuable in individualized planning of operation.

The management of cervical ribs can be medical or surgical depending on symptom and severity. Medical management is in the form of analgesics (NSAIDs) which was chosen by our patient. Surgical management includes rib resection with scalenotomy. It is very likely that simulation, treatment planning and guidance of therapeutic or diagnostic interventions for cervical rib using 3D-CT can be routinely applied in the near future. 3D-CT images are very effective for visually identifying the relationships of the structures and planning the operation [12].

## CONCLUSION

Cervical rib with formation of pseudoarthrosis with the 1<sup>st</sup> thoracic rib causing a slightly tender supraclavicular mass is a relatively rare cause of neck swellings as in our case. Hence it is important to keep in mind the diagnosis of a cervical rib when evaluating supraclavicular neck swellings. Although radiography is diagnostic for cervical rib, the value of three dimensional CT for the evaluation of treatment planning and important neurovascular structures in the region cannot be over stressed. 3D-CT is also very useful for the imaging work up of cervical ribs and thoracic outlet syndrome.

## REFERENCES

- [1] Brewin J, Hill M, Ellis H. The prevalence of cervical ribs in a London population. *Clin Anat.* 2009;22:331-6.
- [2] Gulekon IN BC, Turgut HB. The prevalence of cervical rib in anatolian population. *Gazi Med J.* 1999;10:149-52.
- [3] Steiner HA. Roentgenologic manifestations and clinical symptoms of rib abnormalities. *Radiology.* 1943;40:175-8.
- [4] Oates SD, Daley RA. Thoracic outlet syndrome. *Hand Clin.* 1996; 12:705-718.
- [5] Adam R, Guttentag, Julia K, Salwen. Keep Your Eyes on the Ribs: The spectrum of normal variants and diseases that involve the ribs. *Radio Graphics.* 1999; 19:1125-42.
- [6] Mahadev Dixit, Mohan Gan, Narendra Nishanimath, Bhaskar Venkatakrishnaiah Bhagyalakshmi, Prashant Sajjan, Aruneshwari Dayal. Double cervical rib with uncommon presentation. *Indian J Thorac Cardiovasc Surg.* 2010;26:30-3
- [7] Jeong MS, Jung-A Mo, Ik-Jun Choi Myung-Chul Lee. Three Cases of Cervical Rib. *Korean J Otorhinolaryngol-Head Neck Surg.* 2011;54:482-5.
- [8] Hasan Riaz, Robert Zaiden. *Asymmetric Bilateral Cervical Ribs.* consultant 360.com.
- [9] Leong SC, Karkos PD. A "hard" neck lump. *Singapore Med J.* 2009; 50(4): e141-2.
- [10] VG Viertel, J Intrapromkul, F Maluf, NV Patel, W Zheng, F Alluwaimi, et al. Cervical Ribs: A common variant overlooked in ct imaging. *AJNR Am J Neuroradiol.* 2012; 10:3174/ajnr.A3143.
- [11] Vaibhav H, Mangrulkar, Harris L. Cohen, Douglas Dougherty. Sonography for diagnosis of cervical ribs in children. *J Ultrasound Med.* 2008; 27:1083-6.
- [12] Murat Akal, Ayten Kayı Cangir. Three-dimensional CT of thoracic outlet syndrome: report of three cases. *Ann Thorac Cardiovasc Surg.* 2002; 8: 45-6.

### PARTICULARS OF CONTRIBUTORS:

1. Assistant Professor, Department of Radiology, TMMC&RC, Moradabad, Uttar Pradesh, India.
2. Assistant Professor-Department of Pathology, TMMC&RC, Moradabad, Uttar Pradesh, India.

### NAME, ADDRESS, E-MAIL ID OF THE CORRESPONDING AUTHOR:

Dr. Shruti Chandak,  
OF:207, TMU campus Moradabad, Uttar Pradesh, 244001, India.  
Phone: +917500686489, E-mail: Chandakshruti@yahoo.com

FINANCIAL OR OTHER COMPETING INTERESTS: None.

Date of Submission: **Oct 23, 2013**  
Date of Peer Review: **Jan 20, 2014**  
Date of Acceptance: **Mar 12, 2014**  
Date of Publishing: **May 15, 2014**