

A histologically distinctive interstitial pneumonia induced by overexpression of the interleukin 6, transforming growth factor β 1, or platelet-derived growth factor B gene

(*in vivo* transfection/hemagglutinating virus of Japan–liposome/adenovirus vector)

MITSUHIRO YOSHIDA*[†], JUNKO SAKUMA*[†], SEIJI HAYASHI*[‡], KIN'YA ABE*, IZUMU SAITO[§], SHIZUKO HARADA[§], MITSUNORI SAKATANI[¶], SATORU YAMAMOTO[¶], NORINAO MATSUMOTO^{||}, YASUFUMI KANEDA**[†], AND TADAMITSU KISHIMOTO*

*Department of Medicine III, and ^{||}Department of Orthopedics, Osaka University Medical School, 2-2 Yamada-oka, Suita, Osaka 565, Japan; **Institute for Molecular and Cellular Biology, Osaka University, 1-3 Yamada-oka, Suita, Osaka 565, Japan; [¶]National Kinki Chuo Hospital, 1180 Nagasone Chou, Sakai, Osaka 591, Japan; and [§]Institute of Medical Science, University of Tokyo, 4-6-1 Shirogane-dai Minato-ku, Tokyo 108, Japan

Contributed by Tadamitsu Kishimoto, May 30, 1995

ABSTRACT Interstitial pneumonia is characterized by alveolitis with resulting fibrosis of the interstitium. To determine the relevance of humoral factors in the pathogenesis of interstitial pneumonia, we introduced expression vectors into Wistar rats via the trachea to locally overexpress humoral factors in the lungs. Human interleukin (IL) 6 and IL-6 receptor genes induced lymphocytic alveolitis without marked fibroblast proliferation. In contrast, overexpression of human transforming growth factor β 1 or human platelet-derived growth factor B gene induced only mild or apparent cellular infiltration in the alveoli, respectively. However, both factors induced significant proliferation of fibroblasts and deposition of collagen fibrils. These histopathologic changes induced by the transforming growth factor β 1 and platelet-derived growth factor B gene are partly akin to those changes seen in lung tissues from patients with pulmonary fibrosis and markedly contrast with the changes induced by overexpression of the IL-6 and IL-6 receptor genes that mimics lymphocytic interstitial pneumonia.

Several clinical situations, such as idiopathic pulmonary fibrosis (IPF) and pneumoconiosis, are characterized by a chronic, progressive, and sometimes fatal interstitial pneumonia (IP). IP, which is a heterogeneous group of conditions, is characterized by alveolitis, consisting of an inflammatory cellular infiltration into the alveolar septae with resulting lung fibrosis; the lung pathohistologic changes that result vary, depending on the etiology or clinical stages of the IP. Although the pathogenesis of most types of IP is not precisely understood, several investigations have reported that the expression of certain cytokines or growth factors, such as interleukin (IL) 1 (1), IL-6 (2), tumor necrosis factor α (1), IL-8 (3), platelet-derived growth factor (PDGF) (4), and transforming growth factor β (TGF- β) (5), are up-regulated in the lungs of patients with various histopathologic types of IP. These observations suggest that up-regulation of a certain cytokine is involved in organization of a certain histopathologic type of IP. However, most of these humoral factors are multifunctional and affect the expression of the others (6); consequently *ex vivo* analyses might not establish a definite cause–effect relationship between the increased expression of a humoral factor and the pathogenesis of IP. Moreover, the specific relationship between certain factors and certain histopathologic types of IP has not yet been clarified. An approach with a transgenic animal model is plausible, but systemic overexpression of TGF- β is lethal for mice (7), and very few investigators have

successfully expressed a cytokine gene specifically in the lung (24).

We consequently introduced the gene for IL-6 cytokine or the gene for TGF- β or PDGF growth factor into rats by *in vivo* transfection methods to locally overexpress the gene product in the lungs with minimal systemic effects. To elucidate the role of cytokines in the pathogenesis of IP, we then observed whether a certain cytokine induces a histopathologic change that is characteristic of the humoral factor introduced.

MATERIALS AND METHODS

Replication-Deficient Recombinant Adenovirus Vectors. Replication-deficient recombinant adenoviruses were constructed according to described methods (8); the precise construction strategy will be reported elsewhere. In these recombinant adenoviruses, named Adex1SR, regions E1 and E3 of the adenovirus genome were deleted, and a cassette containing an SR α promoter, which is composed of the simian virus 40 early promoter and the R segment of the U5 sequence of the long terminal repeat of human T-cell leukemia virus type 1 (9), followed by a simian virus 40 polyadenylation signal was inserted at the E1 deletion site. Adex1SRWL contains an empty cassette, Adex1SRlacZ encodes β -galactosidase, and Adex1SRIL-6 encodes human IL-6. Adex1SRIL-6R encodes human IL-6 receptor (IL-6R), and a significantly high titer of soluble form of IL-6R protein was detected in culture supernatant of NIH 3T3 cells into which the IL-6R gene had been introduced by this vector.

A 12-week-old, male Wistar rat weighing 240–260 g (Japan SLC, Hamamatsu, Japan) was anesthetized by i.m. injection of 15 mg of ketalar (Sankyo). The anterior midline was incised, and the trachea was punctured to instill 1.8×10^8 plaque-forming units of each vector into the lung in a total volume of 250 μ l. Ten rats were evaluated in the IL-6 and IL-6R groups, and six or seven rats were evaluated for the other three experimental groups. Three days after the instillation, the animals were killed with ether anesthesia. The lungs, expanded and fixed, were then embedded in OTC compound (Miles) and frozen at -80°C . Five micrometer thick cryostat sections were treated with 5-bromo-4-chloro-3-indolyl β -D-galactoside (X-Gal; Sigma) and then stained with hematoxylin/eosin (H/E).

Abbreviations: IL-6, interleukin 6; IL-6R, IL-6 receptor; TGF- β , transforming growth factor β ; PDGF, platelet-derived growth factor; IP, interstitial pneumonia; IPF, interstitial pulmonary fibrosis; HVJ, hemagglutinating virus of Japan; mAb, monoclonal antibody; H/E, hematoxylin/eosin.

[†]These authors contributed equally to this study.

[‡]To whom reprint requests should be addressed.

The publication costs of this article were defrayed in part by page charge payment. This article must therefore be hereby marked "advertisement" in accordance with 18 U.S.C. §1734 solely to indicate this fact.

Hemagglutinating Virus of Japan (HVJ)-Liposome. The procedure for HVJ-liposome preparation has been described (10). Briefly, 10 mg of a dried lipid mixture (phosphatidylcholine/phosphatidylserine/cholesterol) was hydrated in a balanced salt solution (BSS; 137 mM NaCl/5.4 mM KCl/10 mM Tris-HCl, pH 7.5) containing plasmid DNA and high-mobility-group 1 nuclear protein. The mixture was agitated and sonicated for preparation of unilamellar liposomes. The liposomes were then incubated with HVJ, which had been inactivated with ultraviolet irradiation, to allow fusion into an HVJ-liposome. Plasmid DNA containing $\approx 10\text{--}30\ \mu\text{g}$ of DNA for human TGF- $\beta 1$ (pAct-TGF β) or human PDGF-B (pAct-PDGF) (11) was instilled by HVJ-liposome into the lung of Wistar rats in a total volume of 250 μl . The lungs of control animals were instilled with HVJ-liposome exposed to BSS. The animals were killed 7 or 14 days after exposure to the plasmid DNA by the HVJ-liposome. At each time point, at least four animals were studied after treatment with the expression vector.

Immunohistochemical Analysis. Immunohistochemical staining was done by the avidin-biotin-peroxidase technique, using Vectastain ABC staining kits (Vector Laboratories), according to the manufacturer's method. Normal mouse serum, mouse anti-human IL-6 monoclonal antibody (mAb) (MH60) (12), mouse anti-human IL-6R mAb (MT18) (13), rabbit anti-human TGF- β serum (King Brewing Co., Kakogawa, Japan), or rabbit anti-human PDGF-B serum (Genzyme) was used as primary antibody. The latter two antisera crossreact with rat TGF- $\beta 1$ and rat PDGF-B, respectively.

Transmission Electron Microscopic Studies. For transmission electron microscopic studies, the lungs were instilled with pAct-TGF β or pAct-PDGF, fixed 2 hr at 4°C in 2.5% glutaraldehyde solution/0.1 M phosphate-buffered saline (PBS), pH 7.4, and postfixed for >12 hr at 4°C in 1% OsO₄ solution/0.1 M PBS, pH 7.4. After being washed several times in 10% sucrose solution, sections were then dehydrated through an ethanol gradient and embedded in Epon 812. Ultrathin sections were stained with uranyl acetate and lead citrate and examined with a JEM 1200EX electron microscope (JEOL).

RESULTS

Representative histologic findings 3 days after introduction of the adenovirus vectors are shown in Fig. 1. In alveolar spaces

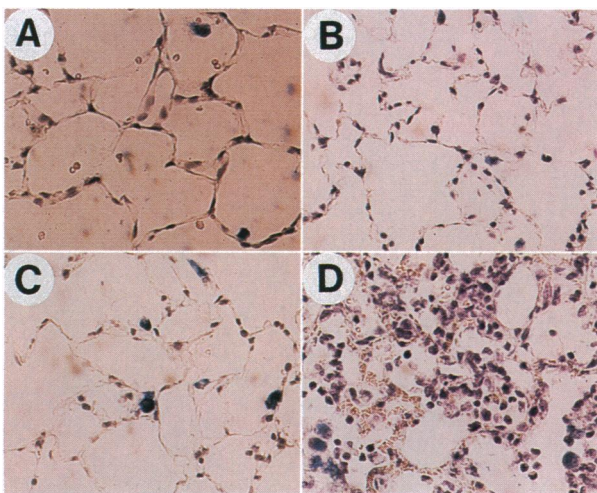


FIG. 1. Photomicrographs showing the histologic changes of lung tissue obtained from Wistar rats 3 days after introduction of IL-6 and/or IL-6R genes. (A) Lung transfected with Adex1SRWL with an empty expression cassette. (B) Lung transfected with Adex1SRIL-6 with human IL-6 gene. (C) Lung transfected with Adex1SRIL-6R with human IL-6R gene. (D) Lung transfected with both Adex1SRIL-6 and Adex1SRIL-6R. To confirm transfection, Adex1SRILacZ with β -galactosidase gene was introduced. Alveolar cells stained blue indicate lacZ activity. (H/E staining, $\times 75$.)

and septae of the lung into which an admixture of 1.8×10^8 plaque-forming units each of Adex1SRIL-6 with human IL-6 gene and Adex1SRIL-6R with human IL-6R gene (Fig. 1D) was introduced, infiltration of alveolar macrophages and mononuclear cells with chromatin-rich nuclei was observed. In lungs instilled with 1.8×10^8 plaque-forming units each of Adex1SRWL with an empty expression cassette (Fig. 1A), Adex1SRIL-6 (Fig. 1B) alone, or Adex1SRIL-6R (Fig. 1C) alone, no remarkable histopathologic changes were observed as compared with normal, untreated lungs. At least six rats were used in each of the three experimental groups, and no remarkable histologic changes were seen in any of the rats. In none of the experimental rats could we find any smudge cells or dense adenovirus inclusions characteristic of adenovirus pneumonia, and the dose of E1-deleted adenovirus vector used in this experiment is far smaller than that reported earlier (14).

Representative histologic findings of lungs 14 days after introduction of human TGF- β gene are shown in Fig. 2. In the rat lungs into which the TGF- $\beta 1$ gene was introduced, the alveolar septae were edematous, and the number of spindle-shaped cells was strikingly increased (Fig. 2B and D). Moreover, fibrotic foci were apparent adjacent to alveolar ducts (Fig. 2D). A mild infiltration of macrophages and mononuclear cells was noted in the air spaces and alveolar septae, but very few polymorphonuclear cells or eosinophils were seen. Rat lungs instilled with HVJ-liposome alone displayed minimal histopathologic changes (Fig. 2A) compared to normal, untreated rat lungs.

The histopathologic changes induced by human PDGF-B gene were also fibrosing alveolitis (Fig. 2C and E). However, proliferation of spindle-shaped cells was not so prominent as that induced by the TGF- $\beta 1$ gene, and an apparent mononuclear cell and macrophage infiltration in the alveolar septae was noted when compared with lungs instilled with the TGF- $\beta 1$ gene.

Expression of the exogenous genes in the lungs of rats in each experimental group was confirmed by immunohistochemical analyses. In the lungs instilled with Adex1SRIL-6 and Adex1SRIL-6R, alveolar macrophages, and to some extent alveolar epithelial cells, expressed human IL-6 and IL-6R protein (Fig. 3B and C, respectively). However, most infiltrating mononuclear cells in the alveolar septae did not express detectable amounts of IL-6 or IL-6R protein. In the lungs instilled with the TGF- $\beta 1$ gene, both TGF- $\beta 1$ and PDGF-B proteins were detected in alveolar macrophages and some alveolar epithelial cells within the fibrotic foci (Fig. 4B and F, respectively). Similarly, in the lungs into which the PDGF-B gene was introduced, both PDGF-B and TGF- $\beta 1$ proteins were detectable in alveolar macrophages and alveolar cells (Fig. 4E and C, respectively).

Transmission electron microscopic studies of the alveolar septae of lungs instilled with the TGF- $\beta 1$ gene showed that the proliferative cells appeared in the expanded extracellular matrix (Fig. 5). Adjacent to these cells, bundles of fibrils were seen in longitudinal and transverse sections. The cross-banded staining pattern of the fibrils was characteristic of collagen fibers (Fig. 5 Inset). In contrast to the lungs into which TGF- $\beta 1$ gene was instilled, lungs instilled with PDGF-B gene had sparse collagen-fiber structures (data not shown).

DISCUSSION

Our experiments showed that IP with its distinctive histopathologic changes was induced by cytokine genes, and the pattern of IP depended on the factor introduced. IL-6 and IL-6R induced alveolitis without marked fibrosis; however, TGF- β and PDGF-B induced fibrosis with minimal or apparent alveolitis, respectively.

In terms of proliferation of fibroblast and deposition of collagen fibrils, the lung introduced to the TGF- β or the

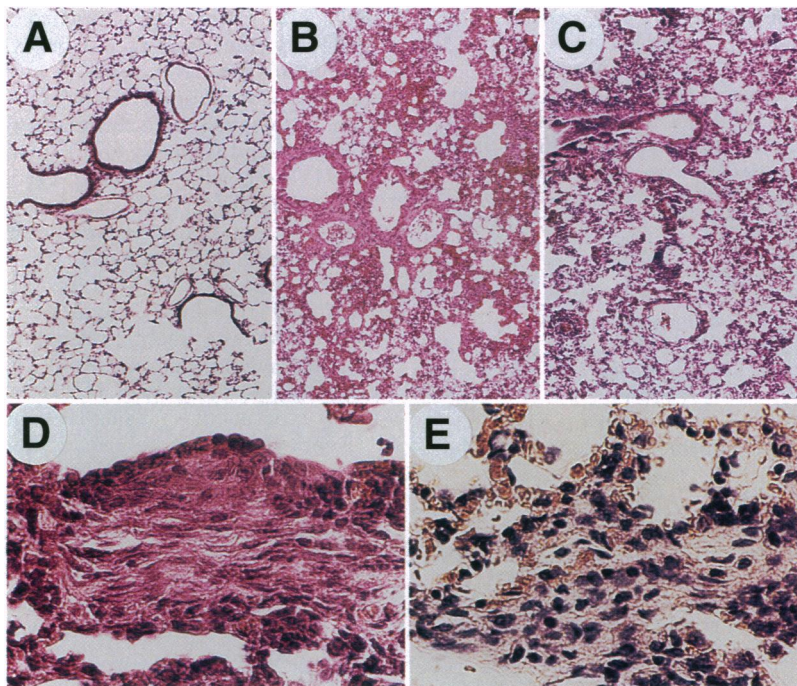


FIG. 2. Histopathologic changes seen in rat lung after introduction of TGF- β 1 or PDGF-B expression vector. Paraffin-embedded sections from lungs of animals 14 days after instillation with HVJ-liposome alone (A), pAct-TGF β (B and D), or pAct-PDGF (C and E). (H/E staining, $\times 10$ for A, B, and C; $\times 50$ for D and E.)

PDGF-B gene demonstrated, in part, histology closely akin to that of IPF. Thus, our *in vivo* investigation confirmed that the biological effects of these factors on lung interstitium, which had been previously tested in *in vitro* systems (4, 5, 15). Because deposition of collagen fibrils was seen in both groups—that is, lung introduced to each of the genes—our data strongly suggest that these two growth factors could be involved in the pathogenesis of IPF. TGF- β is a bidirectional modulator of cell replication, and at lower concentration, *in vitro* replication of fibroblasts is augmented by TGF- β itself (15) and also by PDGF induced by TGF- β (16). Moreover, TGF- β acts to increase transcription of procollagen genes (17) and induces expansion of extracellular matrix. These *in vitro* biological activities explain well the histopathologic characteristics of the lungs tested in our experiments.

In contrast, in terms of degree of infiltration of inflammatory cells, the histology of the lung treated with TGF- β or PDGF-B gene differed somewhat from that of IPF patients. Moreover, hyperplasia of type II alveolar epithelial cells, which is usually observed in the IPF lung, could not be found in either animal group (data not shown). Thus, the lungs of these experimental animals partly mimic, but do not completely reproduce, IPF histopathology. These observations suggested

as well that TGF- β is not relevant to inflammation but is possibly related to fibrosis.

Our *in vivo* analyses showed that the exogenous TGF- β gene product induced rat PDGF-B expression (Fig. 4F) and vice versa (Fig. 4C). The result was compatible with *in vitro* analyses by other workers (16, 18). These findings are not necessarily incompatible with the histopathologic difference between animals transfected with TGF- β gene and with PDGF-B gene. (i) This difference may be explicable by the difference between

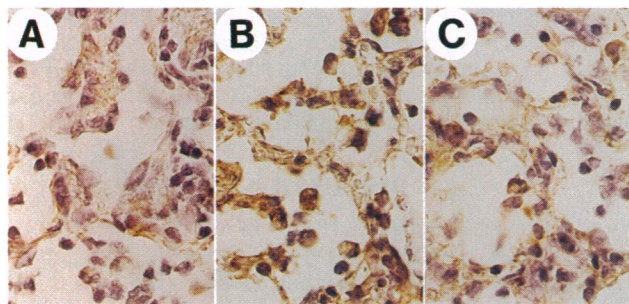


FIG. 3. Immunohistochemical-stained micrographs of rat lungs 3 days after introduction of IL-6 and IL-6R. Primary antibodies consisted of normal mouse serum (A), mouse anti-human IL-6 mAb (MH60) (B), or mouse anti-human IL-6R mAb (MT18) (C). ($\times 185$.)

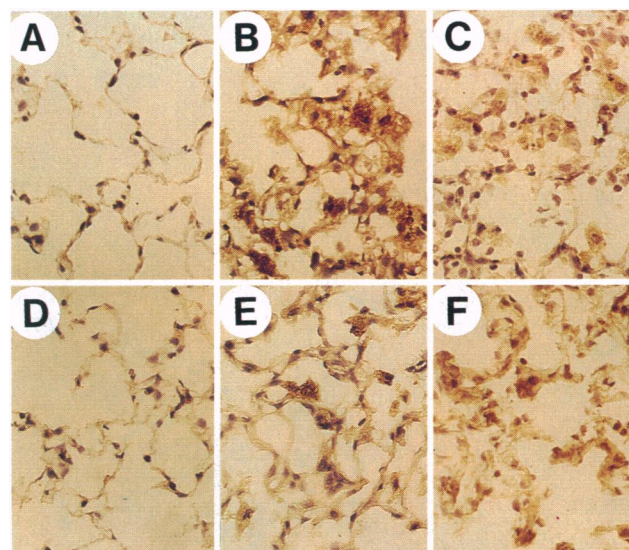


FIG. 4. Immunohistochemical-stained micrographs of rat lungs into which TGF- β 1 or PDGF-B was introduced with anti-TGF- β 1 antibody or anti-PDGF-B antibody. Frozen sections from lungs of animals obtained 7 days after instillation of HVJ-liposome alone (A and D), pAct-TGF β (B and F), and pAct-PDGF (C and E) were stained with rabbit anti-human TGF- β serum (King Brewing Co.) (A–C) or rabbit anti-human PDGF-B serum (Genzyme) (D–F). These antibodies crossreact with rat TGF- β 1 and rat PDGF-B, respectively. ($\times 45$.)

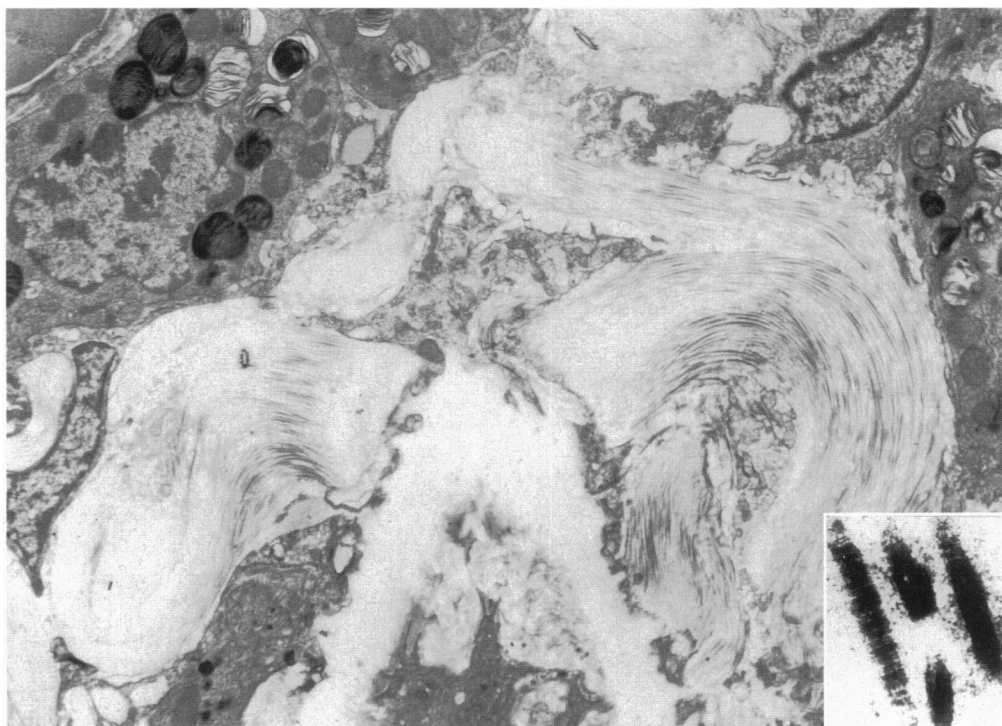


FIG. 5. Transmission electron microscopic study of the lungs 14 days after introduction with the TGF- β 1 gene. Striking expansion of extracellular matrix is seen. ($\times 2250$.) (Inset) Higher magnification of collagen fibrils seen in lung transfected with the TGF- β 1 gene. ($\times 7200$.)

the degree of expression of the host gene and that of the exogenously introduced gene, the latter of which was driven by a powerful β -actin promoter. (ii) The receptors for PDGF are reported to be down-regulated by TGF- β at its higher concentration (16). The difference in the induction of cellular infiltration between TGF- β and PDGF-B genes may partly be explained by their distinctive activities upon the immune system. TGF- β is a potent immunosuppressive agent and may repress cellular infiltration by modulating biological activity of other cytokines, but PDGF is not reported to exert such an effect. The intimate interplay of the factors, as described above, may allow a better interpretation of the histopathogenesis of IPF. One of the characteristic features of IPF is variability in histologic appearance. Both TGF- β and PDGF-B may be involved in the induction of fibrosis, and the relative variability of the expression of the factors in every focus of fibrosis may be responsible for the variability of histology in IPF.

As shown in Fig. 1, the lung transfected with IL-6 and IL-6R genes mimics lymphocytic interstitial pneumonia, a subtype of IPF, in which the radiologic and histopathologic signs of pulmonary fibrosis are usually minor (19). In the lung transfected with the genes, little fibrotic change was seen. As this histopathologic change subsided 2 weeks after the *in vivo* transfection, we repeatedly introduced these genes to accomplish long-term expression. However, marked inflammation was observed after the second introduction of the vector, even with an empty cassette (data not shown), so that we could not examine the possibility that long-term expression of IL-6 induced lung fibrosis. A transgenic mouse with systemic overexpression of both human IL-6 and IL-6R (20) showed marked lung infiltration of lymphocytes with no remarkable lung fibrosis (unpublished observation). This observation and our present result suggest that IL-6 and IL-6R are relevant to alveolitis, but these factors may not have the activity to induce marked fibrosis.

The immunohistochemical analysis indicated that IL-6R was not detectable in the normal, untreated rat lung (data not shown). However, gp130 protein, a signal transducer of IL-6

(21), was ubiquitously expressed in various tissues including lung (22), and complexes of human IL-6 and human IL-6R could bind to this rodent gp130 protein (21). We found that the cells infected with Adex1SRIL-6R shed high titers of soluble IL-6R in culture supernatant (data not shown). Thus, the complex of human IL-6 and soluble IL-6R may bind to rat gp130, which could be responsible for inducing alveolitis. Moreover, in some diseases (23), this complex behaved as if it were a cytokine, and it binds to gp130 and transduces signal.

Inciting factors in the development of IPF have not yet been clarified. Nevertheless, because the current therapeutic regimen for IPF is insufficient to prevent continued deterioration of lung tissue, the agents that suppress expression of the cytokines or neutralize their biological activities may be potential therapeutic agents.

We thank Dr. Enyu Imai (Department of Medicine I, Osaka University Medical School) for gifts of TGF- β 1 and PDGF-B expression vectors, Dr. Tetsuya Taga (Institute for Molecular and Cellular Biology, Osaka University) for cDNA of IL-6 and IL-6R, and Prof. Toyooki Akino (Department of Biochemistry I, Sapporo Medical University, Sapporo, Japan) for anti-rat surfactant protein A antibody. This work was supported by grants from the Japanese Ministry of Science, Culture and Education, the Japanese Ministry of Health and Welfare, and the Osaka Foundation for Promotion of Clinical Immunology.

1. Zhang, A., Lee, T. C., Guillemin, B., Yu, M.-C. & Rom, W. N. (1993) *J. Immunol.* **150**, 4188–4196.
2. Perkins, R. C., Scheule, R. K., Hamilton, R., Gomes, G., Freidman, G. & Holian, A. (1993) *Exp. Lung Res.* **19**, 55–65.
3. Carre, P. C., Mortenson, R. L., King, T. J., Noble, P. W., Sable, C. L. & Riches, D. W. (1991) *J. Clin. Invest.* **88**, 1802–1810.
4. Martinet, Y., Rom, W. N., Grotendorst, G. R., Martin, G. R. & Crystal, R. G. (1987) *N. Engl. J. Med.* **317**, 202–209.
5. Broekelmann, T. J., Limper, A. H., Colby, T. V. & McDonald, J. A. (1991) *Proc. Natl. Acad. Sci. USA* **88**, 6642–6646.
6. Kelley, J. (1990) *Am. Rev. Respir. Dis.* **141**, 765–788.
7. Sellheyer, K., Bickenbach, J. R., Rothnagel, J. A., Bundman, D., Longley, M. A., Krieg, T., Roche, N. S., Roberts, A. B. & Roop, D. R. (1993) *Proc. Natl. Acad. Sci. USA* **90**, 5237–5241.

8. Saito, I., Oya, Y., Yamamoto, K., Yuasa, T. & Shimojo, H. (1985) *J. Virol.* **54**, 711–719.
9. Takebe, Y., Seiki, M., Fujisawa, J., Hoy, P., Yokota, K., Arai, K., Yoshida, M. & Arai, N. (1988) *Mol. Cell. Biol.* **8**, 466–472.
10. Kato, K., Kaneda, Y., Sakurai, M., Nakanishi, M. & Okada, Y. (1991) *J. Biol. Chem.* **266**, 22071–22074.
11. Isaka, Y., Fujiwara, Y., Ueda, N., Kaneda, Y., Kamada, T. & Imai, E. (1994) *J. Clin. Invest.* **92**, 2597–2601.
12. Matsuda, T., Hirano, T. & Kishimoto, T. (1988) *Eur. J. Immunol.* **18**, 951–956.
13. Hirata, Y., Taga, T., Hibi, M., Nakano, N., Hirano, T. & Kishimoto, T. (1989) *J. Immunol.* **143**, 2900–2906.
14. Yang, Y., Nunes, F. A., Berencsi, K., Furth, E. E., Goenczoel, E. & Wilson, J. M. (1994) *Proc. Natl. Acad. Sci. USA* **91**, 4407–4411.
15. Fine, A. & Goldstein, R. H. (1987) *J. Biol. Chem.* **262**, 3897–3902.
16. Battegay, E. J., Raines, E. W., Seifert, R. A., Bowen-Pope, D. F. & Ross, R. (1990) *Cell* **63**, 515–524.
17. Rossi, R., Karsenty, G., Roberts, A. B., Roche, N. S., Sporn, M. B. & de Crombrughe, B. (1988) *Cell* **52**, 405–414.
18. Pierce, G. F., Mustoe, T. A., Lingelbach, J., Masakowski, V. R., Gramates, P. & Deuel, T. F. (1989) *Proc. Natl. Acad. Sci. USA* **86**, 2229–2233.
19. Strimlan, C. V., Rosenow, E. C., III, Weiland, L. H. & Brown, L. R. (1978) *Ann. Intern. Med.* **88**, 616–621.
20. Hirota, H., Yoshida, K., Kishimoto, T. & Taga, T. (1995) *Proc. Natl. Acad. Sci. USA* **92**, 4862–4866.
21. Taga, T., Hibi, M., Hirata, Y., Yamasaki, K., Yasukawa, K., Matsuda, T., Hirano, T. & Kishimoto, T. (1989) *Cell* **58**, 573–581.
22. Saito, M., Yoshida, K., Hibi, M., Taga, T. & Kishimoto, T. (1992) *J. Immunol.* **148**, 4066–4071.
23. Tamura, T., Udagawa, N., Takahashi, N., Miyaura, C., Tanaka, S., Yamada, Y., Koishihara, Y., Ohsugi, Y., Kumaki, K., Taga, T., Kishimoto, T. & Suda, T. (1993) *Proc. Natl. Acad. Sci. USA* **90**, 11924–11928.
24. Korfhagen, T. R., Swantz, R. J., Wert, S. E., McCarty, J. M., Kerlakian, C. B., Glasser, S. W. & Whisett, J. A. (1994) *J. Clin. Invest.* **93**, 1691–1699.