

CASE REPORT

Open Access

Induction of vitiligo after imiquimod treatment of condylomata acuminata

Wenfei Li^{1*}, Hongyan Xin^{1,2}, Lingzhi Ge^{1,3}, Haiyan Song^{1,4} and Wang Cao^{3,5}

Abstract

Background: Condylomata acuminata (genital warts) is the most common sexually transmitted disease, and imiquimod is the sole FDA-approved medication for combating this condition. Vitiligo associated with imiquimod treatment of condylomata acuminata is rare.

Case presentation: A 28-year-old male with condylomata acuminata of the penis presented to our clinic. After removing his condylomata acuminata, we advised him to use imiquimod 5% cream to prevent relapse. When he presented to our clinic again about 12 weeks later, he complained of vitiligo patches on his penis and scrotum. Physical examination showed vitiligo patches involving the glans penis, shaft of the penis, and scrotum, and remaining pigmented areas within the plaques of vitiligo. A skin biopsy of the dorsal surface of the penis showed a complete absence of melanocytes and melanin granules in the basal layer; the dermis was normal.

Conclusion: This is the first report of a case of imiquimod-induced vitiligo diagnosed by histopathological examination. This adverse effect should be considered when dermatologists prescribe this medication.

Keywords: Condylomata acuminata, Imiquimod, Vitiligo

Background

Condylomata acuminata (genital warts) is the most common sexually transmitted disease. It is caused by human papilloma virus (HPV) infection, which may contribute to cervical cancer [1]. The primary goals of treatment are removal of the visible warts and prevention of recurrence. The many methods in the therapy of condylomata acuminata include cryotherapy, electrodesiccation, CO₂ laser, trichloroacetic acid, podophyllin resin 10%–25%, and imiquimod 5% cream [2,3]. Among them, imiquimod is the sole FDA-approved medication for combating condylomata acuminata. It is also used to treat certain diseases of the skin such as Bowen's disease, common and plantar warts, molluscum contagiosum, herpes simplex, Paget's disease, basal cell carcinoma, and superficial squamous cell carcinoma. Although regarded as a safe drug, mild-to-moderate, local and systemic, adverse effects of imiquimod may occasionally occur [4]. Since vitiligo-like hypopigmentation associated with imiquimod treatment

of condylomata acuminata was first reported by Brown in 2005, to the best of our knowledge there have been only eight patients with either vitiligo or vitiligo-like hypopigmentation associated with imiquimod treatment of condylomata acuminata described in the literature [5-11]. The clinical features of these patients are listed in Table 1.

Here, we present an unusual case of imiquimod-induced vitiligo in a 28-year-old male, whose diagnosis was made using clinical and histopathological methods.

Case presentation

A 28-year-old Chinese male presented to our clinic with a 3-year history of condylomata acuminata of the penis. His lesions had been previously treated several times with liquid nitrogen and electrodesiccation without causing any pigmentary changes, but his problem had relapsed half a month before presentation and now he was presenting with five new warts. The patient was treated with electrodesiccation to remove his condylomata acuminata. When his wound healed 12 days later, he was advised to use imiquimod 5% cream for relapse prevention. He applied the cream for three nights weekly and washed it off in the morning. Before long, he noticed

* Correspondence: lwf888026@163.com

¹Department of Dermatology, Qianfoshan Hospital, Shandong University, 16766# Jing-Shi Road, Jinan 250014, China

Full list of author information is available at the end of the article

Table 1 Comparison of published cases of imiquimod-induced vitiligo or vitiligo-like depigmentation in English literature

Case	Author (year)	Age (year)/gender	Diagnosis	Site	Clinical presentation	Pathology	Family genetic history
1	Brown et al. 2005 [5]	25/M	Vitiligo-like hypopigmentation	Scrotum	Multiple depigmented patches on the scrotum ranging from 3 mm to 2 cm	No	No report
2	Stefanaki et al. 2006 [6]	32/M	Vitiligo	Dorsal surface of penis, scrotum, and pubic area	Vitiligo, slight repigmentation	No	Yes
3	Senel et al. 2007 [8]	32 M	Vitiligo-like depigmentation	Glans penis, shaft of penis, and scrotum	Depigmented areas	No	No
4	Al-Dujaili et al. 2007 [7]	21/M	Vitiligo	Penile shaft and scrotum	Depigmented patches	No	No report
5	Serrão et al. 2008 [9]	26/M	Vitiligo-like depigmentation	Shaft of penis	Vitiligo-like depigmentation	No	No report
6	Zhang et al. 2011 [10]	25/M	Vitiligo	Coronoid sulcus and corpus penis	Ivory-white patch nearly 4 × 2 cm	No	No report
7	Zhang et al. 2011 [10]	22/M	Vitiligo	Penis	Depigmented patches with irregular pigmented edges	No	No report
8	Wang et al. 2013 [11]	36/F	Vitiligo	Perineum and perianal	Depigmentation patches with clear demarcation lines	No	No

some irritation from erythema and excoriation in the treated areas, but he persisted in the application. After about 12 weeks of continuous use, he again presented to the clinic complaining of vitiligo-like depigmentation of the macules on his penis. He was instructed to stop using the imiquimod, but the macules in the treated areas gradually enlarged and asymptotically merged; a vitiligo-like, depigmented patch also appeared on his scrotum during the following 10 days. After 4 weeks of applying tacrolimus 0.1% ointment, the lesions became slightly repigmented, and the area of vitiligo lesions stabilized. Unfortunately, no further repigmentation occurred after 3 months of follow-up.

Laboratory examination and a skin biopsy were recommended. He and his family members had no history of vitiligo, other depigmented dermatoses, or autoimmune disorders. He denied use of any other topical treatment. Physical examination showed vitiligo patches involving the glans penis, the shaft of the penis, and the scrotum, along with some remaining pigmented areas within the vitiligo plaques (Figure 1). Wood's light accentuated the depigmented areas. He was not tired or irritable. EKG, chest X-ray, and thyroid and abdominal ultrasonic scans indicated no cardiac, pulmonary, bilateral thyroid, hepatic, splenic, nephritic, or other organ involvement.

Additional laboratory analysis revealed normal counts of white blood cells, red blood cells and blood platelets; normal elevated erythrocyte sedimentation rate; normal thyroid function tests; negative antistreptolysin O titer and rheumatoid factor; normal serum immunoglobulins G, M, and A, E levels; normal liver enzyme level; normal blood urea nitrogen and creatinine level; normal blood

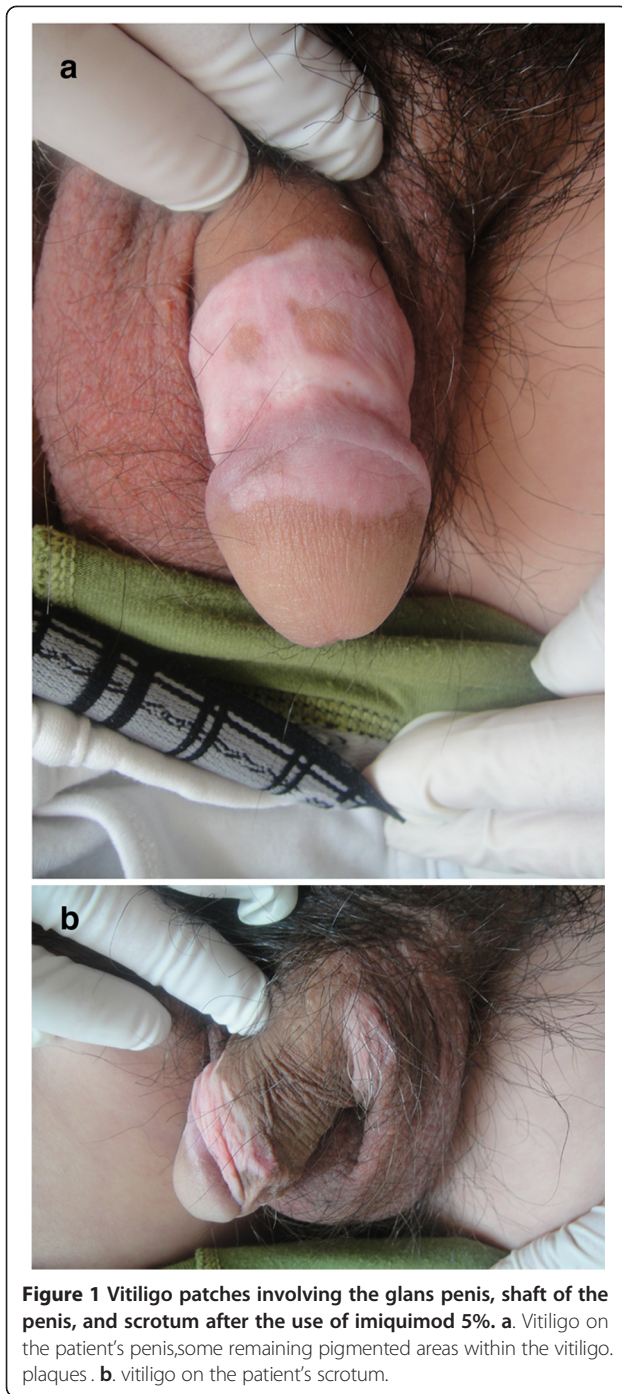
glucose level; negative antinuclear and antineutrophil cytoplasmic antibodies; negative HIV and syphilis antibodies; normal hepatitis A, B, and C serology; normal urine and stool analysis.

A skin biopsy was performed on the dorsal surface of the penis, which showed a complete absence of melanocytes and melanin granules in the basal layer but with a normal dermis (Figure 2). Loss of melanocytes and melanin granules in the epidermis was highlighted by Fontana-Masson staining (Figure 3). Melanocytes and melanin granules exist in the epidermal basal-cell layer of normal skin (Figure 4). He was diagnosed, clinically and pathologically, with imiquimod-induced localized vitiligo.

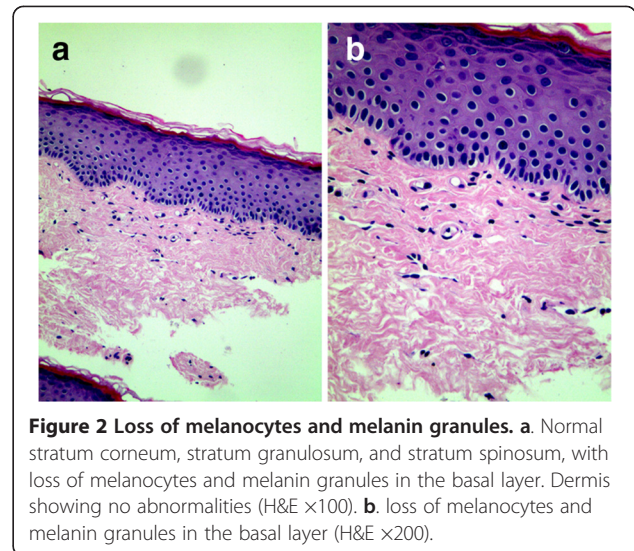
Discussion

Imiquimod is an immune response modifier with the chemical structure 1-(2-methylpropyl)-1H-imidazo[4,5-c]quinolin-4-amin. Since imiquimod was authorized on the US market in 1997 and on the Chinese market in 2003, it has been approved as a patient-applied topical treatment for condylomata acuminata in adults. We find it is a well-tolerated drug but with the frequent side effects of erythema, burning, blistering, and excoriation. We also noted its other adverse effect of inducing localized vitiligo, which occurred in the treated areas.

Vitiligo is a condition characterized by depigmentation of the skin and mucous membranes, with well-demarcated, depigmented macules and patches. The etiology of vitiligo is unknown, but research suggests that it may involve autoimmune, genetic, and other factors. Autoimmune disorders are often associated with thyroid abnormalities, pernicious anemia, systemic lupus erythematosus, and other diseases. Our patient denied any family history of vitiligo or

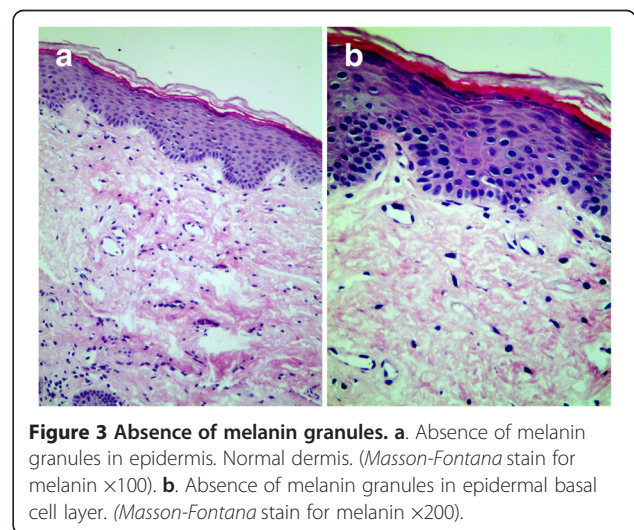


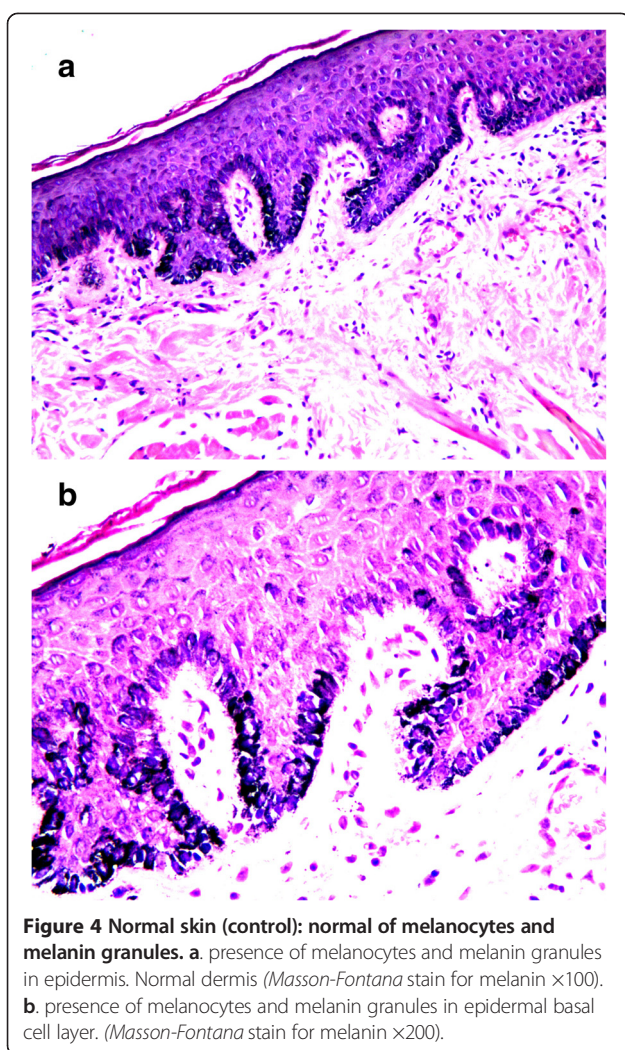
autoimmune disorder, the possibility of which was excluded by laboratory analysis. He denied use of any other topical treatments in the areas treated with imiquimod 5% cream. The features of his depigmented patches and histopathology support the diagnosis of vitiligo. Therefore, we believe that the vitiligo patches of our patient were induced by the imiquimod. We were able to obtain a small amount of superficial skin from the dorsal surface of the genital lesions in the perineal region. All eight of the patients



reported in the English literature refused biopsies of the depigmented areas, and one even refused to have the lesions photographed. Therefore, our patient is the first to undergo histopathological examination and whose diagnosis was based on clinical and histopathological findings.

The possible mechanism for the destruction of the human papilloma virus (HPV) by imiquimod is that it stimulates peripheral blood monocytes, macrophages, and dendritic cells to produce such cytokines as interferon alpha (IFN- α), interleukin-12 (IL-12), and tumor necrosis factor alpha (TNF- α), so imiquimod can enhance the host's innate and cellular immune response and combat anogenital HPV infection [12,13]. To study the safety and effectiveness of imiquimod 5% cream in the treatment of external anogenital warts, Edwards et al. applied it on 109 patients; 50% of the patients experienced eradication of all treated baseline warts [14].





Other studies also indicated that imiquimod 5% cream was effective in treating condylomata acuminata. However, imiquimod not only kills the HPV but also destroys melanocytes. Similarly, the mechanism of imiquimod-induced vitiligo may be that the medication activates the Langerhans cells in the lesions via antigen presentation, leading to the destruction and apoptosis of the melanocytes. Imiquimod-induced apoptosis of melanocytes was confirmed by TUNEL assay, Hoechst 33258 staining, and measuring mitochondrial membrane potential in melanocytes [15]. Moreover, imiquimod can induce cytokines such as IFN- α , TNF- α , IL-6, IL-8, and nitric oxide to cause vitiligo [16]. Additionally, imiquimod binds to Toll-like receptor-7 and -8, increasing production of proinflammatory cytokines such as IFN- α , TNF- α , and IL-12 [17,18], which play a role in the pathogenesis of vitiligo.

Accompanying the use of imiquimod on increasing numbers of patients with condylomata acuminata, dermatologists should keep this potential side effect in mind.

Conclusion

Imiquimod 5% cream, as an immune response modifier and a safe drug, is used to treat condylomata acuminata, basal cell carcinoma, Bowen's disease, common and planar warts, molluscum contagiosum, and other disorders. However, mild-to-moderate, local and systemic, adverse effects of imiquimod may occasionally occur. Among its adverse effects, imiquimod-induced vitiligo should be anticipated when dermatologists prescribe this drug.

Consent

Written informed consent was obtained from the patient for publication of this case report and any accompanying images. A copy of the written consent is available for review by the Editor of this journal. This study was proved by Institutional Review Board of Qianfoshan Hospital, Shandong University.

Competing interests

The authors declare that they have no potential conflicts of interest to disclose.

Authors' contributions

Study concept and design: WFL. Acquisition of data: HYL and LZG. Analysis and interpretation of data: HYS and WC. Drafting of the manuscript: HYL and LZG. Critical revision of the manuscript for important intellectual content: WFL. All authors read and approved the final manuscript.

Acknowledgments

We would like to thank Dr. Qing Sun, Dr. Ping Zhou, Dr. Wei Lu in Qianfoshan Hospital, Shandong University for helping in histological analysis. We also thank Dr. Xianmei Lu in Shandong Provincial Skin Hospital, Shandong University. This study was supported by the grant from Natural Science Foundation of Shandong (No. Y2008C160).

Author details

¹Department of Dermatology, Qianfoshan Hospital, Shandong University, 16766# Jing-Shi Road, Jinan 250014, China. ²Shandong Provincial Chest Hospital, Jinan 250013, China. ³Taishan Medical College, Tai'an 271000, China. ⁴Department of Dermatology, Jinan City Central Hospital, Jinan 250013, China. ⁵Department of Dermatology, Jinan Sixth People's Hospital, Jinan 250200, China.

Received: 12 March 2014 Accepted: 6 June 2014

Published: 13 June 2014

References

1. Castle PE, Gage JC, Partridge EE, Rausa A, Gravitt PE, Scarinci IC: Human papillomavirus genotypes detected in clinician-collected and self-collected specimens from women living in the Mississippi Delta. *BMC Infect Dis* 2013, **13**:5.
2. Shi H, Zhang X, Ma C, Yu N, Wang J, Xia L, Ge X, Liu M, Duan A: Clinical analysis of five methods used to treat condylomata acuminata. *Dermatology* 2013, **227**:338-345.
3. Chen FP: Efficacy of imiquimod 5% cream for persistent human papillomavirus in genital intraepithelial neoplasm. *Taiwan J Obstet Gynecol* 2013, **52**:475-478.
4. Rosenblatt A, de Campos Guidi HG: Local and systemic adverse effects of imiquimod therapy for external ano condyloma acuminatum in men: report of three cases. *Int J STD AIDS* 2012, **23**:909-910.
5. Brown T, Zirvi M, Cotsarelis G, Gelfand JM: Vitiligo-like hypopigmentation associated with imiquimod treatment of condyloma acuminatum. *J Am Acad Dermatol* 2005, **52**:715-716.
6. Stefanaki C, Nicolaidou E, Hadjivassiliou M, Antoniou C, Katsambas A: Imiquimod-induced vitiligo in a patient with condyloma acuminatum. *J Eur Acad Dermatol Venereol* 2006, **20**:755-756.

7. Al-Dujaili Z, Hsu S: Imiquimod-induced vitiligo. *Dermatol Online J* 2007, **13**:10.
8. Senel E, Seckin D: Imiquimod-induced vitiligo-like depigmentation. *Indian J Dermatol Venereol Leprol* 2007, **73**:423.
9. Serrão W, Páris FR, Feio AB: Genital vitiligo-like depigmentation following use of imiquimod 5% cream. *Eur J Dermatol* 2008, **18**:342–343.
10. Zhang R, Zhu W: Genital vitiligo following use of imiquimod 5% cream. *Indian J Dermatol* 2011, **56**:335–336.
11. Wang HW, Miao F, Shi L, Lü T, Huang Z, Wang XL: Imiquimod-induced localized vitiligo in wife and lichen planus in husband. *Chin Med J (Engl)* 2013, **126**:2593.
12. Schöfer H, Van Ophoven A, Henke U, Lenz T, Eul A: Randomized, comparative trial on the sustained efficacy of topical imiquimod 5% cream versus conventional ablative methods in external ano condyloma acuminatum. *Eur J Dermatol* 2006, **16**:642–648.
13. Skinner RB Jr: Imiquimod. *Dermatol Clin* 2003, **21**:291–300. Review.
14. Edwards L, Ferenczy A, Eron L, Baker D, Owens ML, Fox TL, Hougham AJ, Schmitt KA: Self-administered topical 5% imiquimod cream for external anogenital warts: HPV Study Group. *Human PapillomaVirus. Arch Dermatol* 1998, **134**:25–30.
15. Kim CH, Ahn JH, Kang SU, Hwang HS, Lee MH, Pyun JH, Kang HY: Imiquimod induces apoptosis of human melanocytes. *Arch Dermatol Res* 2010, **302**(4):301–306. doi:10.1007/s00403-009-1012-0. Epub 2009 Dec 23.
16. Ueyama A, Yamamoto M, Tsujii K, Furue Y, Imura C, Shichijo M, Yasui K: Mechanism of pathogenesis of imiquimod-induced skin inflammation in the mouse: a role for interferon-alpha in dendritic cell activation by imiquimod. *J Dermatol* 2014, **41**:135–143.
17. Schön MP, Schön M: Imiquimod: mode of action. *Br J Dermatol* 2007, **157**(Suppl 2):8–13.
18. Lacarrubba F, Nasca MR, Micali G: Advances in the use of topical imiquimod to treat dermatologic disorders. *Ther Clin Risk Manag* 2008, **4**:87–97.

doi:10.1186/1471-2334-14-329

Cite this article as: Li et al.: Induction of vitiligo after imiquimod treatment of condylomata acuminata. *BMC Infectious Diseases* 2014 **14**:329.

Submit your next manuscript to BioMed Central
and take full advantage of:

- Convenient online submission
- Thorough peer review
- No space constraints or color figure charges
- Immediate publication on acceptance
- Inclusion in PubMed, CAS, Scopus and Google Scholar
- Research which is freely available for redistribution

Submit your manuscript at
www.biomedcentral.com/submit

