



## REVIEW

# Ruptured retinal arterial macroaneurysm: Diagnosis and management

Ashley M. Speilburg\*, Stephanie A. Klemencic

Illinois College of Optometry/Illinois Eye Institute, 3241 S. Michigan Avenue, Chicago, IL 60616, United States

Received 10 May 2013; accepted 2 August 2013

Available online 26 September 2013

### KEYWORDS

Retinal arterial macroaneurysm;  
Sudden vision loss;  
Retinal hemorrhage;  
Exudation;  
Hypertension

### PALABRAS CLAVE

Macroaneurisma de la arteria retiniana;  
Pérdida súbita de visión;  
Hemorragia retiniana;  
Exudación, hipertensión

**Abstract** Retinal arterial macroaneurysm is an acquired, focal dilation of a retinal artery, typically occurring within the first three bifurcations of the central retinal artery. The clinical presentation of a retinal arterial macroaneurysm is highly variable, making initial diagnosis difficult and differentials many. Identification of retinal arterial macroaneurysms is crucial to appropriately co-manage with the primary care physician for hypertension control. Prognosis is generally good and observation is often an adequate treatment. However, in cases of macular threat or involvement, some treatment options are available and referral to a retinal specialist is indicated.

© 2013 Spanish General Council of Optometry. Published by Elsevier España, S.L. All rights reserved.

### Rotura de macroaneurisma de la arteria retiniana: diagnóstico y manejo

**Resumen** El macroaneurisma de la arteria retiniana es una dilatación focal y adquirida de una arteria retiniana, que se produce normalmente en de las primeras tres bifurcaciones de la arteria central de la retina. La presentación clínica del macroaneurisma de la arteria retiniana es altamente variable, lo que dificulta el diagnóstico inicial dadas las muchas características diferenciales. La identificación de dichos macroaneurismas es esencial para poder coordinar con el facultativo de atención primaria el control de la hipertensión. El pronóstico es generalmente bueno, siendo a menudo la observación el tratamiento adecuado. Sin embargo, en casos de amenaza o afectación macular, las opciones de tratamiento son variables, recomendándose la derivación al especialista de la retina.

© 2013 Spanish General Council of Optometry. Publicado por Elsevier España, S.L. Todos los derechos reservados.

\* Corresponding author at: Illinois College of Optometry/Illinois Eye Institute Chicago, IL, United States.  
E-mail addresses: [ascheurer@ico.edu](mailto:ascheurer@ico.edu), [ascheurer@gmail.com](mailto:ascheurer@gmail.com) (A.M. Speilburg).

## Introduction

Retinal arterial macroaneurysm (RAM) is described as an acquired, focal dilation of a retinal artery, typically occurring within the first three bifurcations of the central retinal artery.<sup>1-4</sup> RAMs can present with a wide variety of retinal findings and are often misdiagnosed at initial presentation.<sup>3</sup> Formation of a RAM is believed to result from a combined process of arteriosclerosis and hypertension. Up to 75% of patients presenting with RAM are shown to have hypertension.<sup>1,3,4</sup> Accurate identification of RAM is crucial to appropriately co-manage these patients with the primary care physician.<sup>3,4</sup> Prognosis for RAM is favorable; most undergo spontaneous resolution over a period of months.<sup>1,2,4</sup> In many instances observation is adequate management. However, in cases of macular involvement referral to a retinal specialist is often warranted as a variety of treatment options exist.<sup>3,4</sup> In this review, we aim to highlight the variable presentation of this frequently misdiagnosed condition and provide an update on current treatment options. We also include a case report of a ruptured RAM with macular involvement, co-managed between optometry and ophthalmology.

## History and epidemiology

Clinical descriptions of retinal arterial aneurysms have been reported in the literature since the late 1800s,<sup>1</sup> but in 1973 Robertson<sup>2</sup> was the first to describe the clinical characteristics and apply the term retinal arterial macroaneurysm. Retinal arterial macroaneurysms are described as an acquired, focal dilation of a retinal artery, typically occurring within the first three bifurcations of the central retinal artery.<sup>4</sup> They are commonly found at arteriovenous crossings<sup>4,6</sup> or directly at a bifurcation.<sup>5</sup> Although RAMs are usually a solitary, unilateral finding, multiple RAMs may be observed in 15–20% of cases and bilateral disease occurs in up to 10% of cases.<sup>5</sup> It is believed that less structural support of arteries exist at arteriovenous crossings due to the absence of the adventitial layer, making these areas more prone to aneurysm formation.<sup>6</sup> Two types of RAM are described in the literature, fusiform (cuffed) and saccular (blowout).<sup>7</sup> Fusiform RAMs are described as a uniform widening of the retinal artery while saccular RAMs are described as a localized outpouching of the arterial wall.<sup>8</sup>

RAMs are most commonly observed in elderly females, with most studies reporting an age range from 66 to 74 years old, and a female preponderance of about 70%.<sup>3,6,8-11</sup> Hypertension is the most common systemic condition associated with RAM; approximately 75% of presenting patients have hypertension.<sup>1,6,11</sup> Other associated conditions include arteriosclerosis and abnormal lipid levels.<sup>3</sup>

## Pathophysiology

The pathophysiology behind the formation of RAMs is not fully understood. RAMs result from a focal weakness in the arterial wall, which is believed to be the combined result of aging and atherosclerosis. With aging, atrophy of the muscularis layer leads to thinning and fibrosis of the vessel wall causing decreased elasticity within the artery.<sup>1</sup> This

sequence of events creates an increased susceptibility to arterial dilation from raised hydrostatic pressure, as seen in hypertension.<sup>1,8</sup> The reason and the localization of these focal, as opposed to widespread, weaknesses develop are not entirely understood. It is suggested that these are areas where emboli have lodged or local thrombosis has occurred. Histological studies of RAMs have shown both thrombus and cholesterol crystals partially filling the macroaneurysm, lending support to these theories.<sup>1</sup>

## Clinical signs and symptoms

The clinical presentation of RAM varies greatly and is frequently described as a masquerade syndrome. A retrospective study by Lavin and colleagues in 1987<sup>6</sup> found RAMs to be misdiagnosed at a rate of 75% at first presentation and a more recent study by Moosavi et al. reported only 4 of 14 cases (28%) listing RAM as the initial diagnosis.<sup>8</sup> Patients may present with an acute or insidious loss of vision when hemorrhage or edema involves the macula or when vitreous hemorrhage is present. But often RAMs are discovered on routine ophthalmic examination, presenting without any symptoms at all.<sup>5</sup>

The clinical appearance of RAMs is also highly variable. Traditionally, we expect to see blood in multiple layers, including subretinal, intraretinal, preretinal and vitreal.<sup>4,12</sup> This is expected as arteries are high flow vessels, thus when an aneurysm ruptures, it does so under significant pressure, pushing blood into many retinal layers. Often the macroaneurysm can be seen as a rounded dilation within an artery<sup>1</sup> and spontaneous pulsations have been documented. There is some thought that spontaneous pulsation could be an indication of pending rupture, however this idea has been challenged.<sup>5</sup> Exudation may also be present, usually seen in a circinate pattern surrounding the aneurysm but may also be found in the macular region.<sup>3</sup> Macular edema can occur with or without exudation and neurosensory detachments may also be seen.<sup>5</sup>

## Differential diagnoses

Differential diagnoses of RAM vary depending on the clinical presentation of the case. The predominating feature – abnormal vessel structure, hemorrhage, or exudates, and the retinal location – is going to alter the differential diagnoses considered in each case. Submacular blood and exudation are often confused with age related macular degeneration (ARMD).<sup>5</sup> The bilateral nature of ARMD can help rule this out; however in patients who may additionally have ARMD, a fluorescein or indocyanine green angiogram can help determine a diagnosis.<sup>3,5</sup> Dense subretinal blood may be flat or elevated and mimic a malignant melanoma. In such a case, ultrasound, fluorescein angiography (FA), magnetic resonance imaging and observation can be considered to help determine a diagnosis.<sup>3</sup> Differentials for the appearance of pre-retinal hemorrhage in the macular region, such as seen in our case, include valsalva retinopathy, posterior vitreous detachment with secondary preretinal hemorrhage, proliferative diabetic retinopathy and exudative ARMD. Valsalva retinopathy presents with pre-retinal hemorrhage near the macula and may be unilateral or bilateral in nature.

There is no age, racial or sex predilection but a history of valsalva maneuver is elicited.<sup>13</sup> Posterior vitreous detachment (PVD) with pre-retinal hemorrhage could also mimic our case presentation. Symptoms will include flashes, a new, often large floater is described and a PVD is present on DFE. Proliferative diabetic retinopathy (PDR) can cause pre-retinal hemorrhage and while PDR may be asymmetric, it would be present bilaterally. There is most often a corresponding history of diabetes mellitus. Presence of vitreous hemorrhage could be confused for an acute posterior vitreous detachment, proliferative diabetic retinopathy, or retinal vein occlusion.<sup>3,5</sup> A good case history and fundus exam of the fellow eye are helpful when considering a unilateral versus bilateral disease process. When exudation dominates the clinical picture additional conditions to consider include Coat's disease, Leber's millitary aneurysms and angiomas retinae.<sup>2</sup> While similar in appearance, the epidemiology of these conditions differ. Coat's disease, Leber's and angiomas retinae typically occur in young, otherwise healthy individuals<sup>3</sup> unlike RAM, seen in the elderly female population. Specifically, Coat's disease affects young males in the first decade and the aneurysmal dilations affect veins, capillaries and arterioles. Peripheral retinal capillary hemangiomas with tortuous feeding vessels are characteristic of angiomas retinae,<sup>3</sup> unlike RAM which tend to occur in the posterior pole within the first three orders of the central retinal artery.<sup>1</sup> Additional differential may be considered depending on the unique presentation of each case.

## Diagnostic testing

Ancillary testing can help differentiate macroaneurysms from the other retinal conditions they may mimic. Fluorescein angiography can be especially useful if the RAM is obscured or involuted.<sup>4</sup> FA of fusiform RAMs shows rapid filling in early arterial phase, while saccular RAMs show minimal early filling, with full filling in the middle to late phases. Filling in the early arterial phase may be segmental in nature due to clot formation or scarring from blockage of the lumen by thrombosis or endothelial cell formation. RAM's that have "self-sealed" may show no leakage,<sup>14</sup> while others may exhibit late leakage.<sup>4</sup> FA may also reveal changes in capillaries adjacent to the RAM, including dilation, telangiectasia, and closure.<sup>14</sup>

In cases where hemorrhage blocks visualization of the aneurysm and imaging with fluorescein angiography is inconclusive, ICG may be more useful.<sup>4,14</sup> The absorption and emission peaks of ICG dye are in the near-infrared spectrum which allows better visualization through dense hemorrhage, exudates, and retinal pigment epithelial changes. RAMs show well-defined areas of hyperfluorescence with ICG angiography and ICG can pinpoint the exact location of the macroaneurysm in cases of dense hemorrhage, which may be useful in planning surgery or treatment.<sup>14</sup>

Optical coherence tomography (OCT) is beneficial to diagnose and monitor associated retinal edema from RAM and to determine the presence and extent of subretinal fluid, macular edema and hemorrhage. More recently, investigators have identified characteristics of macroaneurysms imaged with OCT and are looking at OCT for confirmation

of the diagnosis versus intravenous contrast imaging.<sup>15</sup> OCT scans directed through the macroaneurysm show an abnormal saccular expansion of the arterial vessel wall with an enlarged lumen located in the inner retinal layers. The RAM elevates the internal limiting membrane and ganglion cell layers and produces a shadowing effect of deeper retinal layers.<sup>15</sup>

A study by Lee et al. demonstrated that SD-OCT may be a useful tool for the prediction of treatment responses of RAMs by analyzing the filling pattern of lumen as early as 1 h after the laser photocoagulation. This case series found that SD-OCT of a RAM showing complete filling of the lumen with thrombus immediately after laser treatment suggests a complete obstruction of RAM and was correlated with favorable clinical outcome. The authors postulated that if SD-OCT reveals a RAM with residual fluid collection in the lumen, it could indicate a persistent blood flow in the aneurysm and incomplete treatment.<sup>16</sup> Due to the non-invasive nature of this procedure, OCT can be an effective tool for detecting RAM and monitoring the condition and its complications over time.<sup>15,16</sup> However, visualization may be limited by dense pre-retinal or vitreous hemorrhage,<sup>15</sup> as in our case where no macroaneurysm could be visualized on OCT.

## Clinical course

In the majority of patients, RAMs resolve spontaneously without significant sequelae.<sup>4,17</sup> Complications are not common, but they do occur. The most common complication is vision loss from hemorrhagic complications or chronic macular edema. Eyes with vitreous and pre-retinal hemorrhage tend to recover better visual acuity compared to eyes with macular edema and deeper retinal hemorrhaging. Submacular hemorrhage yields the poorest visual outcome.<sup>18</sup> Subretinal blood damages the photoreceptors from a combined effect of chemical toxins, outer-retinal shear forces and/or a barrier effect limiting diffusion between the photoreceptors and retinal pigment epithelium.<sup>4,18,19</sup> Permanent damage, resulting in permanent vision loss is thought to occur in as little as 2 days<sup>18</sup> and definitely within 2 weeks.<sup>4</sup> Macular holes and subretinal neovascularization have rarely been reported to occur as a result of submacular hemorrhage.<sup>20</sup> Chronic macular edema and dense long-standing exudates can also cause a permanent loss of best corrected visual acuity.<sup>4,8</sup> Additional reported complications include secondary angle closure glaucoma, serous or hemorrhagic retinal detachments and retinal vein occlusion.<sup>4,11</sup>

## Treatment and management

Treatment and management of RAMs depend on the clinical appearance and associated complications. The majority of RAMs will follow a benign course of thrombosis, fibrosis and spontaneous resolution with return to prior visual acuity.<sup>1,14,17</sup> For this reason, asymptomatic RAMs without hemorrhage or exudates can be observed every 6 months until involution.<sup>4,17</sup> In cases of ruptured RAM with hemorrhage and/or exudation, if the macula is not involved and there appears to be little threat of macular involvement, observation is adequate management, with close follow-up

at 1 month, then every 1–3 months until involution.<sup>3,14,17</sup> For symptomatic RAMs with decreased vision secondary to intraretinal, preretinal, or vitreous hemorrhage, close observation over the first 3 months is often advocated due to the high frequency of spontaneous resolution and limited sequelae from these findings.<sup>1,14</sup> Alternatively, these cases can be referred to a retinal specialist for consideration of earlier treatment.<sup>8</sup> Referral may depend on the individual patient and their visual needs. Lastly, in cases of direct macular involvement of exudation, edema, subretinal hemorrhage or sensory detachment, referral to a retinal specialist is indicated as some form of treatment is often recommended.<sup>1,14</sup>

Many treatments exist for RAM, yet no established treatment protocol has been determined. Photocoagulation may be considered, usually when edema or exudation is causing decreased visual acuity. Photocoagulation may be performed directly to the macroaneurysm with intent to speed involution and decrease leakage. Alternatively, indirect laser may be applied to the adjacent retina with aim to stop or decrease leakage progression toward the macula.<sup>17</sup> A superior method of photocoagulation has yet to be determined<sup>5</sup> but there seems to be trend toward favoring indirect.<sup>17</sup> There remains no defined criteria for the use of laser photocoagulation; there are no large, prospective trials of photocoagulation and smaller case series have yielded mixed results questioning if there is any benefit.<sup>5,21</sup> Reported complications of laser photocoagulation include arteriolar occlusion, retinal traction, increased exudation,<sup>17</sup> severe capillary drop out and subretinal scarring.<sup>21</sup> Recently, a newer method of photocoagulation, termed subthreshold laser, was reported. The goal of subthreshold laser treatment (STLT) is to decrease complications of traditional laser by reducing laser exposure and utilizing a subvisible clinical endpoint. Early data is hopeful; a pilot study of nine patients undergoing STLT for RAM complications showed cessation of leakage in all patients with improved BCVA and no evidence of arteriolar occlusion, increased retinal exudation or traction.<sup>22</sup>

Recently, intravitreal injections of anti-vascular endothelial growth factor (VEGF) have been studied as a treatment option for RAM with macular hemorrhage or secondary macular edema.<sup>23,24</sup> In a case series by Cho et al., treatment of symptomatic macular edema and or hemorrhage with intravitreal bevacizumab was compared to observation. While there was no significant difference between groups for final best corrected visual acuity and central macular thickness, the treatment group did show faster resolution of retinal hemorrhage and visual acuity than the observational group.<sup>23</sup> Pichi et al. treated symptomatic RAMs with hemorrhagic, exudative or serous macular complications with 3-monthly injections of intravitreal bevacizumab and observed 94% closure of the RAM at week 6 (after 2 injections) and 100% of patients had complete resolution of macular edema 4 weeks after the final bevacizumab injection.<sup>25</sup> The mechanism of action of anti-VEGF medication for the treatment of RAM is unclear. VEGF causes vasodilation by stimulating endothelial production of nitric oxide and is known to be related to the activation of coagulation cascades. Vasoconstriction has been reported to reduce macular edema independent of the effect of vascular permeability.<sup>23</sup> Cho et al. propose that treatment

with anti-VEGF agents may reduce edema by reducing nitric oxide and causing vasoconstriction. Further, inhibition of VEGF may alter the balance between coagulation and fibrinolysis thus facilitating the clearing of retinal hemorrhage.

Pars plana vitrectomy (PPV) may be considered in cases of non-clearing vitreous hemorrhage, usually after 3 months of observation.<sup>5,26</sup> Alternatively, PPV may be performed earlier to allow removal of pre-retinal blood when speedier visual recovery is desired and/or visualization of the macula is inhibited, thereby making the identification of additional macular pathology difficult. As discussed previously, preretinal blood typically resolves with observation alone but it may take several months.<sup>26</sup> Additionally, the presence of dense pre-retinal blood can cause epiretinal membrane formation and have toxic effects to the retinal tissue.<sup>12,26,27</sup> It was for these reasons that a prompt vitreous surgery was performed in our case. However, because visual prognosis is generally favorable with observation alone, careful consideration of the complications associated with PPV is prudent and should be weighed against the benefits.<sup>3</sup> Post-operative cataract progression is a well-documented complication of PPV, requiring a second surgical procedure with additional risks to maintain visual gain.<sup>26,27</sup> Other possible serious complications of PPV include retinal breaks, retinal detachment, active bleeding, and endophthalmitis.<sup>26,27</sup> Additionally, macular hole is a complication of PPV specifically for treatment of pre-retinal hemorrhage secondary to RAM.<sup>28</sup>

Preretinal hemorrhage may also be treated by pulsed neodymium:yttrium aluminum garnet (Nd:YAG) laser membranotomy.<sup>12,29</sup> Again, the goal in treating preretinal hemorrhages is to speed visual recovery, decrease complications of stagnant preretinal blood, and increase visualization of the retina. Nd:YAG membranotomy causes a focal disruption to the inner limiting membrane of the retina allowing the hemorrhage to dissipate into the vitreous for quicker absorption.<sup>5</sup> Complications include a secondary non-clearing vitreous hemorrhage that requires vitrectomy to remove, macular hole, retinal detachment<sup>29</sup> and epiretinal membrane formation.<sup>26</sup>

In cases of submacular hemorrhage pneumatic displacement or submacular surgery may be performed. Pneumatic displacement uses injected perfluorocarbon gas and downgaze positioning to displace the hemorrhage out of the macula, thereby reducing complications in the macula from the presence of subretinal blood.<sup>30</sup> This procedure has been reported with and without the use of intravitreal tissue plasminogen activator.<sup>31</sup> Ongoing Phase II clinical trials are there to establish efficacy as a treatment option for submacular hemorrhage and to determine the optimal position of gaze for max displacement.<sup>30</sup> An alternative treatment for subretinal hemorrhage is submacular surgery. This procedure includes a pars plana vitrectomy followed by surgical drainage of submacular blood via a retinotomy, fluid-air exchange and insufflation with intravitreal gas. Facedown positioning for 1 week is required.<sup>31</sup> Complications with these two procedures are the same, including cataract, retinal breaks, and retinal detachment; however some speculate complications with pneumatic displacement should occur less frequently.<sup>32</sup>

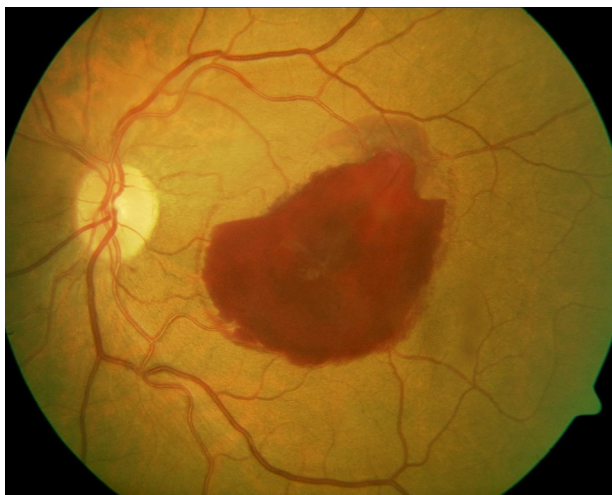


## Case example

A 74-year-old African American female presented with sudden vision loss in her left eye (OS) of 3 days duration. She described a centralized, dark circle blocking her vision. She denied flashes or pain and reported that until 4 days ago vision had been equal between her two eyes. Medical history was notable for hypertension, diagnosed 2 years ago, for which she was taking lisinopril, metoprolol and 81 mg aspirin. She reported poor compliance with these medications. Family and social history were negative.

Best corrected visual acuities were 20/25 right eye (OD) and hand motion OS. Pupils were equal, round and reactive to light without afferent pupillary defect. Ocular motility was full in both eyes (OU) and confrontation visual fields were full to finger count OD, OS. Anterior segment examination was unremarkable in each eye. Goldmann applanation tonometry readings were 14 mmHg OD, OS. Blood pressure measured 196/90 mmHg. Upon questioning, the patient denied having symptoms of elevated blood pressure, including headache, dizziness, nausea, chest pain, paresthesias and shortness of breath. She reported that she did not take her hypertension medications that day.

Dilated fundus examination OD revealed a healthy optic nerve and clear vitreous. The macular area was flat and clear, save for a single microaneurysm superior nasal to the fovea. Vasculature showed generalized attenuation of the arteries and mild tortuosity. The peripheral retina was intact 360°. Dilated fundus examination OS revealed clear vitreous and healthy optic nerve. Macular evaluation showed a large pre-retinal hemorrhage measuring approximately 3 × 2 disk diameters. Areas of intraretinal and subretinal blood were noted along the perimeter of the pre-retinal hemorrhage (Fig. 1). Vasculature was mildly tortuous and showed generalized arterial attenuation, consistent with the appearance of the right eye. Periphery was intact 360°. Due to the multilevel retinal hemorrhage, a tentative diagnosis of retinal artery macroaneurysm was made. Spectral domain optical coherence tomography (SD OCT) was taken through



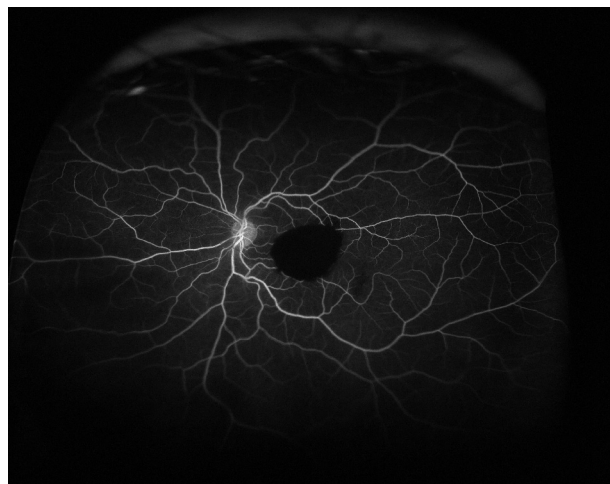**Figure 1** Left fundus at presentation. A large preretinal hemorrhage obscures visualization of the macula. Areas of intraretinal and subretinal blood are also seen.

the area of the suspected macroaneurysm, superior temporal to the fovea. It demonstrated dense pre-retinal and inner layer hyper-reflectivity with subsequent outer layer shadowing consistent with a dense pre-retinal and intraretinal hemorrhage. No macroaneurysm was visualized. The patient was educated on the importance of strict blood pressure control, referred to her primary care doctor for blood pressure management and scheduled for a retina consultation 2 days later.

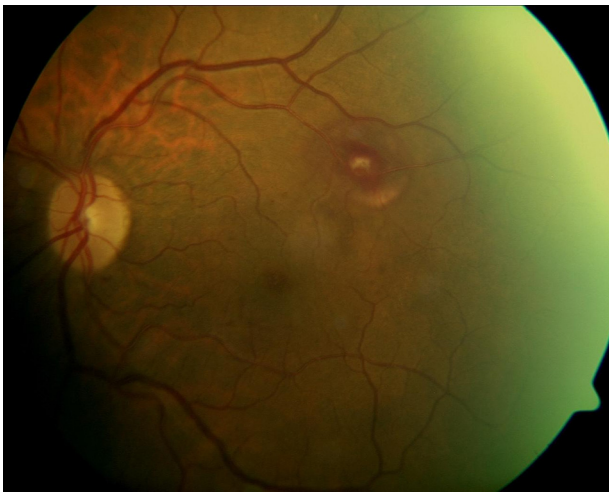Clinical presentation and acuities were unchanged at the consultation. The retinal specialist diagnosed the patient with multilevel retinal hemorrhage likely secondary to RAM. Fluorescein angiography (FA) was requested to evaluate for leakage from the presumed RAM. FA in the right eye was unremarkable except for a focal area of hyperfluorescence superior-nasal to the macular region consistent with the isolated microaneurysm seen on DFE. The left eye showed complete blockage of fluorescein in the macular region (Fig. 2). There was no leakage visible in the presumed location of the macroaneurysm, making a diagnosis of RAM inconclusive. After discussion of treatment options with the patient, including observation versus risks and benefits of surgery, a pars plana vitrectomy (PPV) procedure was elected to remove the pre-retinal blood for improved retinal visibility and to determine a definitive diagnosis.

Two weeks after PPV the patient reported a subjective improvement in her vision OS, denied any pain or irritation, and was overall pleased with her surgical outcome. Uncorrected VA measured 20/30 OD with pinhole to 20/25 and 20/40 OS without pinhole improvement. Funduscopic examination OS revealed a resolving retinal arterial macroaneurysm, located just past the third arterial bifurcation in the superior-temporal arcades (Fig. 3). Residual subretinal and intraretinal hemorrhage remained and SD OCT confirmed mild retinal edema localized to 1.5 disk diameters around the macroaneurysm, sparing the macula.

Six weeks after PPV, she noted further visual improvement OS. Uncorrected VA measured 20/30 OD and 20/25 OS. Fundus examination OS revealed a small amount of dehemoglobinized blood adjacent to the arteriole and the



**Figure 2** Fluorescein angiogram of the left eye shows blockage of fluorescein by the preretinal hemorrhage and no leakage is observed from the presumed location of the RAM.

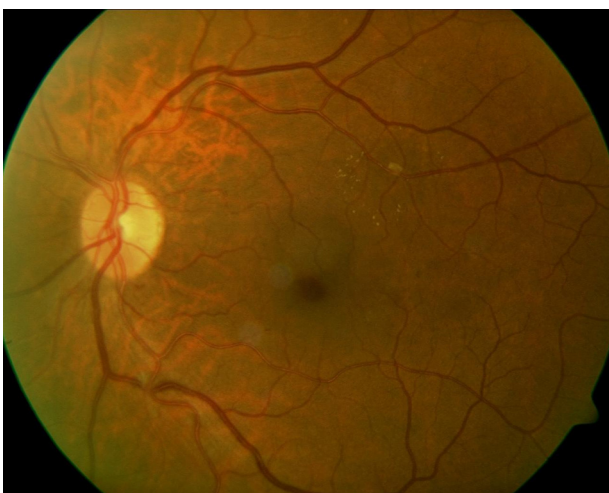


**Figure 3** Two weeks status-post pars plana vitrectomy, a resolving RAM is visible along the superior-temporal arcades surrounded by resolving sub-retinal blood.

previous areas of intraretinal and subretinal hemorrhage were replaced by a circinate pattern of exudation. A FA was ordered to re-evaluate for leakage. Evaluation of the FA revealed a z-shaped kink in the involved arteriole at the site of the macroaneurysm without active leakage.

The patient returned for follow-up 5 months status-post PPV and noted stable vision since the previous visit and denied any medical changes. Best corrected acuities measured 20/20 OD and 20/20 OS. Fundus examination OS revealed continued resolution of the RAM. Mild exudate remained in a circinate pattern with a small amount of dehemoglobinized blood adjacent to the involved arteriole (Fig. 4).

Over the course of her follow-up exams, the patient and her husband were repeatedly educated on the importance of BP control to prevent further ocular and systemic complications. The patient remained unwilling to provide the name and contact information for her primary care provider (PCP). However, she reported scheduling a



**Figure 4** Five months status-post pars plana vitrectomy, resolution of the RAM is nearly complete.

follow-up appointment with her PCP and improved compliance with her current hypertensive medications.

## Conclusion

Retinal arterial macroaneurysm may present a diagnostic dilemma as the clinical presentation varies greatly. Patients presenting with RAM need evaluation by their primary care physician for hypertension, lipid and arteriosclerosis control.<sup>3</sup> Prognosis is good and observation alone is usually adequate treatment, but in cases of macular threat treatment options are available and referral to a retinal specialist is indicated. Accurate diagnosis and co-management are crucial to save vision and help prevent life altering complications from uncontrolled hypertension.

## Conflict of interests

The authors state that they do not to have any conflicts of interest.

## References

1. Rabb M, Gagliano D, Teske M. Retinal arterial macroaneurysm. *Surv Ophthalmol.* 1988;33:73–96.
2. Robertson DM. Macroaneurysms of the retinal arteries. *Trans Am Acad Ophthalmol Otolaryngol.* 1973;77:OP 55–OP 67.
3. Adamczyk AT, Olivares GE, Petito GT. Retinal arterial macroaneurysm: a longitudinal case study. *J Am Optom Assoc.* 1989;60:840–845.
4. Holdeman NR, Le H. Retinal arterial macroaneurysm. *Clin Sur Ophthalmol.* 2010;28(10/11):238–242.
5. Bopp S. Retinal arterial macroaneurysms. In: Jousseaume AM, Gardner TW, Kirchhof B, Ryan SJ, eds. *Retinal Vascular Disease [Internet]*. New York, NY: Springer-Verlag; 2007:543–560. Available from: <http://www.springerlink.com/content/xh4171/#section=345175&page=3&locus=41> [accessed 28.2.11].
6. Lavin MJ, Marsh RJ, Peart S, Rehman A. Retinal arterial macroaneurysms: a retrospective study of 40 patients. *Br J Ophthalmol.* 1987;71:817–825.
7. Abdel-Khalk MN, Richardson J. Retinal macroaneurysm: natural history and guideline for treatment. *Br J Ophthalmol.* 1986;70:2–11.
8. Moosavi RA, Fong KC, Chopdar A. Retinal artery macroaneurysms: clinical and fluorescein angiographic features in 34 patients. *Eye.* 2006;20:1011–1020.
9. Lewis RA, Norton EWD, Gass JDM. Acquired arterial macroaneurysms of the retina. *Br J Ophthalmol.* 1976;60:21–30.
10. Contreras JE, Mitra RA, Mieler WF, Pollack JS. Retinal arterial macroaneurysms. In: Yanoff M, Duker J.S., eds. *Ophthalmology.* 2nd ed. St. Louis: Mosby; 2004:912–917.
11. Pantow RW, Goldberg MF, Farber MD. Retinal arterial macroaneurysms: risk factors and natural history. *Br J Ophthalmol.* 1990;74:595–600.
12. Gedik S, Gur S, Yilmaz G, Akova YA. Retinal arterial macroaneurysm rupture following fundus fluorescein angiography and treatment with Nd:m YAG laser membranectomy. *Ophthalmic Surg Lasers Imaging.* 2007;38:154–156.
13. Regillo CD. Distant trauma with posterior segment defects. In: Yanoff M, Duker JS, eds. *Ophthalmology.* 2nd ed. St. Louis: Mosby; 2004:1017.
14. Kester E, Walker E. Retinal arterial macroaneurysm causing multilevel hemorrhage. *Optometry.* 2009;80:425–430.

15. Goldenberg D, Soiberman U, Loewenstein A, Goldstein M. Heidelberg spectral-domain optical coherence tomographic findings in retinal artery macroaneurysm. *Retina*. 2012;32:990–995.
16. Lee EK, Woo SJ, Ahn J, Park KH. Morphologic characteristics of retinal arterial macroaneurysm and its regression pattern on spectral-domain optical coherence tomography. *Retina*. 2011;31:2095–2101.
17. Gurwood AS, Nicholson CR. Retinal arterial macroaneurysm: a case report. *J Am Optom Assoc*. 1998;69:41–48.
18. Tonotsuka T, Imai M, Saito K, Iijima H. Visual prognosis for symptomatic retinal arterial macroaneurysm. *Jpn J Ophthalmol*. 2003;47:498–502.
19. McCabe CM, Flynn HW, McLean WC, et al. Nonsurgical management of macular hemorrhage secondary to retinal arterial macroaneurysms. *Arch Ophthalmol*. 2000;118:780–785.
20. Murthy K, Puri P, Talbot J. Retinal macroaneurysm with macular hole and subretinal neovascular membrane. *Eye*. 2005;19:488–489.
21. Brown DM, Sobol WM, Folk JC, Weingeist TA. Retinal arteriolar macroaneurysms: long term visual outcome. *Br J Ophthalmol*. 1994;78:534–538.
22. Parodi MB, Iacono P, Ravalico G, Bandello F. Subthreshold laser treatment for retinal arterial macroaneurysm. *Br J Ophthalmol*. 2011;95:534–538.
23. Cho HJ, Rhee TK, Kim HS, et al. Intravitreal bevacizumab for symptomatic retinal arterial macroaneurysm. *Am J Ophthalmol*. 2013;155:898–904.
24. Tsakpinis D, Nasr MB, Tranos P, et al. The use of bevacizumab in a multilevel retinal hemorrhage secondary to retinal macroaneurysm: a 39-month follow-up case report. *Clin Ophthalmol*. 2011;5:1475–1477.
25. Pichi F, Morara M, Torrazza C, et al. Intravitreal bevacizumab for macular complications from retinal arterial macroaneurysms. *Am J Ophthalmol*. 2013;155:287–294.
26. Wu TT, Chuang CT, Sheu SJ, Chiou YH. Non-vitreotomizing vitreous surgery for premacular hemorrhage. *Acta Ophthalmol*. 2011;89:194–197.
27. McCabe FJ, Whelan JB. Vitrectomy. In: Tasman W, Jaeger EA, eds. *Duane's clinical ophthalmology [internet]*. Philadelphia: Lippincott Williams & Wilkins; 2011. Chapter 56. Available from: [http://ovidsp.tx.ovid.com/sp-3.5.1a/ovidweb.cgi?&S=EIEGFPGIBEDDPGCLNCALCEFBDMFFAA00&Link+Set=5.sh.16%7c1%7csl\\_10](http://ovidsp.tx.ovid.com/sp-3.5.1a/ovidweb.cgi?&S=EIEGFPGIBEDDPGCLNCALCEFBDMFFAA00&Link+Set=5.sh.16%7c1%7csl_10) [accessed 19.4.12].
28. Zhao P, Hayashi H, Oshima K, Nakagawa N, Ohsato M. Vitrectomy for macular hemorrhage associated with retinal arterial macroaneurysm. *Ophthalmology*. 2000;107:613–617.
29. Ulbig MW, Mangouritsas G, Rothbacher HH, Hamilton AMP, McHugh JD. Long-term results after drainage of premacular subhyaloid hemorrhage into the vitreous with a pulsed Nd:YAG laser. *Arch Ophthalmol*. 1998;116:1465–1469.
30. *Pneumatic Displacement of Subretinal Hemorrhage with Perfluorocarbon Gases [Internet]*. Bethesda, MD: National Institutes of Health (US); 2011. ClinicalTrials.gov, Available from: <http://clinicaltrials.gov/ct2/show/NCT00161525> [accessed 24.5.11].
31. Tan CS, Au Eong KG. Surgical drainage of submacular hemorrhage from ruptured retinal arterial macroaneurysm. *Acta Ophthalmol Scand*. 2005;83:240–241.
32. Wu TT, Sheu SJ. Intravitreal tissue plasminogen activator and pneumatic displacement of submacular hemorrhage secondary to retinal artery macroaneurysm. *J Ocul Pharmacol Ther*. 2005;21:62–67.