

Development of multiple myeloma in a patient with chronic hepatitis C: A case report and review of the literature

Peter Laszlo Lakatos, Sandor Fekete, Margit Horanyi, Simon Fischer, Margit E Abonyi

Peter Laszlo Lakatos, Simon Fischer, Margit E Abonyi, 1st Department of Medicine Semmelweis University, Budapest, Hungary

Sandor Fekete, Department of Hematology, Szent Laszlo Hospital, Budapest, Hungary

Margit Horanyi, Virus Laboratory, OGYK, Budapest, Hungary

Correspondence to: Peter Laszlo Lakatos, MD, PhD, 1st Department of Medicine, Semmelweis University, Koranyi str. 2/A, H-1083, Hungary. kislakpet@bel1.sote.hu

Telephone: +36-1-9117727 Fax: +36-1-3130250

Received: 2005-10-07 Accepted: 2005-11-10

Key words: HCV; Multiple myeloma; Non-Hodgkin Lymphoma; Extrahepatic manifestation

Lakatos PL, Fekete S, Horanyi M, Fischer S, Abonyi ME. Development of multiple myeloma in a patient with chronic hepatitis C: A case report and review of the literature. *World J Gastroenterol* 2006; 12(14): 2297-2300

<http://www.wjgnet.com/1007-9327/12/2297.asp>

Abstract

An association between chronic hepatitis C virus (HCV) infection and essential mixed cryoglobulinaemia and non-Hodgkin lymphoma (NHL) has been suggested. However, a causative role of HCV in these conditions has not been established. The authors report a case of a 50 year-old woman with chronic hepatitis C (CHC) who has been followed up since 1998 due to a high viral load, genotype 1b and moderately elevated liver function tests (LFTs). Laboratory data and liver biopsy revealed moderate activity (grade: 5/18, stage: 1/6). In April 1999, one-year interferon therapy was started. HCV-RNA became negative with normalization of LFTs. However, the patient relapsed during treatment. In September 2002, the patient was admitted for chronic back pain. A CT examination demonstrated degenerative changes. In March 2003, multiple myeloma was diagnosed (IgG-kappa, bone marrow biopsy: 50% plasma cell infiltration). MRI revealed a compression fracture of the 5th lumbar vertebral body and an abdominal mass in the right lower quadrant, infiltrating the canalis spinalis. Treatment with vincristine, adriamycin and dexamethasone (VAD) was started and bisphosphonate was administered regularly. In January 2004, after six cycles of VAD therapy, the multiple myeloma regressed. Thalidomide, as a second line treatment of refractory multiple myeloma (MM) was initiated, and followed by peginterferon- α 2b and ribavirin against the HCV infection in June. In June 2005, LFTs returned to normal, while HCV-RNA was negative, demonstrating an end of treatment response. Although a pathogenic role of HCV infection in malignant lymphoproliferative disorders has not been established, NHL and possibly MM may develop in CHC patients, supporting a role of a complex follow-up in these patients.

© 2006 The WJG Press. All rights reserved.

INTRODUCTION

Numerous clinical syndromes have been reported in association with hepatitis C virus (HCV) infection. Some are well established while others remain a speculation (Table 1)^[1]. Fourteen to seventy percent of patients with HCV have detectable cryoglobulins in their serum even in the absence of rash, weakness or arthralgias^[1], whereas 50-90% of patients with mixed cryoglobulinaemia are reported to have HCV infection^[2]. It is suggested that approximately 10% of type II mixed cryoglobulinaemias can evolve into malignant lymphoma several years after diagnosis.

Epidemiological studies from Europe, Japan and North America also implicate that HCV plays a role in the pathogenesis of non-Hodgkin lymphomas (NHL)^[3-7]. HCV infection is detectable in a significant proportion of NHL (14%-52%), nonetheless, it has not been confirmed^[8]. A 50-fold elevation in the risk for NHL of the liver or salivary glands has been reported in an Italian case-control study, which is greater than the relative risk of hepatocellular carcinoma. The relative risk for NHL of other sites is increased about 4-fold^[9]. An association between multiple myeloma (MM) and chronic HCV infection has been suggested by some epidemiological studies^[2,9].

CASE REPORT

The authors report a case of a 50 year-old woman with chronic HCV infection who has been followed up since 1998 due to high viral load (13.47 MEq/mL), genotype 1b and moderately elevated liver function tests (LFTs). The patient received treatment of chronic backache and tonsillectomy prior to admission to our hospital. Laboratory data and liver biopsy revealed moderate activity (grade 5/18, stage I). In April 1999, one-year interferon therapy (3x3ME/wk) was initiated. HCV-RNA became negative with normalization of the LFTs. However, the

Table 1 Extrahepatic diseases associated with hepatitis C virus infection

Association: strong	Intermediate	Weak
-Cryoglobulinemic syndrome (Cutaneous leukocytoclastic vasculitis, arthritis, weakness)	-Porphyria cutanea tarda	-Thyroid disease
-Renal disease (membranoproliferative glomerulo- nephritis)	-Diabetes	-Corneal ulcers
-Peripheral neuropathy		-Lichen planus
-Non-Hodgkin lymphoma		-Pulmonary fibrosis
-Sjögren's syndrome		

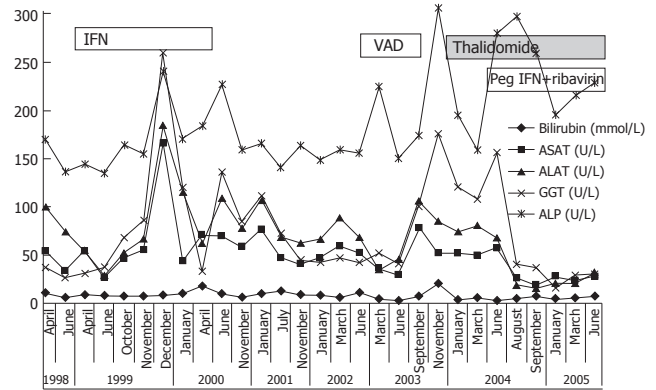


Figure 1 Liver function tests from April 1998 to July 2005.

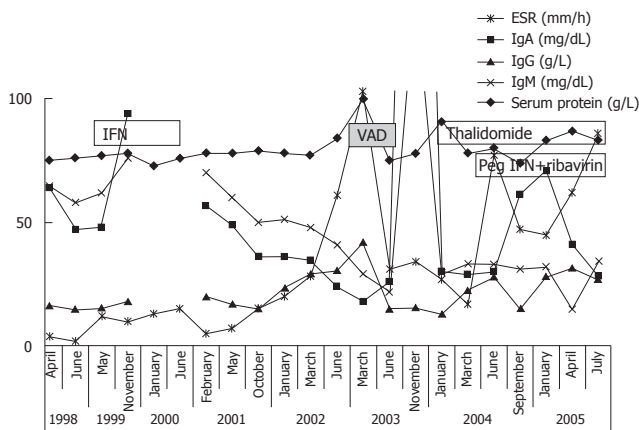


Figure 2 ESR and serum immunoglobulin levels from April 1998 to July 2005.

patient relapsed in the 7th mo of treatment (HCV-RNA became positive, LFTs increased). The liver function tests are summarized in Figure 1. In February 2000, hypothyroidism was diagnosed, substitution was initiated and follow-up was scheduled.

In September 2002, the patient was admitted for chronic backpain. CT examination revealed degenerative changes of the 5th lumbar vertebral body. Subsequently, the patient was not monitored until March 2003, when she was again hospitalized due to chronic backache and weakness of the right lower limb. Based on laboratory results, IgG- κ multiple myeloma was diagnosed (erythrocyte sedimentation rate; ESR): 104 mm/h, IgA: 0.18 g/L, IgG: 41.86 g/L, IgM: 0.29 g/L and 12.8% M-component on serum immunoelectrophoresis; bone marrow biopsy: 50% plasma cell infil). Mixed cryoglobulins were detected in the serum. Anemia, low platelet count or hypercalcaemia did not occur during follow-up. Serum IgG was elevated from 1998. However, monoclonality was not detected prior to March 2003. The serum immunoglobulin data and ESR are presented in Figure 2. MRI revealed a compression fracture of the 5th lumbar vertebral body and an abdominal mass in the right lower quadrant, infiltrating the canalis spinalis, ileum and sacroiliac joint (osteolytic lesions).

An aggressive treatment regimen was implemented with vincristine, adriamycin and dexamethasone (VAD). From April to October 2003, she received six cycles of VAD therapy followed by multiple myeloma's regression. The presence of compression fracture also prompted

the regular adminis of bisphosphonate (Aredia). In January 2004, 22.2% M-components were detected by immunoelectrophoresis, yet the ESR was normal (17mm/h). Methyl prednisolone (100 mg b.i.d) and cytoxane (100 mg o.d.) p.o. therapy was started.

In April 2004, she was admitted to the Haematological Department for paraparesis. Laminectomy (Th VII-IX) with myelin decompression and tumor resection was performed. Therapy was amended with thalidomide (100mg o.d.) orally. In August, repeated CT scans demonstrated compression fractures at L5 and S2 accompanying narrowing of the spinal canal at L5. In September, due to worsening of the paraparesis, a second laminectomy was performed (L5-S1) followed by insertion of a stabilizing prosthesis (L4-S1).

In June 2004, weekly peginterferon- α 2b (1.5 μ g/kg) and 800 mg ribavirin (daily) were prescribed (HCV PCR 145000 IU/mL, Roche TaqMan). No further dose adjustment was necessary. The LFTs became normal and PCR returned negative after three months of therapy, indicating an early viral response (EVR). In June 2005, the LFTs were normal with a negative HCV-PCR, demonstrating an end of treatment response (ETR).

DISCUSSION

In recent years, major advances have been made in the treatment of HCV infection with the sustained response rate of 52%-63% achieved^[11-13]. A major disadvantage in Hungary is that the hard-to-treat genotype 1 is almost universal (90%-95%) and occurs much more frequently compared to that in other European countries^[13,14].

Apart from hepatocellular carcinoma, HCV infection is also associated with various extrahepatic diseases, including mixed cryoglobulinaemia and NHL. Fourteen to seventy percent of patients with HCV have detectable cryoglobulins in their serum^[1,2], while 50%-90% of patients with mixed cryoglobulinaemia are reported to have HCV infection.

Epidemiological case-control studies from the 1990s suggest that chronic HCV infection is associated with the development of NHL. It was reported that 9% and 11.5% of NHL patients are HCV-antibody positive^[15,16]. Germanidis *et al*^[4] investigating 201 NHL patients found that the prevalence of HCV infection was 2-fold higher

than that in controls^[4]. More recent studies have further confirmed this finding. A Japanese study showed that 17% of patients with B-cell NHL were HCV-antibody positive compared to 6.6% of controls^[6]. Moreover, an East European study^[7] reported that 6 out of 42 (24.3%) NHL patients were HCV-antibody positive. In contrast, Rabkin *et al.*^[8] investigated the stored sera of 57 NHL patients, 24 MM patients and fourteen Hodgkin's disease patients, and found that only four patients were HCV-antibody positive.

An association between chronic HCV infection and MM was also found in epidemiological studies. Gharagozloo *et al.*^[2] showed that HCV antigens were detectable in 11% of patients with MM, 69% of patients with essential mixed cryoglobulinaemia and 4.3% of patients with NHL, using recombinant immunoblot assay (RIBA) and enzyme-linked immunosorbent assay (ELISA). Another study revealed that HCV infection was found in 32% of MM patients^[10]. The former was associated with 4.3-fold risk for MM.

The possible mechanism by which HCV infection leads to stimulation of B cells is starting to unravel. It is well documented that HCV infection, as observed in our case, usually precedes NHL by many years^[9]. Hepatitis C is lymphotropic and may replicate in lymphocytes and hepatocytes^[17]. The second portion of the HCV envelope (E2 protein) binds to CD81^[18], suggesting that this phenomenon is associated with CD19 and CR2 as well as MHC class II molecules on lymphocytes. The binding of CD81 to B cells can activate this complex, which lowers the antigen threshold necessary for antibody stimulation, thus rendering the B cell hyper-responsive. Sequencing of the antigen-binding region of immunoglobulin produced by malignant lymphocytes demonstrates that it has a high degree of homology to both antibodies specific for E2, as well as the antibodies produced by B cells that secrete RF. Furthermore, 88% of patients with HCV infection and cryoglobulinaemia demonstrate over-expression [t(14,18)translocation] of the anti-apoptotic *bcl-2* gene, compared with 8% of patients with HCV infection, 2% of patients with other liver diseases, and 3% of individuals with other rheumatoid disorders, which cause enhanced B cell survival^[19]. In addition, over-expression of NF- κ B has been reported in lymphocytes and liver samples of patients with chronic HCV infection and those with NHL^[20, 21]. This is an important finding, as NF- κ B plays a key role in virus-induced lymphomagenesis. Mutations of the NF- κ B gene are common in lymphoid malignancies^[22] and alterations of NF- κ B could initiate changes in downstream regulatory pathways. A second mutation (e.g. myc, NF- κ B) could possibly initiate the progression to lymphoma^[23].

In conclusion, although a pathogenic role of HCV infection in malignant lymphoproliferative disorders has not been established, NHL and possibly MM may develop in cases of CHC, supporting the need for a complex follow-up in these patients.

REFERENCES

- 1 **Agnello V**, De Rosa FG. Extrahepatic disease manifestations of HCV infection: some current issues. *J Hepatol* 2004; **40**: 341-352
- 2 **Gharagozloo S**, Khoshnoodi J, Shokri F. Hepatitis C virus infection in patients with essential mixed cryoglobulinemia, multiple myeloma and chronic lymphocytic leukemia. *Pathol Oncol Res* 2001; **7**: 135-139
- 3 **Agnello V**, Chung RT, Kaplan LM. A role for hepatitis C virus infection in type II cryoglobulinemia. *N Engl J Med* 1992; **327**: 1490-1495
- 4 **Germanidis G**, haïoun C, Dhumeaux D, Reyes F, Pawlotsky JM. Hepatitis C virus infection, mixed cryoglobulinemia, and B-cell non-Hodgkin's lymphoma. *Hepatology* 1999; **30**: 822-823
- 5 **Trejo O**, Ramos-Casals M, Lopez-Guillermo A, Garcia-Carrasco M, Yague J, Cervera R, Font J, Ingelmo M. Hematologic malignancies in patients with cryoglobulinemia: association with autoimmune and chronic viral diseases. *Semin Arthritis Rheum* 2003; **33**: 19-28
- 6 **Mizorogi F**, Hiramoto J, Nozato A, Takekuma Y, Nagayama K, Tanaka T, Takagi K. Hepatitis C virus infection in patients with B-cell non-Hodgkin's lymphoma. *Intern Med* 2000; **39**: 112-117
- 7 **Gasztonyi B**, Par A, Szomor A, Nagy A, Kereskai L, Losonczy H, Pajor L, Horanyi M, Mozsik G. Hepatitis C virus infection and B-cell non-Hodgkin's lymphoma. *Orv Hetil* 2000; **141**: 2649-2651
- 8 **Rabkin CS**, Tess BH, Christianson RE, Wright WE, Waters DJ, Alter HJ, Van Den Berg BJ. Prospective study of hepatitis C viral infection as a risk factor for subsequent B-cell neoplasia. *Blood* 2002; **99**: 4240-4242
- 9 **De Vita S**, Zagonel V, Russo A, Rupolo M, Cannizzaro R, Chiara G, Boiocchi M, Carbone A, Franceschi S. Hepatitis C virus, non-Hodgkin's lymphomas and hepatocellular carcinoma. *Br J Cancer* 1998; **77**: 2032-2035
- 10 **Montella M**, Crispo A, Russo F, Ronga D, Tridente V, Tamburini M. Hepatitis C virus infection and new association with extrahepatic disease: multiple myeloma. *Haematologica* 2000; **85**: 883-884
- 11 **Manns MP**, McHutchison JG, Gordon SC, Rustgi VK, Shiffman M, Reindollar R, Goodman ZD, Koury K, Ling M, Albrecht JK. Peginterferon alfa-2b plus ribavirin compared with interferon alfa-2b plus ribavirin for initial treatment of chronic hepatitis C: a randomised trial. *Lancet* 2001; **358**: 958-965
- 12 **McHutchison JG**, Manns M, Patel K, Poynard T, Lindsay KL, Trepo C, Dienstag J, Lee WM, Mak C, Garaud JJ, Albrecht JK. Adherence to combination therapy enhances sustained response in genotype-1-infected patients with chronic hepatitis C. *Gastroenterology* 2002; **123**: 1061-1069
- 13 **Abonyi ME**, Lakatos PL. Ribavirin in the treatment of hepatitis C. *Anticancer Res* 2005; **25**: 1315-1320
- 14 **Cenci M**, De Soccio G, Recchia O. Prevalence of hepatitis C virus (HCV) genotypes in central Italy. *Anticancer Res* 2003; **23**: 5129-5132
- 15 **Silvestri F**, Pipan C, Barillari G, Zaja F, Fanin R, Infanti L, Russo D, Falasca E, Botta GA, Baccharani M. Prevalence of hepatitis C virus infection in patients with lymphoproliferative disorders. *Blood* 1996; **87**: 4296-4301
- 16 **Kashyap A**, Nademanee A, Molina A. Hepatitis C and B-cell lymphoma. *Ann Intern Med* 1998; **128**: 695
- 17 **Ferri C**, Monti M, La Civita L, Longombardo G, Greco F, Passero G, Gentilini P, Bombardieri S, Zignego AL. Infection of peripheral blood mononuclear cells by hepatitis C virus in mixed cryoglobulinemia. *Blood* 1993; **82**: 3701-3704
- 18 **Pileri P**, Uematsu Y, Campagnoli S, Galli G, Falugi F, Petracca R, Weiner AJ, Houghton M, Rosa D, Grandi G, Abrignani S. Binding of hepatitis C virus to CD81. *Science* 1998; **282**: 938-941
- 19 **Zignego AL**, Giannelli F, Marrocchi ME, Mazzocca A, Ferri C, Giannini C, Monti M, Caini P, Villa GL, Laffi G, Gentilini P. T(14;18) translocation in chronic hepatitis C virus infection. *Hepatology* 2000; **31**: 474-479
- 20 **Tai DI**, Tsai SL, Chen YM, Chuang YL, Peng CY, Sheen IS, Yeh CT, Chang KS, Huang SN, Kuo GC, Liaw YF. Activation of nuclear factor kappaB in hepatitis C virus infection: implications for pathogenesis and hepatocarcinogenesis. *Hepatology* 2000; **31**: 656-664
- 21 **Gasztonyi B**, Par A, Kiss K, Kereskai L, Szomor A, Szeberenyi J, Pajor L, Mozsik G. Activation of the nuclear factor kappa B-

- key role in oncogenesis? Chronic hepatitis C virus infection and lymphomagenesis. *Orv Hetil* 2003; **144**: 863-868
- 22 **Neri A**, Fracchiolla NS, Migliazza A, Trecca D, Lombardi L. The involvement of the candidate proto-oncogene NFKB2/lyt-10 in lymphoid malignancies. *Leuk Lymphoma* 1996; **23**: 43-48
- 23 **Ellis M**, Rathaus M, Amiel A, Manor Y, Klein A, Lishner M. Monoclonal lymphocyte proliferation and bcl-2 rearrangement in essential mixed cryoglobulinaemia. *Eur J Clin Invest* 1995; **25**: 833-837

S-Editor Guo SY **L-Editor** Wang XL **E-Editor** Liu WF