

GASTRIC CANCER

Correlative studies on uPA mRNA and uPAR mRNA expression with vascular endothelial growth factor, microvessel density, progression and survival time of patients with gastric cancer

Li Zhang, Zhong-Sheng Zhao, Guo-Qing Ru, Jie Ma

Li Zhang, Department of Pathology, Wenzhou Medical College, Wenzhou 325000, Zhejiang Province, China

Zhong-Sheng Zhao, Guo-qing Ru, Jie Ma, Department of Pathology, Zhejiang Provincial Hospital, Hangzhou 310014, Zhejiang Province, China

Li Zhang, Shaoxing University Medical College, Shaoxing 312000, Zhejiang Province, China

Supported by the grant from Zhejiang Province Natural Science Foundation, No. M303843

Correspondence to: Dr. Zhong-Sheng Zhao, Department of Pathology, Zhejiang Provincial Hospital, Hangzhou 310014, Zhejiang Province, China. fyzl7618@hotmail.com

Telephone: +86-571-85893289

Received: 2006-02-15

Accepted: 2006-03-27

Abstract

AIM: To investigate the correlations between the expression of urokinase-type plasminogen activator (uPA) mRNA, uPA receptor (uPAR) mRNA and vascular endothelial growth factor (VEGF) protein and clinicopathologic features, microvessel density (MVD) and survival time.

METHODS: *In situ* hybridization and immuno-histochemistry techniques were used to study the expressions of uPA mRNA, uPAR mRNA, VEGF and CD34 protein in 105 gastric carcinoma specimens.

RESULTS: Expressions of uPA mRNA, uPAR mRNA and VEGF protein were observed in 61 (58.1%) cases, 70 (66.7%) cases and 67 (63.8%) cases, respectively. The uPA mRNA and uPAR mRNA positive expression rates in infiltrating-type cases (73.7%, 75.4%), stage III-IV (72.1%, 75.4%), vessel invasion (63.2%, 69.9%), lymphatic metastasis (67.1%, 74.4%) and distant metastasis (88.1%, 85.7%) were significantly higher than those of the expanding-type ($\chi^2 = 15.57, P = 0.001; \chi^2 = 6.91, P = 0.046$), stage I-II ($\chi^2 = 19.22, P = 0.001; \chi^2 = 16.75, P = 0.001$), non-vessel invasion ($\chi^2 = 11.92, P = 0.006; \chi^2 = 14.15, P = 0.002$), non-lymphatic metastasis ($\chi^2 = 28.41, P = 0.001; \chi^2 = 22.5, P = 0.005$) and non-distant metastasis ($\chi^2 = 12.32, P = 0.004; \chi^2 = 17.42, P = 0.002; \chi^2 = 11.25, P = 0.012; \chi^2 = 18.12, P = 0.002$). The VEGF positive expression rates in infiltrating-type cases (75.4%), stage III-IV (88.5%), vessel invasion (82.9%), lymphatic metastasis (84.3%) and distant metastasis (95.2%) were significantly higher than those of the expanding-type ($\chi^2 = 9.61, P = 0.021$),

stage I-II ($\chi^2 = 16.66, P = 0.001$), non-vessel invasion ($\chi^2 = 29.38, P = 0.001$), non-lymphatic metastasis ($\chi^2 = 18.68, P = 0.005$), and non-distant metastasis ($\chi^2 = 22.72, P = 0.007; \chi^2 = 21.62, P = 0.004$). The mean MVD in the specimens positive for the uPA mRNA, uPAR mRNA and VEGF protein was markedly higher than those with negative expression groups. Moreover, a positive relation between MVD and uPA mRNA ($rs = 0.199, P = 0.042$), uPAR mRNA ($rs = 0.278, P = 0.035$), and VEGF ($rs = 0.398, P = 0.048$) expressions was observed. The mean survival time in cases with positive uPA mRNA, uPAR mRNA and VEGF protein expression or MVD value ≥ 54.9 was significantly shorter than those in cases with negative expression or MVD value < 54.9 .

CONCLUSION: uPA and uPAR expressions are correlated with enhanced VEGF-induced tumor angiogenesis and may play a role in invasion and nodal metastasis of gastric carcinoma, thereby serving as prognostic markers of gastric cancer.

© 2006 The WJG Press. All rights reserved.

Key words: Stomach neoplasm; Urokinase-type plasminogen activator; Urokinase-type plasminogen activator receptor; Vascular endothelial growth factor; Prognosis

Zhang L, Zhao ZS, Ru GQ, Ma J. Correlative studies on uPA mRNA and uPAR mRNA expression with vascular endothelial growth factor, microvessel density, progression and survival time of patients with gastric cancer. *World J Gastroenterol* 2006; 12(25): 3970-3976

<http://www.wjgnet.com/1007-9327/12/3970.asp>

INTRODUCTION

Degradation of extracellular matrix (ECM) and basement membrane is essential for tumor invasion and metastasis. The ECM is degraded by extracellular proteolytic enzymes, such as metalloproteases and serine proteases. Plasminogen activators (PA) catalyze the conversion of the inactive pro-enzyme plasminogen to plasmin^[1]. Plasmin acts to degrade the ECM and activates latent enzyme, such as type-IV collagenase. Among the plasminogen activators, urokinase-type plasminogen activator (uPA) and uPA receptor (uPAR)

have been reported to play an important role in tumor progression. uPA activation occurs on the cell surface after binding to its specific receptor and is regulated by the number of uPAR^[2]. The relevance of uPA or uPAR in tumor progression has been demonstrated by the poor prognosis of patient with a high content of uPA or uPAR in tumor tissue.

Angiogenesis is important for tumor growth and metastasis^[3,4]. The formation of tumor microvessels is stimulated by angiogenic factors, especially vascular endothelial growth factor (VEGF). Previous studies have shown that over-expression of VEGF is correlated with the progression of human malignancies, and a significant correlation has been demonstrated between microvessel density (MVD) and VEGF expression in tumor cells^[5,6]. Recently, a role of the PA system in tumor angiogenesis has also been demonstrated^[7]. Simultaneous study of uPA, uPAR and VEGF is of practical value to reveal the mechanism and progression of gastric carcinoma. In this study, we observed the expressions of uPA, uPAR and VEGF in gastric carcinomas so as to explore the relationship of the carcinoma angiogenesis with its infiltration, metastasis and other carcinoma biological behaviors as well as prognosis.

MATERIALS AND METHODS

Patients and tumor tissues

One hundred and five gastric carcinoma samples were collected in our hospital from October 1986 to November 1998. All the samples were fixed with formaldehyde and embedded in paraffin. Complete over 5 years follow-up data were available for all these cases (follow-up ended in October 2002). Survival period was calculated from the day of operation to the end of the follow-up or to the date of death due to recurrence and metastasis. In all samples, uPA and uPAR mRNA expressions were detected using *in situ* hybridization, and VEGF and CD34 expressions were detected using immunohistochemistry. The average age of the cases was 57.6 (range 38-78) years and the male to female ratio was 2:1. According to the standard classification of WHO (1999), 17 cases had papillary adenocarcinomas, while 37, 34, 9 and 8 had the tubular adenocarcinomas, poorly differentiated adenocarcinomas, mucinous adenocarcinomas, and signet-ring cell carcinomas, respectively. Highly and intermediately differentiated carcinomas were found in 63 cases, while poorly and undifferentiated carcinomas were found in 42 cases. Forty-eight cases showed expansive growth, while 57 cases had infiltrative growth of carcinomas; and 20, 24, 32 and 29 cases had T1, T2, T3, and T4 carcinoma, respectively. Carcinomas with vascular invasion were found in 76 cases, and non-vascular invasion carcinomas in 29 cases. Seventy cases had lymph node metastasis, while 35 cases had no lymph node metastasis. Distant metastasis of carcinomas were found in 42 cases (liver metastasis: 18 cases, peritoneum metastasis: 24 cases), while no distant metastasis in 63 cases. Twenty control samples were collected from the same gastric mucosa 5 cm away from the carcinoma tissues.

Histological treatment

In order to avoid the RNase contamination, all the glass slides, slide covers and stain containers were treated with 100 g/L DEPC for 24 h. Gloves were used when handling tissue cutting and 100 g/L SDS was used to clean the cutter. All the sections were spread on glass using 100 g/L DEPC-treated ddH₂O. The tissues were cut into 5-7 μ m thickness and kept in 4°C, and foil covered for HE stain, immunohistochemistry and *in situ* hybridization.

Reagents

Digoxin-labeled oligonucleotides probes of uPA (No. MK1194) and uPAR (No. MK2117) were purchased from Boshide Biological Technology Limited Company, Wuhan, China. The sequences were 5'-CTAGGCCTGGGGAAACACAATTACTGCAGG-3' and 5'-TGTCTACACGAGGGTCTCACACTTCCTGGA-3' for uPA, and 5'-GCCTCTTGGCAGTGCATGCAGTGT-3', 5'-GAGCTGTGAGAGGGCCGGCAGCAAAGCCT-3' and 5'-ACTGCCGTGACCAATGAATCAATGTCTGG-3' for uPAR. Mouse anti-human VEGF and mouse anti-human CD34 and SP kit were purchased from Zhongshan Biotech Co., Beijing, China. The working concentrations of VEGF and CD34 were 1:100 and 1:150, respectively.

In situ hybridization

All the slides, cover-slips and other containers were autoclaved and treated with 100 g/L DEPC-treated ddH₂O for 24 h. All the buffers were also treated with 100 g/L DEPC. The tissues were routinely treated before *in situ* hybridization. DEPC (100 g/L)-treated ddH₂O was used to spread out the sections. Moderate temperature was used for drying the sections; gradient ethanol was used for dehydration with 30 mL/L H₂O₂ incubation for 10 min at room temperature. Digestion was enabled with pepsin at 37°C for 20 min, followed by washing thrice with 0.5 mol/L PBS (5 min each time). Then 20 mL hybridization solution was used for each group with probes, sealed, incubated in wet chamber for 20 h at 45°C. Then the slides were washed with 2 \times SSC for 5 min, followed by incubation with 20 mL hybridization stabilization solution (2 mL A solution, 18 mL B solution) at 45°C for 5 h in a wet chamber. Post-hybridization washing was done with 2 \times SSC-0.05 \times SSC for 2 h, and then the slides were blocked with normal serum at 37°C for 30 min. After directly adding mouse-anti-digoxin antibody for 1 h at 37°C, slides were washed thrice with 0.5 mol/L PBS (5 min each time), followed by incubation with streptavidin-biotin complex (SABC) at 37°C for 20 min and biotin-peroxidase at 37°C for 20 min. Finally, the slides were washed thrice with 0.5 mol/L PBS (5 min each time), stained with DAB for 10 min and counterstained with hematoxylin solution for 8 min. Hybridization solution and RNase-treated sample served as negative controls.

Immunohistochemistry

Consecutive 5-7 μ m paraffin-embedded tissue sections were subjected to immunostaining according to the streptavidin peroxidase (SP) methods. Briefly, the tissue

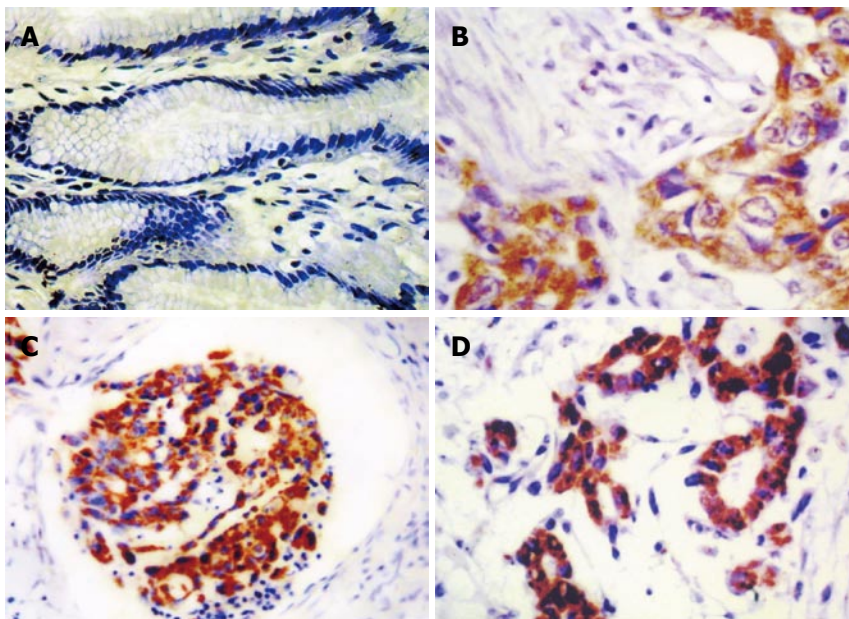


Figure 1 In situ hybridization of uPA mRNA in gastric cancer tissue. **A:** Negative in the plasma of non-tumor gastric mucosa (ISH $\times 100$); **B:** Positive in the plasma of gastric adenocarcinoma (ISH $\times 220$); **C:** Positive in plasma of gastric adenocarcinoma with lymphangial cancer embolus (ISH $\times 180$); **D:** Positive in the plasma of gastric adenocarcinoma with greater peritoneum infiltration (ISH $\times 180$).

sections were deparaffinized, and then endogenous peroxidase was blocked by incubating the slides with 30 mL/L H_2O_2 for 10 min at 37°C. After being thoroughly washed with distilled water 3 times (2 min each time), the slides were heated in the jar containing antigen retrieval solution (0.01 mol/L citrate buffer, pH 6.0) in an oven at 92-98°C for 15 min for the retrieval of the antigens and cooled to room temperature. After being washed with PBS (0.01 mol/L, pH 7.4) for 5 min, the sections were further blocked by goat serum for 20 min at 37°C to reduce nonspecific antibody binding and then incubated separately with primary antibodies (mouse anti-human VEGF or mouse anti-human CD34) at 4°C overnight. After being washed 3 times (3 min each time) in PBS, the sections were incubated with the biotin-labeled goat anti-mouse IgG at 37°C for 30 min, washed again with PBS, followed by incubation with streptavidin-peroxidase complex for 30 min at 37°C. Staining was visualized with DAB for 10 min at room temperature. Finally, the sections were counterstained by hematoxylin solution. To examine the specificity of immunostaining, PBS was used to replace the primary antibodies as the control.

Results evaluation

The cytoplasm of the uPA and uPAR mRNA appeared as brown in color. Two hundred cells were randomly chosen by microscopy to evaluate the stained cell number against the total cell number in the field. Based on the positive cell number, the criteria were set as follows: negative (-) = less than 10% positive cells or without positive staining; (+) = 11%-50% positive cells; (++) = 51%-75% positive cells; and (+++) = more than 75% positive cells. Based on the VEGF-positive cell number, the criteria were set as follows: negative (-) = no positive staining; (+) = less than 25% positive cells; (++) = 26%-50% positive cells; and (+++) = more than 50% positive cells. The MVD in the carcinoma tissue was calculated as previously described^[8]. Briefly, positive stainings for MVD, in five most highly vascularized areas ('hot spots') in each slide, were counted

in 200 \times fields and MVD was expressed as the average of the microvessel count in these areas. Any endothelial cell or endothelial cluster positive for CD34 (brown yellow staining) was considered to be a single countable microvessel. All 105 cases were divided into high MVD (MVD $\geq 54.9/\text{mm}^2$) group and low MVD (MVD $< 54.9/\text{mm}^2$) group according to the MVD mean value of 105 cases ($54.9/\text{mm}^2$)^[9].

Statistical analysis

Statistical evaluation was performed using χ^2 test or Fisher's exact test to differentiate the rates of different groups, *t*-test was used to analyze quantitative data, and rank sum correlation was analyzed with Spearman's test. The survival rate was estimated by the Kaplan-Meier method and analyzed by log-rank test. $P < 0.05$ was considered statistically significant. SPSS11.0 software for windows was employed to analyze all the data.

RESULTS

uPA mRNA, uPAR mRNA and VEGF protein expression

Twenty cases of non-cancer gastric mucosa had no uPA mRNA and uPAR mRNA expression, while positive staining for uPA and uPAR was observed mainly in cancer cells, but also in number of stromal cells including macrophages and fibroblasts. However, the number of these cells was too small to allow quantitative evaluation of the correlation with clinicopathologic factors. The rates of uPA mRNA and uPAR mRNA positive expression in cancer cells were 58.1% and 66.7%, respectively. The carcinoma cells had brown staining in the cytoplasm and invaded the muscular layer, peritoneum and greater omentum (Figure 1 and Figure 2). Moreover, the front of carcinoma infiltration areas, lymphangial cancer embolus had positive uPA mRNA and/or uPAR mRNA expression (Figure 1 and Figure 2). The positive relationships of each factor with the clinicopathologic parameters are shown in Table 1.

No correlation was found between uPA mRNA and/or

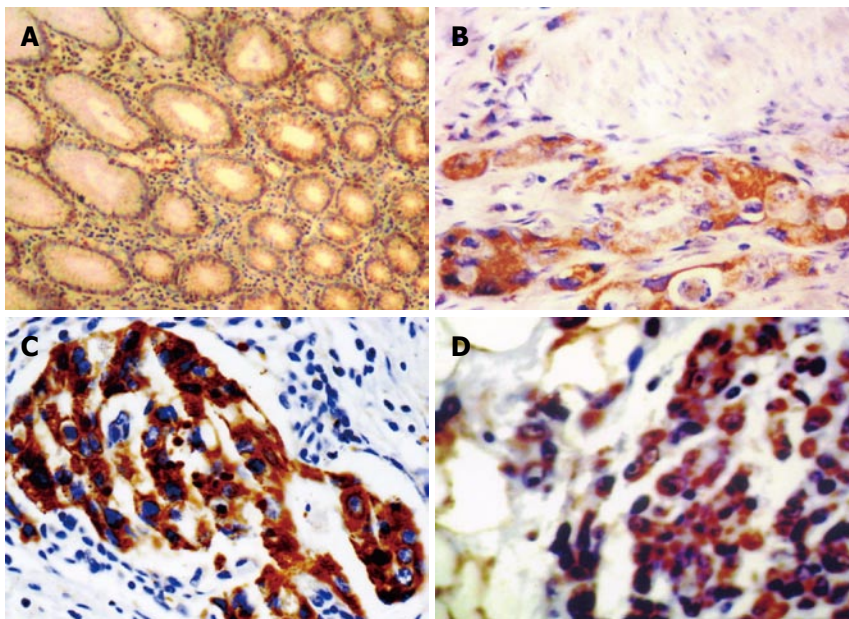


Figure 2 *In situ* hybridization of uPAR mRNA in gastric cancer tissue. **A:** Negative in the plasma of non-tumor gastric mucosa (ISH × 100); **B:** Positive in the plasma of gastric adenocarcinoma infiltrated to muscularis (ISH × 180); **C:** Positive in plasma of gastric adenocarcinoma with lymphangial cancer embolus (ISH × 240); **D:** Positive in the plasma of gastric adenocarcinoma with greater peritoneum infiltration (ISH × 120).

Table 1 Correlation of uPA mRNA, uPAR mRNA and VEGF expression and clinicopathologic parameters in gastric cancer

Clinicopathologic parameters	n	uPA mRNA				uPAR mRNA				VEGF			
		-	+	++	+++	-	+	++	+++	-	+	++	+++
Growth pattern													
Expansive	48	29	8	3	8	21	8	8	11	24	6	8	10
Infiltrative	57	15	8	11	23 ^b	14	7	17	19 ^a	14	5	13	25 ^a
Invasive depth													
T1-T2	44	27	9	2	6	20	11	6	7	31	5	5	3
T3-T4	61	17	7	12	25 ^b	15	4	19	23 ^b	7	6	16	32 ^b
Vessel invasion													
Absent	29	16	8	2	3	14	8	2	5	25	3	1	0
Present	76	28	8	12	28 ^b	21	7	23	25 ^b	13	8	20	35 ^b
Lymph node metastasis													
Absent	35	21	8	3	3	17	8	2	8	27	5	1	2
Present	70	23	8	11	28	18	7	23	22	11	6	20	33 ^b
Distant metastasis													
Absent	63	39	16	1	7	29	14	8	12	36	10	10	7
Peritoneum metastasis	24	2	0	11	11 ^b	2	0	11	11 ^b	0	0	9	15 ^b
Liver metastasis	18	3	0	2	13	4	1	6	7	2	1	2	13

^aP < 0.05, ^bP < 0.01.

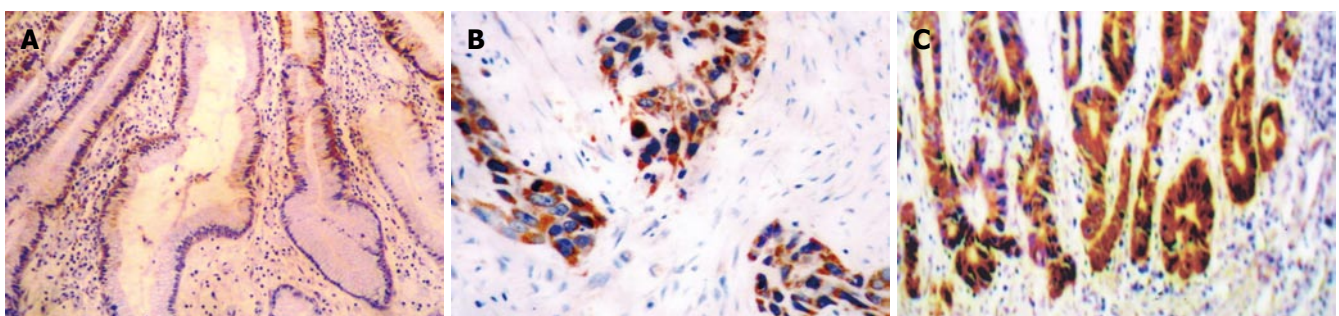


Figure 3 VEGF expression in gastric cancer tissue. **A:** Negative in the plasma of non-tumor gastric mucosa (SP×220); **B:** Positive in the plasma of gastric adenocarcinoma with greater omentum infiltration (SP × 220); **C:** Positive in plasma of gastric adenocarcinoma at the front of the cancer infiltration areas (SP × 180).

uPAR mRNA positive expression and the carcinoma types ($\chi^2 = 1.98, P = 0.78; \chi^2 = 2.82, P = 0.063$), differentiation

($\chi^2 = 2.08, P = 0.083; \chi^2 = 1.08, P = 0.82$), respectively.

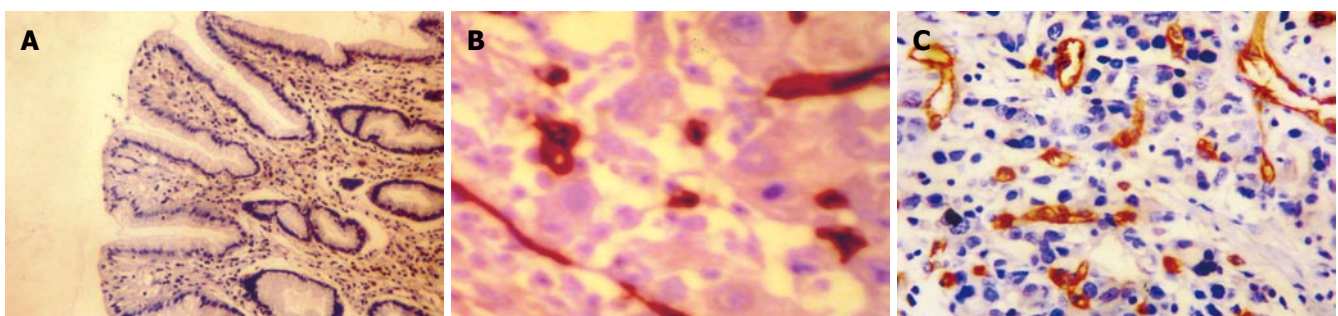
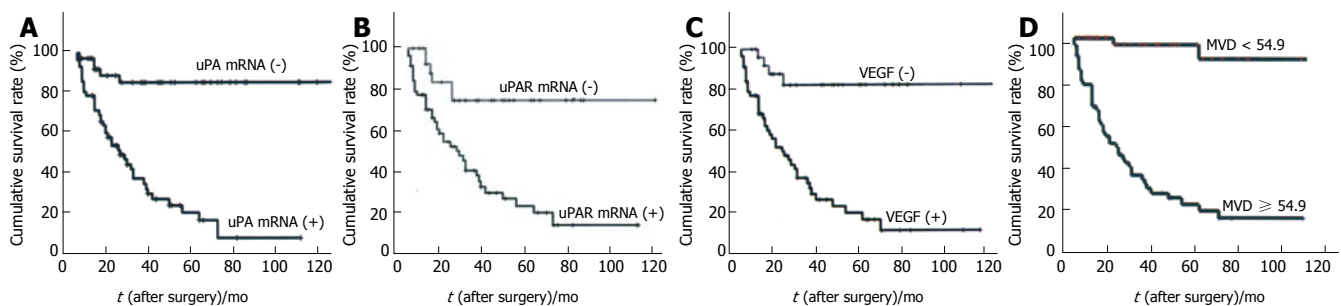
VEGF protein staining was mainly located in the

Table 2 Correlation of MVD with uPA mRNA, uPAR mRNA and VEGF expression in gastric cancer

Expression	<i>n</i>	MVD (<i>n</i> /mm ²)	<i>t</i> value	<i>P</i> value
uPA mRNA			11.25	0.005
+	61	64.89 ± 16.42		
-	44	36.69 ± 14.94		
uPAR mRNA			9.75	0.045
+	70	62.81 ± 19.93		
-	35	39.39 ± 17.29		
VEGF			12.25	0.005
+	67	65.72 ± 14.51		
-	38	35.81 ± 13.36		

Table 3 Correlation of uPA mRNA, uPAR mRNA, VEGF expression and MVD with survival time

Expression	<i>n</i>	Mean survival time (mo)	5-yr survival <i>n</i> (%)	<i>P</i> value
uPA mRNA				
-	44	115.9 ± 7.2	34 (78.9)	0.001
+	61	40.3 ± 6.7	11 (18.2)	
uPAR mRNA				
-	35	107.8 ± 8.8	26 (76.6)	0.002
+	70	49.6 ± 5.7	20 (29.0)	
VEGF protein				
-	38	123.3 ± 9.3	30 (81.0)	0.015
+	67	44.0 ± 7.6	16 (24.1)	
MVD value				
< 54.9	45	85.5 ± 6.8	35 (78.4)	0.006
≥ 54.9	60	38.7 ± 4.8	11 (18.6)	

**Figure 4** Microvessels in gastric cancer. **A:** Negative CD34 in the vascular endothelial cell of non-tumor gastric mucosa (SP × 120); **B:** Positive CD34 in the vascular endothelial cell of gastric adenocarcinoma with MVD < 54.9 (SP × 400); **C:** Positive of CD34 in the vascular endothelial cell of gastric adenocarcinoma with MVD ≥ 54.9 (SP × 120).**Figure 5** Kaplan-Meier survival curves of gastric adenocarcinoma. **A:** With or without uPA mRNA ($P < 0.05$); **B:** With or without uPAR mRNA ($P < 0.05$); **C:** With or without VEGF ($P < 0.05$); **D:** With MVD ≥ 54.9 and MVD < 54.9 ($P < 0.05$).

cytoplasm of tumor cells (Figure 3). About 63.8% gastric carcinoma showed positive expression for VEGF. The positive relationships of the expression of each factor with clinicopathologic parameters are shown in Table 1 (Figure 3). No correlation was found between VEGF protein expression and the carcinoma types ($\chi^2 = 2.21$, $P = 0.078$), differentiation ($\chi^2 = 2.14$, $P = 0.531$). In contrast, twenty cases of non-cancer gastric mucosa had no VEGF protein expression.

Correlation of MVD, uPA mRNA, uPAR mRNA, VEGF expression and survival time

The correlation between MVD, uPA mRNA, uPAR

mRNA and VEGF expression is shown in Table 2. uPA mRNA, uPAR mRNA, VEGF and MVD value within gastric tumor tissue correlated significantly with each other (uPA mRNA and VEGF: $r_s = 0.278$, $P = 0.032$, and MVD: $r_s = 0.199$, $P = 0.042$; uPAR mRNA and VEGF: $r_s = 0.308$, $P = 0.001$, and MVD: $r_s = 0.268$, $P = 0.035$; VEGF and MVD: $r_s = 0.398$, $P = 0.048$; uPA mRNA and uPAR mRNA: $r_s = 0.369$, $P = 0.005$).

The correlation of uPA mRNA, uPAR mRNA expression and MVD value, and survival time were in Table 3 (Figure 4). The survival rate of patients with positive uPA mRNA, uPAR mRNA, VEGF expression and MVD value ≥ 54.9 was significantly lower than that of the patients without these expressions (Figure 5).

DISCUSSION

Degradation of extracellular matrix (ECM) is important in cell migration and tissue remodeling. In cancer tissue, degradation of the ECM is considered to be pro-requisite for cancer invasion and metastasis^[10]. uPA, which belongs to the family of serine proteases, activates plasminogen into plasmin which degrades several components of the ECM, such as fibronectin, laminin and collagen. uPA is released from various cells as an inactive form (pro-uPA). Pro-uPA is converted into an active form after binding to a cell-surface receptor (uPAR). Previous report showed various cell types in which ligand binding to the uPA receptor does induce intracellular phosphorylation on tyrosine^[11], proto-oncogene expression^[12], cell proliferation and cell migration^[13], promoting tumor cell infiltration and metastasis^[14].

In the present study, uPA mRNA and/or uPAR mRNA tended to express more in those patients with serosal invasion, lymph node metastasis, vessel invasion, lymphangial cancer embolus, advanced stage of diseases, and distant metastasis. The results indicated that uPA mRNA and uPAR mRNA was closely related with the clinicopathologic features that reflect the invasion and metastatic potential and prognosis. Up to now, invasion depth, lymph node metastasis or distant metastasis and TNM stage were considered to be the prognostic factors for gastric carcinomas^[15]. uPA mRNA and uPAR mRNA expression statistically related with these factors implied that the invasion and metastasis facilitated by uPA and/or uPAR might indicate prognosis of gastric carcinomas. The results showed that the cancer cells with uPA mRNA and/or uPAR mRNA expression located mainly at invasion front, lymphangial cancer embolus, and involved in gastric wall lymphatic nodule. Our study also revealed that high aggressive cancer with uPA mRNA and/or uPAR mRNA positive expression, which infiltrated muscularis and metastasized to peritoneum, as well as greater omentum, formed cancer glands in the majority. Thus, these results indicated that uPA mRNA and/or uPAR mRNA might be independent biological marker of tumor differentiation. Our data revealed the positive rates of uPA mRNA and/or uPAR mRNA expression in gastric carcinoma with vessel invasion, lymph node metastasis, liver and peritoneum metastasis were significantly higher than that without these clinicopathologic features, and also showed the obvious positive correlation between uPA mRNA and uPAR mRNA, thereby indicating that synergetic high expression of uPA and/or uPAR in tumor cells infiltration area plays a very important role in gastric cancer infiltration and metastasis. Showing that aggressive ability from infiltrating-type growth cancer was stronger than that of expanding-type cancer, our data implied that the more aggressive gastric cancer cells with uPA mRNA and/or uPAR mRNA positive expression degraded ECM strengthenly, thereby facilitating the cancer cells infiltration to the tissue depth, lymphatic and metastatic to the distant organs^[16,17]. So uPA and /or uPAR can be used as a marker of gastric carcinoma infiltration and metastasis.

Both the PA system and VEGF are key factors in

tumor angiogenesis. The PA system degrades the basement membrane and stimulates the migration and progression of endothelial cells in the early phase of angiogenesis^[18]. Beside induction of tumor angiogenesis, VEGF has several additional functions that serve to enhance tumor progression, including enhancing the permeability of tumor vessels^[19] and inhibition of apoptosis of endothelial cells^[20]. An association between the PA system and angiogenesis has been reported. VEGF has been shown to cause up-regulation of uPA and uPAR in endothelial cells. Moreover, a previous study demonstrated that the PA system and VEGF synergistically contributed to liver metastasis of colorectal cancer^[21]. VEGF promotes proliferation of endothelial cells and tube formation after degradation of the ECM by the PA system and/or MMPs^[22,23]. We observed a significant relation of VEGF with both uPA and uPAR in present study. We also observed positive expression of uPA mRNA, uPAR mRNA or VEGF protein in the tumor cells, suggesting that cancer cells with positive expression of uPA, uPAR or VEGF may play an important role in gastric cancer angiogenesis. Interestingly, stepwise analysis demonstrated that uPA mRNA, uPAR mRNA and VEGF protein expression was significantly correlated with MVD. The uPA, uPAR and VEGF produced from gastric cancer cells destroy ECM, which may promote migration of both cancer cells and endothelial cells. On the other hand, cancer cells with high invasive ability may have various malignant potentials, including VEGF production. Since we found a positive correlation between VEGF expression and both uPA mRNA and uPAR mRNA expression, it is possible that the PA system enhances VEGF-induced tumor angiogenesis, which is in agreement with Kaneko *et al.*^[24]. Recently, it has been reported that endostatin inhibits angiogenesis through the down-regulation of the PA system. Thus, the inhibition of uPA and/or uPAR activity may inhibit not only tumor invasion, but also angiogenesis in gastric cancer, and uPA and/or uPAR can be used as a marker of gastric cancer biological behavior.

Previous studies have shown that t-PA and PAI-1 levels are independently associated with survival^[25], and also proved that over-expression of uPA protein is associated with several clinicopathologic features and prognosis^[26,27]. Heiss *et al.*^[28] reported that univariate analysis revealed highly significant inverse correlations between uPA, uPAR and survival time, while multivariate analysis showed PAI-1 was an independent prognostic factor. Lee *et al.*^[29] demonstrated that uPAR level of gastric cancer tissues was correlated with advanced tumor staging and poor survival rates, suggesting that the measurement of uPAR in tumor tissues may be used to predict disease recurrence and the prognosis of gastric cancer. In the present study, survival analysis with the Kaplan-Meier method demonstrated that patients with expression of uPA mRNA and/or uPAR mRNA, VEGF protein had a significantly lower survival rate than those without these. The results suggest that PA system contributes synergistically to tumor invasion, angiogenesis of gastric cancer. uPA mRNA and/or uPA mRNA might be identified as independent prognostic factors.

REFERENCES

- 1 **Duffy MJ**, Reilly D, O'Sullivan C, O'Higgins N, Fennelly JJ, Andreasen P. Urokinase-plasminogen activator, a new and independent prognostic marker in breast cancer. *Cancer Res* 1990; **50**: 6827-6829
- 2 **Ellis V**, Behrendt N, Danø K. Plasminogen activation by receptor-bound urokinase. A kinetic study with both cell-associated and isolated receptor. *J Biol Chem* 1991; **266**: 12752-12758
- 3 **Keck PJ**, Hauser SD, Krivi G, Sanzo K, Warren T, Feder J, Connolly DT. Vascular permeability factor, an endothelial cell mitogen related to PDGF. *Science* 1989; **246**: 1309-1312
- 4 **Folkman J**. Role of angiogenesis in tumor growth and metastasis. *Semin Oncol* 2002; **29**: 15-18
- 5 **Nakata S**, Ito K, Fujimori M, Shingu K, Kajikawa S, Adachi W, Matsuyama I, Tsuchiya S, Kuwano M, Amano J. Involvement of vascular endothelial growth factor and urokinase-type plasminogen activator receptor in microvessel invasion in human colorectal cancers. *Int J Cancer* 1998; **79**: 179-186
- 6 **Yu JX**, Zhang XT, Liao YQ, Zhang QY, Chen H, Lin M, Kumar S. Relationship between expression of CD105 and growth factors in malignant tumors of gastrointestinal tract and its significance. *World J Gastroenterol* 2003; **9**: 2866-2869
- 7 **Brodsky S**, Chen J, Lee A, Akassoglou K, Norman J, Goligorsky MS. Plasmin-dependent and -independent effects of plasminogen activators and inhibitor-1 on ex vivo angiogenesis. *Am J Physiol Heart Circ Physiol* 2001; **281**: H1784-H1792
- 8 **Maeda K**, Chung YS, Ogawa Y, Takatsuka S, Kang SM, Ogawa M, Sawada T, Sowa M. Prognostic value of vascular endothelial growth factor expression in gastric carcinoma. *Cancer* 1996; **77**: 858-863
- 9 **Zhao ZS**, Ru GQ, Ma J. [mRNA expression of IGF-II and HGF in relation to microvascular density, tumor progression and prognosis of gastric carcinoma]. *Zhonghua Zhong Liu Za Zhi* 2004; **26**: 673-677
- 10 **Andreasen PA**, Egelund R, Petersen HH. The plasminogen activation system in tumor growth, invasion, and metastasis. *Cell Mol Life Sci* 2000; **57**: 25-40
- 11 **Dumler I**, Petri T, Schleuning WD. Interaction of urokinase-type plasminogenactivator (u-PA) with its cellular receptor (u-PAR) induces phosphorylation on tyrosine of a 38 kDa protein. *FEBS Lett* 1993; **322**: 37-40
- 12 **Dumler I**, Petri T, Schleuning WD. Induction of c-fos gene expression by urokinase-type plasminogen activator in human ovarian cancer cells. *FEBS Lett* 1994; **343**: 103-106
- 13 **Odekon LE**, Sato Y, Rifkin DB. Urokinase-type plasminogen activator mediates basic fibroblast growth factor-induced bovine endothelial cell migration independent of its proteolytic activity. *J Cell Physiol* 1992; **150**: 258-263
- 14 **Berney CR**, Yang JL, Fisher RJ, Russell PJ, Crowe PJ. Vascular endothelial growth factor expression is reduced in liver metastasis from colorectal cancer and correlates with urokinase-type plasminogen activator. *Anticancer Res* 1998; **18**: 973-977
- 15 **Stephens RW**, Nielsen HJ, Christensen IJ, Thorlacius-Ussing O, Sørensen S, Danø K, Brünner N. Plasma urokinase receptor levels in patients with colorectal cancer: relationship to prognosis. *J Natl Cancer Inst* 1999; **91**: 869-874
- 16 **Kawasaki K**, Hayashi Y, Wang Y, Suzuki S, Morita Y, Nakamura T, Narita K, Doe W, Itoh H, Kuroda Y. Expression of urokinase-type plasminogen activator receptor and plasminogen activator inhibitor-1 in gastric cancer. *J Gastroenterol Hepatol* 1998; **13**: 936-944
- 17 **Lee DH**, Yang Y, Lee SJ, Kim KY, Koo TH, Shin SM, Song KS, Lee YH, Kim YJ, Lee JJ, Choi I, Lee JH. Macrophage inhibitory cytokine-1 induces the invasiveness of gastric cancer cells by up-regulating the urokinase-type plasminogen activator system. *Cancer Res* 2003; **63**: 4648-4655
- 18 **Min HY**, Doyle LV, Vitt CR, Zandonella CL, Stratton-Thomas JR, Shuman MA, Rosenberg S. Urokinase receptor antagonists inhibit angiogenesis and primary tumor growth in syngeneic mice. *Cancer Res* 1996; **56**: 2428-2433
- 19 **Senger DR**, Galli SJ, Dvorak AM, Perruzzi CA, Harvey VS, Dvorak HF. Tumor cells secrete a vascular permeability factor that promotes accumulation of ascites fluid. *Science* 1983; **219**: 983-985
- 20 **Gupta K**, Kshirsagar S, Li W, Gui L, Ramakrishnan S, Gupta P, Law PY, Hebbel RP. VEGF prevents apoptosis of human microvascular endothelial cells via opposing effects on MAPK/ERK and SAPK/JNK signaling. *Exp Cell Res* 1999; **247**: 495-504
- 21 **Mandriota SJ**, Seghezzi G, Vassalli JD, Ferrara N, Wasi S, Mazziere R, Mignatti P, Pepper MS. Vascular endothelial growth factor increases urokinase receptor expression in vascular endothelial cells. *J Biol Chem* 1995; **270**: 9709-9716
- 22 **Wickström SA**, Veikkola T, Rehn M, Pihlajaniemi T, Alitalo K, Keski-Oja J. Endostatin-induced modulation of plasminogen activation with concomitant loss of focal adhesions and actin stress fibers in cultured human endothelial cells. *Cancer Res* 2001; **61**: 6511-6516
- 23 **Bajou K**, Masson V, Gerard RD, Schmitt PM, Albert V, Praus M, Lund LR, Frandsen TL, Brunner N, Dano K, Fusenig NE, Weidle U, Carmeliet G, Loskutoff D, Collen D, Carmeliet P, Foidart JM, Noël A. The plasminogen activator inhibitor PAI-1 controls in vivo tumor vascularization by interaction with proteases, not vitronectin. Implications for antiangiogenic strategies. *J Cell Biol* 2001; **152**: 777-784
- 24 **Kaneko T**, Konno H, Baba M, Tanaka T, Nakamura S. Urokinase-type plasminogen activator expression correlates with tumor angiogenesis and poor outcome in gastric cancer. *Cancer Sci* 2003; **94**: 43-49
- 25 **Allgayer H**, Babic R, Grütznert KU, Beyer BC, Tarabichi A, Schildberg FW, Heiss MM. Tumor-associated proteases and inhibitors in gastric cancer: analysis of prognostic impact and individual risk protease patterns. *Clin Exp Metastasis* 1998; **16**: 62-73
- 26 **Yang JL**, Seetoo Dq, Wang Y, Ranson M, Berney CR, Ham JM, Russell PJ, Crowe PJ. Urokinase-type plasminogen activator and its receptor in colorectal cancer: independent prognostic factors of metastasis and cancer-specific survival and potential therapeutic targets. *Int J Cancer* 2000; **89**: 431-439
- 27 **Konno H**, Baba M, Shoji T, Ohta M, Suzuki S, Nakamura S. Cyclooxygenase-2 expression correlates with uPAR levels and is responsible for poor prognosis of colorectal cancer. *Clin Exp Metastasis* 2002; **19**: 527-534
- 28 **Heiss MM**, Allgayer H, Gruetzner KU, Funke I, Babic R, Jauch KW, Schildberg FW. Individual development and uPA-receptor expression of disseminated tumour cells in bone marrow: a reference to early systemic disease in solid cancer. *Nat Med* 1995; **1**: 1035-1039
- 29 **Lee KH**, Bae SH, Lee JL, Hyun MS, Kim SH, Song SK, Kim HS. Relationship between urokinase-type plasminogen receptor, interleukin-8 gene expression and clinicopathological features in gastric cancer. *Oncology* 2004; **66**: 210-217

S- Editor Wang J L- Editor Kumar M E- Editor Ma WH