

Brain abscess due to odontogenic infection: a case report

Sung Yong Park, Dong Won Suh, Chul Min Park, Min Seok Oh, Dong-Kun Lee

Department of Oral and Maxillofacial Surgery, Sun Dental Hospital, Daejeon, Korea

Abstract (J Korean Assoc Oral Maxillofac Surg 2014;40:147-151)

In this report, we describe a case of brain abscess due to odontogenic infection. A 53-year-old female who had been suffering from headache and trismus for two weeks visited the Department of Oral and Maxillofacial Surgery at the Sun Dental Hospital (Daejeon, Korea). Even after several routine tests, we still could not make a diagnosis. However, after the combined multidisciplinary efforts of oral surgeons and neurosurgeons, the patient was treated for odontogenic infection and made an uneventful recovery. Therefore, patients with infections in the head and neck region showing symptoms such as headache, changes in mental state, nausea, vomiting, seizures, hemiplegia, speech disturbance, and visual disturbance, a brain abscess should be included in the list of differential diagnoses.

Key words: Brain abscess, Odontogenic, Infection

[paper submitted 2014. 5. 5 / revised 2014. 5. 25 / accepted 2014. 5. 27]

I. Introduction

Untreated odontogenic infections can advance to osteomyelitis, cellulitis, myofascial space abscess, lymphadenitis, bacteremia, or sepsis, all of which can be extremely dangerous. Brain abscesses, which are rare, are also a potential type of infection that could arise. These are suppurative infections of the brain parenchyma that are surrounded by a vascularized capsule. In the United States, there are only 1,500 to 2,500 brain abscess cases each year¹. Bacterial brain abscesses have three main etiologies. The most common cause is contiguous spread of infection from the oropharynx, middle ear, and paranasal sinuses². Brain abscesses can also arise from hematogenous dissemination of bacteria³. Previous cranial trauma and neurosurgical procedures can also cause brain abscesses⁴⁻⁶.

The aim of this report is to present a rare case of a brain abscess due to odontogenic infection in a middle-aged woman.

Dong-Kun Lee

Department of Oral and Maxillofacial Surgery, Sun Dental Hospital, 645, Daejong-ro, Jung-gu, Daejeon 301-841, Korea
TEL: +82-42-251-5000 FAX: +82-42-257-2280
E-mail: omsdklee@gmail.com

©This is an open-access article distributed under the terms of the Creative Commons Attribution Non-Commercial License (<http://creativecommons.org/licenses/by-nc/3.0/>), which permits unrestricted non-commercial use, distribution, and reproduction in any medium, provided the original work is properly cited.

Copyright © 2014 The Korean Association of Oral and Maxillofacial Surgeons. All rights reserved.

II. Case Report

A 53-year-old female visited the Department of Oral and Maxillofacial Surgery at the Sun Dental Hospital (Daejeon, Korea) in September 2013 with trismus being her chief complaint. The patient had been receiving treatment for headaches and trismus at a local medical hospital and dental clinic for two weeks but the symptoms did not subside and the etiology was unclear. So the patient visited our clinic. At the time of her visit, the patient had facial swelling and trismus <20 mm. Routine clinical and radiologic exams showed localized chronic periodontitis of the maxillary right posterior region, but no other possible causes of the patient's symptoms (e.g., fascial space abscess) were found. (Figs. 1, 2) No systemic conditions that could have interfered with the patient's immune system were found.

A pterygomandibular space abscess was first suspected to be the cause of trismus, but palpation and an aspiration exam yielded negative results. Meanwhile, laboratory blood tests revealed signs of an on-going infection. These results showed a white blood cell count of 12,900/mm³ with a differential count of 76.9% segmented cells and 16.5% lymphocytes. The erythrocyte sedimentation rate was 114 mm/hr and C-reactive protein level was 11.02 mg/dL. The patient's body temperature was 36.9°C. She also showed signs of myalgia, slightly altered orientation, and speech difficulty.

After her admission to the hospital, additional radiographs

were taken.

On day one at the hospital, the patient had a 38.9°C body temperature, which then rose to 39.3°C. She complained of

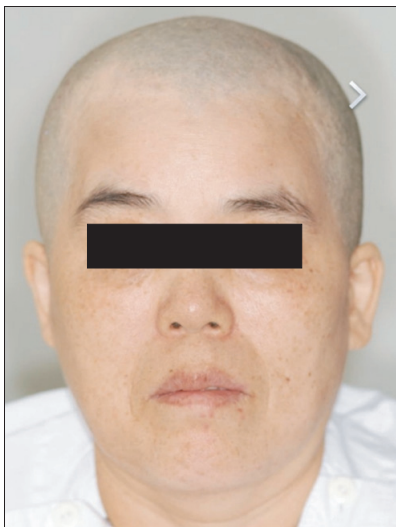

Fig. 1. Photo shows preoperative facial characteristics on third day of hospitalization.
Sung Yong Park et al: Brain abscess due to odontogenic infection: a case report. J Korean Assoc Oral Maxillofac Surg 2014

a headache and soon became drowsy. Empirical antibiotics, such as augmentin, isepamicin, and metronidazole, were administered five days prior to her operation.

During imaging analyses, a 1.5×1.5 cm-sized perforation of the right sphenoid bone was detected (Fig. 3) and on magnetic resonance imaging (MRI) T2, a 1.3×1.8 cm-sized capsulated regular mass was observed in the right temporal lobe along with irregular edema.(Fig. 4) After consulting with neurosurgery specialists, the patient was diagnosed with

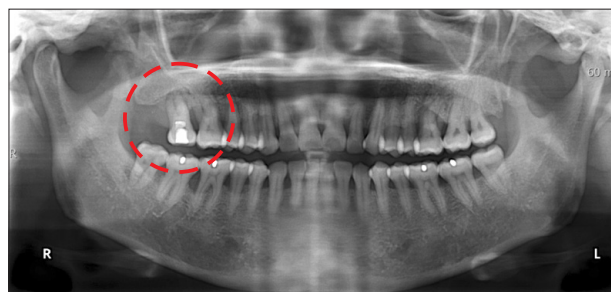


Fig. 2. Panorex showed severe alveolar resorption of #17 (circle).
Sung Yong Park et al: Brain abscess due to odontogenic infection: a case report. J Korean Assoc Oral Maxillofac Surg 2014

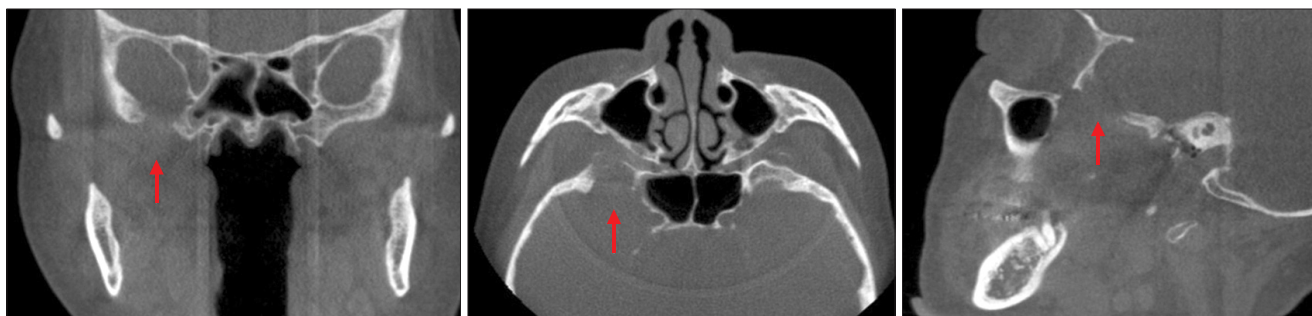

Fig. 3. Computed tomography showed a perforation of the right sphenoid bone (arrows).
Sung Yong Park et al: Brain abscess due to odontogenic infection: a case report. J Korean Assoc Oral Maxillofac Surg 2014

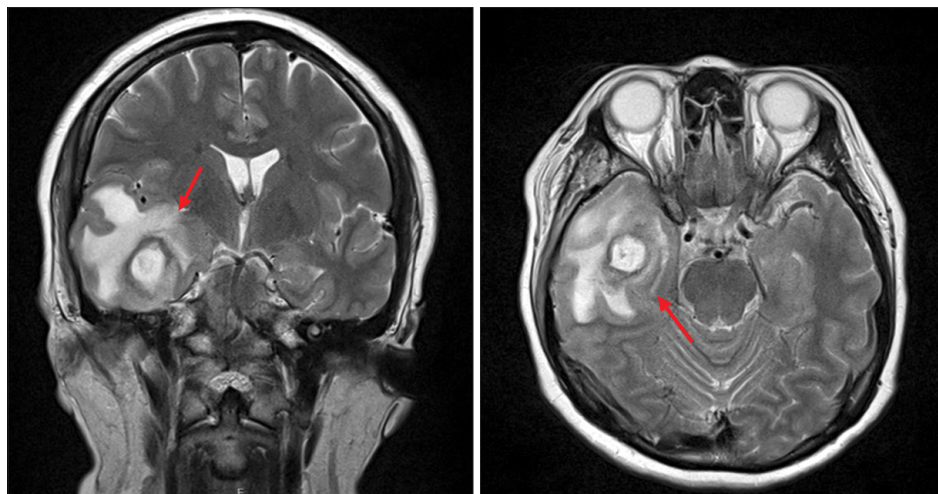


Fig. 4. Magnetic resonance imaging T2 scan showed a 1.3×1.8 cm capsulated regular mass (arrows).
Sung Yong Park et al: Brain abscess due to odontogenic infection: a case report. J Korean Assoc Oral Maxillofac Surg 2014

a brain abscess of dental origin.

The patient then underwent abscess drainage through a craniotomy procedure, which involved decompressive craniotomy and aspiration without resection of the capsule while the patient was under general anesthesia. Approximately 8 mL of yellowish-brown pus was aspirated from the lesion (Fig. 5) and a small amount of the pus was sent for culture. The capsule of the abscess was not removed because it had adhered to the brain parenchyma. The patient was put on postoperative intravenous antibiotic therapy, including ceftriaxone, Hanomycin (Sam Jin Pharm., Seoul, Korea), isepamicin and trizel. Antibiotics were administered intravenously until all symptoms subsided. After 48 hours, there was no bacterial growth from the pus culture. One week after undergoing decompressive craniotomy and aspiration, the patient's head-

ache disappeared and her maximal mouth opening increased to about from 15 mm to 30 mm. The upper right second molar, which was suspected to be the source of the infection, was extracted while the patient was under local anesthesia. (Fig. 6) After the operation, the patient remained on antibiotics for two months. The patient remained under the care of an oral surgeon and a neurosurgeon and she recovered fully. She was discharged from the hospital without any neurological sequela.(Fig. 7)

The total treatment process is described in Table 1.

Table 2 shows the patient's lab results and body temperatures at different treatment stages.

By seven months post-surgery, there had been no recurrence of the infection, as determined by computed tomography (CT) and MRI during follow-up appointments.(Fig. 8)

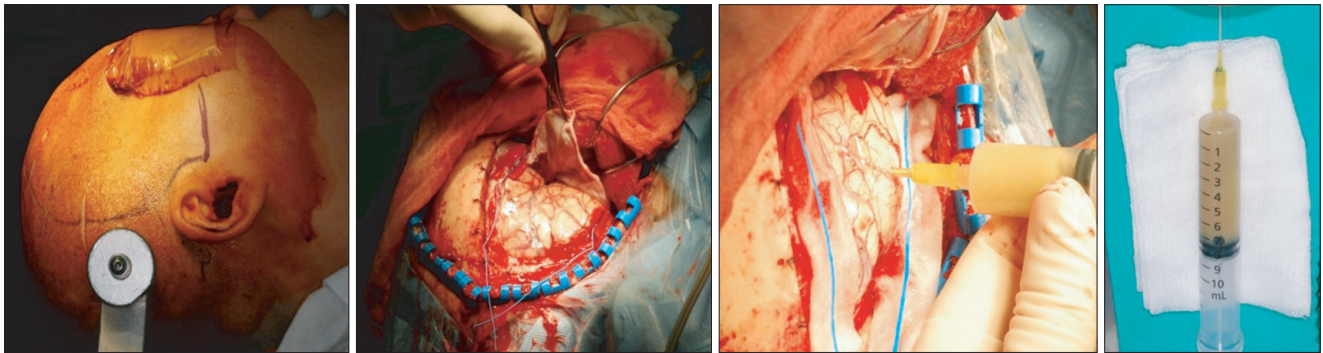


Fig. 5. Procedures of craniotomy and aspiration: approximately 8 mL of pus was removed.
Sung Yong Park et al: Brain abscess due to odontogenic infection: a case report. J Korean Assoc Oral Maxillofac Surg 2014

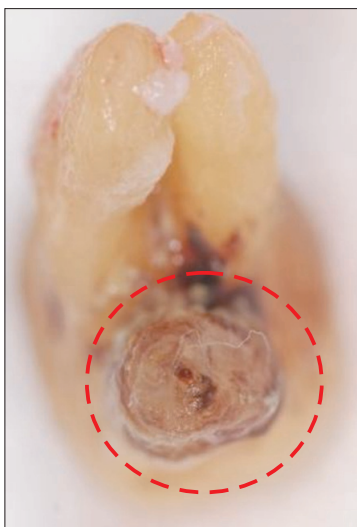


Fig. 6. The extracted tooth had severe root resorption (circle).
Sung Yong Park et al: Brain abscess due to odontogenic infection: a case report. J Korean Assoc Oral Maxillofac Surg 2014

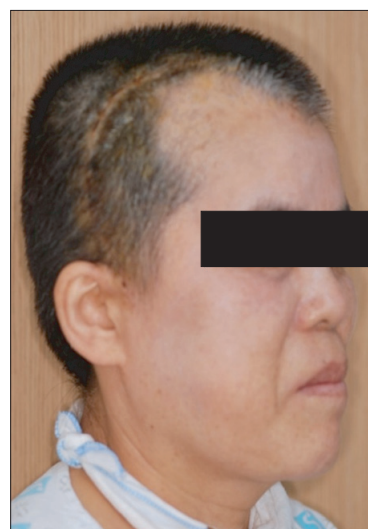

Fig. 7. The patient did not show any signs of neurological sequela.
Sung Yong Park et al: Brain abscess due to odontogenic infection: a case report. J Korean Assoc Oral Maxillofac Surg 2014

Table 1. Timetable showing the treatment process

Onset	Department					Discharge
	OM	IM	OM OMFS	NS	OMFS	
2013/08/20 (yr/mo/day)	2013/09/03	2013/09/05	2013/09/06	2013/09/17	2013/10/18	2013/10/22
Temporal pain	+	+	+	-	-	Recovered
	Trismus	+	+	+	+/-	
		Headache	+	-	-	
			Drowsy	-	-	
Tx	CT	MRI	ADM	Craniotomy	Ext #17	
	Antibiotics	-	Antibiotics			→

(OM: oral medicine, IM: internal medicine, OMFS: oral and maxillofacial surgery, NS: neurosurgery, Tx: treatment, CT: computed tomography, MRI: magnetic resonance imaging, ADM: admission, Ext: extraction)

Sung Yong Park et al: Brain abscess due to odontogenic infection: a case report. J Korean Assoc Oral Maxillofac Surg 2014

Table 2. Lab results and body temperature at different treatment stages

	HD #1	HD #2	HD #3	HD #4	HD #11	Op. day	POD #2	POD #6	POD #13	POD #20	POD #27
WBC (/mm ³)	12,900	9,700	7,260	9,870	9,420	13,300	9,220	7,040	5,800	3,980	3,090
ESR (mm/hr)	114	82	92	73	74		92	91	60	37	24
CRP (mg/dL)	11.02		9.37				6.24			0.17	0.13
BT (°C)	36.9	38.9	39.7	38.3	37.0		37.0	37.0	36.8	36.8	36.9

(HD: hospital day, Op.: operative, POD: postoperative date, WBC: white blood cell, ESR: erythrocyte sedimentation rate, CRP: C-reactive protein, BT: body temperature)

Sung Yong Park et al: Brain abscess due to odontogenic infection: a case report. J Korean Assoc Oral Maxillofac Surg 2014

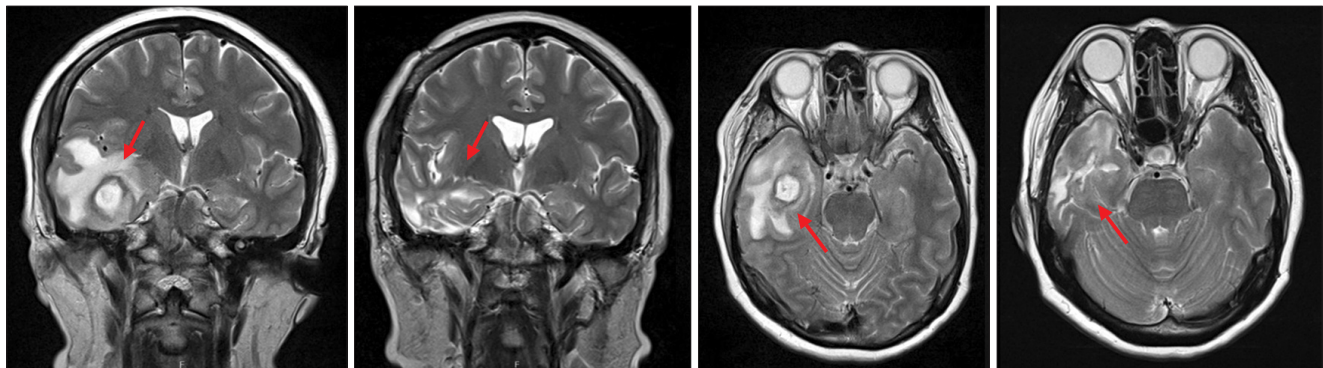


Fig. 8. Comparing preoperative magnetic resonance imaging (MRI) with seven-month postoperative MRI is shown (arrows).

Sung Yong Park et al: Brain abscess due to odontogenic infection: a case report. J Korean Assoc Oral Maxillofac Surg 2014

III. Discussion

Brain abscess is an extremely aggressive, life-threatening infection. It can have as its etiology a metastasis of chronic suppurative disease or congenital cardiomyopathy, or can arise after trauma like open-head injuries or after neurosurgical procedures. Sinusitis, otitis, and untreated odontogenic infections can also be a cause of brain abscess⁷. Corson et al.⁸ reported that cerebral abscesses, albeit rarely, can result from dental or maxillofacial infections.

A diagnosis of brain abscess is considered definite if bacterial organisms were isolated from abscess pus or cerebra-

spinal fluid cultures. In this case, the CT scan showed findings characteristic of brain abscess, including the classical clinical manifestations of headache, fever, localized neurological signs, or disturbance of consciousness. In other patients, confirmation of abscess has come about upon the disappearance of CT abnormalities after antibiotic treatment.

Development and advancement of antibiotics, bacteriological culture and identification techniques, computed tomography, and magnetic resonance imaging have changed the prognosis dramatically^{1,9,10}, which, in turn, has resulted in the mortality rate being reduced from 40%-60% in the pre-CT era to 0%-10% currently¹.

The causative pathogens of brain abscesses vary with underlying medical or surgical conditions and the mode of infection^{11,12}. Lu et al.¹² reported 19 out of 123 patients with brain abscesses were culture-negative. Between 24%-40% of all intracerebral abscesses produce negative culture results because the patient has already received antimicrobial therapy¹², which is the reason that we suspect there was no bacterial growth in this case.

There have been a few articles dealing with brain abscesses that have suspected odontogenic origin.

A PubMed search using the key words “brain abscess,” “odontogenic,” and “dental” yielded twenty-two articles, all of which were case reports. However, none of these reports described the relationship between brain abscess and dental infection because they lacked evidence to do so. In the case reported here, there was a clear progression route from infection in the right maxillary second molar to the right temporal lobe through the perforated sphenoid bone. Upon extracting the right maxillary second molar, severe palatal root resorption was observed.

In 2000, de Louvois et al.¹³ argued for a more thoughtful use of antibiotics for treating brain abscesses, emphasizing the ability of antibiotics to penetrate the blood-brain barrier. Sjölin et al.¹⁴ used third-generation cephalosporins, such as cefotaxime, ceftriaxone, and ceftazidime, as well as metronidazole, to treat patients with odontogenic intracranial infections. They recommended a combination of ampicillin, metronidazole, and either ceftazidime or gentamicin, for treating odontogenic abscesses.

Gorgan et al.¹⁵ reported a general morbidity of 26.19% and mortality remained stable at 7.14% among a total of 84 patients over 12 years, from 2000 to 2011. Half of the patients in this series were diagnosed inaccurately at the initial stage, and it took an average of 7.2 days until the patients received the accurate diagnosis of brain abscess. Bibliographically, the average time between the onset of the symptoms and confirmed diagnoses was 9.6 days¹⁶.

In the case reported here, the patient was initially inaccurately diagnosed. It took 14 days to get an accurate diagnosis of a brain abscess. Successful treatment of brain abscesses requires early diagnosis, timely surgical intervention, and continuous high-dose antibiotic therapy.

Symptoms of brain abscess include headache, changes in mental state, nausea, vomiting, seizures, hemiplegia, speech disturbance, visual disturbance, and others. Therefore, in ex-

amining patients with infections in the head and neck region, if they display any of the above symptoms, brain abscess should be included in the differential diagnosis list. An immediate medical consultation to the neurosurgery department must follow when brain abscess is suspected.

Conflict of Interest

No potential conflict of interest relevant to this article was reported.

References

1. Mamelak AN, Mampalam TJ, Obana WG, Rosenblum ML. Improved management of multiple brain abscesses: a combined surgical and medical approach. *Neurosurgery* 1995;36:76-85.
2. Mathisen GE, Johnson JP. Brain abscess. *Clin Infect Dis* 1997;25:763-79.
3. Heilpern KL, Lorber B. Focal intracranial infections. *Infect Dis Clin North Am* 1996;10:879-98.
4. Xiao F, Tseng MY, Teng LJ, Tseng HM, Tsai JC. Brain abscess: clinical experience and analysis of prognostic factors. *Surg Neurol* 2005;63:442-9.
5. Tseng JH, Tseng MY. Brain abscess in 142 patients: factors influencing outcome and mortality. *Surg Neurol* 2006;65:557-62.
6. Tonon E, Scotton PG, Gallucci M, Vaglia A. Brain abscess: clinical aspects of 100 patients. *Int J Infect Dis* 2006;10:103-9.
7. Carpenter J, Stapleton S, Holliman R. Retrospective analysis of 49 cases of brain abscess and review of the literature. *Eur J Clin Microbiol Infect Dis* 2007;26:1-11.
8. Corson MA, Postlethwaite KP, Seymour RA. Are dental infections a cause of brain abscess? Case report and review of the literature. *Oral Dis* 2001;7:61-5.
9. Petti CA, Simmon KE, Bender J, Blaschke A, Webster KA, Conneely MF, et al. Culture-Negative intracerebral abscesses in children and adolescents from *Streptococcus anginosus* group infection: a case series. *Clin Infect Dis* 2008;46:1578-80.
10. Mamelak AN, Obana WG, Flaherty JF, Rosenblum ML. Nocardial brain abscess: treatment strategies and factors influencing outcome. *Neurosurgery* 1994;35:622-31.
11. Kao MC. Brain abscess. A clinical analysis of 26 cases with surgical treatment. *Bull Tokyo Med Dent Univ* 1973;20:35-50.
12. Lu CH, Chang WN, Lin YC, Tsai NW, Liliang PC, Su TM, et al. Bacterial brain abscess: microbiological features, epidemiological trends and therapeutic outcomes. *QJM* 2002;95:501-9.
13. de Louvois J, Brown EM, Bayston R, Lees PD, Pople IK. The rational use of antibiotics in the treatment of brain abscess. *Br J Neurosurg* 2000;14:525-30.
14. Sjölin J, Lilja A, Eriksson N, Arneborn P, Cars O. Treatment of brain abscess with cefotaxime and metronidazole: prospective study on 15 consecutive patients. *Clin Infect Dis* 1993;17:857-63.
15. Gorgan M, Neacsu A, Bucur N, Pruna V, Lipan C, Sandu AM, et al. Brain abscesses: management and outcome analysis in a series of 84 patients during 12 year period. *Romanian Neurosurg* 2012;XIX 3:175-82.
16. Le Moal G, Landron C, Grollier G, Bataille B, Roblot F, Nassans P, et al. Characteristics of brain abscess with isolation of anaerobic bacteria. *Scand J Infect Dis* 2003;35:318-21.