



CASE REPORT

Positioning a prone patient with cauda equina syndrome who presents at 15 weeks gestation: a case report [v1; ref status: indexed, <http://f1000r.es/2qn>]

Elizabeth Speirs, Matthew Wiles, Andrew Bacon, Stephen Radley

Royal Hallamshire Hospital, Sheffield Teaching Hospitals, Sheffield, S10 2JF, UK

v1 First published: 27 May 2014, 3:117 (doi: [10.12688/f1000research.3310.1](https://doi.org/10.12688/f1000research.3310.1))
 Latest published: 27 May 2014, 3:117 (doi: [10.12688/f1000research.3310.1](https://doi.org/10.12688/f1000research.3310.1))

Abstract

Cauda equina syndrome is a neurosurgical emergency that requires prompt intervention to prevent irreversible spinal cord paralysis. This article describes how we managed a case of an obese pregnant patient who was placed in the prone position for surgery. We discuss the evidence behind the management options and choice of operating tables available.

Article Status Summary

Referee Responses

Referees	1	2	3
v1 published 27 May 2014	 report	 report	 report

1 **Bernard Wittels**, Saint Francis Hospital
USA

2 **John Svigos**, University of Adelaide
Australia

3 **Michael Paech**, The University of Western
Australia Australia, **Lars Wang**, Royal
Perth Hospital Australia

Latest Comments

No Comments Yet

Corresponding author: Elizabeth Speirs (Elizabeth.Speirs@sth.nhs.uk)

How to cite this article: Speirs E, Wiles M, Bacon A and Radley S (2014) **Positioning a prone patient with cauda equina syndrome who presents at 15 weeks gestation: a case report [v1; ref status: indexed, <http://f1000r.es/2qn>]** *F1000Research* 2014, 3:117 (doi: [10.12688/f1000research.3310.1](https://doi.org/10.12688/f1000research.3310.1))

Copyright: © 2014 Speirs E *et al.* This is an open access article distributed under the terms of the [Creative Commons Attribution Licence](#), which permits unrestricted use, distribution, and reproduction in any medium, provided the original work is properly cited. Data associated with the article are available under the terms of the [Creative Commons Zero "No rights reserved" data waiver](#) (CC0 1.0 Public domain dedication).

Grant information: The author(s) declared that no grants were involved in supporting this work.

Competing interests: No competing interests were disclosed.

First published: 27 May 2014, 3:117 (doi: [10.12688/f1000research.3310.1](https://doi.org/10.12688/f1000research.3310.1))

First indexed: 11 Jun 2014, 3:117 (doi: [10.12688/f1000research.3310.1](https://doi.org/10.12688/f1000research.3310.1))

Case

We present a case of Cauda equina syndrome in a 24 year old woman at 15 weeks gestation. She had no other medical problems to note and had previously had two uncomplicated pregnancies. Her elevated body mass index (BMI) of 36 kg/m² did provide a potential difficulty in managing this case.

The patient was referred to our tertiary neurosurgical unit with a 24 hour history of severe lower back pain, altered perianal sensation and right lower limb weakness. An urgent MRI scan showed a large L5/S1 disc prolapse (Figure 1). A frank discussion of the risks of medical versus surgical management was undertaken, and immediate surgery was chosen by the patient.

The decompression was performed with our patient prone under general anaesthesia, which was maintained using a combination of sevoflurane and remifentanyl. Due to the body habitus of the patient (BMI 36 kg/m²), it was felt that undertaking surgery in the lateral position would have been technically difficult, with an increased operative time and a greater risk of bleeding. We chose to prone the patient on to a Jackson table (OSI, Union City, CA) with supports on the sternum and laterally on the iliac spines. Absolute care was taken to ensure that there was no abdominal compression once positioned.

The operation was performed uneventfully and lasted 90 minutes. Cardiovascular stability was maintained throughout. The patient's neurology had fully recovered by the first postoperative day and a fetal ultrasound that day showed a viable fetus. Unfortunately this was later found to be a twin pregnancy, one of whom was spontaneously aborted. The second twin was delivered healthy at 39 weeks gestation.

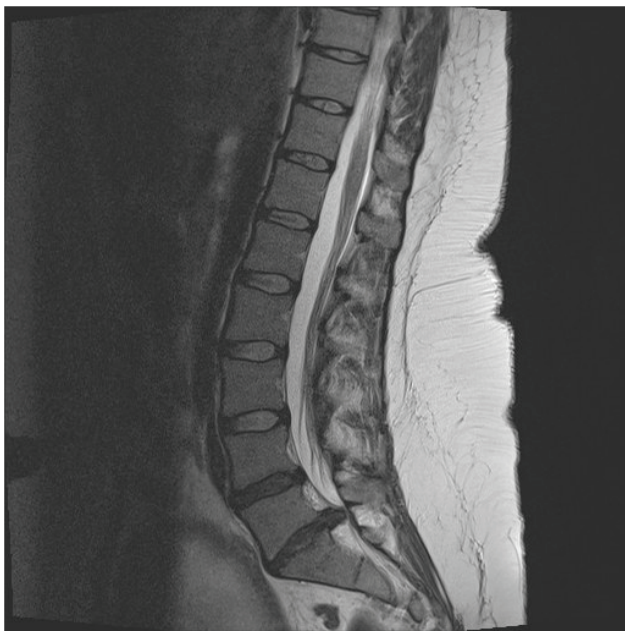


Figure 1. Pre-operative MRI lumbar spine showing a L5/S1 prolapse.

Discussion

There is little literature currently available to guide positioning, especially discussing prone techniques in pregnant patients for spinal surgery. Discectomies in gestational patients can be performed in both the prone and lateral position¹. A proned patient allows better surgical access, but the lateral position may make it easier to ensure that there is no abdominal compression to compromise uterine blood flow. Even though the majority of operating tables designed for prone allow the abdomen to hang free in non-pregnant patients, they are not designed to fit the larger pregnant abdomen. We could find no literature comparing the use of different operating tables and the abdominal space that they offer a pregnant abdomen.

Uterine blood flow during prone positioning has been examined by Nakai *et al.*². They took 23 healthy women at 34 weeks gestation and laid them in a supine, right lateral, left lateral and prone position. The prone table had a hole in it for the pregnant abdomen so they could see that no compression occurred. They found that prone positioning actually provided optimal relief of umbilical artery compression as measured by the umbilical artery systolic/diastolic ratio, and that this is superior to that of both the right and left lateral positions. The effect of the prone position on uterine blood flow in an anaesthetised patient has not been determined however.

The few small case series and cases that we found describing spinal surgery in the prone position for gestational women have demonstrated good fetal outcomes. One series³ presents the course of three women of 16 to 20 weeks gestation who required discectomies for lumbar disc herniation during pregnancy. They all received epidural anaesthesia and then self positioned themselves prone on a Relton-Hall laminectomy frame (IS, Dorval, Quebec). All babies were delivered without complications at full term. The authors chose the Relton-Hall frame as it has pressure points on the anterior superior iliac spines and the chest, which they felt allowed most freedom of the abdomen and uncompressed Inferior vena cava blood flow. In addition, they concluded that letting the women position themselves prior to receiving an anaesthetic was an extra safety measure. They believed that if they could ensure that the women were comfortable once proned, they were satisfied that there was no undue pressure on the abdomen and uterus. Even at 30 weeks gestation, the technique of regional anaesthesia and patient self-positioning has been seen to have no adverse foetal effects⁴. In this case they also undertook foetal monitoring throughout surgery, and noted no foetal compromise intra-operatively.

Cervical and thoracic decompressions for epidural haematomas are similar surgical emergencies that present the need to prone patients under general anaesthesia. A case series of six patients reports all the babies being born healthily after spinal decompressions⁵. These patients were placed on a Wilson frame (ZA, Jiangsu, China). Three procedures were undertaken at 20, 24 and 34 weeks, with spontaneous deliveries occurring at term. Three other women of 35, 38 and 41 weeks gestation underwent caesarean sections prior to decompression with no adverse foetal outcomes. The recommendations from this series are that neurosurgical intervention to avoid permanent neurological damage is safe and that surgery should not be delayed in obstetric patients.

There is only one published guideline that we could find on positioning and spinal surgery in gestational women, produced by a centre in Korea¹. They followed a case series of ten women from their institution, 6 of who had lumbar disc herniation, the others infection or tumour. All patients in the first trimester were placed in a prone position, five delivering healthy full term babies whilst one patient had a therapeutic abortion for early radiation exposure. Of the later term patients, two were put in right, and two in left lateral positions. One baby was born healthily at full term, one by elective caesarean section at 34 weeks gestation, one pre-term at 33 weeks spontaneously and one therapeutic abortion was performed, also due to radiation exposure. Their guidelines produced from this review suggest epidural anaesthesia for most procedures, but for longer operating duration general anaesthesia may be preferable. It also recommends that during the first and early second trimester a prone position for surgery is safe, but a left lateral position is preferable for the latter part of the second trimester and third trimester. They conclude that from their review and own experiences peripartum, neurosurgical procedures can be safely performed in most pregnancies.

Conclusion

In summary, there is very limited evidence to guide the optimal management of the pregnant patient who requires emergency spinal surgery. However, safe outcomes for both mother and fetus undergoing general anaesthesia for varying pathologies during the first trimester have been seen in many case series⁶. These women were all supine, but there appears to be no reason to delay general anaesthesia during the first trimester. For pregnancies of 34 weeks gestation and over, a caesarean section can be performed safely prior to, or, as a combined procedure with discectomies⁷.

Another very important aspect of case management involves a multi disciplinary team approach peri-operatively. A fetal ultra sound

should be performed before any intervention is undertaken and fetal heart monitoring intra-operatively should be considered. Alterations in fetal heart rate can alert the anaesthetist as early as possible to aortocaval compression and cardiovascular insufficiency due to poor positioning of the mother. Close obstetric follow up is essential in any non-obstetric surgery.

From all the literature that we have looked at, there appears to be no reason to avoid the prone position for surgery. Nor is there evidence to suggest that regional or general anaesthesia offers significant benefits to either mother or foetus. There is also no particular operating table that we can recommend, but knowledge of your own equipment is vital. We believe that the key aspects of the management of such cases is to take meticulous care during positioning to ensure that the abdomen is free, no matter what position or operating table is chosen.

Consent

Written informed consent for publication of their clinical details and/or clinical images was obtained from the patient.

Author contributions

ES wrote up the case report and first draft and MW was the main reviewer. AB and SR provided expert input in the case and reviewed the case report.

Competing interests

No competing interests were disclosed.

Grant information

The author(s) declared that no grants were involved in supporting this work.

References

- Han IH, Kuh SU, Kim JH, *et al.*: **Clinical approach and surgical strategy for spinal diseases in pregnant women: a report of ten cases.** *Spine.* 2008; **33**(17): E614–619.
[PubMed Abstract](#) | [Publisher Full Text](#)
- Nakai Y, Mine M, Nishio J, *et al.*: **Effects of maternal prone position on the umbilical arterial flow.** *Acta Obstet Gynecol Scand.* 1998; **77**(10): 967–969.
[PubMed Abstract](#) | [Publisher Full Text](#)
- Brown MD, Levi AD: **Surgery for lumbar disc herniation during pregnancy.** *Spine.* 2001; **26**(4): 440–443.
[PubMed Abstract](#)
- Kim HS, Kim SW, Lee SM, *et al.*: **Endoscopic discectomy for the cauda equina syndrome during third trimester of pregnancy.** *J Korean Neurosurg Soc.* 2007; **42**(5): 419–420.
[PubMed Abstract](#) | [Publisher Full Text](#) | [Free Full Text](#)
- Jea A, Moza K, Levi AD, *et al.*: **Spontaneous spinal epidural haematoma during pregnancy: Case report and literature review.** *Neurosurgery.* 2005; **56**(5): E1156.
[PubMed Abstract](#)
- Cohen-Kerem R, Railton C, Oren D, *et al.*: **Pregnancy outcome following non-obstetric surgical intervention.** *Am J Surg.* 2005; **190**(3): 467–473.
[PubMed Abstract](#) | [Publisher Full Text](#)
- Brown MD, Brookfield KF: **Lumbar disc excision and cesarean delivery during the same anesthesia. A case report.** *J Bone Joint Surg Am.* 2004; **86-A**(9): 2030–2203.
[PubMed Abstract](#)

Current Referee Status:

Referee Responses for Version 1



Michael Paech¹, Lars Wang²

¹ Department of Anaesthesia and Pain Medicine, The University of Western Australia, Perth, WA, Australia

² Royal Perth Hospital, Perth, WA, Australia

Approved with reservations: 11 June 2014

Referee Report: 11 June 2014

doi:[10.5256/f1000research.3551.r4903](https://doi.org/10.5256/f1000research.3551.r4903)

The submission is a case report of a 15 week pregnant woman who needs urgent lumbar discectomy for cord compression. This requires the use of the prone position (PP) on a Jackson table.

The use of a so-called Jackson Table is sensible. It allows for the abdomen to hang freely between the pelvic and chest support. It thus reduces the epidural venous pressure that may cause troublesome bleeding for the surgeon. The Wilson frame (as mentioned in the Discussion) will cause more pressure on the abdomen.

The main message is the discussion of the effects of the PP on uteroplacental blood flow and fetal outcome. However, in week 15 the effects on the uteroplacental blood flow may not be significant and the other problems associated with the prone position should be mentioned.

A number of other case reports and case series are presented that indicate the PP may be safe during pregnancy. However, the lack of reference to the anaesthetic literature in the references suggests that the authors may not be aware use of the PP during GA is already reasonably well described during pregnancy.

More specific comments:

- The word 'proning' (and term 'proned patient') are incorrect in our opinion – use as a verb except in gaming vernacular. The terms 'prone' or 'patient in the prone position' should be substituted throughout.
- There is inadequate discussion of the anaesthetic issues. Although “safe outcomes” occur after GA in the first trimester, the clear consensus in the anaesthesia community is to avoid or delay GA until the second trimester if possible and to use regional anaesthesia when possible.
- **Conclusion:**
L2-3: What is meant by “varying pathologies”? Do the authors refer to spinal pathology or any pathology that requires general anaesthesia during first trimester?

L7-8: Fetal heart rate monitoring was not adequately discussed. During surgery is not useful until

after fetal viability and is difficult to interpret at early gestations. It may give some indication of fetal compromise that prompts change in anaesthesia, but it is only of true value if provision has been made to perform emergency delivery, which does not apply in this case.

We have read this submission. We believe that we have an appropriate level of expertise to confirm that it is of an acceptable scientific standard, however we have significant reservations, as outlined above.

Competing Interests: No competing interests were disclosed.



John Svigos

Discipline of Obstetrics & Gynaecology, School of Paediatrics & Reproductive Health, Faculty of Health Sciences, University of Adelaide, Adelaide, SA, Australia

Approved: 02 June 2014

Referee Report: 02 June 2014

doi:[10.5256/f1000research.3551.r4956](https://doi.org/10.5256/f1000research.3551.r4956)

Whilst I find it to be an informative and current paper with a good appraisal of the available literature, intuitively and grammatically I believe the use of "proning" etc is incorrect as prone is an adjective and must be used in this manner as the "alternative" use detracts from the paper.

I have read this submission. I believe that I have an appropriate level of expertise to confirm that it is of an acceptable scientific standard.

Competing Interests: No competing interests were disclosed.



Bernard Wittels

Continental Anesthesia, Saint Francis Hospital, Evanston, IL, USA

Approved with reservations: 02 June 2014

Referee Report: 02 June 2014

doi:[10.5256/f1000research.3551.r4905](https://doi.org/10.5256/f1000research.3551.r4905)

These authors present an unusual case of an obese, pregnant woman at 13 weeks gestational age who presented with perineal hypesthesia and partial loss of motor function in her right lower leg. An MRI showed an L5-S1 herniated nucleus pulposus that required emergency decompression. The authors discuss their anesthetic management of the patient and review the current literature.

Title: The title should be re-worded because the patient did not have cauda equina syndrome (which usually includes partial or full loss of control of bowel and bladder sphincters, and may include painful paresthesias), and the word "prone" should only be used as an adjective. A more appropriate title would be: *Anesthesia for emergent lumbosacral discectomy and nerve decompression in an obese parturient at 13 weeks gestation.*

Case report:

1. Again, the term cauda equina should be removed. The list of potential difficulties in administering anesthesia to an obese, preterm parturient needs to be elaborated in detail. There is no mention of

consenting the patient for the MRI, including the risks of MRI to the developing fetus. The patient's sensorimotor radiculopathies represent a neurosurgical emergency; medical therapy in this setting does not conform to the standard of care and should not have been offered as a valid alternative therapy. To conform with their discussion points, the authors should have obtained an obstetric consultative evaluation. The absence of preoperative, intraoperative, and postoperative obstetric consultations should be explained. The failure to detect twin gestations at 13 weeks of age, despite having an MRI, needs to be discussed.

2. It appears that epidural and/or spinal anesthesia were not considered or offered as an alternative to general anesthesia, nor were these two anesthesia techniques compared for their relative risks and benefits to the mother and her fetus. The authors should mention that spinal anesthesia produces decreased fetal drug exposure and decreased maternal blood loss, compared to general anesthesia. What was the patient's airway evaluation? Many obese parturients have difficult airways that can pose life-threatening problems with hypoxemia and failure to intubate after induction of anesthesia. How was the anesthetic induction managed? What drugs were used? What happened to her oxygenation, ventilation, and hemodynamics on induction of anesthesia? Why were sevoflurane and remifentanyl chosen for maintenance of anesthesia? What advantages or disadvantages does this regimen have over other choices?
3. In an obese patient, the prone position would seem to be the only reasonable choice by the neurosurgeon. Abdominal compression is just one consideration in the safe positioning of an obese, pregnant patient prone on the operating table. What are the other concerns? Could the fetal heart rate be monitored externally? If so, then why wasn't fetal heart monitoring employed intraoperatively? What would be the expected fetal heart rate pattern?
4. Exactly when was the twin gestation diagnosis made? Why wasn't that diagnosis made earlier? Could the radiation from the MRI, or the effects of surgery, anesthetic drugs, or the prone position have any potential effect on halting the growth and development of the unborn twin?

Discussion: It would be useful for the authors to distinguish known safety concerns in this setting from factors that are unknown and untested. This section should be shortened. The Nakai reference should be dropped because it was done in awake patients near term gestation. No comparative study of OR tables for the prone position of pregnant patients has been done. It is inconsistent to review a study that used intraoperative fetal monitoring without commenting on why it was not used on your study case patient. None of the referenced studies involved preterm gestations or obese parturients. ASA guidelines are worth referencing, but not one from Korea based on a single study of ten patients.

Conclusion: What did you do differently throughout the perioperative period to manage these problems that were unique to your case? Where did you succeed? After reviewing the literature, how do you see your case enhancing our knowledge of neuroanesthesia during pregnancy? Since there are no studies comparing regional versus general anesthesia in this setting, no conclusion can be made about their relative benefits and risks. Abdominal compression alone is not the only major concern with the prone position. What are other concerns and how are these assessed and managed? What would you do differently or better in the future to provide the safest level of care? Can you suggest further research that is needed?

I have read this submission. I believe that I have an appropriate level of expertise to confirm that it is of an acceptable scientific standard, however I have significant reservations, as outlined above.

Competing Interests: No competing interests were disclosed.
