

Breast magnetic resonance imaging: focus/foci

Liuquan Cheng¹, Xiru Li²

¹Department of Radiology; ²Department of Surgery, Chinese PLA General Hospital, Beijing 100853, China

Correspondence to: Liuquan Cheng, MD. Department of Radiology, Chinese PLA General Hospital, No. 28 Fuxing Road, Beijing 100853, China.
Email: lvquan_cheng@yahoo.com.



Submitted Jul 23, 2012. Accepted for publication Aug 24, 2012.

doi: 10.3978/j.issn.2227-684X.2012.08.06

Scan to your mobile device or view this article at: <http://www.glandsurgery.org/article/view/1010/1198>

Focus refers to a tiny non-specific spot of enhancement. Different BI-RADS-MRI literature applies different focus classifications. Some literature regards focus as a special type of nonmasslike enhancement (NMLE), while others classify it as an independent enhancement type dependent from mass and NMLE (*Figures 1,2,3*). Focus usually is independent tiny spot enhancement, but can also be multiple diversely-distributed spotty enhancement. The lesion has space-occupying effect, with a diameter less than 5 mm. The spatial resolution of MRI is not sufficient to display its shape and margin features, and therefore can not provide accurate morphological descriptions. Dynamic contrast enhancement curve and apparent diffusion coefficient (ADC) measurement can not provide precise information due to the partial volume effect resulted from small region of interest (ROI) (1). Foci with tiny spot of enhancement are common upon MRI. The spot of enhancement during the arterial phase of dynamic enhancement (within 90s after the administration of agent) often has uncertain nature. As an occasional finding during breast examination, it is relatively common in women who are in the the secretory phase of the menstrual cycle, with strong estrogen secretion, using contraceptives, and/or using estrogen health care products. The recommended management for patients with foci is BI-RADS Category 3 follow-up (2).

Foci should be differentiated from the stippled enhancement of NMLE. Foci refers to the obvious enhancement during the first enhancement phase, and it can not be identified morphologically due to its small size; on the contrary, the stippled NMLE is even smaller (1-2 mm in diameter) and shows mild enhancement or non-enhancement during the first phase and the enhancement occurs 3-4 minutes after the administration of agent or even later. The magnitude and scope of the enhancement gradually increase as the time

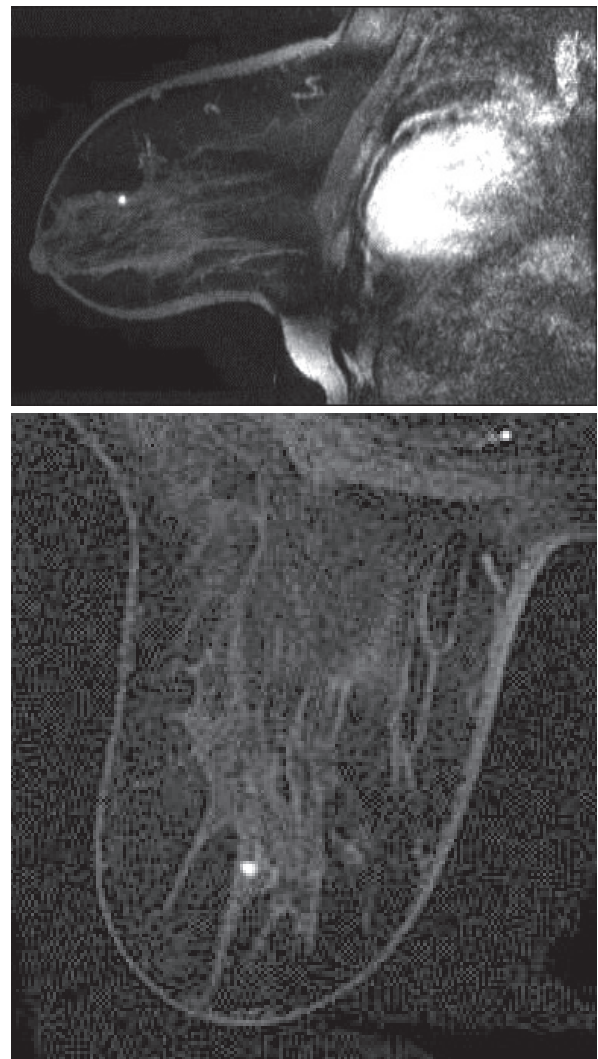


Figure 1 Stippled lesion. It shows remarked enhancement during the arterial phase, with a diameter less than 5 mm. No morphological feature is identified, and further follow-up is needed.

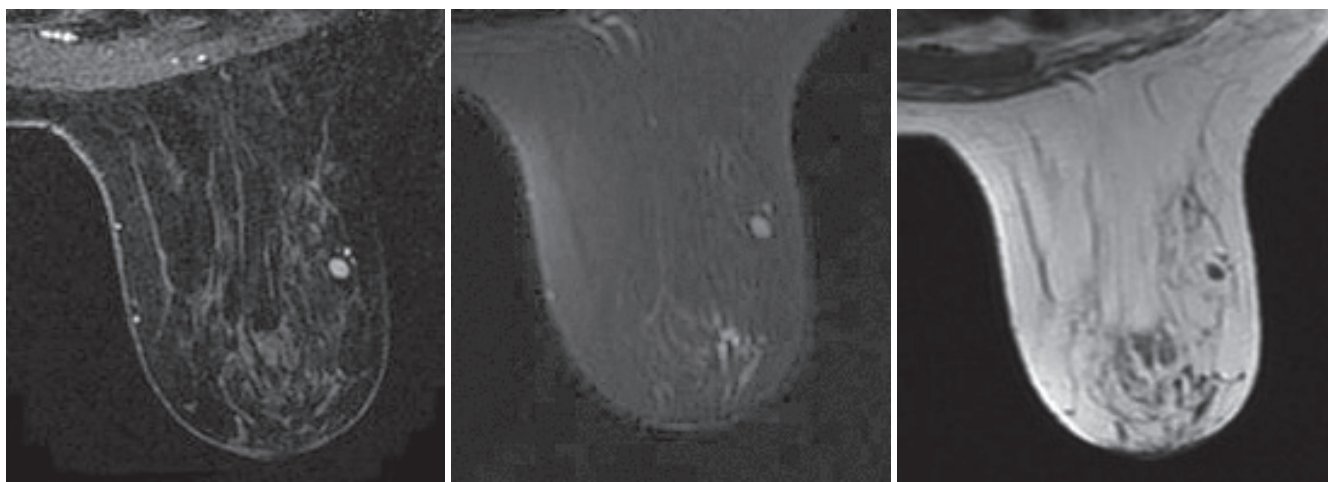


Figure 2 Stippled enhancement. Stippled enhancement during the arterial phase, with a diameter less than 5 mm. It can be identified as oval-shaped, with smooth margin and rim internal enhancement. Intramammary lymph nodes. Under high-resolution MRI, enhancements (even though it is less than 5 mm in diameter) with identifiable shape, margin, and internal enhancement should be managed as masses.

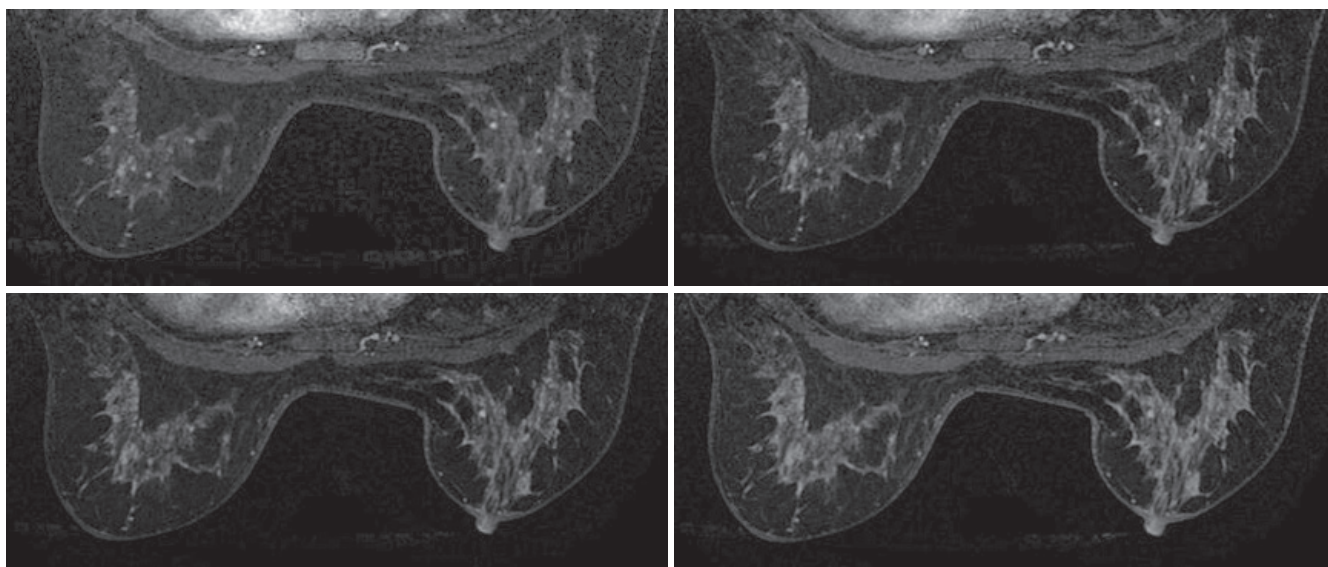


Figure 3 Multiple stippled enhancements. Multiple stippled enhancements in both breasts during the arterial phase with a diameter less than 5 mm and unidentifiable morphological features. The stippled enhancement in the medial left breast remains enhancing during the delayed phase. It is interpreted as BI-RAD category 3, and follow-up is recommended. Most stippled enhancements become centrifugal enhancements during the delayed phase, which is lost among the enhancing glands. It is then interpreted as BI-RADS category 2.

goes by, somehow similar to the plum blossom painting skills in Chinese Painting. Most stippled enhancements at delayed phase on dynamic contrast-enhanced scan are associated with mammary gland hyperplasia or fibrocystic

changes. It can be symmetric in both breasts at the early stage of the menstrual cycle (mammary secretory phase), and shows isointensity with breast parenchyma on DWI, T2WI, and T1WI. This lesion is classified as BI-RADS

category 2.

When the term “focus/foci” is used, it should be carefully distinguished from “focal area”. “Focus/foci” is used to describe enhancement without specific features, whereas “focal area” describes NMLE that is confined in small scope. Focus/foci usually refers to the isolated stippled enhancement during the early arterial phase with a diameter less than 5 mm. No exact term is used for morphological description; furthermore, since these foci have too small ROI, the dynamic contrast enhancement curve is easily affected by partial volume effect and therefore is inaccurate. The focal area refers to NMLE than is larger than a focus. Compared with the surrounding normal tissues, it has certain morphological features, with isolate fat or gland tissues

inside, which enables it to be differentiated from mass.

Acknowledgements

Disclosure: The authors declare no conflict of interest.

References

1. Zhang BN, Cao XC, Chen JY, et al. Guidelines on the diagnosis and treatment of breast cancer (2011 edition). *Gland Surg* 2012;1:39-61.
2. Cheng L, Li X. Breast Imaging Reporting and DataSystem (BI-RADS) of magnetics resonance imaging: Breast mass. *Gland Surg* 2012;1:62-74.

Cite this article as: Cheng L, Li X. Breast magnetic resonance imaging: focus/foci. *Gland Surg* 2012;1(2):136-138. doi: 10.3978/j.issn.2227-684X.2012.08.06