

Wound Dressings and Comparative Effectiveness Data

Aditya Sood,^{1,*} Mark S. Granick,¹ and Nancy L. Tomaselli²

¹Department of Surgery, Division of Plastic Surgery, University of Medicine and Dentistry in New Jersey (UMDNJ)—New Jersey Medical School, Newark, New Jersey.

²Premier Health Solutions, LLC, Cherry Hill, New Jersey.

Significance: Injury to the skin provides a unique challenge, as wound healing is a complex and intricate process. Acute wounds have the potential to move from the acute wound to chronic wounds, requiring the physician to have a thorough understanding of outside interventions to bring these wounds back into the healing cascade.

Recent Advances: The development of new and effective interventions in wound care remains an area of intense research. Negative pressure wound therapy has undoubtedly changed wound care from this point forward and has proven beneficial for a variety of wounds. Hydroconductive dressings are another category that is emerging with studies underway. Other modalities such as hyperbaric oxygen, growth factors, biologic dressings, skin substitutes, and regenerative materials have also proven efficacious in advancing the wound-healing process through a variety of mechanisms.

Critical Issues: There is an overwhelming amount of wound dressings available in the market. This implies the lack of full understanding of wound care and management. The point of using advanced dressings is to improve upon specific wound characteristics to bring it as close to “ideal” as possible. It is only after properly assessing the wound characteristics and obtaining knowledge about available products that the “ideal” dressing may be chosen.

Future Directions: The future of wound healing at this point remains unknown. Few high-quality, randomized controlled trials evaluating wound dressings exist and do not clearly demonstrate superiority of many materials or categories. Comparative effectiveness research can be used as a tool to evaluate topical therapy for wound care moving into the future. Until further data emerge, education on the available products and logical clinical thought must prevail.

SCOPE AND SIGNIFICANCE

THE SKIN IS THE LARGEST ORGAN of the human body with numerous complex functions essential for our survival. Its primary function is to serve as a protective barrier against the environment. It can protect against harmful chemicals, ultraviolet radiation, and pathogenic organisms, while at the same time it can produce vitamin D and regulate body temperature and moisture loss.

Injury to the skin provides a unique challenge, as wound healing is a complex and intricate process. With more than 1.25 million burns in the United States annually¹ and 6.5 million chronic skin ulcers caused by pressure, venous stasis, or diabetes mellitus,² it is no wonder why cutaneous wound healing has become a topic of ongoing research and debate worldwide. Cost-effectiveness of differing modalities in treatment is yet



Aditya Sood, MD, MBA

Submitted for publication December 23, 2012.

*Correspondence: Department of Surgery, Division of Plastic Surgery, UMDNJ—New Jersey Medical School, 140 Bergen Street, Suite E1620, Newark, NJ 07103 (e-mail: asood17@gmail.com).

Abbreviations and Acronyms

CMC = carboxymethylcellulose
 MMP = matrix metallo-proteinase
 MRSA = methicillin-resistant *Staphylococcus aureus*
 NPWT = negative pressure wound therapy
 ORC = oxidized regenerated cellulose
 PHMB = polyhexamethyle biguanide
 RCT = randomized control trial
 VRE = vancomycin-resistant enterococci

another variable in treating these wounds. Chronic wounds account for an estimated \$6–\$15 billion annually in U.S. health care costs.³ The exact costs remain unknown due to difficulty in obtaining accurate measurements because patients are seen in a variety of settings or even fail to access the health care system. There is tremendous pressure on the medical system to develop cost-effective therapies.

Many complicated and delicate interactions are involved in wounds successfully transitioning from an acute inflammatory phase to the subsequent proliferation and remodeling phases. Abnormal wound healing becomes evident when optimized local and systemic conditions are absent, leading to a “nonideal” wound-healing environment. Acute wounds have the potential to move from the acute wound to chronic wounds, requiring the clinician to have a thorough understanding of outside interventions to bring these wounds back into the healing cascade.

TRANSLATIONAL RELEVANCE

The development of new and effective interventions in wound care remains an area of intense research. The roles of inflammatory cells, cytokines, chemokines, and gene regulation have been extensively studied. However, studies are filled with conflicting evidence resulting in a multitude of available products and few randomized controlled trials (RCTs).

In the 1960s, the idea of moist wound healing was introduced, in the 1990s advanced technological products became available at a commercial level, and at the turn of the 21st century tissue-engineered products emerged in the market. Despite the many beneficial advances, the understanding of the mechanisms and pathways involved in normal and abnormal wound healing are limited.

To achieve an effective outcome, certain principles hold universally true. The host environment must be suitable for wound healing. Optimizing blood glucose and supplementing host nutrition, if inadequate, should generally be regarded as the first step in successful treatment. A suitable wound bed that is well vascularized with minimal bacterial burden and little or no exudates is crucial. By re-creation of an acute wound, progression through the normal and well-understood stages of wound healing proceeds. All chronic wounds contain bacteria, but this does not necessarily mean that the wound is infected or that bacteria have impaired wound healing. Some research has even suggested that low levels of bacteria may aid wound healing by producing proteolytic enzymes that help wound

debridement and stimulate release of proteases from neutrophils.⁴ When the number of bacteria reaches critical colonization and moves to infection, wound healing becomes impaired. Wounds must also have a reliable and adequate inflow of oxygen, nutrients, enzymes, and cells in order for healing to occur. Nonviable tissue impedes movement of cells needed to build granulation tissue and this leads back to the importance of wound debridement as a principal intervention. Edema or exudates also prevent cell migration and prevent bactericidal activity of leukocytes.

CLINICAL RELEVANCE

For wounds to heal, they must have consistent and sufficient supply of oxygen, nutrients, enzymes, and cells. Once the mentioned factors are controlled and the wound bed is prepared with adequate debridement and moisture control, wound healing will be ready to progress. Products aimed at achieving a well-prepared wound bed suitable to healing will be discussed in this article with mention of available comparative effectiveness data.

DISCUSSION OF FINDINGS AND RELEVANT LITERATURE

Wound healing, obstacles, and optimization

Abnormal wound healing. The basic elements in wound healing can be described using three sequential and overlapping phases: inflammation, proliferation, and remodeling. Chronic wounds are arrested in a specific phase of wound healing and unable to progress, and those that remain unhealed at ~4 weeks are placed into this category. There are several factors responsible for chronic wounds—namely, age, ischemia, and infection.⁵ In patients deemed complicated or with multiple factors, the body’s innate ability to heal may be impeded.

There has been increasing experimental evidence suggestive of an impaired response by aging cells to stress. Microarray analysis of human fibroblasts from aged patients reveal a baseline increase in expression of stress response genes.⁶ This may reduce cell viability and decrease the ability to upregulate the pathways essential in a normal stress response. Impaired blood flow to a wound bed undoubtedly leads to decreased oxygen, nutrients, and cells. Ischemic wound models on several species have demonstrated a major impairment in wound healing.⁷ Ischemia reperfusion injury has been linked to abnormal tissue healing due to the production of proinflammatory cytokines and oxygen free radicals. Wounds that have reached critical colonization by bacteria also demonstrate a

decreased ability to heal due to the metabolic load imposed by bacteria.

Other local factors such as matrix metalloproteinases (MMPs) also play a role in wound healing. These proteolytic enzymes are present in all wounds and promote cell migration, regulate biologically active molecules, and facilitate the remodeling of extracellular matrices.⁸ In chronic wounds with excessive exudates these enzymes can be overproduced resulting in premature degradation of fibronectin and collagen. Keeping in the mind the principle of managing exudates in wounds can help keep MMPs at an optimal level, reducing chronic inflammation and degradation of essential growth factors.⁹

Bacterial burden. All wounds eventually become hosts to bacteria and are usually contaminated within 48 h. The point at which bacteria have a negative effect on wound healing is still controversial, but the number of bacteria on a wound should be looked as part of a continuum. Wounds can be classified into four groups with reference to bacterial presence. Contaminated wounds have a low number of bacteria that do not replicate. Colonized wounds have microflora adherent to the body's surface, which replicate and form colonies. At this stage, there is no overt host reaction. When a wound is critically colonized, the increasing number of bacteria becomes a bioburden and delay wound healing. At this stage, secondary signs and symptoms of impending infection become present, such as increased serous exudates, friable granulation tissue, a change in color of granulation tissue to bright red, increasing pain at the wound site, increasing or unusual wound odor, and breakdown of the wound caused by deficient tissue. The final stage in the continuum is infection. At this stage bacteria have invaded the tissue, are reproducing, and are causing a host reaction. Classic signs and symptoms include fever, warmth, edema, swelling, pain, erythema, and purulent drainage. Infected wounds will have a density of $> 10^5$ colony-forming bacterial units per cubic millimeter of tissue.¹⁰

The point of intervention with bacterial presence is very case specific, although most experts will agree that once a wound reaches the level of critical colonization or infection, intervention is necessary. The term "bacterial bioburden" represents the metabolic demands placed upon the tissue by the bacteria, including toxic by-products, competition for local nutrients and oxygen, and detrimental effects of the host inflammatory reaction.¹¹ A high level of bacterial bioburden may overwhelm host healing and result in prolongation or stagnation in the inflammatory phase.

Bacteria are known to form a protective polysaccharide coating, especially in chronic wounds, called a "biofilm." This coating goes unrecognized by host defenses and is impermeable to most systemic and topical antimicrobials. It is for this reason that the primary intervention of wound debridement is essential, disrupting this film and allowing permeation of beneficial host cells and interactive materials from dressings.

Wound optimization. As described above, wound optimization involves many variables. The first and most important is viewing and identifying host compromise to healing—including glycemic control and nutritional support if necessary. Revascularization and optimization of blood flow to a wound is critical and it should be performed before implementing advanced wound care methods. Other factors such as edema/exudates, bacterial burden, and nonviable tissue must be addressed with debridement. There are various debridement techniques including sharp or surgical, autolytic, enzymatic, mechanical, or larval therapy. Eliminating external forces of wound compromise including shear forces is equally important. If viable tissue is insufficient or unavailable to form a well-formed wound base, flap reconstruction must be considered.

Before proceeding to use various wound dressings and topical agents, the patient and wound characteristics above must be addressed. For the purposes of this article, we will assume the patient has been optimized in terms of medical comorbidities, nutrition, and blood supply. This assumption generally means that a patient will have controlled blood glucose < 200 g/dL, albumin > 3.0 g/dL, prealbumin level > 15 mg/dL, total lymphocyte count $> 1,500$, cessation of smoking, and a well-vascularized wound bed (in conjunction with either a revascularization procedure or various aggressive debridement techniques to remove nonviable tissue, debris, and bacteria).

Ideal dressings

Since ancient times, many different materials have been used to treat wounds in an attempt to stop bleeding, absorb exudates, and promote healing. Some of these materials consisted of honey, animal oils or fat, cobwebs, mud, leaves, sphagnum moss, or animal dung.¹² Although most of these readily available natural substances would later prove to provide little benefit, others such as honey have been studied and shown to provide some value.

What we do know is that wounds are more susceptible to healing in a moist, clean, and warm environment.¹³ A moist wound bed will allow

Characteristics of an ideal dressing

- Creates a moist, clean, warm environment
- Provides hydration if dry or desiccated
- Removes excess exudates
- Prevents desiccation and is nontraumatic
- Provides protection to periwound area
- Allows for gaseous exchange
- Impermeable to microorganisms
- Free of toxic or irritant particles
- Does not release particles or fibers
- Can conform to wound shape
- Minimal pain during application and removal
- Easy to use
- Cost-effective

growth factors and numerous cell types including epithelial cells to migrate, facilitating wound edge contraction.¹⁴ To create and maintain this environment, appropriate dressings come into play. There are four basic principles involved in choosing an optimal dressing.¹⁵ If a wound proves to be dry or desiccated, it will need hydration. If a wound produces excessive exudates, the fluid needs to be absorbed. If a wound has necrotic tissue or evident debris, it will need debridement. Lastly, if a wound is infected, it needs to be treated with the appropriate antibacterial agent. There are also several other factors that are important when choosing a dressing, such as providing protection to the periwound skin, forming an effective bacterial barrier, conforming to wound shape, producing minimal pain during application and removal, being free of toxic or irritant extractables, not releasing particles or nonbiodegradable fibers into the wound, and maintaining the wound at an optimal temperature and pH. Each set of needs can be met with a corresponding dressing that fits the situation. It is important to remember that as the wound environment changes the dressing also needs to change.

There is an overwhelming amount of wound dressings available in the market. This implies the lack of full understanding of wound care and management. The point of using advanced dressings is to improve upon specific wound characteristics to bring it as close to “ideal” as possible. It is only after properly assessing the wound characteristics and obtaining knowledge about available products that the “ideal” dressing may be chosen.

Dressing descriptions

The standards for early dressings were rather simple and concentrated mainly on product com-

position and structure. In 1982, Lawrence¹⁶ published a review on the structure of dressings and their effects upon wound healing where he implied the importance of dressing design to prevent adherence and fiber loss while providing a degree of environmental control. Early testing of absorbency and dressing specifications were described by Piskozub¹⁷ and Thomas *et al.*¹⁸ As more sophisticated dressings were developed, new standards and test systems were required to prove that these new materials performed a specific function in consistent and reproducible ways. Thomas,¹⁹ in his book on *Surgical Dressings and Wound Management* (2012) discusses the need for dressing standards, describes how these have evolved, and outlines test methods that can be used to assess key aspects of performance in the many different available products.

All interactive dressing materials have the ability to manipulate one or multiple aspects of wound environment. Deciding which to use will depend on matching wound characteristics with dressing capabilities, keeping in mind that the wound characteristics will change in the process likely requiring change in dressing subtype. There are three broad wound-dressing categories, each with a specific goal. The first category of dressings exerts its effects on the tissue itself, facilitating autolytic debridement. Autolytic debridement entails the host's own proteolytic enzymes and phagocytic cells promoting debridement of the nonviable tissue.²⁰ The second category adjusts moisture level of the wound bed. The third category involves controlling the bacterial load. Either combining dressings or using dressings that are multifaceted may allow many of these goals to be met.

The current medical literature continues to be lacking in comparative effectiveness data of specific dressing subtypes. The available data will be presented in conjunction with each dressing subtype to provide the most current evidence.

Gauze. Johnson and Johnson began mass-producing a sterile surgical dressing by sterilizing cotton yarn and thread in 1891, after which time gauze has become the most widely used surgical dressing.²¹ Gauze is undoubtedly familiar to hospital staff, inexpensive, reliable, available, and highly absorbent. Gauze comes in woven and nonwoven forms, with the latter made of synthetic fibers pressed together and having a greater absorbency. It is highly permeable and nonocclusive and can be used as a primary or secondary wound dressing. It is commonly used on both infected and

noninfected wounds, large or irregularly shaped wounds, or in packing strips to prevent premature closure or to keep away exudates (Fig. 1).

Although gauze has proven useful in many situations, clinicians and hospital staff must be aware when use of this material is *not* optimal. Woven gauze requires force to remove, and it can potentially lead to wound trauma and/or mechanical debridement. Residue left behind from woven gauze may allow the body to respond with granulation formation. Kerlix Gauze® (Covidien, Mansfield, MA), or rolled gauze, should be applied without tension to prevent a tourniquet-like effect of tissues.

Although wet-to-dry dressings have gained popularity throughout much of the 20th century for its ability to mechanically debride tissues, many investigations have published reports on the negative aspects of this method. Ovington states, "removal of a wet-to-moist dressing that has dried may then cause reinjury of the wound, resulting in pain and delayed wound healing."²² Gauze dressings have been reported to cause local tissue cooling during the evaporation period in wet-to-dry dressings. This cooling results in reflex vasoconstriction, hypoxia, impaired leukocyte and phagocyte activity, and increased affinity of hemoglobin for oxygen; all of which contribute to impaired wound healing.²² The removal of these dressings when dry also leads to patient discomfort and pain. The mechanical debridement via removal of these dressings can lead to cross-contamination of wounds by dispersion of bacteria into the air upon removal. The nonselective mechanical debridement of healthy adjacent tissue is among another negative aspect of this wound care method. The

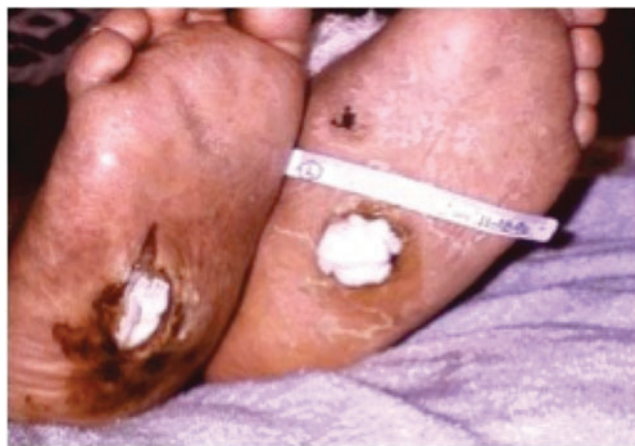

Figure 1. Gauze used as packing in an infected and irregularly shaped wound of the lower extremity. To see this illustration in color, the reader is referred to the web version of this article at www.liebertpub.com/wound

average nursing time and costs per patient may be significantly affected, as this dressing type often requires dressing changes three times a day.

Gauze has also been criticized for its inherent nonocclusive nature. Lawrence²³ demonstrated that bacteria can pass through up to 64 layers of dry gauze in an *in vitro* study. It is permeable to exogenous bacteria and is associated with a higher infection rate than with transparent films or hydrocolloids.^{24,25}

Most of the criticisms with regard to gauze remain theoretical. A somewhat recent (2004) Cochrane Collaboration review of "dressings and topical agents for surgical wounds healing by secondary intention" revealed a paucity of RCTs demonstrating a statistically significant difference between dressings when the primary end point was time to wound healing.²⁶ More data are needed on this subject.

Impregnated gauze. Gauze dressings are also available impregnated with substances such as petroleum, iodine, bismuth, and zinc. The impregnated materials help make these dressings nonadherent and moderately occlusive. They add moisture to the wound bed and facilitate wound healing by decreasing trauma and preventing desiccation during dressing changes. They can function well as nonadherent primary dressings or used as a contact layer on granulating wound beds combined with secondary gauze dressings (Fig. 2A). They are commonly used on skin graft donor sites as a single layer and as the primary dressing overlying the actual skin graft (Fig. 2B). Impregnated gauze is also commonly used on burn wounds because of its pain-free removal (Fig. 2C).

Semiocclusive dressings such as impregnated gauze decrease moisture loss from the wound, preventing local cooling and its negative associated effects,²² as described above. It must be taken into consideration that bismuth, present in many preparations, is cytotoxic to inflammatory cells and may cause an increased inflammatory response. It is for this reason that bismuth-containing compounds are not advisable for patients with venous insufficiency ulcers. Iodine-impregnated gauze is also cytotoxic and only mildly antimicrobial. It is indicated for tunneling wounds with foul discharge, but it must be frequently changed and limited to <5 days due to its tissue destructive nature. Recent studies have shown that semiocclusive dressings do not lead to a reduction in costs and wound healing time compared with gauze dressings for surgical patients.^{27,28} Essentially, the savings from less frequent dressing changes (with occlusive or semi-

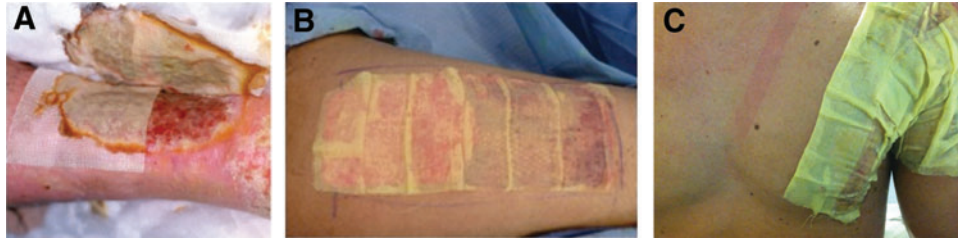

Figure 2. (A) Adaptic Gauze® (Johnson and Johnson, New Brunswick, NJ) used as a contact layer on a granulating wound bed of the lower leg combined with a compressive dressing. Removal shows nonadherent nature of dressing and facilitation of intrinsic healing. (B) Xeroform Gauze® (Covidien) used as the primary dressing over a split-thickness skin graft donor site on the lateral thigh. (C) Xeroform Gauze used as a contact layer on second- and third-degree burns of the chest and arm. To see this illustration in color, the reader is referred to the web version of this article at www.liebertpub.com/wound

occlusive dressings) do not balance the higher costs of these materials. Lastly, impregnated gauze does not absorb exudates and therefore does not have a role in wounds with a heavy drainage.

Transparent film dressings. Transparent film dressings are thin flexible transparent sheets with adhesive backing, composed of polyurethane or copolyester. They are permeable to water vapor, oxygen, and carbon dioxide but impermeable to bacteria and water. They provide a moist healing environment and promote autolytic debridement. They do not have any absorptive capabilities and therefore do not have a role in wounds with excessive exudates. This material should not cover infected wounds because bacteria have an ideal environment to multiply without adequate drainage.

Transparent films are commonly used to cover primarily closed surgical incision sites, superficial wounds with minimal exudates, skin graft donor sites, intravenous catheter sites, and areas of friction (Fig. 3). When film dressings were compared with other modalities including paraffin gauze and foam dressings in a prospective randomized study involving 80 patients undergoing elective split-thickness skin grafting, there were no dressing-dependent differences in healing rates detected at 14 days, but polyurethane film was shown to be more comfortable in use and easier to remove.²⁹ Many earlier studies reported improved healing rates and greatly reduced pain in treating skin graft donor sites.^{30,31} Although transparent films do not have any exudative management capabilities, they are still widely used for the purpose of covering skin graft donor sites. When excess exudates do arise under the treated areas, this can be managed with release of the exudates and subsequent patch coverage with another transparent film. Film dressings have also been used following primary closure in surgery or for wounds left to heal by secondary intention. Rubio³² used three

different film dressings as a protective cover for 3,637 surgical incisions over 8 years. He concluded that films resulted in faster wound healing, decreased pain, less scarring, visual wound assessment, and promoted patient mobility and hygiene.

Foam dressings. Foam dressings are made from a polyurethane base and are permeable to both gases and water vapor. Their hydrophilic properties allow high absorptive properties while they also provide thermal insulation. These highly versatile dressings are indicated for wounds with moderate-to-heavy exudates, granulating or slough covered partial and full-thickness wounds, donor sites, ostomy sites, minor burns, and diabetic ulcers. They are not recommended in dry or eschar covered wounds and arterial ulcers due to their ability to dry wounds further. They can be left in place for up to 4–7 days, but should be changed once saturated with exudates. Their composition makes them atraumatic upon removal. If changed daily, they can also be used on infected wounds.³³

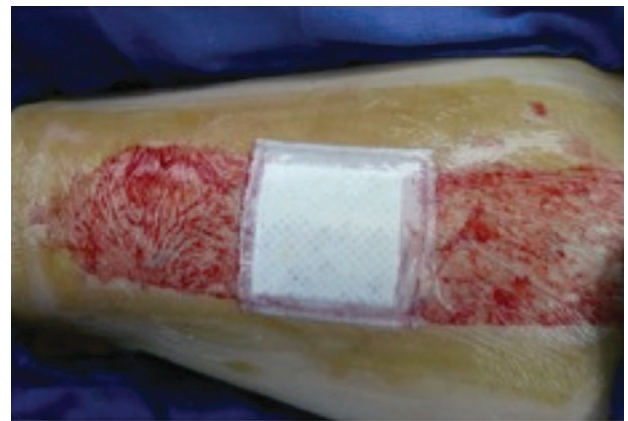


Figure 3. Tegaderm® (3M, St. Paul, MN) used as a primary dressing over a split-thickness skin graft donor site of the lateral thigh. To see this illustration in color, the reader is referred to the web version of this article at www.liebertpub.com/wound

Different types of foam dressings have been compared in numerous publications, mainly due to their affinity for liquid and/or permeability to moisture vapor. These properties may make certain foams more appropriate for treatment of lightly exudative wounds versus excessively draining wounds. Anderson *et al.*³⁴ conducted an RCT to compare the effectiveness of Allevyn (Smith and Nephew, London, United Kingdom) versus Biatain (Coloplast, Humblebaek, Denmark) in the management of lower leg ulcers. Of the 118 patients, 76% had excellent absorbency rated during dressing changes with Biatain, versus 7% with Allevyn. Noting the presence of leakage at weekly assessment and requirement of using secondary absorbent layers supported these results. Statistically fewer dressing changes per week were required in wounds dressed with Biatain (2.14 vs. 3.34), which resulted in lower treatment costs (\$10.87 vs. \$18.99) in favor of Biatain. Data comparing foam dressings to other modalities in the treatment of highly exudative modalities are lacking to date.

Hydrogels. Hydrogels are complex hydrophilic organic cross-linked polymers, consisting of an 80%–90% water base. These gels are available in a free-flowing amorphous or fixed flexible sheet form (Fig. 4). They can absorb a minimum amount of fluid by swelling, but they also can donate moisture to a dry wound, thereby facilitating autolytic debridement and maintaining a moist wound environment that is thermally insulated. They have also been shown to promote granulation and epithelialization and reduce the temperature of a wound bed by up to 5°C.^{35,36} They are permeable to gas and water and have proven to be a less effective bacterial barrier than occlusive dressings. The main application of these dressings is hydrating dry wound beds and softening and loosening slough and necrotic wound debris. They are unable to absorb heavy drainage due to their high water concentration; they absorb very slowly and therefore are not useful on bleeding wounds, and they generally require a secondary dressing. They can be used on a variety of wounds including pressure ulcers, partial and full-thickness wounds, and vascular ulcers. Maceration can be of concern, as periwound skin areas need to be protected from excess hydration. Among its benefits, hydrogels can be used in conjunction with topical medications or antibacterial agents. The fixed form of hydrogels should not be used in infected wounds. Hydrogels need to be covered with secondary dressings while remaining in place for up to 3 days.

In 1990, Darkovich *et al.*³⁷ compared Biofilm® (B.F. Goodrich, Akron, OH), a hydrogel dressing,

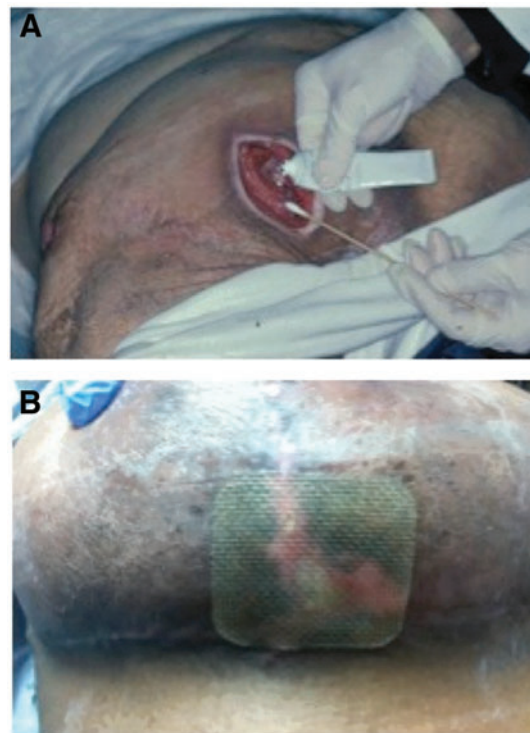

Figure 4. (A) Regranex® (Healthpoint Biotherapeutics, Arlington, TX), a platelet-derived growth factor therapy that utilizes an amorphous hydrogel as a vehicle for its active ingredient, being applied to a sacral decubitus ulcer. (B) Flexigel (Smith and Nephew) hydrogel flexible sheet dressing applied to a nonhealing wound of the lower breast. To see this illustration in color, the reader is referred to the web version of this article at www.liebertpub.com/wound

with Duoderm® (Convatec, Skillman, NJ), a hydrocolloid, in an RCT involving 90 patients with 129 pressure ulcers. Sixty-two wounds were treated with hydrogel and 67 with the hydrocolloid for a maximum of 60 days. About 90% of the hydrogel-treated wounds and 78% of the hydrocolloid improved during the treatment while nearly double the amount of wounds actually healed with hydrogel (43% vs. 24%). In 2005, Kaya *et al.*³⁸ compared hydrogel with gauze soaked in povidone-iodine solution, in a prospective study involving 27 spinal cord injury patients with a total of 49 pressure ulcers. The number of wounds that healed in the two groups was 84% with hydrogel versus 54% with gauze and was statistically significant ($p < 0.04$). The authors of this study concluded that hydrogel dressing facilitated healing of pressure ulcers by promoting more rapid epithelialization.

Hydrocolloids. Hydrocolloid dressings contain an inner layer that is self-adhesive, gel forming, and composed of hydrophilic colloid particles such as carboxymethylcellulose (CMC), pectin, gelatin, or an elastomer. This layer absorbs exudates and

swells into a gel-like mass over the wound. This allows for a moist healing environment and also provides thermal insulation to the wound bed. The outer layer, which usually consists of polyurethane, seals and protects the wound from bacteria, foreign debris, and shearing. These dressings are available in a variety of sizes/shapes and also come in a paste, powder, or granule form. The effectiveness of these dressings lie in their ability to provide a moist healing environment, prevent contamination, promote autolytic debridement, and not require a secondary dressing. They can remain in place for up to 7 days or until drainage is noted from beneath the dressing. They are indicated for partial and full-thickness wounds with low-moderate exudates, granular and necrotic wounds, minor burns, and pressure ulcers. They must be avoided in clinically infected wounds. Caution should also be taken in fragile periwound skin as the adhesive may cause further damage.

Varghese *et al.*³⁹ attempted to compare the local environment of chronic wounds under hydrocolloid versus film dressings who examined fluid collected from 9 patients with 14 chronic full-thickness ulcers dressed with Duoderm or Opsite[®] (Smith and Nephew), a transparent film dressing. They found that pO_2 was very low beneath both dressings despite the relative permeability of film dressings. They also found that pH of the wound fluid beneath the hydrocolloid was more acidic, postulated to be due to the chemical nature of the hydrocolloid base. It was thought that this acidic fluid has an inhibiting effect on the growth of some bacteria, and reduces the histotoxicity of ammonia produced by enzymatic breakdown. Many subsequent studies looked into fibrinolytic activity of hydrocolloid, much of which has been refuted.⁴⁰

Since hydrocolloids were first developed, many animal and clinical studies have been conducted comparing them to film dressings. In 1991, Chvapil *et al.*⁴¹ compared the effect of eight dressing regimens on the rate of epithelialization of 92 split-thickness wounds on pigs. Inflammatory changes, moderate or severe, were induced by dressings such as collagen sponge, polyethylene glycol, Duoderm, and lanolin ointment. The same wounds also re-epithelialized significantly faster than the controls (gauze-covered wounds). They hypothesized that wound dressings that induce an inflammatory reaction thereby enhance healing by activating cells such as macrophages or fibroblasts that produce growth factors and mediators of the repair process. In 1992, Gokoo and Burhop⁴² compared healing rates of Duoderm with Clearsite[®] (ConMed, Utica, NY), a hydrogel sheet dressing, on

eight full-thickness circular surgical wounds produced on the backs of four micropigs. The hydrogel dressing showed a more rapid rate of closure and re-epithelialization versus the hydrocolloid. Histological examination of the same wounds confirmed larger numbers of vacuoles and foam cells in the hydrocolloid-treated wounds compared with hydrogel. Subsequent studies have implied that there is extensive incorporation of the hydrophobic dressing material from the hydrocolloid dressings, which may cause the wound bed to be less suitable for epithelial migration during acute secondary wound healing.⁴³

Alginates. Alginates are yet another dressing for clinicians to use in highly exudative wounds. They contain alginic acid from seaweeds and are covered in calcium/sodium salts. These dressings are highly absorbent, nonadherent, biodegradable, contain nonwoven fibers derived from brown seaweed, and may contain controlled-release ionic silver. When placed on a wound, sodium and calcium ions interact with serum to form a hydrophilic gel. Alginates are useful because they allow formation of a moist wound environment, are highly absorptive, and can prevent microbial contamination.

Alginates are capable of absorbing 20 times their weight; although this may vary depending on a particular product. These dressings are particularly effective for managing highly draining wounds, pressure/vascular ulcers, surgical incisions, wound dehiscence, tunnels, sinus tracts, skin graft donor sites, exposed tendons, and infected wounds. Alginates have also been implied to have hemostatic properties that make them useful on bleeding wounds. These dressings are contraindicated for dry wounds as they readily promote absorption and have no hydration qualities. In clean wounds, they may be kept *in situ* for up to 7 days or until the gel loses its viscosity. For infected wounds, alginate dressings should be changed daily.

The majority of alginate dressings are produced in sheet form, which is beneficial for superficial wounds, but also available in the form of a ribbon or rope,⁴⁴ useful for packing deep wounds and cavities. There have been many reviews published on alginate dressings and a literature search reveals many references to their use.

In an RCT, Cannavo *et al.*⁴⁵ compared three different dressing materials in the management of 36 cases of abdominal wound dehiscence. The dressings included an alginate; gauze moistened with 0.05% sodium hypochlorite solution, and a combined dressing pad consisting of an absorbent pad with addition of a semipermeable film dress-

ing. The healing rates between the three groups did not prove to be statistically significant. Pain was significantly greater ($p=0.011$), satisfaction significantly lower, and costs generally higher in the sodium hypochlorite group. The authors implied that based on these results the use of sodium hypochlorite dressings for surgical wounds be abandoned. Studies to assess performance of alginate and film dressing combinations have also been performed,⁴⁶ with results largely pointing to the effectiveness of this combination approach for moist chronic wounds that produce low-to-moderate levels of exudates. The first RCT involving alginates was carried out as a Drug Tariff reimbursement study.⁴⁷ Sixty-four community patients with leg ulcers were treated with Sorbsan[®] (UDL, Rockford, IL), an alginate, or paraffin gauze dressings. Sorbsan showed a 31% healing rate during the course of study versus 4% for ulcers treated with tulle. Overall, 73% of patients in the Sorbsan group showed evidence of improvement during the trial, indicated by a reduction in wound area versus control. This study was criticized mainly due to lacking of a sustained graduated compression.^{48,49} The effect of application of alginates to skin graft donor sites have also been heavily studied, many alluding to significantly better healing and reduced pain as compared with controls with paraffin gauze.⁵⁰

Although a substantial number of alginate dressings are used annually, there are few publications producing statistically significant evidence to justify their use in any particular type of wound environment. Randomized trials performed have often produced conflicting evidence. It must be realized that the secondary dressing used in conjunction with alginates has much to do with their performance. An absorbent pad may be necessary for heavily exuding wounds while a semipermeable film or foam may be more practical for lightly exuding wounds. Pirone *et al.*⁵¹ compared two types of alginate dressings covered with either polyurethane film or gauze with a hydrocolloid dressing in partial thickness wounds on pigs. Their results alluded to the fact that the healing rate was related to the moisture-retaining properties of the dressing system. Healing was significantly diminished beneath alginate and gauze, leading the authors to suggest that alginates should not be used on dry wounds or under gauze dressings. Thomas,¹⁹ in his book *Surgical Dressings and Wound Management* (2012), alludes to three factors that need to be considered, including chemical nature of the alginate, the amount of fiber implanted, and the vascularity of the tissue at the site of implantation.

Hydrofibers. Hydrofiber dressings made from sodium CMC and interact with serum or exudates to form a gel. In 1997, Convatec Ltd. launched the brand name Aquacel[®], consisting of 100% CMC fiber. Hydrofibers are structurally similar to alginates and have many of the same properties. They are comfortable, easy to remove, and are amenable to heavily exuding or infected wounds (Fig. 5). Hydrofibers have been proven to be effective in reduction of MMP and bioburden levels due to their highly absorptive nature. They have also been combined with silver in Aquacel Ag[®]. These dressings may be left in place for up to 3–7 days or until saturated.

The marked similarities in appearance and physical properties of Aquacel and alginate dressings suggest that they will have a similar range of indications; specifically, highly exudative and/or infected wounds. Several studies have been performed comparing these two materials. Robinson⁵² performed an RCT multicenter leg ulcer study that compared Aquacel with Sorbsan involving 132 patients for 84 days. A significant preference was reported for Aquacel in terms of its ease of appli-

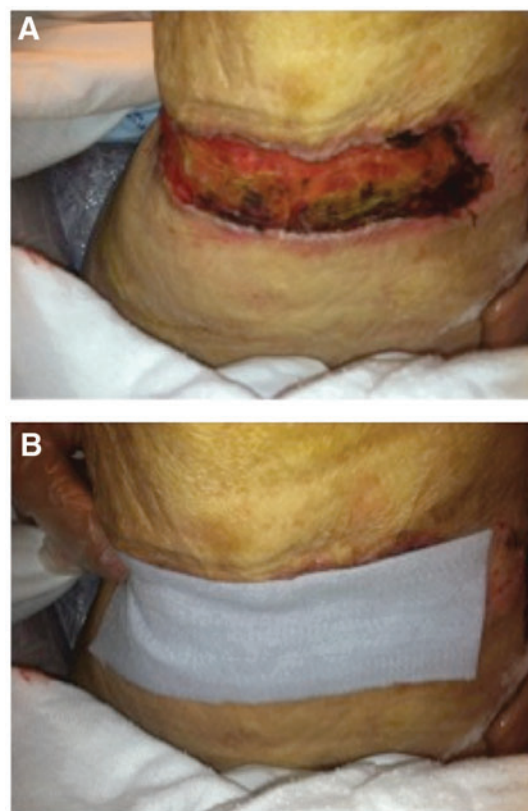


Figure 5. (A) A chronic nonhealing wound of the posterior upper thigh. (B) Same wound covered with Aquacel prior to placement of a secondary compressive dressing. To see this illustration in color, the reader is referred to the web version of this article at www.liebertpub.com/wound

cation and removal, an increased interval between dressing changes, and decreased treatment costs. The use of hydrofibers in treatment of split-thickness skin graft donor sites was examined by Barnea *et al.*⁵³ He compared hydrofibers with paraffin gauze dressings in a study involving 23 patients, in which half of the donor site was covered with Aquacel and the other with paraffin gauze. The Aquacel-treated wounds produced significantly less pain and healed more rapidly according to the study, with a superior cosmetic appearance noted at 1 year. Studies on burns revealed that CMC could be considered for partial thickness and small burns but allograft skin was to be preferred for larger burns of mixed depth.⁵⁴ Cost-analysis studies of treating wounds with Aquacel or gauze was compared using a theoretical model by Guest and Ruiz,⁵⁵ who calculated probable cost advantages associated with CMC due to reduced nursing costs associated with a lower frequency of dressing changes in comparison to gauze.

Hydroconductive dressings. Hydroconductive dressings (SteadMed Medical's Drawtex[®], Fort Worth, TX) are a relatively new and novel class of products introduced at the Symposium on Advanced Wound Care in Spring of 2011. These dressings provide a capillary action that lifts and moves exudates away from a wound into the core of the dressing from where it disperses into a second layer. They also have the additional benefit of moving debris from the wound surface. Levafiber[™], the proprietary name of the Drawtex dressing technology, utilizes two types of absorbent, cross-action structures that facilitate the ability to move large volumes of exudates and debris through the dressing. These dressings can move fluid in a horizontal or vertical vector into the dressing and hold up to 30–50× of its own weight. The hydroconductive debridement component helps to lift and loosen adherent slough tissues, allowing for easy removal when the dressing is changed. These dressings are versatile and can be tailored to fit different sizes and shapes. The material does not shed fibers or break apart and can be utilized for a 7-day wear time.

Over the past year, much investigation has been done on the many actions of this hydroconductive dressing. Drawtex has demonstrated in multiple RCTs to decrease wound exudate, decrease tissue bacterial levels, decrease nutrients for biofilm production, decrease MMPs, facilitate wound bed preparation, aid in burn wounds, and serve as a possible alternative to negative pressure wound therapy (NPWT). Ortiz *et al.* presented the first *in vitro* experiments in an infected burn wound

model, demonstrating a significant reduction in bacterial counts in methicillin-resistant *Staphylococcus aureus* (MRSA)-containing media that had Drawtex submerged in it, while simultaneously showing a significant increase in bacteria in the Drawtex material itself. A protein assay also demonstrated significant reduction in protein concentration over time in solutions containing Drawtex, suggesting the capability of this material to absorb other proteins such as virulence factors in a wound environment.⁵⁶ In a chronic wound model, Ochs *et al.* demonstrated decreasing bacterial levels to $<10^2$ colony-forming units per gram, decreasing MMP-1 and MMP-9 levels, while simultaneously measuring increased levels in the Drawtex material itself. These data suggest that hydroconductive dressings have the ability to draw bacteria and deleterious cytokines from wound tissue into the dressing.⁵⁷ In a published series of eight patients using independent digital wound analysis, the average area of necrotic tissue, fibrin, and slough of all the patients were reduced by 36% in week 1, 52% by week 2, and 77% in 3 weeks.⁵⁸ There was also a corresponding reduction in wound area of 15% in 1 week, 35% by week 2, and 47% by week 3. Wolcott and Cox performed a study on 10 patients with nonhealing, moderate to highly exudative venous leg ulcers in a small cohort study. Drawtex dressings were applied with a multilayer compression wrap. Nine of 10 patients showed a 40% or more healing within the 4-week duration of the study. Polymerase chain reaction methods were used to quantify the amount of bacteria on the wound pre- and post-treatment. Their study demonstrated that the rapid removal of wound exudate speeds healing and suppresses biofilm activity, although there did not seem to be a correlation between the reduction of wound biofilm and wound healing. They concluded that the ability of the hydroconductive dressing to rapidly remove wound exudate improves wound healing, but not by the mechanism of reducing the number of bacteria present.⁵⁹

Hydroconductive dressings have already begun to suggest multiple uses and benefit a variety of wounds. With the innate ability to absorb high-protein fluid from the wound bed, the ability of bacteria to survive is affected. With further research into this material and RCTs, Drawtex may further prove to be an attractive alternative to currently available methods of wound treatment.

Oxidized regenerated cellulose and collagen. Oxidized regenerated cellulose (ORC) is a bioabsorbable topical hemostatic woven material used to control bleeding. It has been used as a surgical and

dental hemostat for almost half a century, proving to be efficacious at controlling capillary, venous, and small arterial bleeding in various settings. When applied to a bleeding surface, it forms a gelatinous mass, which eventually is absorbed within 2–7 days. ORC may also exert moderate bacteriostatic effects *in vitro* due to creation of an acidic pH.⁶⁰

Hofman *et al.*⁶¹ conducted a small-scale, 12-week pilot study involving Traumacel (Synapse Medical, Dublin, Ireland), the calcium salt of oxidized cellulose, on 11 patients with 15 nonhealing leg ulcers. Five ulcers healed within the study period and three patients reported significant pain relief. The authors concluded that the treatment was safe in management of chronic wounds and appeared to promote healing in some recalcitrant ulcers. The same authors undertook a study to determine the effect of Traumacel P[®] powder on human dermal fibroblasts *in vitro*.⁶² At concentrations of 0.5 and 1.0 mg/mL, they found stimulation in metabolic activity of fibroblasts in a variety of growth media and concluded that direct stimulation of fibroblast proliferation may be a mechanism in which this material facilitated healing of ulcers reported earlier.

ORC can also be manufactured in combination with a collagen matrix. Collagen is a major protein of the body and necessary in wound healing and repair. Commonly, 55% bovine collagen is combined with 45% ORC. In the presence of exudates, this dressing transforms into a gel matrix and binds to MMPs to help inactivate some of these overproduced enzymes. A study comparing ORC/collagen dressing with hydrocolloid in a rat model demonstrated a statistically significant increased rate of reepithelialization in the ORC/collagen group.⁶³ Decreased skin cell apoptosis, increased local growth factor concentrations and accelerated wound healing in full-thickness excisional wounds in the ORC/collagen group from this study.

Silicone dressings. Abnormal wound healing, as described earlier in this article, can lead to a hypertrophic or keloid scar. Historically, these have often been treated with long-term application of pressure garments. In 1981, it was found that the benefits of pressure therapy could be enhanced or replaced by applying a sheet of silicone gel made from polydimethylsiloxane (Fig. 6). This would relax or soften scar tissue and thereby allow a leveling effect on the hypertrophied area.⁶⁴ The mechanism of action of silicone gel sheeting is not fully understood at this point in time. A popular hypothesis involves the altered local environment created under the silicone

sheet in which decreased vapor loss allows hydration of the scar. Capillary and fibroblast activity are reduced and collagen deposition decreased, with a net result of a less hypertrophic scar.⁶⁵

In several published studies, silicone sheeting subjectively was shown to stop development of hypertrophic scars and to soften existing scars in certain populations. De Oliveira *et al.*⁶⁶ compared silicone with nonsilicone gel dressings in a controlled prospective trial in treatment of keloids and hypertrophic scars. Compared to the untreated controls, all of the measured parameters including scar size and induration were reduced in both silicone and nonsilicone-treated groups. The authors concluded that both treatments were equally effective in the treatment of keloids and hypertrophic scars. Silicone sheeting has also decreased the incidence of new hypertrophic scarring when applied to surgical wounds ~2 weeks postoperatively in high-risk populations.⁶⁷

Unfortunately, most of the studies evaluating silicone gel suffer from several shortcomings:

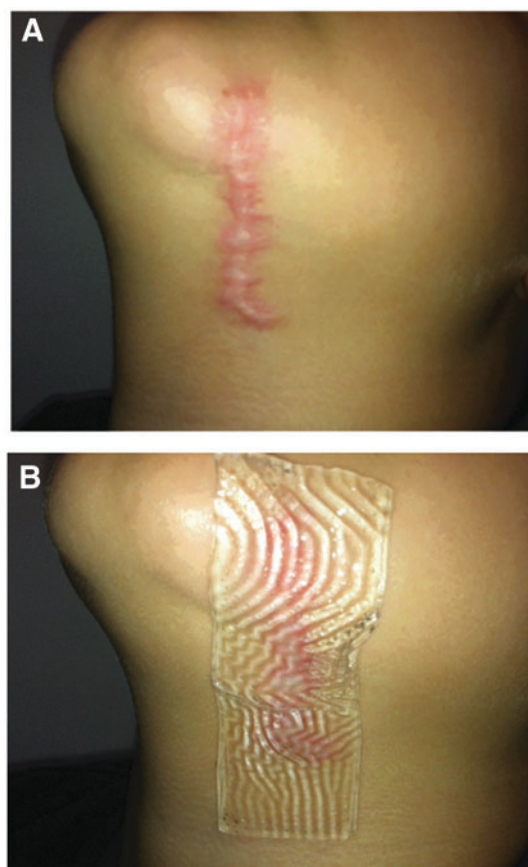


Figure 6. (A) A hypertrophic scar extending from the lower border of the mandible to the neck. (B) Cica-Care (Smith and Nephew) silicone sheet applied to this wound. To see this illustration in color, the reader is referred to the web version of this article at www.liebertpub.com/wound

small sample size, lack of controls and other methods of treatment, and short follow-up times. A number of formal reviews of the use of silicone gel sheet and other agents in the management of hypertrophic and keloid scars have been published. Three concluded that there appeared to be some benefits associated with the use of silicone gel although with weak evidence,^{68–70} one suggested that surgical excision followed by postoperative intralesional steroid injection seemed to provide a reasonable treatment outcome,⁷¹ one recommended a polytherapeutic strategy for scar management,⁷² and one concluded that insufficient information was available for clinicians to make informed decisions.⁷³ There has been an increasing trend to use silicone as a nontraumatic adhesive component in many existing dressing categories to reduce procedural pain associated with dressing changes. Silicone is inert, and therefore does not chemically interact with the wound or have any effect upon the cells responsible for healing, but rather due to the ease of removal of soft silicone, it does not traumatize the wound or the surrounding skin.

Silver dressings. The use of topical antimicrobials in wounds is filled with controversy. Concern over bacterial resistance has led to a revived interest in silver-based agents. Silver has been used in medicine for its antimicrobial properties for thousands of years. John Woodall first documented its use in surgical patients in 1617 in *The Surgeons Mate*. Today, silver is commonly used in numerous dressings and topical agents. Silver is a broad-spectrum antimicrobial agent that is effective against bacteria, fungi, viruses, and yeast. It has also been proven to be active against MRSA and vancomycin-resistant enterococci (VRE) when used at an appropriate concentration.⁷⁴ It has also been known that silver reduces inflammation of wounds and promotes healing. The concentration of silver needed to exert a bacteriostatic or bacteriocidal effect depends on the local wound environment.⁷⁵ It has proven to be effective against superficial pathogens but may not affect bacteria that have penetrated a significant distance into the wound bed. Therefore, silver is indicated for mild wound infections in which it may be used to help decrease the bacterial count when colonization or critical colonization is suspected.⁷⁶

Silver cations are released from their carrier dressings upon contact with fluid. The rate, duration, and peak level of silver released greatly varies depending on the dressing used. Once released, silver acts to destroy bacteria in multiple ways. It

disrupts bacterial cell walls, inactivates bacterial enzymes, and interferes with bacterial DNA synthesis. Due to its multi-mode of action, widespread bacterial resistance has yet to be documented, although reports of isolated *Escherichia coli* and *Pseudomonas aeruginosa* have shown resistance to silver *in vitro*.⁷⁴ This is especially problematic if the minimum inhibitory concentrations of silver are not maintained in contaminated wounds.

Although multiple *in vitro* studies have been performed on simulated wound fluid in the laboratory, *in vivo* studies are lacking. Because of factors such as presence of a biofilm, mixture of multiple bacterial species, tissue proteins, and anions, silver dressings *in vivo* may not achieve the results seen *in vitro* studies. In a fairly recent review by the Cochrane Collaboration, the effect of topical silver and silver dressings on wound healing in contaminated and infected wounds was evaluated.⁷⁷ Only three RCTs met the inclusion studies. Most of the studies comparing silver-containing dressings with other treatment modalities found no significance in the rate of complete healing. Of the studies analyzed, one demonstrated a statistically significant reduction in relative wound size in the silver-treated group,⁷⁸ another reported a statistically significant advantage of silver as reflected in the wound-healing rate (cm²/day) over 4 weeks,⁷⁹ and the third reported that the relative wound size reduction was statistically faster in the treatment group.⁸⁰ None of the studies examined duration of wound infection, and the conclusion of the Cochrane Collaboration was that there is insufficient evidence to recommend the use of silver containing dressings or topical agents for treatment of infected or contaminated wounds. It is due to the lack of studies that clinicians must make assumptions about superiority of silver dressings based on *in vitro* results.⁸¹

Even with a lacking of quality *in vivo* evidence, silver is available in many preparations (Fig. 7). It is manufactured in combination with almost every available dressing type, including cream, alginates, collagens, hydrofibers, negative pressure sponges, films, hydrogels, foams, and hydrocolloids.⁷⁶ Active or ionic silver is released at different rates and durations depending on delivery system chosen. The minimum concentration of silver for most clinically relevant bacteria is between 5 and 50 ppm. The various dressings deliver silver levels within a very large range. In addition, *in vivo* wound environments are much more complex than those simulated in the lab, with bacterial biofilms and host proteins likely reducing the total delivery of silver ions to the bacteria. Without further in-

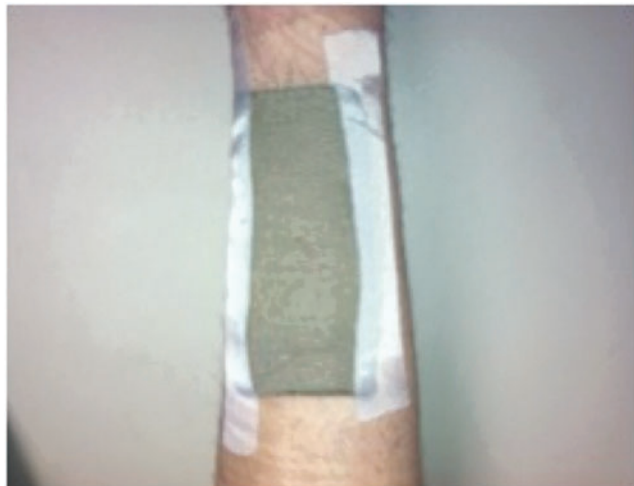

Figure 7. A silver-impregnated dressing used to cover a chronic lower extremity wound. To see this illustration in color, the reader is referred to the web version of this article at www.liebertpub.com/wound

investigation and clinical data, only assumptions can be made in regard to which formulations and dressings with silver work best.

Polyhexamethylene biguanide and honey dressings. There are several other well-known antimicrobial dressings that have been on the market for years. Polyhexamethylene biguanide (PHMB) is an antiseptic that is currently attracting interest from wound care professionals, although it has a long history of use in things such as contact lens cleaning solutions, wet wipes, and others. PHMB is available both as a cleansing solution and in biocellulose dressings. In a concentration of 0.3%, it has proven to be both noncytotoxic and a nonirritant, with a very low risk of sensitization.⁸² It has also been found to be effective against a broad spectrum of bacteria, fungi, molds, yeasts, MRSA, and VRE. Eberlein *et al.* compared treatment with a PHMB containing biocellulose wound dressing versus silver dressings in 38 critically colonized or locally infected wounds.⁸³ Compared with the silver-treated group, the PHMB-biocellulose group had a significantly faster reduction of critical colonization and local wound infection ($p < 0.001$) in the 28-day study period. Both groups were effective in reducing pain and bacterial burden; however, the PHMB group was significantly faster and better in removing the critical bacterial load.

Manuka honey is an ancient remedy for the treatment of infected wounds and was first recognized as a topical antibacterial agent in 1892. Since this time, there have been many published reports describing the effectiveness of honey products in

wound healing. In laboratory studies, Manuka honey has been shown to provide antibacterial action against a broad spectrum of bacteria and fungi, including *S. aureus*, *P. aeruginosa* MRSA, and VRE.⁸⁴ Published reports have recognized that honey can inhibit biofilms of various species. Honey may also have a role in reducing malodor, providing an autolytic debridement environment whereby the osmotic action of honey encourages exudates to move away from the wound bed, and having an anti-inflammatory and immune-modifying effect. Gethin and Cowman conducted a prospective, multicenter RCT to compare the desloughing efficacy and healing outcome in venous ulcers with Manuka honey versus hydrogel.⁸⁵ At week 4 of treatment, the mean reduction in slough was 67% with Manuka honey versus 52.9% with hydrogel ($p = 0.054$). Mean reduction in wound size was 34% versus 13% ($p = 0.001$). At 12 weeks, 44% versus 33% healed ($p = 0.037$). The Manuka honey group had an overall increased incidence of healing, effective desloughing, and a lower incidence of infection than the control (hydrogel). This study helps to confirm that Manuka honey may be considered for use in sloughy venous ulcers. Gupta *et al.* compared honey dressings versus silver sulfadiazine dressings for wound healing in burn patients in a retrospective study.⁸⁶ The average duration of healing was found to be 18.16 versus 32.68 days in the honey and silver sulfadiazine groups, respectively. All wounds treated with honey became sterile within 21 days, while for silver sulfadiazine this was 36.5 days. The authors concluded that honey dressings make the wounds sterile in less time, enhance healing, and have a better outcome in terms of hypertrophic scars and postburn contractures.

Both of the materials examined above have proven to be efficacious versus silver in published studies. The type of wound must be taken into consideration when contemplating use of these agents, as not all wounds are amenable to treatment.

Iodine dressings. Iodine is a natural, nonmetallic element that plays a key role in human metabolism. The antimicrobial properties of this element were first demonstrated in 1882.⁸⁷ Since this time, iodine-based preparations have played an important role in the prevention of surgical site infections. Iodophors were developed in the 1950s to overcome the side effects associated with elemental iodine, including pain, irritation, and skin irritation. Bonding iodine with another molecule makes it less toxic and able to be slow released from the carrier molecules over a more sustained period

of time. The two most commonly used iodophors in modern dressings include povidone-iodine and cadexomer iodine. Povidone-iodine preparations, introduced in the 1960s, are popularly used as an antiseptic in preparing patient's skin before surgery as in preoperative hand scrubs.

There is extensive evidence in support of using povidone-iodine in wound healing but this has been met with controversy due to perceived issues with toxicity, systemic absorption, and delayed healing. Numerous reviews have analyzed the conflicting evidence and cited that studies on animal models tend to support the argument for iodine's cytotoxicity while human studies suggest that povidone-iodine preparations can help the wound-healing process by reducing bacterial load.^{88,89} The mode of action is not understood but it is believed to be associated with its ability to rapidly penetrate the cell wall of microorganisms.⁹⁰ Nonetheless, povidone-iodine and cadexomer iodine have been proven in numerous *in vitro* studies to be effective in common bacterial wound isolates as well as MRSA infections.

The effectiveness of iodine in the management of bacterial biofilm is currently unclear, although studies have cited that low-dose, slow release iodine is effective in killing free-floating microorganisms and is therefore a good choice of antiseptic dressing when the intention is to suppress biofilm formation or prevent recontamination.^{91,92} Thorn *et al.* studied the antimicrobial effectiveness of silver- and iodine-containing wound dressings against preformed mature biofilms of pathogenic wound bacteria grown *in vitro*,⁹³ and demonstrated that both dressings exerted an antimicrobial effect against the target species biofilms, although the iodine dressing was more efficacious under the experimental conditions employed. Similar results from Phillips *et al.* also suggest that sustained release iodine may penetrate biofilms more effectively than silver or PHMB.⁹⁴

Slow release iodine dressings are indicated in a wide range of wound types where infection is present or suspected. These wound types include pressure ulcers, venous leg ulcers, diabetic foot ulcers, minor burns, and superficial skin-loss injuries. These dressings should be used under close medical supervision in patients with thyroid disease, iodine sensitivity, pregnant or breastfeeding women, or in newborn babies. To avoid toxicity or risk of thyroid-related complications, iodine products should be used in caution in children, in patients with large burn areas, and when prolonged treatment of large open wounds may be required. Generally, when the dressing has lost its color, the

antiseptic effect has been lost and the dressing should be changed.

Although speculation exists in regard to iodine delaying healing and being cytotoxic, substantial evidence also exists to suggest that the commonly used low concentration and slow release iodophors can improve healing rates and are effective as highly potent antimicrobial with a broad spectrum of activity. The studies and methods of design of several studies make it difficult to draw reliable comparison and conclusion of this dressing type.

Charcoal dressings. The key function of activated charcoal dressings is to reduce wound odor by absorbing gases released by bacteria. They have a large surface area and can absorb odor molecules and therefore act as a deodorizing agent. It is difficult to accurately measure and quantify wound odor and it is therefore highly subjective in nature. Wounds that are most commonly associated with odor production include leg ulcerations and fungating lesions of various types. The organisms frequently associated from malodorous wounds include anaerobes such as *Bacteroides* and *Clostridium* species in addition to numerous aerobic bacteria. Research has also shown that certain wound odors may be specific to a species.⁹⁵

The most effective method of dealing with wound odors is elimination of the offending organism. Systemic antibiotics may be effective but achieving an effective concentration of the antibiotic at site of infection may be difficult. Topical preparations such as metronidazole, clindamycin, honey, and sugar have been shown to be promising in this regard in various studies to date.⁹⁶⁻⁹⁸ Despite widespread use of activated charcoal dressings in malodorous wounds, many publications to date tend to focus on wound healing rather than odor control.⁹⁹⁻¹⁰¹ The ability of these dressings to decrease wound odor is undeniable in respect to clinical experiences to date, but objective data of strictly charcoal compounds are lacking.

Negative pressure wound therapy. NPWT was developed in the early 1990s and since has become familiar to any practitioner dealing with wounds. NPWT applies subatmospheric pressure, or suction, to the wound bed via a unit attached to a dressing/sponge. The exact type of dressing varies by manufacturer, but an adhesive drape around the sponge provides for a semioclusive environment in which moist wound healing is encouraged. The nature of semioclusive dressings has been discussed above, facilitating gas exchange and so

on. The suction effect of the device removes excess fluid allowing for enhanced circulation and disposal of cellular waste thereby reducing the risk of bacterial contamination.

The NPWT guidelines for appropriate wounds include acute and traumatic wounds; surgical dehiscent; pressure ulcers; diabetic, arterial, and venous ulcers; and fresh flaps and any compromised flaps. Use of this system to bolster skin grafts and increase the rate of granulation and epithelialization for draining wounds and fistulae has also been advocated. With NPWT, the dressing changes can vary between 48 and 72 h, but in dealing with untreated infected wounds should be changed every 12 h. There are various types of foam densities utilized for different types of wounds (Fig. 8). The black, sterile, polyurethane foam has large pores and is more effective for stimulating granulation tissue and wound contraction. The white, sterile, polyvinyl alcohol foam is denser with smaller pore size. The latter foam is recommended in deep wounds, undermined flaps, sinus tracts, or overexposed vertebra. It has fewer tendencies to adhere to the wound bed, but does not stimulate granulation. There are other wound contact dressings available for NPWT, including gauze and

polyurethane. There is currently a lack of comparative effectiveness data regarding these contact layers.

The literature on NPWT is very extensive and is full of case reports, reviews, and trials on wounds with varying complexities and qualities. In 2008, Vikatmaa *et al.*¹⁰² identified 14 RCTs involving patients with a variety of wound types. Only two of these were classified as “high-quality” studies, the remainder was classified as having poor internal validity. Nevertheless, in all studies NPWT was found to be at least as effective, and in some cases more effective, than the control treatment. The cost of NPWT has also been extensively studied. Philbeck *et al.*¹⁰³ conducted a retrospective study comparing treatment costs of NPWT with more conventional therapies by comparing healing rates. Treatment records of 1,032 Medicare patients with 1,170 NPWT-treated wounds of all types were reviewed. They calculated that the time to heal a group of patients with wounds 22.2 cm² would be 97 days and cost \$14,546, compared with 247 days with traditional therapy with a cost of \$23,465. They concluded that NPWT is an effective treatment modality for a variety of chronic wounds producing healing in certain types of pressure ulcers 61% faster than saline-soaked gauze while at the same time reducing costs by 38%. Studies in regard to time at which NPWT have also proved fruitful. Kaplan *et al.*¹⁰⁴ used retrospective data to study the clinical and cost-effective benefits of using NPWT at an early stage (day 1 or 2, 518 patients) compared with initiating later (day 3 or later, 1,000 records) in the management of traumatic wounds. The early group of patients demonstrated fewer hospital inpatient days (10.6 vs. 20.6 days; $p < 0.0001$) and fewer treatment days (5.1 vs. 6.0 days; $p = 0.0498$). The early-treated group also demonstrated lower total and variable costs per patient discharge (\$43,956 vs. \$32,175; $p < 0.001$ and \$22,891 vs. \$15,805; $p < 0.001$, respectively). The data suggest that early intervention with NPWT has potential clinical and cost-effective benefits in the treatment of traumatic wounds.

Although there are numerous articles and publications in support of NPWT for various types of wounds, the costs of initiating this therapy create reluctance for some practitioners. The further need for high-quality RCTs is necessary to demonstrate cost effectiveness in routine use. Regardless, NPWT treatment undoubtedly plays a role in the management of extensive cavity wounds that cannot be primarily closed and are too large to be dressed with conventional modalities. Heavily exudative wounds, including those with lymphatic

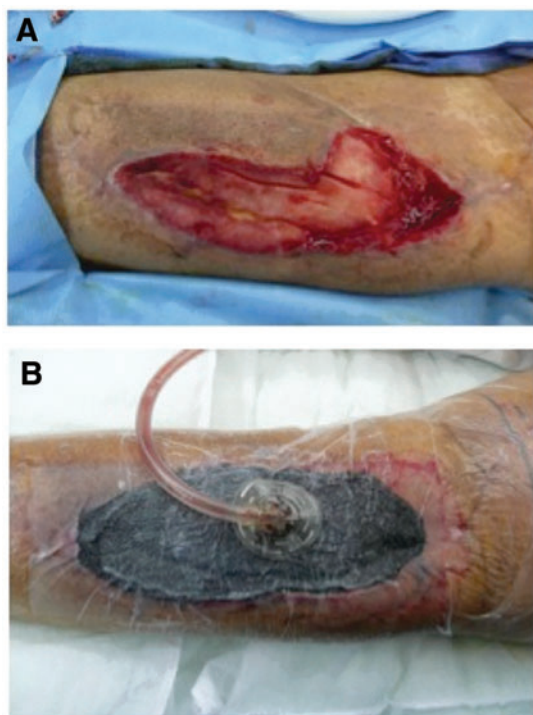


Figure 8. (A) A chronic lower extremity wound after sharp debridement. (B) The same wound closed with a black, sterile, polyurethane foam and negative pressure wound therapy. To see this illustration in color, the reader is referred to the web version of this article at www.liebertpub.com/wound

involvement and excluding those without proper hemostasis, also prove to be an amenable group to this therapy. In 2008, Calne¹⁰⁵ published an excellent summary of the indications and contraindications of NPWT in the form of a consensus document.

FUTURE DIRECTIONS

Advanced treatments and biologically active therapies

There are several new modalities and products that have emerged over the past decade that have aided the constant need for improvement in wound care. NPWT has undoubtedly changed wound care from this point forward and has proven beneficial for a variety of wounds. Hydroconductive dressings are another category that is emerging and studies of its functionality are underway. Other modalities such as hyperbaric oxygen, growth factors, biologic dressings, skin substitutes, and regenerative materials also have proven efficacious in advancing the wound-healing process through a variety of mechanisms (Fig. 9). The future of wound healing at this point remains unknown, but the entities mentioned will likely help shape our future. These products and methods fall outside the scope of this article and are discussed in detail elsewhere.

SUMMARY

After a careful review of current literature on wound management and dressing materials, it is evident that the information, although abundant, provides much conflicting data. Few, high-quality RCTs evaluating wound dressings exist and do not clearly demonstrate superiority of many materials

TAKE-HOME MESSAGES

- Acute wounds have the potential to move from the acute wound to chronic wounds, requiring the clinician to have a thorough understanding of outside interventions to bring these wounds back into the healing cascade.
- Chronic wounds are arrested in a specific phase of wound healing and unable to progress, and those that remain unhealed at ~4 weeks are placed into this category.
- The point of intervention with bacterial presence is very case specific, although most experts will agree that once a wound reaches the level of critical colonization or infection, intervention is necessary.
- Wound characteristics such as edema/exudates, bacterial burden, and nonviable tissue must be addressed with debridement.
- There are several other factors that are important when choosing a dressing: providing protection to the periwound skin, forming an effective bacterial barrier, conforming to wound shape, producing minimal pain during application and removal, being free of toxic or irritant extractables, not releasing particles or nonbiodegradable fibers into the wound, and maintaining the wound at an optimal temperature and pH.
- Gauze in wet-to-dry dressings can re-injure the wound upon removal.
- Semioclusive dressings are not necessarily better than gauze for surgical patients.
- Many physicians have accepted transparent film dressings as the dressing of choice for skin graft donor sites.
- Hydrocolloids appear to trigger an inflammatory reaction, which may help granulation but not epithelial migration.
- Hydrogels are superior to hydrocolloids and gauze for pressure ulcers.
- Alginates are particularly suited for highly draining wounds and bleeding wounds due to their high absorbency and hemostatic properties.
- Silver dressings lack *in vivo* evidence of efficacy.
- All interactive dressing materials have the ability to manipulate one or multiple aspects of the wound environment. Deciding which to use will depend on matching wound characteristics with dressing capabilities, keeping in mind that the wound characteristics will change in the process likely requiring change in dressing subtype.

or categories. There is, however, evidence to suggest the following points: gauze in wet-to-dry dressings can re-injure the wound upon removal, semioclusive dressings are not necessarily better than gauze for surgical patients, many physicians have accepted transparent film dressings as

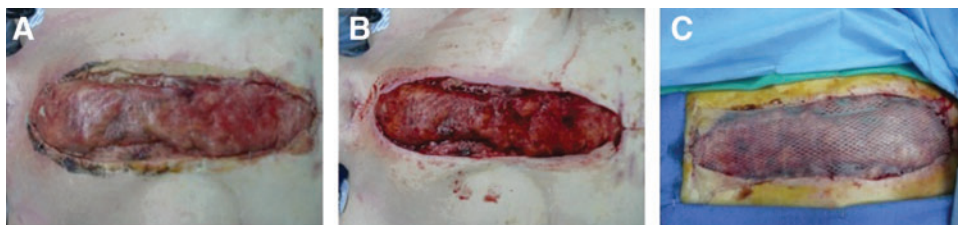

Figure 9. (A) Open chest wound after coronary artery bypass graft covered with Biobrane® (UDL Laboratories), a biocomposite dressing composed of nylon fibers embedded in silicone and collagen. (B) After removal of Biobrane 2 weeks later, showing abundant granulation tissue present at base. (C) After coverage with a split-thickness skin graft. To see this illustration in color, the reader is referred to the web version of this article at www.liebertpub.com/wound

the dressing of choice for skin graft donor sites, hydrocolloids appear to trigger an inflammatory reaction that may help granulation but not epithelial migration, hydrogels have proven superior to hydrocolloids and gauze for pressure ulcers, alginates are particularly suited for highly draining wounds and bleeding wounds due to their highly absorbency and hemostatic properties, and silver dressings lack *in vivo* evidence of efficacy.

Comparative effectiveness research can be used as a tool to evaluate topical therapy for wound care. As described by van Rijswijk and Gray,¹⁰⁶ using clearly defined processes to study patient-centered outcomes and only product groupings that meet an operational definition of functioning will help clinicians decide whether an intervention can and will work and whether the value of the clinical/economic benefits is greater than the potential harm/cost. While consensus exists that clinical practice in wound care should be evidence based, difficulty arises due to confusion about the various approaches to wound management. In efforts to address this, the European Wound Management Association set up a Patient Outcome Group to produce recommendations on clinical data and collection on wound care.¹⁰⁷ The authors of this article urge readers to refer to this document, disseminated by the *Journal of Wound Care*, to further understand how to ensure that studies are consistent and reproducible.

Until further data emerges, education on the available products and logical clinical thought must prevail. Each individual wound must be

carefully evaluated, categorized, and treated. The importance of identifying the need for debridement, level of exudates, and presence of infection cannot be overstated. Armed with the knowledge on different interactive dressing materials presented in this article, an effective and efficient wound care strategy can be formed.

AUTHOR DISCLOSURE AND GHOSTWRITING STATEMENT

No competing financial interests exist. The content of this article was expressly written by the authors listed. No ghostwriters were used to write this article.

ABOUT THE AUTHORS

Dr. Aditya Sood is a Plastic and Reconstructive Surgery Resident at the University of Medicine and Dentistry in New Jersey (UMDNJ)—New Jersey Medical School, where he trains under **Dr. Mark Granick**, Chief of the Division of Plastic Surgery. Dr. Granick has lectured extensively throughout the United States and the world, and has authored several publications in wound care. **Nancy Tomaselli** is the President and CEO of Premier Health Solutions, LLC, a professional medical services company specializing in wound, ostomy, and continence care. She is nationally known for her extensive speaking and publication history, having authored professional education materials and articles for scientific journals.

REFERENCES

- Brigham PA and McLoughlin E: Burn incidence and medical care use in the United States: estimate, trends, and data sources. *J Burn Care Rehabil* 1996; **17**: 95.
- Medical Data International, Inc.: U.S. markets for wound management products. Irvine, CA: Medical Data International, August 1997.
- Markova A and Mostow EN: US skin disease assessment: ulcer and wound care. *Dermatol Clin* 2012; **30**: 107, ix.
- Ovington LG: Bacterial toxins and wound healing. *Ostomy Wound Manage* 2003; **49** (7A Suppl): 8.
- Mustoe T: Understanding chronic wounds: a unifying hypothesis on their pathogenesis and implications for therapy. *Am J Surg* 2004; **187**: 65S.
- Mustoe TA, O'Shaughnessy K, and Kloeters O: Chronic wound pathogenesis and current treatment strategies: a unifying hypothesis. *Plast Reconstr Surg* 2006; **117**: 35S.
- Sisco M and Mustoe TA: Animal models of ischemic wound healing: toward an approximation of human chronic cutaneous ulcers in rabbit and rat. *Methods Mol Med* 2003; **78**: 55.
- Fleck CA: Differentiating MMPs, biofilm, endotoxins, exotoxins, and cytokines. *Adv Skin Wound Care* 2006; **19**: 77.
- Dabiri G and DiPersio M: Matrix metalloproteinases. In: *Wound Healing*, edited by Falabella A, and Kirsner R. Boca Raton, FL: Taylor and Francis, 2005, pp. 49–59.
- Robson MC, Krizek TJ, and Heggers JP: Biology of surgical infection. *Curr Probl Surg* 1973; Mar: 1.
- Galiano RD and Mustoe TA: Wound care. In: *Grabb and Smith's Plastic Surgery*, 6th edition, edited by Thorne CH. Philadelphia: Lippincott Williams and Wilkins, 2007, pp. 23–32.
- Forrest RD: Early history of wound treatment. *J R Soc Med* 1982; **75**: 198.
- Okan D, Woo K, and Ayello EA: The role of moisture balance in wound healing. *Adv Skin Wound Care* 2007; **20**: 39.
- Attinger CE, Janis JE, Steinberg J, Schwartz J, Al-Attar A, and Couch K: Clinical approach to wounds: debridement and wound bed preparation including the use of dressings and wound healing adjuvants. *Plast Reconstr Surg* 2006; **117**(7S): 72.
- Morin RJ and Tomaselli NL: Interactive dressings and topical agents. *Clin Plast Surg* 2007; **34**: 643.
- Lawrence JC: What materials for dressings? *Injury* 1982; **13**: 500.

17. Piskozub ZT: The efficiency of wound dressing materials as a barrier to secondary bacterial contamination. *Br J Plast Surg* 1968; **21**: 387.
18. Thomas S, Dawes C, and Hay NP: Wound dressing materials—testing and control. *Pharm J* 1982; **228**: 576.
19. Thomas S: *Surgical Dressings and Wound Management*. Hinesburg, VT: Kestrel Health Information, Inc., 2012, pp. 79–106.
20. Ayello EA and Cuddigan JE: Debridement: controlling the necrotic/cellular burden. *Adv Skin Wound Care* 2004; **17**: 66.
21. Broughton G, Janis J, and Attinger C: A brief history of wound care. *Plast Reconstr Surg* 2006; **117(7S)**: 6.
22. Ovington LG: Hanging wet to dry dressings out to dry. *Home Healthc Nurse* 2001; **19**: 477.
23. Lawrence JC: Dressings and wound infection. *Am J Surg* 1994; **167 (Suppl 1A)**: 1S.
24. Hutchinson JJ: Prevalence of wound infection under occlusive dressings: a collective survey of reported research. *Wounds* 1989; **1**: 123.
25. Hutchinson JJ: A prospective clinical trial of wound dressings to investigate the rate of infection under occlusion. In: *Proceedings of the first European Conference on Advances in Wound Management*, edited by Harding K. London: Macmillan, 1993.
26. Vermeulen H, Ubbink D, Goossens A, de Vos R, and Legemate D: Dressings and topical agents for surgical wounds healing by secondary intention. *Cochrane Database Syst Rev* 2004; **1**: CD003554.
27. Ubbink DT, Vermeulen H, and van Hattem J: Comparison of homecare costs of local wound care in surgical patients randomized between occlusive and gauze dressings. *J Clin Nurs* 2008; **17**: 593.
28. Ubbink DT, Vermeulen H, Goossens A, Kelner RB, Schreuder SM, and Lubbers MJ: Occlusive vs. gauze dressings for local wound care in surgical patients: a randomized clinical trial. *Arch Surg* 2008; **143**: 950.
29. Persson K and Salemark L: How to dress donor sites of split thickness skin grafts: a prospective randomized study of four dressings. *Scand J Plast Reconstr Surg Hand Surg* 2000; **34**: 55.
30. Dinner MI, Peters CR, and Sherer J: Use of semipermeable polyurethane membrane as a dressing for split-skin graft donor sites. *Plast Reconstr Surg* 1979; **64**: 112.
31. Barnett A, Berkowitz RL, Mills R, and Vistnes LM: Scalp as a skin graft donor site: rapid reuse with synthetic adhesive moisture vapor permeable dressings. *J Trauma* 1983; **23**: 148.
32. Rubio PA: Use of semioclusive, transparent film dressings for surgical wound protection: experience in 3637 cases. *Int Surg* 1991; **76**: 253.
33. Seaman S: Dressing selection in chronic wound management. *J Am Podiatr Med Assoc* 2002; **92**: 24.
34. Anderson KE, Franken CPM, Gad P, Larsen AM, Larsen JR, van Neer PAFA, Vuerstaek J, Wuite J, and Neumann HAM: A randomized, controlled study to compare the effectiveness of two foam dressings in the management of lower leg ulcers. *Ostomy Wound Manage* 2002; **48**: 34.
35. Choucair M and Phillips TJ: Wound dressings. In: *Fitzpatrick's Dermatology in General Medicine*, 5th edition, edited by Freedberg IM, Eisen AZ, Wolff K, Austen KF, Goldsmith LA, Katz SI, and Fitzpatrick TB. New York: McGraw-Hill Book Co., 2000, pp. 2954–2958.
36. Ovington LG: The well-dressed wound: an overview of dressing types. *Wounds* 1998; **10**: 1A.
37. Darkovich SL, Brown-Etris M, and Spencer M: Biofilm hydrogel dressing: a clinical evaluation in the treatment of pressure sores. *Ostomy Wound Manage* 1990; **29**: 47.
38. Kaya AZ, Turani N, and Akyuz M: The effectiveness of a hydrogel dressing compared with standard management of pressure ulcers. *J Wound Care* 2005; **14**: 42.
39. Varghese MC, Balin AK, Carter DM, and Caldwell D: Local environment of chronic wounds under synthetic dressings. *Arch Dermatol* 1986; **122**: 52.
40. Mulder G, Jones R, Cederholm-Williams S, Cherry G, and Ryan T: Fibrin cuff lysis in chronic venous ulcers treated with a hydrocolloid dressing. *Int J Dermatol* 1993; **32**: 304.
41. Chvapil M, Holubec H, and Chvapil T: Inert wound dressings is not desirable. *J Surg Res* 1991; **51**: 245.
42. Gokoc C and Burhop K: A comparative study of wound dressings on full-thickness wounds in micropigs. *Decubitus* 1993; **6**: 42.
43. Agren MS, Mertz PM, and Franzen L: A comparative study of three occlusive dressings in the treatment of full-thickness wounds in pigs. *J Am Acad Dermatol* 1997; **36**: 53.
44. Qin Y and Gilding DK: Alginate fibres and wound dressings. *Med Device Technol* 1996; **7**: 32.
45. Cannavo M, Fairbrother G, Owen D, Ingle J, and Lumley T: A comparison of dressings in the management of surgical abdominal wounds. *J Wound Care* 1998; **7**: 57.
46. Moody M: Tissue viability. Calcium alginate: a dressing trial. *Nurs Stand Spec Suppl* 1991; (13): 3.
47. Thomas S and Tucker CA: Sorbsan in the management of leg ulcers. *Pharm J* 1989; **243**: 706.
48. Smith J and Lewis JD: Sorbsan and leg ulcers (letter). *Pharm J* 1990; **244**: 468.
49. Franks PJ: Sorbsan and leg ulcers (letter). *Pharm J* 1990; **244**: 468.
50. Attwood AI: Calcium alginate dressing accelerates split skin graft donor site healing. *Br J Plast Surg* 1989; **42**: 373.
51. Pirone LA, Bolton LL, Monte KA, and Shannon RJ: Effect of calcium alginate dressings on partial-thickness wounds in swine. *J Invest Surg* 1992; **5**: 149.
52. Robinson BJ: The use of a hydrofibre dressing in wound management. *J Wound Care* 2000; **9**: 32.
53. Barnea Y, Amir A, Leshem D, Zaretski A, Weiss J, Shafir R, Gur E: Clinical comparative study of aquacel and paraffin gauze dressing for split-skin donor site treatment. *Ann Plast Surg* 2004; **53**: 132.
54. Vloemans AF, Soesman AM, Kreis RW, and Middelkoop E: A newly developed hydrofibre dressing in the treatment of partial-thickness burns. *Burns* 2001; **27**: 167.
55. Guest JF and Ruiz FJ: Modeling the cost implications of using carboxymethylcellulose dressing compared with gauze in the management of surgical wounds healing by secondary intention in the US and UK. *Curr Med Res Opin* 2005; **21**: 281.
56. Truhan-Ortiz R, Molfatt LT, Robson MC, Jordan MH, and Shupp JW: *In vivo* and *in vitro* evaluation of the properties of Drawtex LevaFiber wound dressing in an infected wound model. Presented at a Symposium of Investigators, Innovations for Wound Bed Preparation: The Role of Drawtex Hydroconductive Dressings, Tampa, FL, 2012.
57. Ochs D, Uberti MG, Donate GA, Abercrombie M, Mannari RJ, and Payne WG: Evaluation of mechanisms of action of a hydroconductive wound dressing, Drawtex, in chronic wounds. *Wounds* 2012; **24 (9 Suppl)**: 3.
58. Livingston M, and Wolvos T: Hydroconductive debridement: a new perspective in reducing slough and necrotic tissue. Presented at the 24th Annual Symposium on Advanced Wound Care and the Wound Healing Society Meeting, Dallas, TX, 2011.
59. Wolcott RD, and Cox S: The effects of a hydroconductive dressing on wound biofilm. Presented at a Symposium of Investigators, Innovations for Wound Bed Preparation: The Role of Drawtex Hydroconductive Dressings, Tampa, FL, 2012.
60. Spangler D: *In vitro* antimicrobial activity of oxidized regenerated cellulose against antibiotic resistant microorganisms. *Surg Infect (Larchmt)* 2003; **4**: 255.
61. Hofman D, Wilson J, Poore S, Cherry G, and Ryan T: Can Traumacel be used in the treatment of chronic wounds? *J Wound Care* 2000; **9**: 393.
62. Hughes MA, Yang Y, and Cherry GW: Effect of Traumacel P on the growth of human dermal fibroblasts *in vitro*. *J Wound Care* 2002; **11**: 149.
63. Jeschke MC, Sandmann G, Schubert T, and Klein D: Effect of oxidized regenerated cellulose/collagen matrix on dermal and epidermal healing and growth factors in an acute wound. *Wound Repair Regen* 2005; **13**: 324.
64. Perkins K, Davey RB, and Wallis KA: Silicone gel: a new treatment for burn scars and contractures. *Burns* 1983; **9**: 201.

65. Li-Tasang CW, Lau JC, Choi J, Chan CC, and Jianan L: A prospective randomized clinical trial to investigate the effect of silicone gel sheeting (Cica-Care) on post-traumatic hypertrophic scar among the Chinese population. *Burns* 2006; **32**: 678.
66. de Oliveira GV, Nunes TA, Magna LA, Cintra ML, Kitten GT, Zarpellon S, and Raposo Do Amaral CM: Silicone versus nonsilicone gel dressings: a controlled trial. *Dermatol Surg* 2001; **27**: 721.
67. Zurada JM, Kriegel D, and Davis IC: Topical treatments for hypertrophic scars. *J Am Acad Dermatol* 2006; **55**: 1024.
68. Poston J: The use of silicone gel sheeting in the management of hypertrophic and keloid scars. *J Wound Care* 2000; **9**: 10.
69. Mustoe TA, Cooter RD, Gold MH, Hobbs FD, Ramelet AA, Shakespeare PG, Stella M, Téot L, Wood FM, Ziegler UE; International Advisory Panel on Scar Management: International clinical recommendations on scar management. *Plast Reconstr Surg* 2002; **110**: 560.
70. O'Brien L, and Pandit A: Silicon gel sheeting for preventing and treating hypertrophic and keloid scars. *Cochrane Database Syst Rev* 2006; (1): CD003826.
71. Mofikoya BO, Adeyemo WL, and Abdus-Salam AA: Keloid and hypertrophic scars: a review of recent developments in pathogenesis and management. *Nig Q J Hosp Med* 2007; **17**: 134.
72. Reish RG and Ericksson E: Scars: a review of emerging and currently available therapies. *Plast Reconstr Surg* 2008; **122**: 1068.
73. Durani P and Bayat A: Levels of evidence for the treatment of keloid disease. *J Plast Reconstr Aesthet Surg* 2008; **122**: 1068.
74. Warriner R and Burrell R: Infection and the chronic wound: a focus on silver. *Adv Skin Wound Care* 2005; **18**: 2.
75. Burrell BE: A scientific perspective on the use of topical silver preparations. *Ostomy Wound Manage* 2003; **49** (5A Suppl): 19.
76. Tomaselli N: The role of topical silver preparations in wound healing. *J Wound Ostomy Continence Nurs* 2006; **33**: 367.
77. Vermeulen H, van Hattem JM, Storm-Versloot MN, and Ubbink DT: Topical silver for treating infected wounds. *Cochrane Database Syst Rev* 2007; (1): CD005486.
78. Jorgensen B, Price P, Andersen KE, Gottrup F, Bech-Thomsen N, Scanlon E, Kirsner R, Rheinen H, Roed-Petersen J, Romanelli M, Jemec G, Leaper DJ, Neumann MH, Veraart J, Coerper S, Agerslev RH, Bendz SH, Larsen JR, and Sibbald RG: The silver-releasing foam dressing, Contreet foam, promotes faster healing of critically colonized venous leg ulcers: a randomized, controlled trial. *Int Wound J* 2005; **2**: 64.
79. Meaume S, Vallet D, Morere MN, and Téot L: Evaluation of a silver-releasing hydroalginate dressing in chronic wounds with signs of local infection. *J Wound Care* 2005; **14**: 411.
80. Munter KC, Beele H, Russell L, Crespi A, Gröchenig E, Basse P, Alikadic N, Fraulin F, Dahl C, and Jemma AP: Effect of a sustained silver-releasing dressing on ulcers with delayed healing: the CONTOP study. *J Wound Care* 2006; **15**: 199.
81. Ovington LG: The truth about silver. *Ostomy Wound Manage* 2004; **50** (9A Suppl): 11S.
82. Dissemmond J, Gerber V, Kramer A, Riepe G, Strohal R, Vassel-Biergans A, and Eberlein T: Practice-oriented recommendation for the treatment of critical colonised and local infected wounds using polihexanide. *J Wound Healing* 2009; **14**: 20.
83. Eberlein T, Haemmerle G, Signer M, Gruber Moesenbacher U, Traber J, Mittlboeck M, Abel M, and Strohal R: Comparison of PHMB-containing dressing and silver dressings in patients with critically colonised or locally infected wounds. *J Wound Care* 2012; **21**: 12, 14–16.
84. Blair SE, Cocctin NN, Harry EJ, and Carter DA: The unusual antibacterial activity of medical-grade leptospermum honey: antibacterial spectrum, resistance and transcriptome analysis. *Eur J Clin Microbiol Infect Dis* 2009; **28**: 1199.
85. Gethin G and Cowman S: Manuka honey vs. hydrogel—a prospective, open label, multi-centre, randomized controlled trial to compare desloughing efficacy and healing outcomes in venous ulcers. *J Clin Nurs* 2009; **18**: 466.
86. Gupta SS, Singh O, Bhagel PS, Moses S, Shukla S, and Mathur RK: Honey dressings versus silver sulfadiazine dressing for wound healing in burn patients: a retrospective study. *J Cutan Aesthet Surg* 2011; **4**: 183.
87. Vallin E: *Traite des desinfectants et de la desinfectation*. Paris: Masson, 1882.
88. Burks RI: Povidone-iodine solution in wound treatment. *Phys Ther* 1998; **78**: 212.
89. Drosou A, Falabella A, and Kirsner RS: Antiseptics on wounds: an area of controversy. *Wounds* 2003; **15**: 149.
90. Chang SL: Modern concepts of disinfection. *J Sanit Eng Div Proc ASCE* 1971; **97**: 689.
91. Durani P and Leaper DJ: Povidone-iodine: use in hand disinfection, skin preparation and antiseptic irrigation. *Int Wound J* 2008; **5**: 376.
92. Phillips PL, Wolcott RD, Fletcher J, and Schultz GS: Biofilms Made Easy. *Wounds Int* 2010; 1. Available from: www.woundsinternational.com
93. Thorn RM, Austin AJ, Greenman J, Wilkins JP, and Davis PJ: *In vitro* comparison of antimicrobial activity of iodine and silver dressings against biofilms. *J Wound Care* 2009; **18**: 343.
94. Schultz G, Phillips PL, Yang QP, and Sampson EM: Microbicidal effects of wound dressings on mature bacterial biofilm on porcine skin explants. Poster presented at EWMA, Helsinki, Finland, 2009.
95. Parry AD, Chadwick PR, Simon D, Oppenheim B, and McCollum CN: Leg ulcer odour detection identifies beta-haemolytic streptococcal infection. *J Wound Care* 1995; **4**: 404.
96. Newman V: The use of metronidazole gel to control the smell of malodorous lesions. *Palliat Med* 1989; **3**: 303.
97. Ogura T, Urade M, and Matsuya T: Prevention of malodor from intraoral gauze tamponade with the topical use of clindamycin. *Oral Surg Oral Med Oral Pathol* 1992; **74**: 58.
98. Chiwenga S, Dowlen H, and Mannion S: Audit of the use of sugar dressings for the control of wound odor at Lilongwe Central Hospital, Malawi. *Trop Doct* 2009; **39**: 20.
99. Woodhouse P: Managing a breast wound. *Nursing Times* 1992; **88**: 74.
100. Boardman M and Mellor K: Treating a patient with a heavily exudating malodorous fungating ulcer. *J Wound Care* 1993; **2**: 74.
101. Young T: The challenge of managing fungating wounds. *Nurseprescriber/Community Nurse* 1997; **3**: 41.
102. Vikatmaa P, Juutilainen V, Kuukasjarvi P, and Malmivaara A: Negative pressure wound: a systemic review on the effectiveness and safety. *Eur J Vasc Endovasc Surg* 2008; **36**: 438.
103. Philbeck TE, Whittington KT, Millsap MH, Briones RB, Wight DG, and Schroeder WJ: The clinical and cost effectiveness of externally applied negative pressure wound therapy in the treatment of wounds in home healthcare Medicare patients. *Ostomy Wound Manage* 1999; **45**: 41.
104. Kaplan M, Daly D, and Stemkowski S: Early intervention of negative pressure wound therapy using Vacuum-Assisted Closure in trauma patients: impact on hospital length of stay and cost. *Adv Skin Wound Care* 2009; **22**: 128.
105. Apelqvist J, Armstrong DG, Augustin M, Baharestani M, Banwell P, Dalla Paola L, Deva A, Ennis W, Fish J, Fleischmann W, Gupta S, Gustafsson R, Harding K, Horch RE, Ingemansson R, Jukema G, Mahoney J, Mouës C, Price P, Agreda JS, Song C, Téot L, Trueman P, Vowden K, Vowden P, and Wild T: Vacuum assisted closure: recommendations for use. A consensus document. *Int Wound J* 2008; **5** Suppl 4: iii–19.
106. van Rijswijk L and Gray M: Evidence, research, and clinical practice: a patient-centered framework for progress in wound care. *J Wound Ostomy Continence Nurs* 2012; **39**: 35.
107. Gottrup F, Apelqvist J, and Price P: Outcomes in controlled and comparative studies on non-healing wounds: recommendations to improve the quality of evidence in wound management. *J Wound Care* 2010; **19**: 237.