

Peripheral nerve injury grading simplified on MR neurography: As referenced to Seddon and Sunderland classifications

Avneesh Chhabra, Shivani Ahlawat¹, Allan Belzberg², Gustav Andreseik³

Department of Radiology and Orthopaedic Surgery, University of Texas Southwestern Medical Center, ¹Department of Radiology and Radiological Science, Johns Hopkins University School of Medicine, ²Department of Neurosurgery, The Johns Hopkins Hospital, Baltimore, MD, USA, ³Department of Radiology, University Hospital Zürich, Zürich, Switzerland

Correspondence: Dr. Avneesh Chhabra, Associate Professor Radiology and Orthopedic Surgery, University of Texas Southwestern, 5323 Harry Hines Blvd., Dallas, TX 75390, USA. E-mail: avneesh.chhabra@utsouthwestern.edu

ABSTRACT

The Seddon and Sunderland classifications have been used by physicians for peripheral nerve injury grading and treatment. While Seddon classification is simpler to follow and more relevant to electrophysiologists, the Sunderland grading is more often used by surgeons to decide when and how to intervene. With increasing availability of high-resolution and high soft-tissue contrast imaging provided by MR neurography, the surgical treatment can be guided following the above-described grading systems. The article discusses peripheral nerve anatomy, pathophysiology of nerve injury, traditional grading systems for classifying the severity of nerve injury, and the role of MR neurography in this domain, with respective clinical and surgical correlations, as one follows the anatomic paths of various nerve injury grading systems.

Key words: Axonotmesis; injury; MR neurography; neuroma-in-continuity; neurotmesis; peripheral nerve; Seddon; Sunderland

Introduction

According to some estimates, 2-5% of trauma patients presenting in a level I tertiary care center experience peripheral nerve injury and about 100,000 peripheral nerve surgeries are performed each year in the North America.^[1-3] Milder nerve injuries are usually managed medically, while more severe injuries require surgical intervention. The two widely used major classifications for nerve injury grading are the Seddon and Sunderland classifications.^[4-7]

While Seddon classification is simpler to follow and more relevant to electrophysiologists, Sunderland grading is more often used by surgeons to decide when and how to intervene. Further, accomplished surgeons Mackinnon and Dellon have identified another addition to Sunderland classification by describing a mixed type of injury.^[8]

With increasing availability of high-resolution and high soft-tissue contrast imaging provided by magnetic resonance neurography (MRN), evaluation of peripheral nerve anatomy and pathology has become facile and the surgical treatment can be prudently guided following the above described grading systems.^[8-10] The article discusses peripheral nerve anatomy, pathophysiology of nerve injury, traditional grading systems for classifying the severity of nerve injury, and the role of MRN in this domain, with relevant clinical and surgical correlations, as one follows the anatomic paths of various nerve injury grading systems.

Access this article online

Quick Response Code:



Website:
www.ijri.org

DOI:
10.4103/0971-3026.137025

Nerve Anatomy

A peripheral nerve is a cord-like collection of axons (nerve fibers) that are long and slender tail-like projections from the neuron cell bodies. The connective tissue sheath around the axon is called the endoneurium. A bundle of axons are covered together in another connective tissue layer referred to as the perineurium. The perineurium along with the endoneurium forms the blood-nerve barrier as it encircles the cable-like structure called the fascicle. The fascicles are finally bundled together by a thick connective tissue layer called the epineurium. There are outer and inner epineurial layers [Figure 1]. The inner epineurium contains the vessels supplying and coursing through the nerve and small amount of adipose tissue.^[9] The fascicles vary from 1 to 3 in number in the small sensory nerves to about 200 in the large nerves, such as the sciatic nerve. There is also predictable topographical anatomical arrangement of the fascicles in a particular nerve, for example, in the ulnar nerve in the forearm, the sensory, motor, and dorsal cutaneous fascicles are organized from lateral to medial.^[11] The peripheral nerves are divided into motor, sensory, or mixed from a functional perspective.

Nerve Injury - Pathophysiology

The peripheral nerve injuries can be caused by a variety of mechanisms, broadly classified as systemic conditions or local pathologies.^[12] Systemic conditions, such as autoimmune inflammation, diabetes mellitus, vasculitis, or drug-induced injury, generally involve multiple nerves in multi-compartment or bilateral distribution and are best diagnosed by a combination of clinical findings and electrophysiology. Local pathologies include blunt trauma, penetrating injury, chronic traction or acute stretch injury, local chemical injury, or freeze injury. From an imaging perspective, further discussion will focus on the pathophysiology of nerve injury related to local pathology and its grading schemes. Nerve injury may involve axonal loss, myelin loss, or commonly a combination

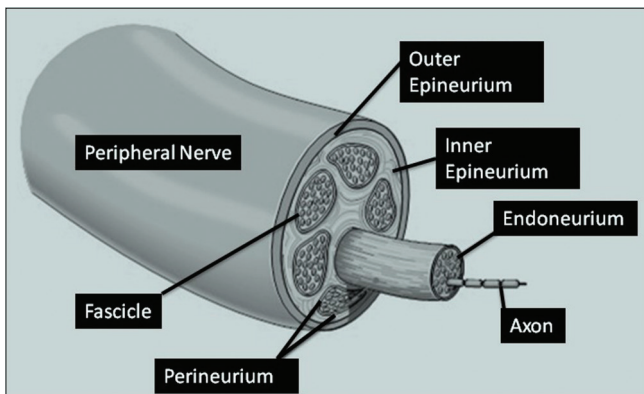


Figure 1: Peripheral nerve anatomy. Illustration shows various layers of the nerve demonstrated along its cross section

of both. Clinically, it may lead to sensory dysfunction and/or motor loss. Functional recovery entails axonal regeneration (occurring at ~1 mm/day or ~1 inch/month) and remyelination with reinnervation of sensory receptors, neuromuscular junction, or both, and it may take days to months depending upon the distance the axon has to travel.^[13-15] Children recover earlier than older subjects as the axons have to travel less distance to reinnervate the regional muscles.^[5]

Nerve Injury Grading Systems

In 1943, Sir Herbert Seddon^[4,5] described the three basic types of nerve injuries, and referred to them as neurapraxia, axonotmesis, and neurotmesis, using a mild/moderate/severe surgical model. Neurapraxia, the first-degree injury, is the most common response to blunt trauma causing a temporary conduction block with demyelination at the site of injury. Clinically, it results in sensory dysfunction. The Tinel sign is absent and electrophysiologic studies are negative. The recovery may take a few days upto 12 weeks. Axonotmesis is the second-degree injury leading to axonal loss while the connective tissue layers are preserved. The distal targets of peripheral nerves release trophic factors for growth and survival of axons and neuronal cell bodies that enhance formation of proximal axonal sprouts. Chemotactic factors released from distal targets also help guide sprouting axons to the appropriate destination.^[9,11,13] Clinically, motor and/or sensory dysfunction is present and Tinel sign is positive at the site of injury. Electrophysiologic study reveals decreased nerve conduction velocity and regional muscle denervation changes with fibrillations. With reinnervation, muscle unit potentials are observed on electrophysiology. Neurotmesis is the third-degree and the most severe nerve injury, where the nerve is physically divided. No conduction on electrophysiology and no recovery are expected unless surgery is performed. More commonly, electrophysiologic studies are not able to distinguish axonotmesis from neurotmesis. This classification is simple to understand and is popular among electrophysiologists; however, further distinction of injury in terms of differential involvement of various nerve layers is important from a surgical perspective and nerve recovery potential.

Sir Sydney Sunderland^[7] described five degrees of peripheral nerve injury [Table 1]. The first degree corresponds to neurapraxia and the second degree to axonotmesis as described above. The third, fourth, and fifth degrees involve injury to endoneurial tubes, perineurium, and epineurium, respectively. In these injuries, since the connective tissue sheaths are disrupted, the regenerating axons are misdirected and may not be able to innervate the sensory endings or muscle end plates, and the pattern of recovery indicated by muscle unit potentials is mixed and, often, incomplete. More retrograde degeneration occurs in third-degree injury as compared to second-degree injury

and the fascicular continuity is still maintained [Figure 2]. While recovery usually occurs in the third-degree injury over many months with conservative treatment, surgical intervention may be required to release the entrapment sites over the swollen nerve with or without limited neurolysis. In the fourth-degree injury, internal hemorrhage and fibrous tissue entangles the regenerating and growing nerve sprouts due to fascicular discontinuity, inhibiting the directed distal axonal growth, thereby resulting in the formation of neuroma-in-continuity. Fifth-degree injury leads to complete nerve discontinuity and formation of end-bulb neuroma [Figure 3]. In these two injuries, Tinel sign fails to advance beyond the level of injury and no muscle unit potentials are observed. Electrophysiology studies cannot differentiate fourth-degree injury from fifth-degree injury and not much functional recovery is expected without surgery. Since fibrosis may occur diffusely or focally within a neuroma-in-continuity, the involved segment may still

conduct action potentials among preserved axons and produce minimal muscular contractions upon stimulation. Internal neurolysis with careful dissection may enhance nerve regeneration. However, this may also lead to further scarring. On the other hand, in case of absence of nerve conduction, neuroma resection and grafting across the nerve defect or damaged parts of the nerve offer acceptable chances of functional recovery. When excessive length of the nerve gap or timing of regeneration preclude grafting, nerve transfer may be employed to optimize recovery. In case of definite nerve gap, proximal and distal nerve stumps may be realigned using epineurial or perineurial sutures, with fibrin glue reinforcement. This technique is usually reserved for very distal repairs and coaptation under tension should be avoided by employing other methods of surgical repair.^[16]

Finally, Mackinnon and Dellon described a mixed type or Grade VI injury as an addition to Sunderland grading scheme.^[17] This classification denotes that across the cross section of the nerve, the injury may involve various layers and not necessarily follow the traditional inside-outside

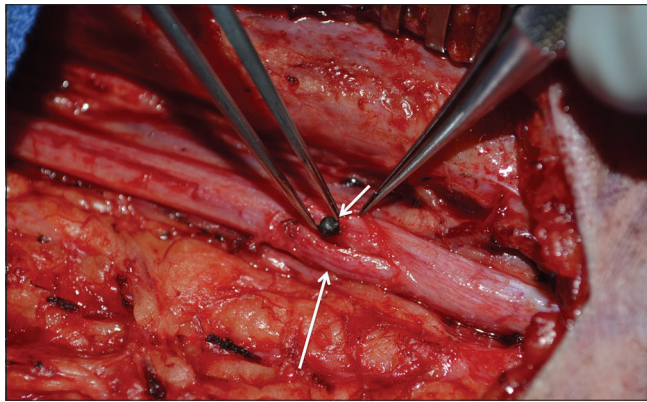


Figure 2: Sunderland grade III injury. Intraoperative image demonstrates shot gun fragment (small arrow) in the exposed swollen median nerve following epineurotomy. Notice intact nerve fascicles (long arrow)

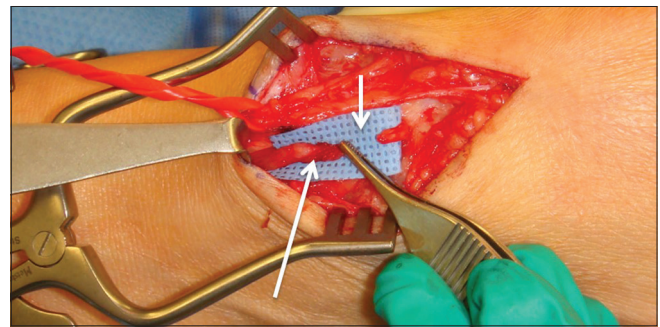


Figure 3: Sunderland grade V injury. Prior injury related discontinuity of the deep peroneal nerve in the lower leg. Notice clear gap between the nerve endings (small arrow) with proximal neuroma (large arrow)

Table 1: Nerve injury classification, clinical and MRN findings, prognosis and treatment

Degree of nerve injury	Myelin	Axon	Endo-neurium	Peri-neurium	Epi-neurium	Tinel sign	MRN (signal intensity)	Recovery potential	Rate of recovery	Surgery
I Neurapraxia	±					No	Nerve-incr T2 SI Muscle-Normal	Full	Upto 12 weeks	None
II Axonotmesis	Yes	Yes	No	No	No	Yes	Nerve-incr T2SI and diffusely enlarged Fascicles-enlarged or effaced due to edema Muscles-denervation	Full	1mm/day	None
III	Yes	Yes	Yes	No	No	Yes		Usually slow, incomplete	1mm/day	None or Neurolysis
IV NIC-neuroma in continuity	Yes	Yes	Yes	Yes	No	Yes but no advancement	Nerve-focally enlarged with heterogeneous SI. Underlying diffuse abnormality ± Fascicles-disrupted with heterogeneous SI-NIC Muscles-denervation	Poor to none	Poor to none	Nerve repair, graft or transfer
V Neurotmesis	Yes	Yes	Yes	Yes	Yes	Yes but no advancement	Complete nerve discontinuity ± hemorrhage and fibrosis in the nerve gap and end-bulb neuroma proximally. Epineurial thickening Muscles-denervation	None	None	Nerve repair, graft or transfer
VI Mixed injury (I to V)	Variable combination of above across the cross section of the nerve					Some fascicles (II, III)	Variable findings along the circumferential segment of the nerve (I-V) with heterogeneous SI due to fibrosis Muscles-denervation	Variable, can be poor to none	Variable, depends upon the injury (I-V)	Neurolysis, Nerve repair, graft or transfer

MRN: Magnetic resonance neurography, SI: Signal intensity

model as with Sunderland grading. Arguably, this might represent the most common type of direct nerve injury in penetrating trauma and fracture/dislocations in the vicinity of the nerves. The recovery potential is variable and depends upon the degree of injury (I-V). The treatment also varies from simple neurolysis to nerve repair, graft, or transfer.

Controversies and Diagnostic Limitations

While the above-described grading systems make anatomic sense, the injury may not follow the typical model as in our clinical experience. The nerve injury may involve various lengths of one or more regional nerves, and furthermore, the degree of injury may vary along the length of a particular nerve or along its cross section.^[17] From a prognostic point of view, younger patients and patients with distal injuries fare better than older patients or patients with more proximal injuries.^[11] Apart from these important factors of patient demographics and underlying functionality status, treatment ultimately is dictated by the worst degree of injury in a functionally important nerve and its recovery potential.^[18] From electrophysiology perspective, absence of electrical response does not always mean that the nerve is severed. On the other hand, the electrical response may be normal upto a week, even if the nerve is completely severed.^[19-21] Therefore, short of gross inspection by opening the nerve surgically, one should be equipped with better means to detect and grade these injuries in a timely and non-invasive fashion.

In addition, it is important to distinguish grade III injury (commonly treated medically) from grade IV-VI injuries (commonly treated surgically). Currently, the latter is accomplished using serial electrophysiology examinations and surgery is contemplated if there is no evidence of electrical reinnervation at 3-6 months interval time. But it is important to remember that the longer the wait, more would be the chance that regional muscles will significantly atrophy, ultimately leading to poor functional recovery and disability.^[16,17] Therefore, there is a significant lack of diagnostic capabilities after the onset of peripheral neuropathies.

Role of MRN

MRN could very well fill this gap as it allows fine, detailed evaluation of peripheral nerve anatomy and pathology due to excellent soft tissue contrast and high spatial resolution. The imaging shows the normal nerve anatomy, internal architecture, course, caliber, and regional muscles. In literature, imaging performed at high field (3T) as well as 1.5T has been shown to correlate well with clinical, electrophysiology, and surgical findings.^[9,12,22-28] A typical MRN protocol includes high-resolution 2D and 3D, predominant spin-echo-type sequences [Table 2]. Intravenous contrast media are not

routinely needed as most injuries are subacute and no abnormal enhancement is expected within the injured nerves.^[9] While 2D pulse sequences are most useful to identify and characterize the fascicular details as normal or abnormal, isotropic 3D imaging is useful to define and display the neuroma-in-continuity and end-bulb neuroma in nerve discontinuity. Further discussion will focus on imaging appearances of normal peripheral nerve and its abnormalities as they pertain to above described grading schemes.

A normal peripheral nerve shows isointense to minimally hyperintense homogeneous T2 signal intensity (SI). Other features of a normal nerve include uniform fascicular bubbly appearance, minimal fat within the epineurium, pencil-thin hypointense epineurium, relatively invisible perineurium, size similar to the adjacent arteries with gradual decrease in caliber distally and minimal smooth variations around the joints, and finally, clear halo of perineural fatty tissue.^[9] It could have mild hyperintensity on intermediate-weighted and T2-weighted (T2W) images due to magic angle artifact; however, it occurs at expected locations such as the sciatic notch for the sciatic nerves, iliopsoas notch for the femoral nerves, medial plantar nerve at the ankle, ulnar nerve as it enters the Guyon's canal, median nerve at the pronator teres fascial edge, and T1 nerve at the thoracic outlet.

A pathologic nerve shows hyperintensity approaching the adjacent vessel SI or asymmetric to contralateral side, high nerve to muscle SI ratios, and longer extent of signal abnormality.^[26-28] The abnormal nerve may also show one or more of the following findings: abnormally increased SI, heterogeneous SI, focal or diffuse nerve enlargement, epineurial or perineurial thickening, fascicular enlargement and effacement due to different degrees of edema, and fascicular disruption with intraneural and/or perineural fibrosis.^[8,9,12,22-28] One should also remember the key sign of regional muscle denervation change that occurs in the distribution of the injured nerve and as a rule, involves the muscles distal to the site of injury. Increased T2 SI can also be caused by other inflammatory causes of diffuse neuropathy, such as autoimmune

Table 2: A typical 3T MRN extremity protocol

MR sequence	TR (ms)	TE (ms)	SL (mm)	Matrix	2D/3D/additional comments
Axial T1W	500	7.9	3-4	256×384	2D
Axial T2 SPAIR	2840	70	3-4	256×384	2D
Coronal fsPD	2900	35	4	256×256	2D
STIR SPACE	1500	97	1.5	256×256	3D isotropic
DW PSIF	12	4.2	0.9	320×320	3D isotropic, diffusion moment-80 s/mm ²

fsPD: Fat-suppressed proton density, TR: Repetition time, TE: Echo time, ms: Milliseconds, SL: Slice thickness, mm: Millimeter, s: Seconds, STIR: Short tau inversion recovery, SPACE: Sampling perfection with application optimized contrasts using varying flip angle evolutions, DW: Diffusion-weighted, PSIF: Reversed steady state in free precession

neuropathy (Parsonage-Turner syndrome) and multifocal motor neuropathy. Therefore, clinical correlation is essential in such conditions. It is observed as diffusely increased T2 SI on fat-suppressed T2W images without fascial edema or enhancement. With chronicity, there is fatty replacement

and atrophy in the affected muscles that progress over time^[9] [Table 1].

Type I-III injuries [Figures 2-6], which are commonly treated medically, may cause diffuse nerve swelling, but there is no focal nerve enlargement or heterogeneous signal alteration in the enlarged nerve. Regional muscle denervation change is absent in neurapraxia. Endoneurium is not visible with current magnetic resonance imaging (MRI) techniques; therefore, differentiation of grade II and III injuries is not possible on MRN. However, in most instances, both conditions are treated medically. Regional muscle denervation changes cannot be used to distinguish

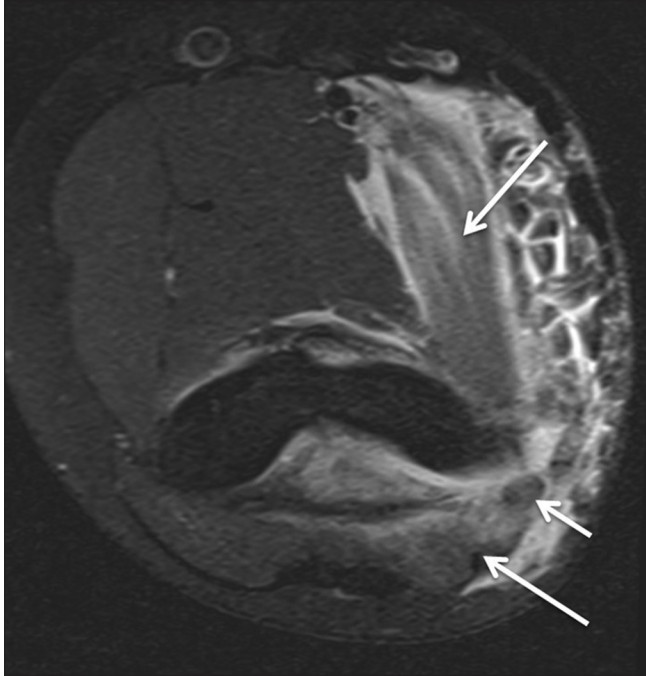


Figure 4: Mild stretch injury (neurapraxia/Sunderland grade I). A 15 month old boy with recent elbow injury complained of pain and numbness in ulnar nerve distribution. Axial T2 Spectral Adiabatic Inversion Recovery (SPAIR) image through the cubital tunnel shows grade I muscle strains of flexor-pronator group and triceps (large arrows). Notice mild hyperintensity of the ulnar nerve (small arrow) suggesting mild traumatic neuropathy. The symptoms of neuropathy resolved in 2 weeks over conservative treatment

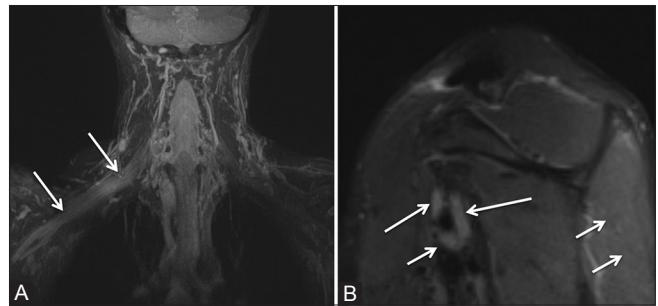


Figure 5 (A and B): Moderate stretch injury (Sunderland grade II/III). A 42 year old man with right clavicle fracture status post internal fixation developed right shoulder pain and substantial right arm weakness. Electromyography (EMG) raised the suspicion of radiculopathy versus plexopathy. Clinically, nerve avulsion could not be excluded. MIP reconstruction from coronal 3D STIR SPACE (A) shows moderate diffuse enlargement of the right brachial plexus with abnormal hyperintensity and no neuroma or discontinuity. Sagittal STIR (B) image demonstrates mild diffuse enlargement of median (small arrow), ulnar (medium arrow), and radial (large arrow) nerves. Notice subtle denervation edema-like signal of the infraspinatus muscle (double arrows). The patient improved over next 6 months consistent with the diagnosis of Sunderland grade II/III injury

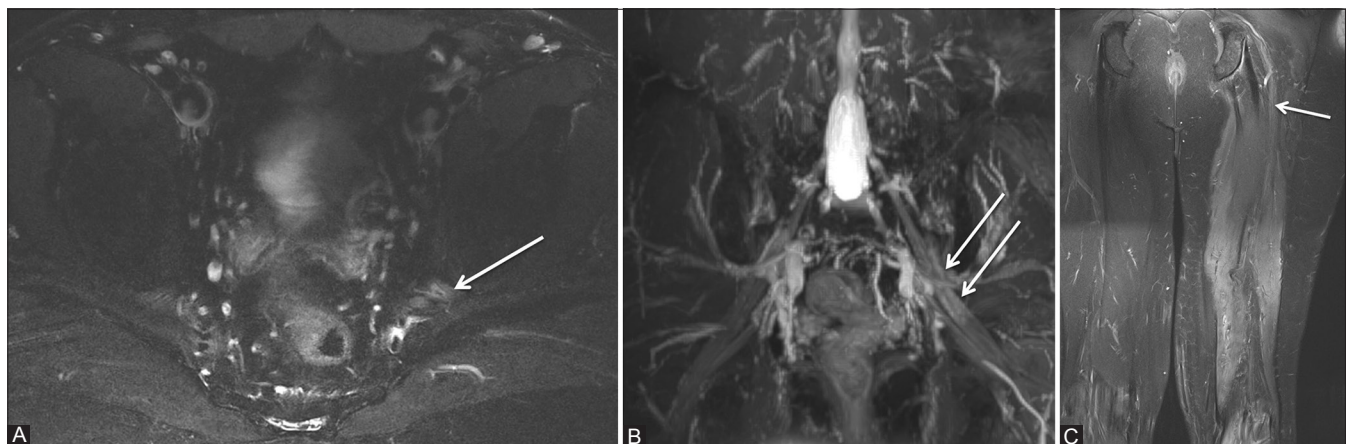


Figure 6 (A-C): Moderate to severe stretch injury (Sunderland grade III). A 51 year old male, status post motor vehicle accident, ankle fixation, and knee arthroscopy developed left sciatic distribution weakness over the course of treatment. The patient continued to have weakness for 6 months from the original injury and severe left sciatic neuropathy on EMG. Axial T2 SPAIR image (A) demonstrates moderate left sciatic hyperintensity with homogeneous signal intensity and preserved fascicular appearance (arrow). Maximum Intensity Projection (MIP) reconstruction from coronal 3D STIR SPACE (B) confirms asymmetric hyperintensity of the left sciatic nerve (arrows). Coronal fat-suppressed proton density image of the lower extremities (C) shows subacute denervation of the left thigh muscles. Notice the abnormal left sciatic nerve (arrow) hyperintensity. Findings are in keeping with moderate to severe stretch injury (Sunderland grade III injury), which was managed conservatively resulting in slow and incomplete recovery

Sunderland grade III from grade IV injury and direct assessment of peripheral nerve is essential to embark upon accurate diagnosis.

Type IV injury manifests as a neuroma-in-continuity, which is seen as focal fusiform nerve enlargement with or without underlying diffuse long segment enlargement. Fascicular discontinuity and focally enlarged nerve with heterogeneous signal is the key to differentiate grade IV injury from grade III injury, where the nerve is homogeneous with fascicular continuity. Grade III injury should be distinguished from grade IV and V injuries for timely surgical management of the latter injuries. Neuroma-in-continuity shows heterogeneous signal abnormality due to internal hemorrhage and fibrosis [Figure 7]. It usually shows no significant enhancement as compared to peripheral nerve sheath tumor, which shows classic imaging signs (target, fascicular)

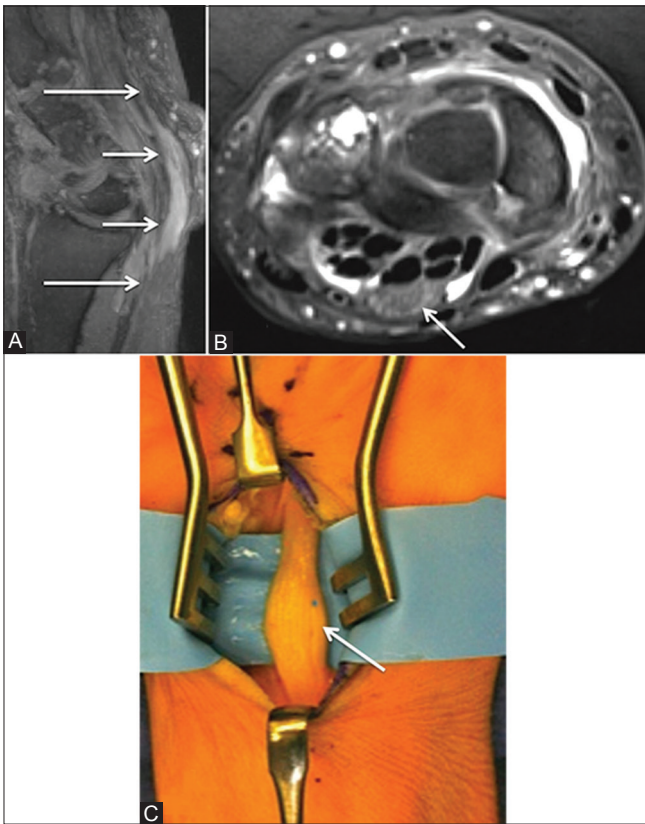


Figure 7 (A-C): Neuroma-in-continuity (Sunderland grade IV/severe stretch injury with fascicular disruption). A 65 year old woman with suspected carpal tunnel syndrome and remote history of injury presented with pain and weakness in the median nerve distribution. MIP reconstruction from sagittal 3D DW-PSIF (three-dimensional diffusion-weighted reversed fast imaging with steady state free precession) (A) shows fusiform enlargement (small arrows) of the median nerve (large arrows). Axial T2 SPAIR image (B) demonstrates the enlarged heterogeneous median nerve in keeping with multifocal fascicular disruption and internal fibrosis (arrow). Intraoperative image (C) confirmed Sunderland grade IV injury with a neuroma-in-continuity (arrow). The patient underwent transverse carpal ligament release and limited intra-as well as peri-neural neurolysis. There was limited improvement on physical examination on 6 month follow-up. (Image C-courtesy Dr. Damon Cooney, MD)

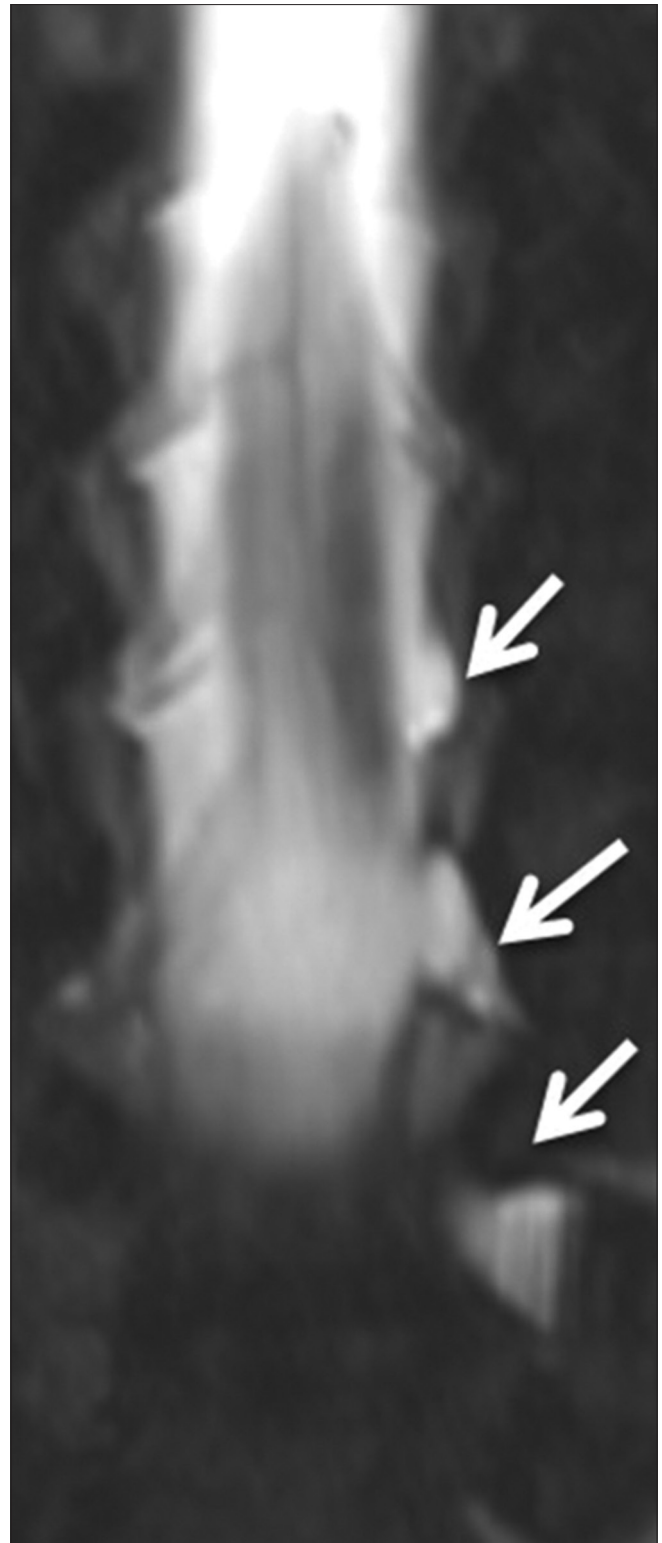

Figure 8: Nerve avulsions/Sunderland grade V injury. A 23 year old man, status post motor vehicle accident, presented with flail left arm and clinical suspicion of severe brachial plexus injury. EMG 5 months after initial injury suggested predominantly upper trunk brachial plexopathy and other co-existent nerve root injuries could not be excluded. MRN was obtained a month after to exclude Sunderland grade V injury. Coronal T2 SPACE image (A) shows pseudomeningoceles with avulsions of ventral and dorsal nerve roots and lateral displacement of dorsal root ganglia (arrows)

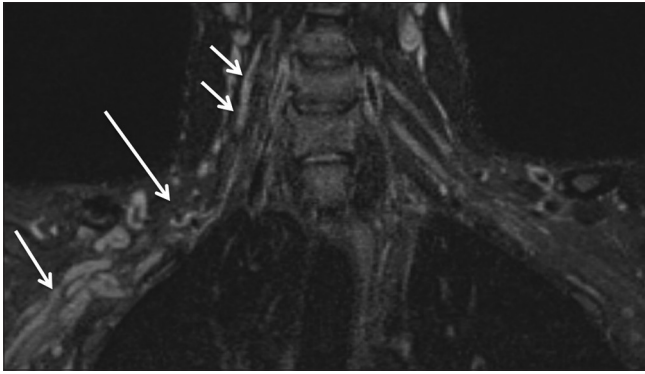


Figure 9: Nerve root lacerations/Sunderland grade V Injury. A 25 year old man, status post motor vehicle accident, suffered spine injury and multiple injuries to the right shoulder region including clavicle fracture which required internal fixation and trapezius muscle tear. The patient was noted to have right brachial plexus injury on clinical assessment, with flail right extremity and Horner's syndrome. EMG was performed 2 months after the initial injury which demonstrated lack of motor units in the right C5 through T1 nerve root distribution. Although not definitive on clinical exam or EMG, avulsion injury was suspected due to the presence of Horner's syndrome. MRN was performed 3 months after the initial injury. MIP reconstruction from coronal 3D STIR SPACE demonstrates complete discontinuity of the right brachial plexus (large arrow) with bundling of the lacerated nerve roots and trunks (medium arrow) in the right axilla. Intraoperative electrophysiology confirmed lack of conduction in the enlarged right C5 nerve root (double small arrows), lacerated distally

and commonly enhances with intravenous contrast.^[10] In suspected neuroma-in-continuity on imaging with no clear history of trauma, one should perform contrast MRN to exclude a peripheral nerve sheath tumor or other mass lesion. 3D isotropic imaging is often very useful in demonstrating neuroma-in-continuity (grade IV injury) and neurotmesis (grade V injury) for the reader and the referring physicians alike. Nerve discontinuity in grade V injury shows a clear nerve gap or intervening hemorrhage and/or fibrosis [Figures 8 and 9]. The proximal nerve segments show end-bulb neuromas.^[9] One of the key roles of imaging is to measure the gap between the proximal and distal discontinuous nerve fragments for the purpose of operative management. The radiologist can play an important role in accurately diagnosing Sunderland V injury in a functionally important nerve and inform the surgeon about the length of the gap so that appropriate dimension allograft or autograft can be prepared prior to nerve repair. Therefore, close interrogation with high-resolution imaging to correctly identify abnormalities is essential for treatment planning.^[29,30] Identification of pseudomeningocele does not always mean dorsal nerve root ganglion avulsion as the pre-ganglionic segments may be partially intact.^[31] Therefore, it is important to look at 3D T2W TSE imaging to evaluate the integrity of preganglionic nerve segments and position of dorsal nerve root ganglions. Finally, chronic neuropathy results in atrophic nerve with decreased nerve caliber and relatively increased intra-epineurial fat deposition with atrophic appearance of the fascicles.^[32]

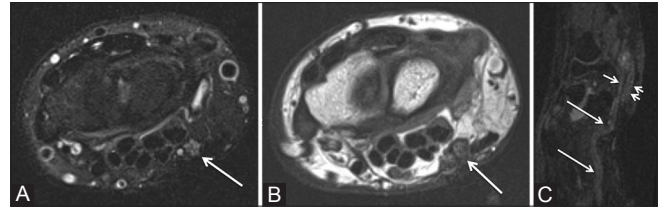


Figure 10 (A-C): Mixed/grade VI injury. A 34 year old woman with history of prior injury to the wrist presented with ulnar neuropathy clinically and on EMG. Axial T2 SPAIR (A) and axial T1W (B) images show homogeneous hyperintensity, uniform fascicular enlargement, and enlargement of the ulnar nerve. Notice thickened hypointense epineurium with perineural scarring from prior injury (B). MIP reconstruction from sagittal 3D DW PSIF image (C) demonstrates hyperintense enlarged and tortuous ulnar nerve with fascicular continuity at the site of injury (large arrows) with normal nerve distally (small arrow) and denervation edema of hypothenar muscles (double small arrows)

Grade VI injury can demonstrate a combination of findings of above grades; however, the diagnostic clues include epineurial thickening due to direct injury, history or mechanism of external injury, and internal nerve heterogeneity from hemorrhage or fibrosis [Figure 10].

An important aspect that enhances the role of MRN is the accurate and uniform reporting of nerve lesion. One should use the same terminology to describe the various grades of nerve injuries as the electrophysiologist and nerve surgeon use in their practice. This will help optimization of pre-operative planning and surgical referrals. In the authors' experience, the terms "mild stretch injury" or "Sunderland grade I injury," "moderate stretch injury" or "Sunderland grade II/III injury," "neuroma-in-continuity" or "Sunderland grade IV injury," "neurotmesis" or "Sunderland grade V injury," and "mixed injury" or "grade VI injury with description of the worse grade of injury" are useful.

Future Directions

It could be further useful to accurately and reliably distinguish grade II, III, and IV injuries as the prognosis varies.^[7,16] Additionally, on imaging, interfascicular edema may decrease the conspicuity of fascicular depiction and decrease the diagnostic accuracy to differentiate grade III from grade IV injury.

Functional diffusion tensor imaging (DTI) may play an important imaging role in this domain. DTI has been shown to be useful in peripheral nerve sheath tumors as it provides insight into the internal microarchitecture that may not be otherwise possible on anatomic neurography.^[22,23,33] Currently, it shows nerves and their abnormalities with relative selectivity due to fat and vessel suppression; however, whether the quantitative measures derived from the DTI data (e.g., fractional anisotropy, mean diffusivity, etc.) are able to determine or differentiate various grades of injuries remains to be tested. A longitudinal

prospective large-scale study with direct surgical and electrophysiologic correlations is essential to evaluate the relative value of DTI in the domain of nerve injury grading. DTI also holds promise in the evaluation of peripheral nerve regeneration following nerve repair and/or reconstruction.^[14,15] In future, MRI contrast agents may be developed and tested to evaluate the functional behavior of various nerve injuries. Finally, one may add time-resolved MRI angiogram for the assessment of regional vascular patency due to the vessel's close proximity to the injured nerves in the common neurovascular bundles.^[34]

Conclusion

MRN helps to distinguish pathologic changes in peripheral nerves allowing for clinically useful grading according to established injury grading schemes and it could play an important role in the evaluation of peripheral nerve injuries.

References

- Martyn CN, Hughes RA. Epidemiology of peripheral neuropathy. *J Neurol Neurosurg Psychiatry* 1997;62:310-8.
- Noble J, Munro CA, Prasad VS, Midha R. Analysis of upper and lower extremity peripheral nerve injuries in a population of patients with multiple injuries. *J Trauma* 1998;45:116-22.
- Siemionow M, Brzezicki G. Chapter 8: Current techniques and concepts in peripheral nerve repair. *Int Rev Neurobiol* 2009;87:141-72.
- Seddon HJ. Three types of nerve injuries. *Brain* 1943;66:237.
- Seddon HJ, Medawar PB, Smith H. Rate of regeneration of peripheral nerves in man. *J Physiol* 1943;102:191-215.
- Seddon HJ. A review of work on peripheral nerve injuries in Great Britain during World War II. *J Nerv Ment Dis* 1948;108:160-8.
- Sunderland S. A classification of peripheral nerve injuries producing loss of function. *Brain* 1951;74:491-516.
- Chhabra A, Andreisek G. *Magnetic Resonance Neurography*. 1st ed. Delhi, India: Jaypee Publishers; 2012. pp 1-8.
- Filler AG, Maravilla KR, Tsuruda JS. MR neurography and muscle MR imaging for image diagnosis of disorders affecting the peripheral nerves and musculature. *Neurol Clin* 2004;22:643-82.
- Chhabra A, Williams EH, Wang KC, Dellon AL, Carrino JA. MR neurography of neuromas related to nerve injury and entrapment with surgical correlation. *AJNR Am J Neuroradiol* 2010;31:1363-8.
- Glaus SW, Johnson PJ, Mackinnon SE. Clinical strategies to enhance nerve regeneration in composite tissue allotransplantation. *Hand Clin* 2011;27:495-509.
- Zhang H, Xiao B, Zou T. Clinical application of magnetic resonance neurography in peripheral nerve disorders. *Neurosci Bull* 2006;22:361-7.
- Yan Y, Johnson PJ, Glaus SW, Hunter DA, Mackinnon SE, Tung TH. A novel model for evaluating nerve regeneration in the composite tissue transplant: The murine heterotopic limb transplant. *Hand (N Y)* 2011;6:304-12.
- Morisaki S, Kawai Y, Umeda M, Nishi M, Oda R, Fujiwara H, et al. *In vivo* assessment of peripheral nerve regeneration by diffusion tensor imaging. *J Magn Reson Imaging* 2011;33:535-42.
- Lehmann HC, Zhang J, Mori S, Sheikh KA. Diffusion tensor imaging to assess axonal regeneration in peripheral nerves. *Exp Neurol* 2010;223:238-44.
- Belzberg AJ. Acute nerve injuries. In: Rengachary SS, Ellenbogen RG, editors. *Principles of Neurosurgery*. 2nd ed. Philadelphia: Elsevier Mosby; 2005. p. 387-95.
- Mackinnon S, Dellon AL. *Diagnosis of nerve injury*. Surgery of the peripheral nerve. NY: Thieme; 1988. p. 74-8.
- Mackinnon S. Reconstruction using distal sensory and motor nerve transfers. Instructional course 25. Annual meeting of the American society for the surgery of the hand. Chicago, Illinois, Sept. 2008.
- Bowen JM. Peripheral nerve electrodiagnostics, electromyography and nerve conduction velocity. In: Hoerlein BF, editor. *Canine Neurology*. Philadelphia: WB Saunders; 1978. p 254.
- Dyck PJ. Invited review: Limitations in predicting pathologic abnormality of nerves from the EMG examination. *Muscle Nerve* 1990;13:371-5.
- Chuang TY, Chiu FY, Tsai YA, Chiang SC, Yen DJ, Cheng H. The comparison of electrophysiologic findings of traumatic brachial plexopathies in a tertiary care center. *Injury*. 2002;33:591-8.
- Viallon M, Vargas MI, Jlassi H, Lövlblad KO, Delavelle J. High-resolution and functional magnetic resonance imaging of the brachial plexus using an isotropic 3D T2 STIR (Short Term Inversion Recovery) SPACE sequence and diffusion tensor imaging. *Eur Radiol* 2008;18:1018-23.
- Vargas MI, Viallon M, Nguyen D, Beaulieu JY, Delavelle J, Becker M. New approaches in imaging of the brachial plexus. *Eur J Radiol* 2010;74:403-10.
- Eppenberger P, Chhabra A, Andreisek G. MR Neurography – Imaging of the peripheral nervous system [German]. *Radiologie up2date* 2012;12:339-55.
- Lee PP, Chalian M, Bizzell C, Williams EH, Rosson GD, Belzberg AJ, et al. Magnetic resonance neurography of common peroneal (fibular) neuropathy. *J Comput Assist Tomogr* 2012;36:455-61.
- Petchprapa CN, Rosenberg ZS, Sconfienza LM, Cavalcanti CF, Vieira RL, Zember JS. MR imaging of entrapment neuropathies of the lower extremity. Part 1. The pelvis and hip. *Radiographics* 2010;30:983-1000.
- Keen NN, Chin CT, Engstrom JW, Saloner D, Steinbach LS. Diagnosing ulnar neuropathy at the elbow using magnetic resonance neurography. *Skeletal Radiol* 2012;41:401-7.
- Bäumer P, Dombert T, Staub F, Kaestel T, Bartsch AJ, Heiland S, et al. Ulnar neuropathy at the elbow: MR neurography – nerve T2 signal increase and caliber. *Radiology*. 2011;260:199-206.
- Du R, Auguste KI, Chin CT, Engstrom JW, Weinstein PR. Magnetic resonance neurography for the evaluation of peripheral nerve, brachial plexus, and nerve root disorders. *J Neurosurg* 2010;112:362-71.
- Aagaard BD, Maravilla KR, Kliot M. MR neurography. MR imaging of peripheral nerves. *Magn Reson Imaging Clin N Am* 1998;6:179-94.
- Terzis JK, Novikov ML. Radiological and electrophysiological detection of nerve roots avulsion in patients with birth related brachial plexus paralysis. *Semin Plast Surg* 2005;19:24-41.
- Thakkar RS, Del Grande F, Thawait GK, Andreisek G, Carrino JA, Chhabra A. Spectrum of high-resolution MRI findings in diabetic neuropathy. *AJR Am J Roentgenol* 2012;199:407-12.
- Chhabra A, Thakkar RS, Andreisek G, Chalian M, Belzberg AJ, Blakeley J, et al. Anatomic MR imaging and functional diffusion tensor imaging of peripheral nerve tumors and tumorlike conditions. *AJNR Am J Neuroradiol* 2013;34:802-7.
- Nielsen YW, Thomsen HS. Contrast-enhanced peripheral MR: Technique and contrast agents. *Acta Radiol* 2012;53:769-77.

Cite this article as: Chhabra A, Ahlawat S, Belzberg A, Andreisek G. Peripheral nerve injury grading simplified on MR neurography: As referenced to Seddon and Sunderland classifications. *Indian J Radiol Imaging* 2014;24:217-24.

Source of Support: Nil, **Conflict of Interest:** None declared.